

Histopathological investigation in porcine infected with torque teno sus virus type 2 by inoculation

Mei et al.

RESEARCH

Open Access

Histopathological investigation in porcine infected with torque teno sus virus type 2 by inoculation

Miao Mei¹, Ling Zhu¹, Yun Wang¹, Zhiwen Xu^{1,2*}, Ling Zhao¹, Xi Peng¹, Yunfei Wu¹, Song Li¹ and Wanzhu Guo¹

Abstract

Background: Porcine torque teno sus virus (TTSuV) is a small icosahedral and non-enveloped virus which contains a single-stranded (ssDNA), circular and negative DNA genome and infects mainly vertebrates and is currently classified into the 'floating' genus Anellovirus of Circoviridae with two species. Viral DNA of both porcine TTSuV species has a high prevalence in both healthy and diseased pigs worldwide and multiple infections of TTSuV with distinct genotypes or subtypes of the same species has been documented in the United States, Europe and Asia. However, there exists no information about histopathological lesions caused by infection with porcine TTSuV2.

Methods: Porcine liver tissue homogenate with 1 ml of 6.91×10^7 genomic copies viral loads of porcine TTSuV2 that had positive result for torque teno sus virus type 2 and negative result for torque teno sus virus type 1 and porcine pseudorabies virus type 2 were used to inoculate specific pathogen-free piglets by intramuscular route and humanely killed at 3,7,10,14,17,21 and 24 days post inoculation (dpi), the control pigs were injected intramuscularly with 1 ml of sterile DMEM and humanely killed the end of the study for histopathological examination routinely processed, respectively.

Results: All porcine TTSuV2 inoculated piglets were clinic asymptomatic but developed myocardial fibroblasts and endocardium, interstitial pneumonia, membranous glomerular nephropathy, and modest inflammatory cells infiltration in portal areas in the liver, foci of hemorrhage in some pancreas islet, a tiny amount red blood cells in venule of muscularis mucosae and outer longitudinal muscle, rarely red blood cells in the microvasculature and infiltration of inflammatory cells (lymphocytes and eosinophils) of tonsil and hilar lymph nodes, infiltration of inflammatory lymphocytes and necrosis or degeneration and focal gliosis of lymphocytes in the paracortical zone after inoculation with porcine TTSuV2-containing tissue homogenate.

Conclusions: Analysis of these presentations revealed that porcine TTSuV2 was readily transmitted to TTSuV-negative swine and that infection was associated with characteristic pathologic changes in specific pathogen-free piglets inoculated with porcine TTSuV2. Those results indicated no markedly histopathological changes happened in those parenchymatous organs, especially the digestive system and immune system when the specific pathogen-free pigs were infected with porcine TTSuV2, hence, to some extent, it was not remarkable pathological agent for domestic pigs at least. So, porcine TTSuV2 could be an unrecognized pathogenic viral infectious etiology of swine. This study indicated a directly related description of lesions responsible for TTSuV2 infection in swine.

Keywords: Torque teno sus virus 2(TTSuV2), Porcine, Histopathological lesions, Hematoxylin and eosin

* Correspondence: abtcxzw@126.com

¹Animal Biotechnology Center, College of Veterinary Medicine of Sichuan Agricultural University, Ya'an 625014, P R China

Full list of author information is available at the end of the article

Background

In 1997, torque teno sus virus (TTSuV) was discovered in Japan in a patient with post-transfusion hepatitis of unknown aetiology [1]. Torque teno sus virus (TTSuV) is a small icosahedral and non-enveloped virus which contains a single-stranded (ssDNA), circular and negative DNA genome and infects mainly vertebrates, such as human, non-primate and domestic species, including domestic swine and wild boar [2-8]. In 2005, torque teno sus virus was firstly classified into the 'floating' genus Anellovirus of Circoviridae by the International Committee on Taxonomy of Viruses, suggesting the new and present name for TTSuV [4,9], and was firstly described as the homologous counterpart of the human TTSuV from domestic pigs in Japan in 2002 [8].

Recently, TTSuVs have attracted markedly interest within the research community [4] and porcine TTSuVs have been detected using PCR assays in pig populations from the United States, Canada, Brazil, Spain, France, Italy, Germany, China, Thailand, Korea, Hungary, Australia and Cuban [10-21], with variable prevalence, those results have determined that porcine TTSuVs are ubiquitous and widely distributed in the world. A recent retrospective study revealed evidence of both genogroups of porcine TTSuV infection in pigs as early as 1985 in Spanish intensive conventional commercial pig farms [22]. In spite of being a single strand DNA virus, the sequences of human TTSuV genome are markedly diverse, containing five groups and 34 genotypes [4,23,24]. The genome of porcine TTSuV is approximately 2.8 kb in length and contains three or four overlapping open reading frames (ORFs) as well as a short stretch of untranslated region with high GC content [25] and investigations in swine have identified two distinct TTSuV genogroups for TTSuV-1 and TTSuV-2 [12]. At present, both genogroups have been defined as species [26].

To date, much attention has been paid to TTSuV infection in other vertebrates [8,27,28], especially pigs [4,10,13,15-17,19-22,29-33]. Even though porcine TTSuVs are ubiquitous in swine, the pathogenesis is not clear [4]. Despite the fact human TTSuV infection is not considered to be directly associated with a specific disease [34], porcine TTSuV has been proven to partially contribute to the experimental induction of porcine dermatitis and nephropathy syndrome (PDNS) associated with the porcine reproductive and respiratory syndrome virus (PRRSV) infection [35], and postweaning multisystemic wasting syndrome (PMWS) associated with PCV-2 infection in a gnotobiotic pig model [36]. Moreover, high prevalence of TTSuVs, especially TTSuV2, have been detected in PMWS pigs [18]. These results suggest that porcine TTSuVs are probably pathogenic in pigs due to synergistic effects with together different viruses acting.

However, further studies will be required to associate TTSuVs infection with specific diseases.

No tissue culture system for TTSuVs propagation has been identified [4]. Although porcine TTSuV is not found to be associated with any swine disease, coinfection of pigs with TTSuV and other known swine pathogens (PMWS, PCV2, PRRSV, PRV) may result in enhanced disease [16,18,31,36-42]. There are also concerns for risk of potential human infection during xenotransplantation and a public health problem. The role of the sows in transmitting porcine TTSuV to piglets and the infection dynamics of both swine TTSuV genogroups (TTSuV1 and TTSuV2) during the lactation period has been studied [29,33]. However, the recent studies is roughly focused on serum sample analysis of sows and piglets based on porcine torque teno virus nucleic acid by conventional nested PCR and real-time PCR assays [18,19,26] and no methods about tissue detection, pathogenesis or cell culture lines studies were conducted, and nothing is known regarding porcine TTSuV2-specific histopathological examination, except that the development of ELISA assay based on expressing of the putative OFR1 capsid protein of PTTSuV2 for the possibility of serological diagnoses [43,44]. The aim of this study was to describe whether the presence of specific histopathological lesions of PTTSuV-2 infection was observed by hematoxylin-eosin stain and olympus light microscope on an intensive pig farm in Sichuan of China.

Results

Control animals displayed no clinical manifestations throughout the study. No obvious gross lesions were observed between the control group and the infected animals on necropsy examination. In totally, specific microscopical lesions were found in the tissues from the twenty-one pigs infection with porcine torque teno sus virus 2 throughout the study, and there existed subtle pathologic changes in the tissues containing myocardial fibroblasts and endocardium, interstitial pneumonia, membranous glomerular nephropathy, and modest inflammatory cells infiltration in portal areas in the liver, foci of hemorrhage in some pancreas islet, a tiny amount red blood cells in venule of muscularis mucosae and outer longitudinal muscle, rarely red blood cells in the microvasculature and infiltration of inflammatory cells (lymphocytes and eosinophils) of tonsil and hilar lymph nodes, infiltration of inflammatory lymphocytes and necrosis or degeneration and focal gliosis of lymphocytes in the paracortical zone after inoculation with the porcine TTSuV2-containing tissue homogenate; these changes were not detected in uninoculated control pigs or pigs injected with tissue homogenate devoid of porcine TTSuV2 genome. Firstly, hyperemia and congestion were

found in the myocardial fibroblasts and endocardium seen in Figure 1a and 1b.

The lung lesions contained of a mild interstitial pneumonia characterized by a slight thickening of the alveolar septa by mononuclear cells and congestion, and bronchial epithelial cells happened defluvia and inflammation infiltration in pulmonary alveolus seen in Figure 2c and 2d.

Figure 3e and 3f illustrated the histopathological findings in the kidney infected with PTTsuv2, slight congestion happened in the renal tube and the degeneration and necrosis or degeneration and focal gliosis were observed in epithelial cells, that's to say membranous glomerular nephropathy. In addition, the ventral cells defluvia of renal capsule were observed in capsular space.

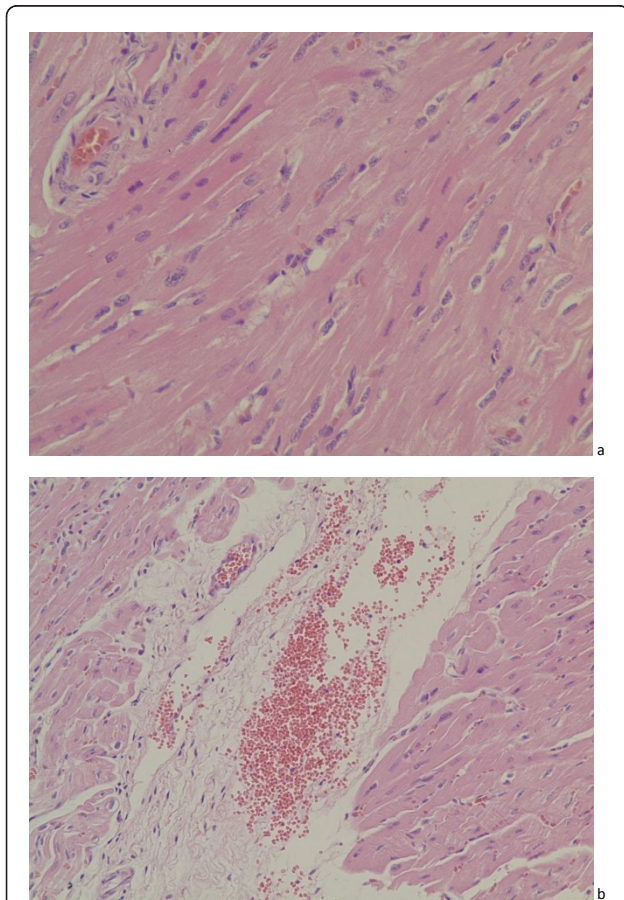


Figure 1 Photomicrograph of heart from two of the pigs. There is hyperemia in artery and subtle congestion among myocardial fibroblasts at 17 dpi. (HE. $\times 400$), and large number of red blood cells distribute in endocardium, but cells of endocardium were not found changes and lesions from a specific pathogen-free pig euthanized at 14 dpi. with the liver homogenate of porcine TTSuV2 (HE. $\times 200$). Those histopathological lesions were marked with arrowheads.

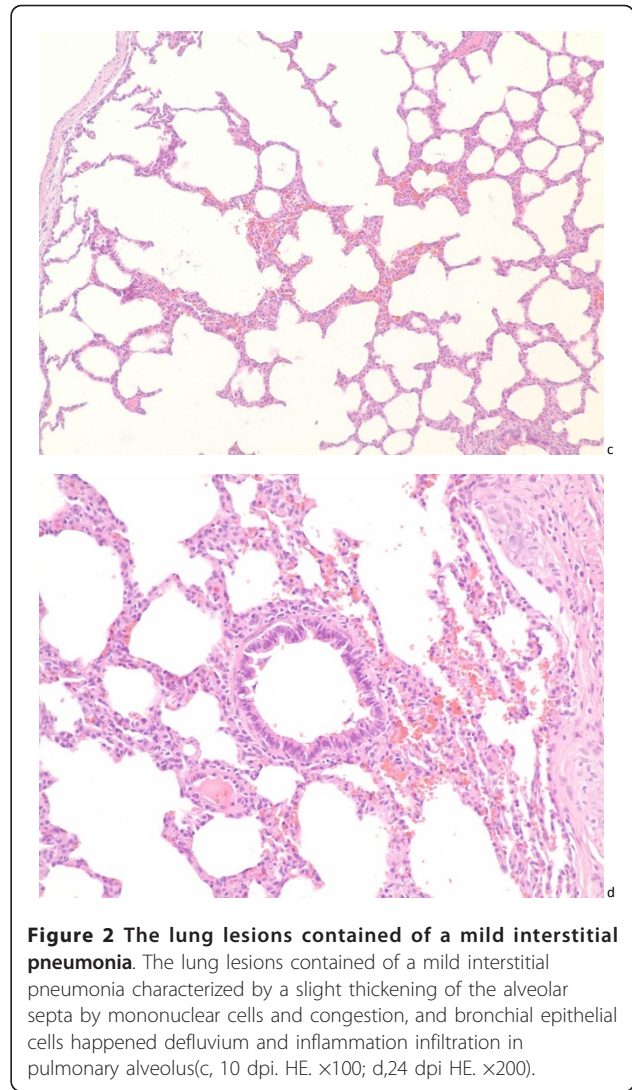
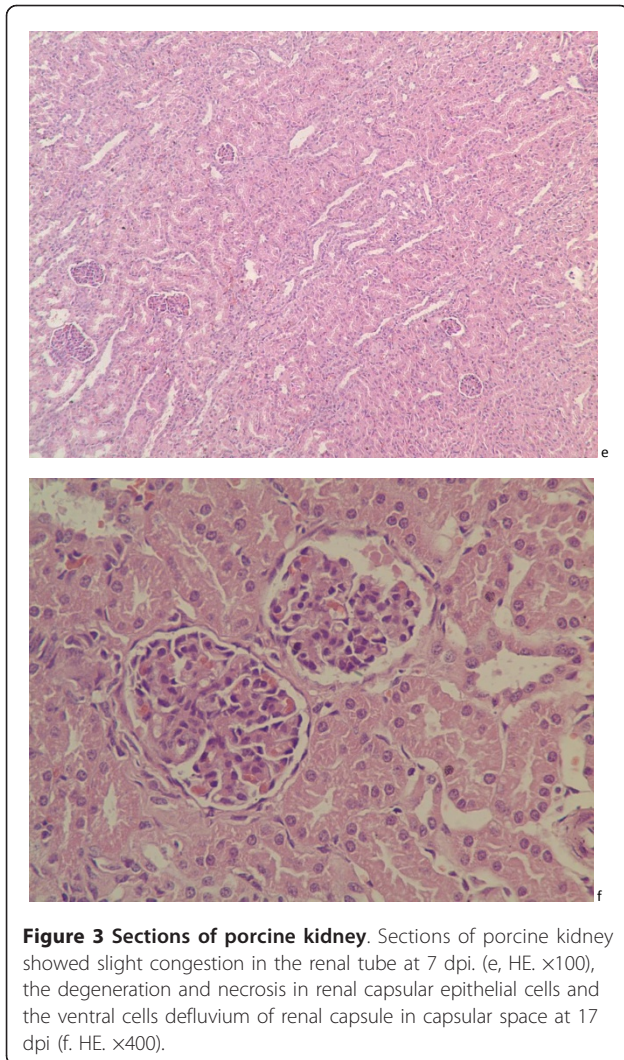


Figure 2 The lung lesions contained of a mild interstitial pneumonia. The lung lesions contained of a mild interstitial pneumonia characterized by a slight thickening of the alveolar septa by mononuclear cells and congestion, and bronchial epithelial cells happened defluvia and inflammation infiltration in pulmonary alveolus(c, 10 dpi. HE. $\times 100$; d,24 dpi HE. $\times 200$).

Figure 4g, h, i, j, k and 4l represented the histopathological changes in the digestive system containing liver, pancreas and duodenum. The sections of liver showed that there existed a tiny amount of red blood cells in the interlobular veins and sinusoid and a bit of inflammatory cells infiltration in portal areas, but no various pathological lesions were observed at other parts of the liver; the photomicrograph of pancreas manifested subtle congestion among pancreas islets and foci of hemorrhage in some pancreas islet, a little of infiltration was inferred as pancreatic juice or electrolyte inner interlobular duct; however, non-specific histopathological lesions of the duodenum except a tiny amount red blood cells in venule of muscularis mucosae and outer longitudinal muscle was observed and could be pictured as normal histological graph.

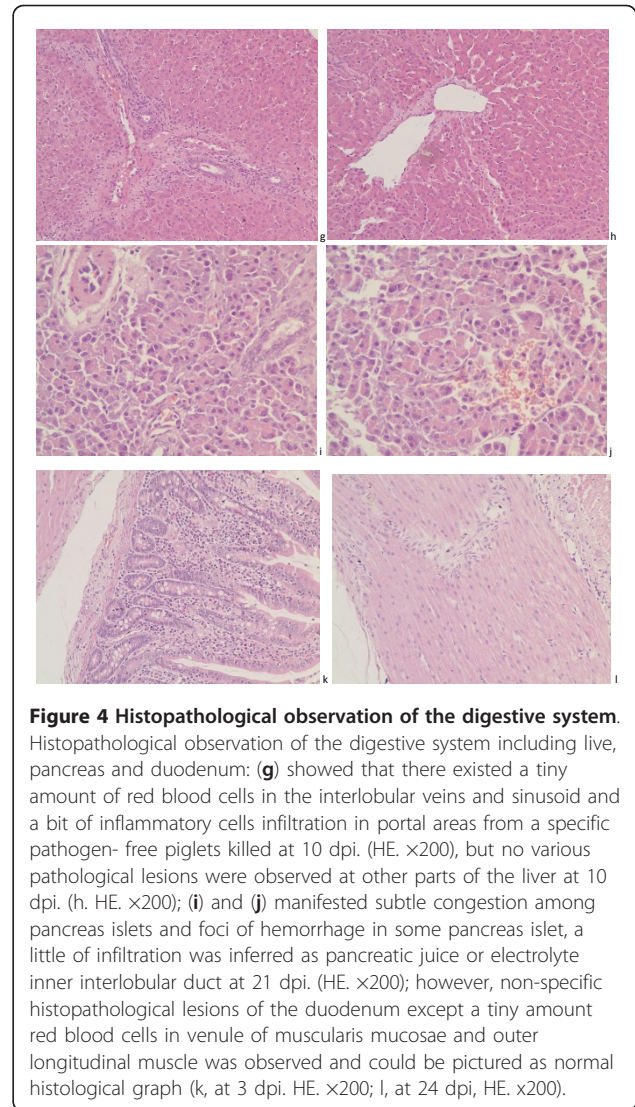
The micrographic pathological changes of the immune system showed in Figure 5m, n, o, p, q, r, s, t, u and 5v



involving in spleen, tonsil, hilar lymph nodes, mesenteric lymph nodes and inguinal lymph nodes collected from five 45 days-age weaned piglets infection with PTTsuv2. With the development of infection, the sections of tonsil, spleen, hilar lymph nodes and mesenteric lymph nodes showed the normal architecture with no special lesions but only rarely red blood cells in the microvasculature and infiltration of inflammatory cells (lymphocytes and eosinophils) of tonsil and hilar lymph nodes marked by black arrowheads. In addition, inguinal lymph nodes' architecture was normal, but congestion, infiltration of inflammatory lymphocytes and necrosis or degeneration and focal gliosis of lymphocytes in the paracortical zone were observed.

Discussion

In the experimental study, porcine TTSuV2 genome were identified in the serum of a conventional pig used as the source material of porcine TTSuV2 for inoculation into



gnotobiotic porcine. TTSuV has been elucidated that it was readily transmitted to young gnotobiotic swine that had negative results for TTSuV genome [45], serial passage of liver tissue homogenate which was extracted twice with chloroform so as to remove infectivity of any extraneous enveloped viruses [45] obtained from the pig with positive result for porcine TTSuV2 and negative result for porcine TTSuV1 and PCV2 by using nPCR and conventional PCR. In pigs euthanized at 1, 3, 7, 10, 14, 17, 21 and 24 days post inoculation. The previous investigations have found a higher positive rate of porcine TTSuV in analyzed reproductive apparatus samples [37], indicating its importance in public hygienics and vertical transmission. Considering its transmission routine [30,46-48], specific pathogen-free pregnant primiparous sows were subjected to produce porcine TTSuVs negative specific pathogen-free piglets.

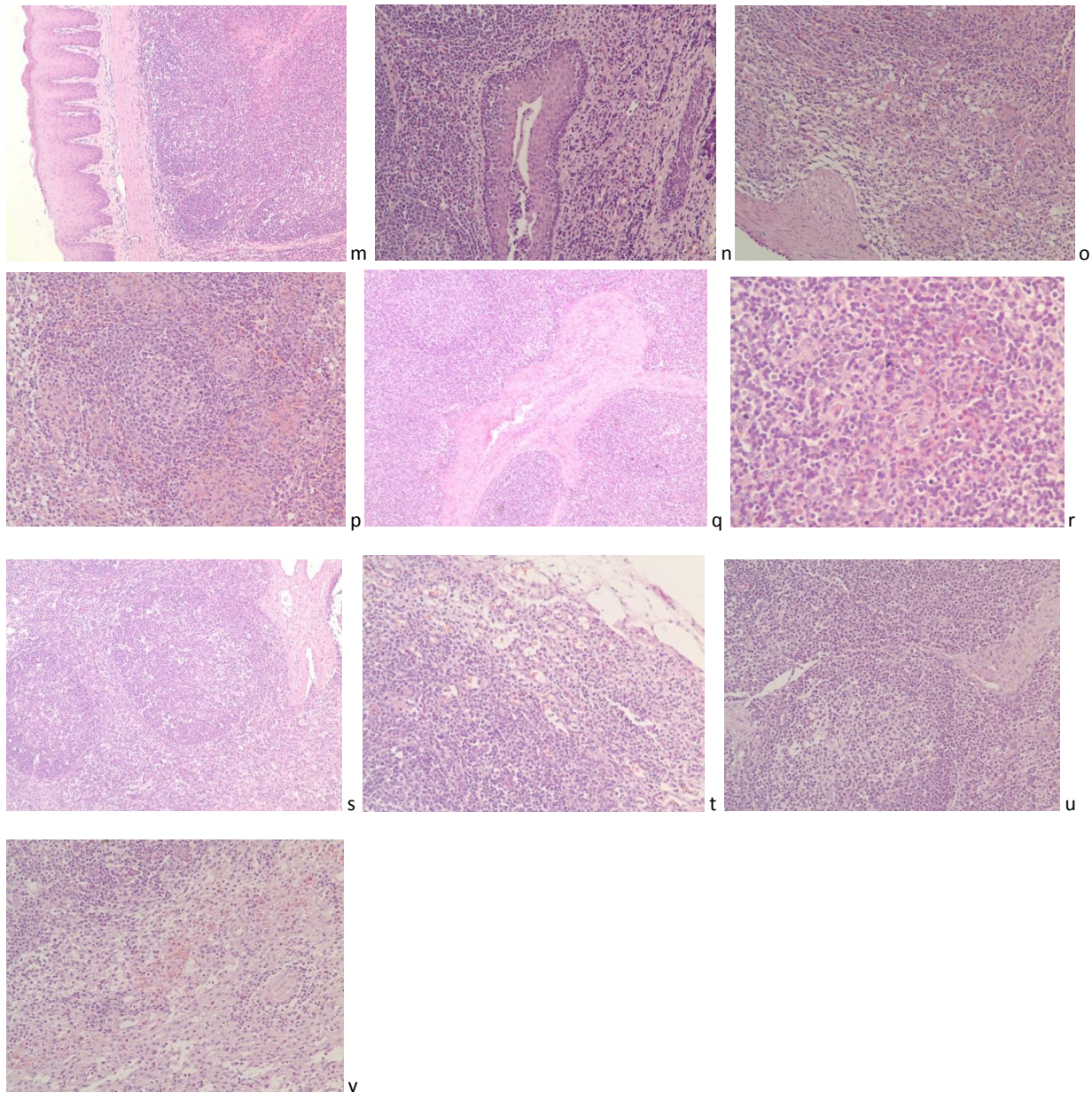


Figure 5 Photomicrograph of the main immune system. Photomicrograph of the main immune system involving in spleen, tonsil, hilar lymph nodes, mesenteric lymph nodes and inguinal lymph nodes collected from experimental groups weaned piglets euthanized at different days post inoculation porcine TTSuV2. With the development of infection, the sections of tonsil, spleen, hilar lymph nodes and mesenteric lymph nodes showed the normal architecture with no special lesions through the study but only rarely red blood cells in the microvasculature and infiltration of inflammatory cells (lymphocytes and eosinophils) of tonsil and hilar lymph nodes marked by black arrowheads (m, o, p, s. HE. $\times 100$; n, t. HE. $\times 200$; r. HE. $\times 400$). In addition, inguinal lymph nodes' architecture was normal, but congestion, infiltration of inflammatory lymphocytes and necrosis or degeneration and focal gliosis of lymphocytes in the paracortical zone were observed at 24 dpi. (u. HE. $\times 100$; v. HE. $\times 200$). The red four-point star, five-point star and rhomboid represent the normal architecture of those immune organs.

The present study evaluated the histopathological lesions of inoculation infection of the porcine Circoviridae family DNA virus torque tero sus virus (TTSuV) in main parenchymatous organs containing heart, lung, kidney, digestive system and immune system tonsil, spleen

and lymph nodes on account of the viral tropism to lymphoid cells [45,49]. The results presented here specific histopathological lesions were conducted by porcine TTSuV2 infection alone in analyzed organs and tissues, there existed subtle pathologic changes in the tissues

containing myocardial fibroblasts and endocardium, interstitial pneumonia, membranous glomerular nephropathy, and modest inflammatory cells infiltration in portal areas in the liver, foci of hemorrhage in some pancreas islet, a tiny amount red blood cells in venule of muscularis mucosae and outer longitudinal muscle, rarely red blood cells in the microvasculature and infiltration of inflammatory cells (lymphocytes and eosinophils) of tonsil and hilar lymph nodes, infiltration of inflammatory lymphocytes, necrosis or degeneration and focal gliosis of lymphocytes in the paracortical zone after inoculation with the porcine TTSuV2-containing tissue homogenate; these changes were not detected in uninoculated control pigs or pigs injected with tissue homogenate devoid of porcine TTSuV2 genome. Although TTSuV seems to be non-pathogenic virus for the domestic pig [37], those results indicated it can induce a certain degree of lesions for some organs of pigs, and the present study was similar to the histopathological lesions via parenteral inoculation of g1-TTSuV-positive tissue homogenates into TTSuV-negative gnotobiotics [45], so it is necessary to compare the different histopathological lesions caused by porcine TTSuVs between single-infection and co-infection. Through the investigation, we found that the main severely microscopic lesions happened at the respiratory system, urinary system and cardiovascular system, however, there existed only minimal injury in the digestive system and immune system, those results indicated no marked histopathological changes happened in those parenchymatous organs, especially the digestive system and immune system when the specific pathogen-free piglets were infected with porcine TTSuV2, hence we can think it was so poor pathological agent for domestic pigs at least.

To date, it has been found that it is common for an individual to coinfect with different genogroups of TTSuV [3] and the role of porcine TTSuV in co-infection with other pathogens has been investigated and demonstrated porcine TTSuV2 is frequently related to PCV2 associated diseases (PCVAD) while compared to porcine TTSuV1 in Spain [18]. In the swine industry, TTSuV is thought to be one of the agents that aggravate clinical manifestation of porcine circovirus-associated disease (PCVAD), a newly emerging, economically devastating disease. However, a researcher verified there were no statically considerable differences in TTSuV viral load between the two genotypes in serum obtained from porcine circovirus-2-negative pigs and PCVAD-affected pigs with real-time quantitative polymerase chain reaction assay, which indicated that TTSuV might not be an etiology of aggravation in PCVAD, and TTSuV genogroup 2 could readily give rise to viremia even in the PCV-2-negative pigs [16]. Other reports indicated that TTSuV1 viral infection facilitated PCVAD

[36]. Interestingly, positive stillborn piglets were always positive with the same genotype as their mothers, but sequencing analysis showed nucleotide diversity of TTSuV genomes from the sows and in stillborns [30]. It was hypothesized that stillborns may be infected with several strains of TTSuV, even from the semen, by the transplacental route [30]. Higher rate of PCV2 DNA in semen (47% of tested samples) and followed by TTSuV2 (11.7%) has been investigated in spite of presenting with a low viral load and all tested semen samples were negative for TTSuV1 [37]. Other investigations published a higher prevalence of TTSuV1 and TTSuV2 in pig semen (55% and 32%, respectively), with no interference on semen quality [47].

Viral persistence and sporadic infection may be a risk factor for dissemination of PCV2 or TTSuV to negative sows, potentially resulting in reproductive failures. This irregular pattern of infection also paid attention to the fact that boars which tested negative on the first collection may be positive in subsequent ejaculates. A periodic monitoring for PCV2 or TTSuV2 must be established in boar community. PCV2 and TTSuV2 presence in semen samples of younger animals may indicate a recent infection or may even be related to management or measures of stress. Morphology and sperm motility analysis did not indicate significant diversities between PCV2 positive and negative boars. All semen samples tested presented motility superior to 80%, which could allow their use for processing, dilution and artificial insemination. No manifestation of reproductive failure was associated with this co-infection. These findings raised the problem of the importance of these viral infections in the pathology of reproductive failures [37]. Although TTSuV2 was detected in almost 50% of the sows studied, the association with PCV2 co-infection and reproductive failure was statistically insignificant difference [37].

Moreover, in both species, genotype 2 is more prevalent than genotype 1. In domestic pig, TTSuV2 infections have been shown to be more common in pigs affected by postweaning multisystemic wasting syndrome (PMWS), a porcine circovirus type 2 (PCV2) disease, than non-PMWS affected pigs [18,49]. Due to its ubiquitous nature in both domestic pig and wild boar, it is likely that TTSuV has adapted to both species and is circulating within these species with similar prevalence [3]. On account of lack in a culture system or an animal model to support the viral multiplication, the infection and replication mechanisms and the pathogenicity of TTSuV are still unknown. Some reports have indicated that several different genotypes of TTSuV are considered responsible for human diseases [50]. However, TTSuV has been indicated to be a commensal in normal conditions which should benefit for the host, this is an intriguing aspect hitherto unexplored with TTSuV [51].

In 2006, a surprising finding was found some marked differences in prevalence of TTSuV genotype 2 were induced by age, that is to say that younger animals were more often infected than adults and sub-adults, it would be interesting to compare such dynamics in wild boar with that in domestic pig since the same agents apparently infect both species, prevalence of both TTSuV genotypes was higher in females than males, although only important for genotype 2. In addition, there lack in comparison patterns with domestic pigs or other species that suffer from TTSuV infection [3].

Up to now, to our knowledge, the only available method for detection of TTSuV is focused on nucleic acid detection, such as nested polymerase chain reaction (nPCR) [18], quantitative PCR (qPCR) [16], and enzyme-linked immunosorbent assay (ELISA) based on ORF1 of porcine TTSuV2 has presently been investigated but still not has been applied clinically [44]. To date, no tissue culture system and little information for detection method of pathology has been available for the propagation of the virus. Further study of TTSuV pathology is required to answer those lesions of single infection of porcine TTSuV or co-infection with other agents, and diverse technologies are required for defining the role of TTSuV in clinics and public health. The pathogenesis of porcine TTSuV infection and its link with specific diseases are as yet undetermined. This result maybe be considered as important descriptive for the histological lesions caused by infection with porcine TTSuV type 2. In this study, it, to some extent, was lack of scientific by using liver homogenate containing porcine TTSuV2 genome to inoculate the specific pathogen-free piglets, because it was difficult to rule out others non-enveloped viral genomes contamination, despite non-infecting agents were isolated via marc145 and vero cells to purify the homogenate in our previous study, so we propose the primary task of researchers is to seek a new cell culture system to separate and isolate porcine torque teno sus virus.

Conclusions

Analysis of these presentations revealed that porcine TTSuV2 was readily transmitted to TTSuV-negative swine and that infection was associated with characteristic pathologic changes in specific pathogen-free piglets inoculated with porcine TTSuV2. Those results indicated no markedly histopathological changes happened in those parenchymatous organs, especially the digestive system and immune system when the specific pathogen-free pigs were infected with porcine TTSuV2, hence, to some extent, it was not remarkable pathological agent for domestic pigs at least. So, porcine TTSuV2 could be an unrecognized pathogenic viral infectious etiology of swine.

This study indicated a directly related description of lesions responsible for TTSuV2 infection in swine.

Methods

Experimental animals

Date-mated specific pathogen-free pregnant primiparous sows fetched in Canada were purchased from a new constructed pigfarm located in Chongqing and transported to National Animal Experimental Teaching Demonstration Center of Sichuan Agricultural University for caesarian section of specific pathogen-free piglets litters using methods described elsewhere [52]. Twenty-four 28-day-old specific pathogen-free piglets which were screened for the absence of PCVs, genogroup 1 and genogroup 2-TTSuV DNA through nested PCR used for histopathological examination for porcine infection with TTSuV genogroup 2.

Source of virus and detection

Porcine torque teno sus virus 2 was derived from 20% (w/v) liver tissue homogenate which was extracted twice with chloroform so as to remove infectivity of any extraneous enveloped viruses [45] and was designated as infection with porcine TTSuV2 by nPCR not with PCV2 by use of PCR assay, and collected from a 6-week-old clinically asymptomatic pig and tested negative for classic swine fever virus (CSFV), porcine reproductive and respiratory syndrome virus (PRRSV), porcine pseudorabies virus (PRV), Japanese encephalitis virus (JEV), porcine parvovirus (PPV), transmissible gastroenteritis virus (TGEV), porcine circovirus type 2 (PCV2), swine influenza virus (SIV), porcine cytomegalo virus (PCMV) by IFA, RT-PCR, multiple-PCR, nPCR or conventional PCR based on those viral genomic untranslated regions or specific genes, and the aqueous phase was frozen at -70°C by Animal Biotechnological Center of Sichuan Agricultural University, and the viral DNA loads (6.91×10^7 genomic copies/ml) is determined by SYBR green-based real-time quantitative PCR.

Experimental design

Twenty-four 28-day-old specific pathogen-free piglets were randomly divided two groups, housed separately in the experimental animal houses at National Animal Experimental Teaching Demonstration Center of Sichuan Agricultural University, twenty-one piglets used as experimental group which were inoculated by intramuscular route with 1 ml of 6.91×10^7 genomic copies viral loads of porcine TTSuV2 liver tissue homogenate and humanely killed at 3,7,10,14,17,21 and 24 days post inoculation (dpi). The three remaining pigs, which were used as control pigs, were injected intramuscularly with 1 ml of sterile Dulbecco's modified Eagle's medium (DMEM, Gibco, USA), supplemented with 10% (v/v)

fetal calf serum (FCS, Gibco, USA), 100 IU/ml of streptomycin and penicillin, respectively, and humanely killed the end of the study.

Histopathological examination

All pigs were subjected to gross necropsy examination and main tissues and organs samples for microscopical examination were collected from each pig at the same time of necropsy. These samples contained portions of heart, liver, spleen, lung, kidney, hilar lymph nodes, mesenteric lymph nodes, inguinal lymph nodes, pancreas, tonsil and duodenum for histopathological examination. All tissues were fixed in 10% neutral buffered formalin for 24-48 hours and routinely processed and embedded in paraffin wax. Sections were cut into slices with 4 ~ 5 micrometer thick and stained with hematoxylin and eosin (HE). Those slices were detected under a light microscope for conventional morphological evaluation.

Acknowledgements

This research was supported by Program of Changjiang Scholars and innovative Research Team in University (IRT0848), Miao Mei and Ling Zhu contributed equally to the work, Zhiwen Xu is the corresponding author. Full list of authors information is available at the end of the article. Kejie Cheng helped the authors perform the sections for this work, Xianbiao Gao and Qing Yu helped read the changes caused by the virus studied. Key Laboratory of Animal Disease and Human Health of Sichuan Province & Animal Biotechnology Center, College of Veterinary Medicine of Sichuan Agricultural University, 46# Xinkang Road, Yucheng district, Ya'an 625014, Sichuan province of P. R. China. Tel.: +86 835 2885846; fax: +86 835 2885302; E-mail address: abtcxzw@126.com.

Author details

¹Animal Biotechnology Center, College of Veterinary Medicine of Sichuan Agricultural University, Ya'an 625014, P R China. ²Key Laboratory of Animal Disease and Human Health, College of Veterinary Medicine of Sichuan Agricultural University, Ya'an 625014, P R China.

Authors' contributions

MM, LZ carried out most of the experiments and drafted the manuscript. ZWX and WZG critically revised the manuscript and the experimental design. YW, XP, LZ, YFW and SL helped with the study. All of the authors read and approved the final version of the manuscript.

Competing interests

The authors declare that they have no competing interests.

Received: 11 July 2011 Accepted: 15 December 2011

Published: 15 December 2011

References

1. Nishizawa T, Okamoto H, Konishi K, Yoshizawa H, Miyakawa Y, Mayumi M: A Novel DNA Virus (TTV) Associated with Elevated Transaminase Levels in Posttransfusion Hepatitis of Unknown Etiology. *Biochem Biophys Res Commun* 1997, **241**:92-97.
2. Mushahwar IK, Erker JC, Muerhoff AS, Leary TP, Simons JN, Birkenmeyer LG, Chalmers ML, Pilot-Matias TJ, Desai SM: Molecular and biophysical characterization of TT virus: evidence for a new virus family infecting humans. *Proc Natl Acad Sci USA* 1999, **96**:3177-3182.
3. Martinez L, Kekarainen T, Sibila M, Ruiz-Fons F, Vidal D, Gortazar C, Segales J: Torque teno virus (TTV) is highly prevalent in the European wild boar (*Sus scrofa*). *Vet Microbiol* 2006, **118**:223-229.
4. Kekarainen T, Segalés J: Torque teno virus infection in the pig and its potential role as a model of human infection. *The Veterinary J* 2009, **180**:163-168.
5. Leary TP, Erker JC, Chalmers ML, Desai SM, Mushahwar IK: Improved detection systems for TT virus reveal high prevalence in humans, non-human primates and farm animals. *J Gen Virol* 1999, **80**:2115.
6. Okamoto H, Akahane Y, Ukita M, Fukuda M, Tsuda F, Miyakawa Y, Mayumi M: Fecal excretion of a nonenveloped DNA virus (TTV) associated with posttransfusion non-A-G hepatitis. *J Med Virol* 1998, **56**:128-132.
7. Okamoto H, Nishizawa T, Kato N, Ukita M, Ikeda H, Iizuka H, Miyakawa Y, Naito Y, Yoshikawa A: Genomic characterization of TT viruses (TTVs) in pigs, cats and dogs and their relatedness with species-specific TTVs in primates and tupaia. *J Gen Virol* 2002, **83**:1291-1297.
9. Biagini P: Classification of TTV and related viruses (anelloviruses). *Curr Top Microbiol Immunol* 2009, **331**:21-33.
10. Takács M, Dencs Á, Csiszár C, Hettmann A, Rusvai E, Szomor KN, Pálfi V, Nagy B: First description of swine Torque teno virus (TTV) and detection of a new genogroup in Hungary: short communication. *Acta Veterinaria Hungarica* 2008, **56**:547-553.
11. Pérez LJ, Arce HD, Frías MT, Perera CL, Ganges L: Molecular detection of Torque teno virus in lymphoid tissues in concomitant infections with other porcine viral pathogens. *Res Veterinary Sci* 2011, doi:10.1016/j.rvsc.2011.1002.1012.
12. Niel C, Diniz-Mendes L, Devalle S: Rolling-circle amplification of Torque teno virus (TTV) complete genomes from human and swine sera and identification of a novel swine TTV genogroup. *J Gen Virol* 2005, **86**:1343-1347.
13. McKeown N, Fenaux M, Halbur P, Meng X: Molecular characterization of porcine TT virus, an orphan virus, in pigs from six different countries. *Veterinary Microbiol* 2004, **104**:113-117.
14. Martelli F, Caprioli A, Di Bartolo I, Cibin V, Pezzotti G, Ruggeri F, Ostanello F: Detection of swine torque teno virus in Italian pig herds. *J Veterinary Med, Ser B* 2006, **53**:234-238.
15. Liu X, Gu W, Guo X, Ge X, Chen Y, Yang H: Prevalence of torque teno virus infection in pig herds in China. *Veterinary Record* 2011, **168**:410.
16. Lee S, Sunyoung S, Jung H, Shin J, Lyoo YS: Quantitative detection of porcine Torque teno virus in Porcine circovirus-2-negative and Porcine circovirus-associated disease-affected pigs. *J Veterinary Diagnostic Invest* 2010, **22**:261-264.
17. Lang C, S Illner H, Barz A, Ladinig A, Langhoff R, Weissenböck H, Kekarainen T, Segalés J, Ritzmann M: Investigation of the prevalence of swine torque teno virus in Austria. *Berliner und Münchener tierärztliche Wochenschrift* 2011, **124**:142-147.
18. Kekarainen T, Sibila M, Segales J: Prevalence of swine Torque teno virus in post-weaning multisystemic wasting syndrome (PMWS)-affected and non-PMWS-affected pigs in Spain. *J Gen Virol* 2006, **87**:833-837.
19. Gallei A, Pesch S, Eising WS, Keller C, Ohlinger VF: Porcine Torque teno virus: Determination of viral genomic loads by genogroup-specific multiplex rt-PCR, detection of frequent multiple infections with genogroups 1 or 2, and establishment of viral full-length sequences. *Veterinary Microbiol* 2010, **143**:202-212.
20. Bigarré L, Beven V, De Boissésion C, Grasland B, Rose N, Biagini P, Jestin A: Pig anelloviruses are highly prevalent in swine herds in France. *J Gen Virol* 2005, **86**:631-635.
21. Aramouni M, Segalés J, Cortey M, Kekarainen T: Age-related tissue distribution of swine Torque teno virus 1 and 2. *Veterinary Microbiol* 2010, **146**:350-353.
22. Segalés J, Martínez-Guino L, Cortey M, Navarro N, Huerta E, Sibila M, Pujols J, Kekarainen T: Retrospective study on swine Torque teno virus genogroups 1 and 2 infection from 1985 to 2005 in Spain. *Veterinary Microbiol* 2009, **134**:199-207.
23. Biagini P, Gallian P, Cantaloube JF, Attoui H, de Micco P, de Lamballerie X: Distribution and genetic analysis of TTV and TTMV major phylogenetic groups in French blood donors. *J Med Virol* 2006, **78**:298-304.

24. Biagini P, De Micco P, De Lamballerie X: **Identification of a third member of the Anellovirus genus ("small anellovirus") in French blood donors.** *Arch Virology* 2006, **151**:405-408.
25. Zhu C, Shan T, Cui L, Luo X, Liu Z, Tang S, Liu Z, Yuan C, Lan D, Zhao W: **Molecular detection and sequence analysis of feline Torque teno virus (TTV) in China.** *Virus Res* 2011, doi:10.1016/j.virusres.2010.1012.1008.
26. Huang Y, Dryman B, Harrall K, Vaughn E, Roof M, Meng X: **Development of SYBR green-based real-time PCR and duplex nested PCR assays for quantitation and differential detection of species-or type-specific porcine Torque teno viruses.** *J Virological Methods* 2010, **170**:140-146.
27. Zhu CX, Shan TL, Cui L, Luo XN, Liu ZJ, Tang SD, Liu ZW, Yuan CL, Lan DL, Zhao W, Hua XG: **Molecular detection and sequence analysis of feline Torque teno virus (TTV) in China.** *Virus Res* 2010, **156**:13-16.
28. Okamoto H: **TT viruses in animals.** *Curr Top Microbiol Immunol* 2009, **331**:35-52.
29. Sibila M, Martinez-Guino L, Huerta E, Mora M, Grau-Roma L, Kekarainen T, Segales J: **Torque teno virus (TTV) infection in sows and suckling piglets.** *Vet Microbiol* 2009, **137**:354-358.
30. Martinez-Guino L, Kekarainen T, Segales J: **Evidence of Torque teno virus (TTV) vertical transmission in swine.** *Theriogenology* 2009, **71**:1390-1395.
31. Martinez-Guino L, Kekarainen T, Maldonado J, Aramouni M, Llorens A, Segales J: **Torque teno sus virus (TTV) detection in aborted and slaughterhouse collected foetuses.** *Theriogenology* 2010, **74**:277-281.
32. Aramouni M, Segalés J, Sibila M, Martin-Valls G, Nieto D, Kekarainen T: **Torque teno sus virus 1 and 2 viral loads in postweaning multisystemic wasting syndrome (PMWS) and porcine dermatitis and nephropathy syndrome (PDNS) affected pigs.** *Veterinary Microbiol* 2011.
33. Sibila M, Martinez-Guino L, Huerta E, Llorens A, Mora M, Grau-Roma L, Kekarainen T, Segales J: **Swine torque teno virus (TTV) infection and excretion dynamics in conventional pig farms.** *Vet Microbiol* 2009, **139**:213-218.
34. Jelcic I, Hotz-Wagenblatt A, Hunziker A, Zur Hausen H, De Villiers EM: **Isolation of multiple TT virus genotypes from spleen biopsy tissue from a Hodgkin's disease patient: genome reorganization and diversity in the hypervariable region.** *J Virol* 2004, **78**:7498-7507.
35. Krakowka S, Hartunian C, Hamberg A, Shoup D, Rings M, Zhang Y, Allan G, Ellis JA: **Evaluation of induction of porcine dermatitis and nephropathy syndrome in gnotobiotic pigs with negative results for porcine circovirus type 2.** *Am J Veterinary Res* 2008, **69**:1615-1622.
36. Ellis JA, Allan G, Krakowka S: **Effect of coinfection with genogroup 1 porcine torque teno virus on porcine circovirus type 2-associated postweaning multisystemic wasting syndrome in gnotobiotic pigs.** *Am J Veterinary Res* 2008, **69**:1608-1614.
37. Ritterbusch G, Sa RCA, Mores N, Simon N, Zanella E, Coldebella A, Ciacci-Zanella J: **Natural co-infection of torque teno virus and porcine circovirus 2 in the reproductive apparatus of swine.** *Res Veterinary Sci* 2011, doi:10.1016/j.rvsc.2011.1004.1001.
38. Krakowka S, Ellis J, Meehan B, Kennedy S, McNeilly F, Allan G: **Viral wasting syndrome of swine: experimental reproduction of postweaning multisystemic wasting syndrome in gnotobiotic swine by coinfection with porcine circovirus 2 and porcine parvovirus.** *Veterinary Pathol Online* 2000, **37**:254-263.
39. Kennedy S, Moffett D, McNeilly F, Meehan B, Ellis J, Krakowka S, Allan G: **Reproduction of lesions of postweaning multisystemic wasting syndrome by infection of conventional pigs with porcine circovirus type 2 alone or in combination with porcine parvovirus.** *J Comp Pathol* 2000, **122**:9-24.
40. Ellis J, Bratanich A, Clark E, Allan G, Meehan B, Haines D, Harding J, West K, Krakowka S, Konoby C: **Coinfection by porcine circoviruses and porcine parvovirus in pigs with naturally acquired postweaning multisystemic wasting syndrome.** *J Veterinary Diagnostic Invest* 2000, **12**:21-27.
41. Allan G, McNeilly F, Ellis J, Krakowka S, Meehan B, McNair I, Walker I, Kennedy S: **Experimental infection of colostrum deprived piglets with porcine circovirus 2 (PCV2) and porcine reproductive and respiratory syndrome virus (PRRSV) potentiates PCV2 replication.** *Arch Virol* 2000, **145**:2421-2429.
42. Rovira A, Balasch M, Segalés J, Garcia L, Plana-Duran J, Rosell C, Ellerbrok H, Mankertz A, Domingo M: **Experimental inoculation of conventional pigs with porcine reproductive and respiratory syndrome virus and porcine circovirus 2.** *Arch Virol* 2002, **76**:3232-3239.
43. Huang Y, Ni Y, Dryman B, Meng X: **Multiple infection of porcine Torque teno virus in a single pig and characterization of the full-length genomic sequences of four US prototype PTTV strains: implication for genotyping of PTTV.** *Virol* 2010, **396**:289-297.
44. Huang Y, Harrall K, Dryman B, Beach N, Kenney S, Opriessnig T, Vaughn E, Roof M, Meng X: **Expression of the putative ORF1 capsid protein of porcine Torque teno sus virus 2 (TTSuV2) and development of Western blot and ELISA serodiagnostic assays: Correlation between TTSuV2 viral load and IgG antibody level in pigs.** *Virus Res* 2011, doi:10.1016/j.virusres.2011.1003.1013.
45. Krakowka S, Ellis J: **Evaluation of the effects of porcine genogroup 1 torque teno virus in gnotobiotic swine.** *Am J Veterinary Res* 2008, **69**:1623-1629.
46. Pozzuto T, Mueller B, Meehan B, Ringler SS, McIntosh KA, Ellis JA, Mankertz A, Krakowka S: **In utero transmission of porcine torque teno viruses.** *Veterinary Microbiol* 2009, **137**:375-379.
47. Kekarainen T, Lopez-Soria S, Segales J: **Detection of swine Torque teno virus genogroups 1 and 2 in boar sera and semen.** *Theriogenology* 2007, **68**:966-971.
48. Brassard J, Gagné MJ, Lamoureux L, Inglis G, Leblanc D, Houde A: **Molecular detection of bovine and porcine Torque teno virus in plasma and feces.** *Veterinary Microbiol* 2008, **126**:271-276.
49. Segales J, Allan GM, Domingo M: **Porcine circovirus diseases.** *Anim Health Res Rev* 2005, **6**:119-142.
50. Takahashi K, Hoshino H, Ohta Y, Yoshida N, Mishiro S: **Very high prevalence of TT virus (TTV) infection in general population of Japan revealed by a new set of PCR primers.** *Hepatology Res* 1998, **12**:233-239.
51. Griffiths P: **Time to consider the concept of a commensal virus?** *Rev Med Virol* 1999, **9**:73-74.
52. Krakowka S, Eaton K: **Helicobacter pylori infection in gnotobiotic piglets: a model of human gastric bacterial disease.** *Adv Swine Biomed Res* 1996, **2**:779-810.

doi:10.1186/1743-422X-8-545

Cite this article as: Mei et al.: Histopathological investigation in porcine infected with torque teno sus virus type 2 by inoculation. *Virology Journal* 2011 **8**:545.

Submit your next manuscript to BioMed Central and take full advantage of:

- Convenient online submission
- Thorough peer review
- No space constraints or color figure charges
- Immediate publication on acceptance
- Inclusion in PubMed, CAS, Scopus and Google Scholar
- Research which is freely available for redistribution

Submit your manuscript at
www.biomedcentral.com/submit

