

Meeting abstract

Open Access

## I 104 The volumetric bull's eye plot

Maurice Termeer\*<sup>1</sup>, Javier Oliván Bescós<sup>2</sup>, Marcel Breeuwer<sup>2</sup>, Anna Vilanova<sup>3</sup>, Frans Gerritsen<sup>2</sup> and Eduard Gröller<sup>1</sup>

Address: <sup>1</sup>Vienna University of Technology, Vienna, Austria, <sup>2</sup>Philips Medical Systems, Best, The Netherlands and <sup>3</sup>Eindhoven University of Technology, Eindhoven, The Netherlands

\* Corresponding author

from 11<sup>th</sup> Annual SCMR Scientific Sessions  
Los Angeles, CA, USA. 1–3 February 2008

Published: 22 October 2008

*Journal of Cardiovascular Magnetic Resonance* 2008, **10**(Suppl 1):A229 doi:10.1186/1532-429X-10-S1-A229

This abstract is available from: <http://jcmr-online.com/content/10/S1/A229>

© 2008 Termeer et al; licensee BioMed Central Ltd.

### Introduction

The bull's eye plot is a commonly used schematic for the visualization of quantitative late enhancement cardiac MRI data. It gives an intuitive overview of the viability of the entire left ventricular myocardium in a single diagram. However, common implementations do not provide a continuous transition between slices and provide poor or no information about the exact location and transmural-ity of non-viable tissue.

### Purpose

We propose a novel visualization technique that relieves the drawbacks of the bull's eye plot but maintains its advantages. Our hypothesis is that our technique will enable a more accurate assessment of the relation between viable and non-viable myocardial tissue (scar).

### Methods

Short-axis late enhancement cardiac MRI acquisitions consist of 10–20 slices. We segment the left-ventricular myocardium in all slices using manually drawn contours on both the epicardium and the endocardium. The segmented myocardium is subsequently unfolded along the long axis and reformatted to form a thin cylinder (Figure 1a). In this process myocardial cross-sections are mapped to equidistant rings within this cylinder. The volumetric nature of the myocardium is preserved during the unfolding.

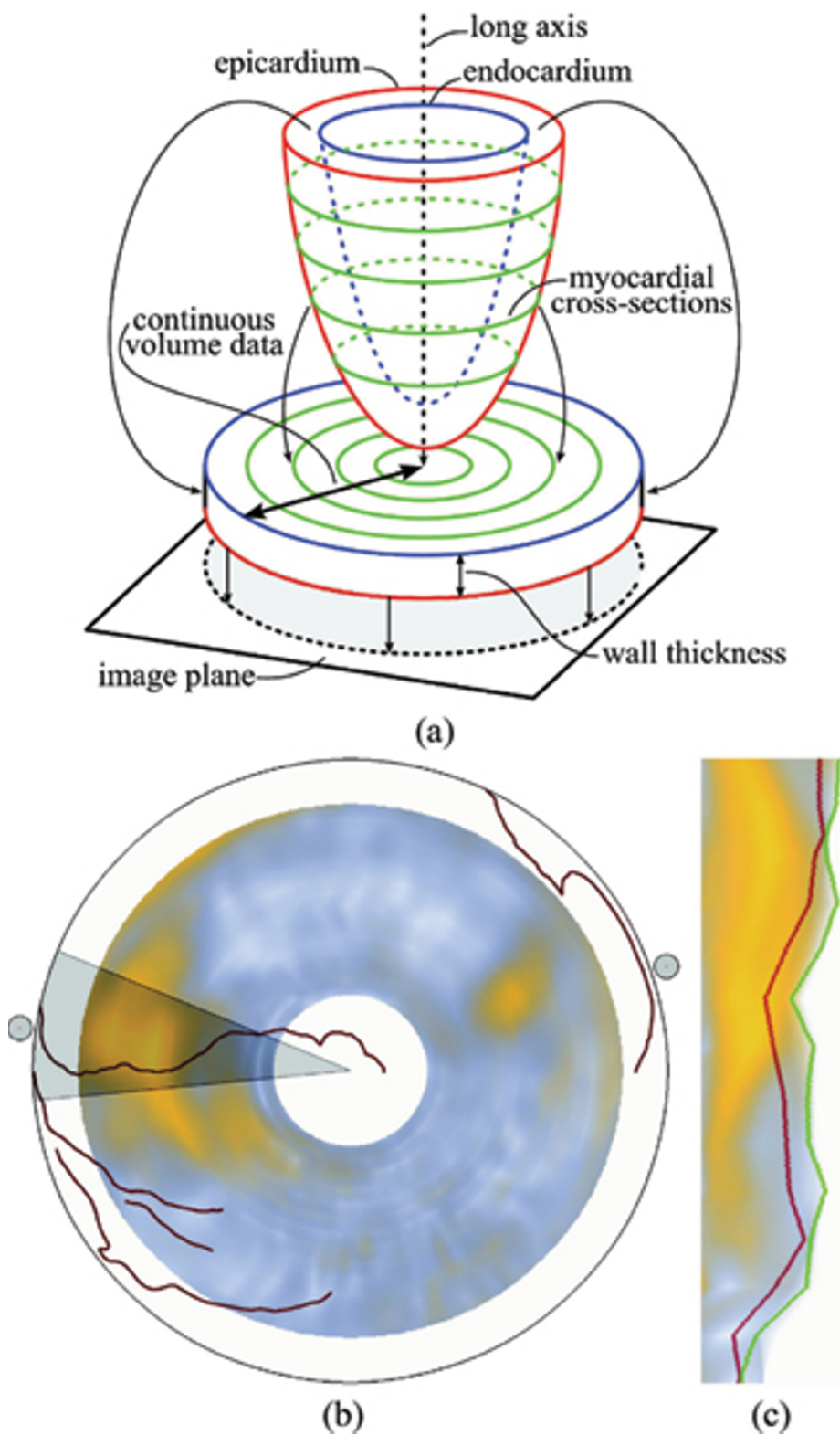
A projection of the cylinder is generated using the technique of volume rendering (Figure 1b). The viewing direc-

tion in this projection is oriented from the apex towards the base of the ventricle. This makes the viewer perceive the endocardium to be behind the epicardium. This view is further augmented with the main coronary arteries extracted from a whole heart MRI scan (150 slices, SSFP). Furthermore, two dots indicating the points where the left and right-ventricular myocardial connect are added. A thin slab perpendicular to the long axis within the cylinder can be selected for exclusive rendering, providing a method of visualizing only epicardial or endocardial viability.

To investigate scar transmural-ity, the user can select a wedge-shaped region of interest. Figure 1c shows the transmural-ity of that region by projecting it from its side. The unfolding method is modified for this projection to compensate for distortions due to the shape of the selected region. Since the wall thickness may vary within the region of interest, lines indicating the minimum and maximum wall thickness in the selected region are displayed.

### Results

The long-axis projection provides a smooth overview of the viability due to the unfolding method that preserves the continuous, volumetric nature of the myocardium. This also causes the resolution of the diagram to increase when more slices are acquired. The additional context information (i.e., coronary arteries) allows for easier interpretation of the location of any scar. Due to the close relation to the bull's eye plot, we believe that clinical



**Figure 1**

The volumetric bull's eye plot is a novel visualization method that provides a smooth and comprehensive overview of the location and transmuralty of scar from a cardiac MRI late enhancement scan.

adoption will be easy. The transmural view provides detailed information on the distribution of scar within the myocardium. The preservation of wall thickness allows for judgment of the location and extent of the scar in relation to healthy tissue.

### Conclusion

Our novel volumetric bull's eye plot allows for a comprehensive assessment of viability and scar transmural extent thanks to its continuous nature and the additional context information provided.

Publish with **BioMed Central** and every scientist can read your work free of charge

*"BioMed Central will be the most significant development for disseminating the results of biomedical research in our lifetime."*

Sir Paul Nurse, Cancer Research UK

Your research papers will be:

- available free of charge to the entire biomedical community
- peer reviewed and published immediately upon acceptance
- cited in PubMed and archived on PubMed Central
- yours — you keep the copyright

Submit your manuscript here:  
[http://www.biomedcentral.com/info/publishing\\_adv.asp](http://www.biomedcentral.com/info/publishing_adv.asp)

