

Case report

Open Access

Altered decorin expression of systemic sclerosis by UVA I (340–400 nm) phototherapy: Immunohistochemical analysis of 3 cases

Hiroo Sawada*, Zenzo Isogai and Akimichi Morita

Address: Department of Geriatric and Environmental Dermatology, Nagoya City University Graduate School of Medical Sciences, Nagoya 467-8601, Japan

Email: Hiroo Sawada* - shiroo@med.nagoya-cu.ac.jp; Zenzo Isogai - zenzo@med.nagoya-cu.ac.jp; Akimichi Morita - amorita@med.nagoya-cu.ac.jp

* Corresponding author

Published: 12 March 2003

Received: 12 December 2002

BMC Dermatology 2003, 3:2

Accepted: 12 March 2003

This article is available from: <http://www.biomedcentral.com/1471-5945/3/2>

© 2003 Sawada et al; licensee BioMed Central Ltd. This is an Open Access article: verbatim copying and redistribution of this article are permitted in all media for any purpose, provided this notice is preserved along with the article's original URL.

Abstract

Background: Ultraviolet A I (340–400 nm, UVA I) phototherapy is highly effective in sclerotic lesions of systemic sclerosis (SSc). Histological evaluation of skin specimens obtained before and after UVA I phototherapy revealed loosening of collagen bundles and the appearance of small collagen fibers. We have previously shown that UVA I irradiation induced collagenase in vitro study by using SSc fibroblasts. The increased levels of mRNA and protein of decorin in SSc fibroblasts were reported. In this study, we focus on the lesional expression of small dermatan sulfate proteoglycan, decorin that has a role of binding to collagen and fibrillogenesis.

Case presentation: We employed immunohistochemical analysis of decorin before and after UVA I phototherapy. The skin specimens from three patients who were effectively treated with UVA I phototherapy were analysed. Monoclonal antibody 6B6 as the specific reactivity to decorin was used. The increased decorin was focally accumulated in the newly synthesized collagen fibers in the sclerotic lesion of SSc. After UVA I phototherapy, decorin was decreased in upper to middle dermis, although decorin was slightly increased in papillary dermis.

Conclusions: These results suggest that decreased and normalized levels of accumulated decorin may relate to the efficacy of sclerotic lesions in UVA I phototherapy.

Background

Decorin is a leucine-rich proteoglycan (PG) with a protein core of 36 kDa and a glycosaminoglycan (GAG) chain attached to the N-terminus [1]. Decorin contributes to fibril stability of several collagen types in vivo, including types I, II, V, VI and XIV by binding through leucine-rich repeat regions or GAG chain [2], and influences cell adhesion by interacting with extracellular adhesive molecules such as fibronectin [3] and thrombospondin [4]. In some cells, decorin activates the epidermal growth factor receptor, thereby triggering a signaling cascade that leads to phosphorylation of mitogen-activated protein kinases, to the

induction of p21, and to growth suppression [5]. Decorin also interacts with transforming growth factor (TGF)- β and modulates its activity and transfection of decorin gene prevent fibrosis in kidney [6], or it may increase TGF- β activity on osteoblasts [7].

SSc is a connective tissue disease characterized by fibrosis of the skin, subcutaneous tissue, and various internal organs. The most prominent pathological manifestation of the disease is an abnormal accumulation of extracellular matrix molecules, especially type I and III collagen [8,9]. Decorin binds to type I collagen and regulates

fibrillogenesis, and mRNA of decorin from fibroblast of patients with SSc were previously examined. Decorin mRNA with early stage SSc (less than 1 year duration of disease) was highly expressed than that of normal control [9].

SSc is an autoimmune disorder characterized by excessive deposition of collagen within the skin and other organs. SSc can severely affect the quality of life and may cause significant morbidity. Numerous treatments have been tried but with only limited success. UVA1 phototherapy has proven to be effective for atopic dermatitis [10], cutaneous T cell lymphoma [11], and urticaria pigmentosa [12] because it depletes skin-infiltrating T cells or mast cells. More recently, UVA1 has been shown to clear sclerosis plaques in patients with long-standing widespread morphea, resistant to previous treatments [13,14] and to be effective for scleroderma in patients with SSc [15]. UVA1 is also effective to other sclerotic disorders such as localized scleroderma [16] and lichen sclerosus even with low dose regimen [17]. We have previously shown that UVA1 phototherapy treated skin lesions were markedly softened after 9–29 exposures in all the SSc patients studied [15]. Clinical improvement was associated with an increase in joint passive range of motion values, skin temperature, and cutaneous elasticity. Histological evaluation of skin specimens obtained before and after UVA1 phototherapy revealed loosening of collagen bundles and the appearance of small collagen fibers. Moreover, we have shown that UVA1 irradiation induced collagenase *in vitro* study by using SSc fibroblasts [[18] in press]. In this study, we analysed the skin specimen of previous study in which UVA1 phototherapy was highly effective to examine a small dermatan sulfate proteoglycan, decorin that has a role of binding to collagen and fibrillogenesis.

Case Presentation

Patients

Two diffuse type (2 female) and one limited type (1 female) patients with SSc were treated with UVA1 phototherapy after informed consent had been obtained. The patients' profiles are summarized in detail in Table 1 (see additional file 1). Three patients enrolled in this study were identical to those of the previous report [15].

UVA1 Phototherapy

For UVA1 irradiation, a partial body UVA1 Sellamed 2000 System Dr Sellmaier (Sellas, Gevelsberg, Germany) irradiation device was used as previously described [15]. The emission was filtered with a UVA1 filter (Sellas) and an infrared absorbing filter UG1 (Schott, Mainz, Germany) and consisted exclusively of UV wavelength greater than 340 nm and smaller than 450 nm. The UVA1 irradiance was measured with a IL 1700 photometer (International Light, Newburyport, Mass) and found to be 50 mW/cm² at body

distance [19]. To rule out sensitivity to UVA1 irradiation, all patients were phototested before UVA1 phototherapy with increasing doses of UVA1 radiation (10–60 J/cm²) as previously described [15]. For UVA1 phototherapy, all patients were treated with the lesional forearm and hand to single doses of 60 J/cm² UVA1 daily (Monday-Friday). UVA1 phototherapy was given as monotherapy except for the oral medication which the patients had been given before a phototherapy session. Topical treatment was restricted to the use of emollients.

Immunohistochemical analysis of Decorin

6B6 is a monoclonal antibody prepared with a purified small dermatan sulfate PG from human ovarian fibroma capsule as an antigen [20]. Its epitope region located within a stretch of amino acid residues 50–65, termed the N-terminal cysteine cluster region, and is useful for immunohistochemistry [21].

Biopsy specimens taken from three patients before and at the end point of treatment and three normal skin taken from margin of benign tumor were fixed with 10% buffered formalin for 48 h, followed by embedding in paraffin. Tissue sections (3 μm) were dewaxed in xylene, and rehydrated through decreasing concentrations of ethanol. To block endogenous peroxidase activity, rehydrated sections were treated in a 0.3 % H₂O₂ in absolute ethanol for 5 min, and were processed for immunostaining with 6B6 (Seikagaku Kogyo, Tokyo, Japan, 500-fold dilution) and a Histofine Simple Stain Max PO (M) (Nichirei, Tokyo, Japan) according to a manufacturer's instruction. For regular histology tissue sections were stained with Elastica van Gieson stain.

Site-matched biopsy specimens were taken from the forearms of patients before and after UVA1 phototherapy. The histopathology revealed that there were enlarged collagen bundles in the dermis before therapy. After UVA1 irradiation, histological analysis showed a loosening of collagen bundles, the appearance of small collagen fibers in the dermis and a decrease in the thickness of the dermal collagen (Fig. 1). In normal skin, three specimens were stained similarly and decorin localized entire dermis co-distributing with collagen fiber, but epidermis, dermal region facing the basement membrane, and appendage was not stained (Fig. 2G). In SSc patients, decorin was stained entire dermis, especially focally accumulated collagen bundles in upper to middle dermis. Decorin shows remarkable decrease around enlarged collagen bundles in upper to middle dermis according to depth that UVA1 achieve after UVA1 phototherapy. However, decorin was slightly increased around increased small collagen fibers in papillary dermis (Fig. 2A,2B,2C,2D,2E,2F).

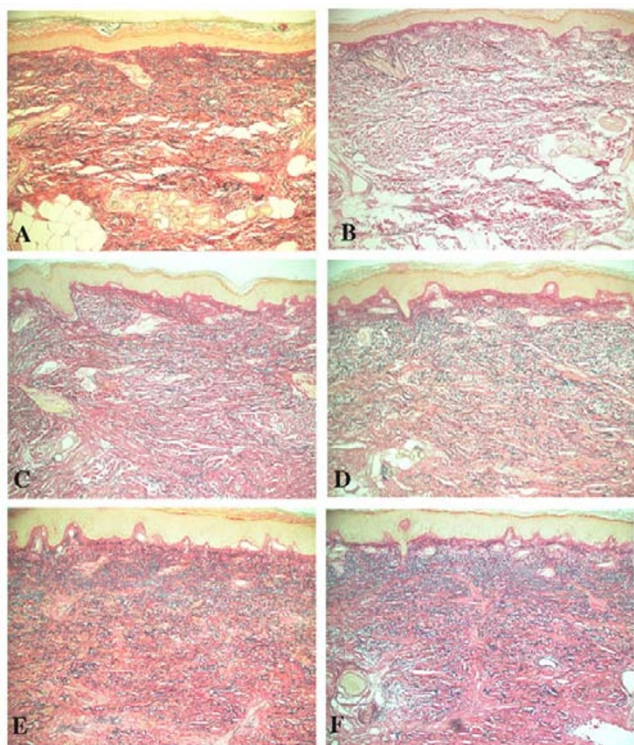


Figure 1
Histological evaluation of site-matched skin biopsy specimens before (A, C, E) and after (B, D, F) UVA1 phototherapy Biopsy specimens were taken from sclerotic skin lesions of the forearms of patients 1 (A, B), 2 (C, D), and 3 (E, F). Before UVA1 therapy, there are enlarged collagen bundles in the dermis. After UVA1 irradiation, histological analysis shows a loosening of collagen bundles, the appearance of small collagen fibers in the dermis and a decrease in the thickness of the dermal collagen. (Elastica van Gieson stain, original magnification $\times 200$)

Its mechanism assumed that degradation of collagen fibers by UVA1-induced matrix metalloproteinase may lead to decrease accumulated decorin in the upper to middle dermis and normalization of decorin may induce normal collagen assembly. This sequence may soften the skin of SSc.

Conclusions

In this study, aberrant localization of decorin was normalized after UVA1 phototherapy. The altered expression of decorin may correlate with the change of collagen fiber. These results suggest that decreased and normalized levels of accumulated decorin may relate to the efficacy of sclerotic lesions in UVA1 phototherapy.

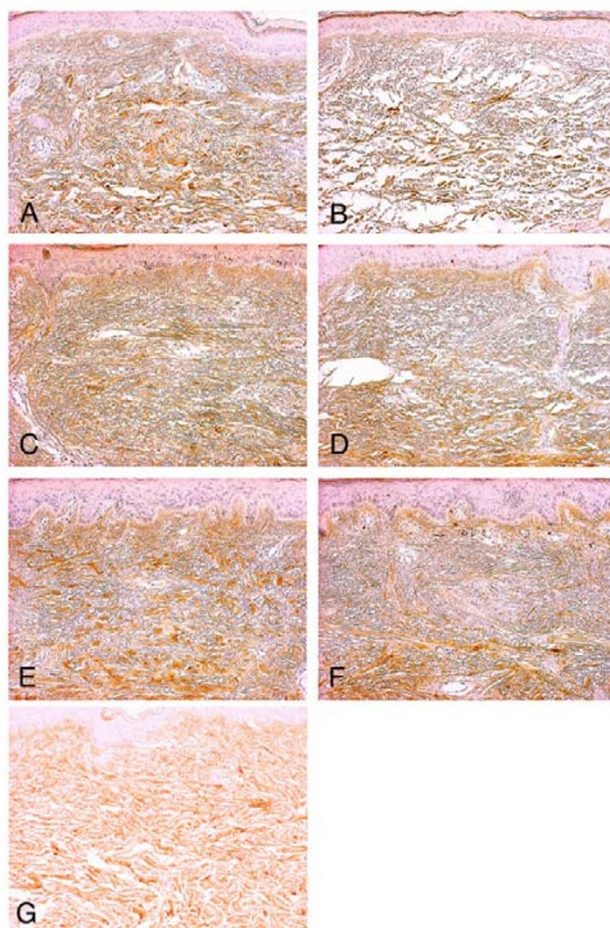


Figure 2
Immunohistochemical analysis of decorin of site-matched skin biopsy specimens before (A, C, E) and after (B, D, F) UVA1 phototherapy Biopsy specimens were taken from sclerotic skin lesions of the forearms of patients 1 (A, B), 2 (C, D), and 3 (E, F), and were stained with monoclonal antibody 6B6 that recognize core protein of small dermatan sulfate proteoglycan, decorin. Decorin is decreased in upper to middle dermis and enlarged collagen bundles are disappeared after UVA1 phototherapy. Decorin is slightly increased in papillary dermis, suggesting newly synthesized collagen. In normal skin (G), decorin is stained entire dermis, but epidermis, dermal region facing the basement membrane, and appendage are not stained.

Competing interests

None declared.

Authors' contributions

H.S. participated in the design of the study, carried out the immunohistochemistry and drafted the manuscript. A.M.

conceived of the study. Z.I. participated in the coordination.

All authors read and approved the final manuscript.

Additional material

Additional file 1

Table 1. Patients' profile

Click here for file

[<http://www.biomedcentral.com/content/supplementary/1471-5945-3-2-S1.xls>]

Acknowledgements

This work was in part supported by Grant-in-Aid for Scientific Research (C) from the Ministry of Education, Science and Culture of Japan (12670831, AM), a grant for the Basic Dermatological Research from Shiseido Co. Ltd., and a grant from Ojinkai (Nagoya City University Medical School), Nagoya, Japan. Written consent was obtained from the patient or their relative for publication of the patient's details.

References

- Krusius T and Ruoslahti E **Primary structure of an extracellular matrix proteoglycan core protein deduced from cloned cDNA.** *Proc Natl Acad Sci U S A* 1986, **83**:7683-7687
- Iozzo RV **The biology of the small leucine-rich proteoglycans. Functional network of interactive proteins.** *J Biol Chem* 1999, **274**:18843-18846
- Schmidt G, Robenek H, Harrach B, Glossl J, Nolte V, Hormann H, Richter H and Kresse H **Interaction of small dermatan sulfate proteoglycan from fibroblasts with fibronectin.** *J Cell Biol* 1987, **104**:1683-1691
- Winnemoller M, Schon P, Vischer P and Kresse H **Interactions between thrombospondin and the small proteoglycan decorin: interference with cell attachment.** *Eur J Cell Biol* 1992, **59**:47-55
- Moscattello DK, Santra M, Mann DM, McQuillan DJ, Wong AJ and Iozzo RV **Decorin suppresses tumor cell growth by activating the epidermal growth factor receptor.** *J Clin Invest* 1998, **101**:406-412
- Border WA, Noble NA, Yamamoto T, Harper JR, Yamaguchi Y, Pierschbacher MD and Ruoslahti E **Natural inhibitor of transforming growth factor-beta protects against scarring in experimental kidney disease.** *Nature* 1992, **360**:361-364
- Takeuchi Y, Kodama Y and Matsumoto T **Bone matrix decorin binds transforming growth factor-beta and enhances its bioactivity.** *J Biol Chem* 1994, **269**:32634-32638
- Kuroda K and Shinkai H **Decorin and glycosaminoglycan synthesis in skin fibroblasts from patients with systemic sclerosis.** *Arch Dermatol Res* 1997, **289**:481-485
- Kuroda K and Shinkai H **Gene expression of types I and III collagen, decorin, matrix metalloproteinases and tissue inhibitors of metalloproteinases in skin fibroblasts from patients with systemic sclerosis.** *Arch Dermatol Res* 1997, **289**:567-572
- Krutmann J, Czech W, Diepgen T, Niedner R, Kapp A and Schopf E **High-dose UVA1 therapy in the treatment of patients with atopic dermatitis.** *J Am Acad Dermatol* 1992, **26**:225-230
- Plettenberg H, Stege H, Megahed M, Ruzicka T, Hosokawa Y, Tsuji T, Morita A and Krutmann J **Ultraviolet A1 (340-400 nm) phototherapy for cutaneous T-cell lymphoma.** *J Am Acad Dermatol* 1999, **41**:47-50
- Stege H, Schopf E, Ruzicka T and Krutmann J **High-dose UVA1 for urticaria pigmentosa.** *Lancet* 1996, **347**:64
- Stege H, Berneburg M, Humke S, Klammer M, Grewe M, Grether-Beck S, Boedeker R, Diepgen T, Dierks K and Goerz G **High-dose UVA1 radiation therapy for localized scleroderma.** *J Am Acad Dermatol* 1997, **36**:938-944
- Rook AH, Freundlich B, Jegasothy BV, Perez MI, Barr WG, Jimenez SA, Rietschel RL, Wintroub B, Kahaleh MB and Varga J **Treatment of systemic sclerosis with extracorporeal photochemotherapy. Results of a multicenter trial.** *Arch Dermatol* 1992, **128**:337-346
- Morita A, Kobayashi K, Isomura I, Tsuji T and Krutmann J **Ultraviolet A1 (340-400 nm) phototherapy for scleroderma in systemic sclerosis.** *J Am Acad Dermatol* 2000, **43**:670-674
- Kerscher M, Volkenandt M, Gruss C, Reuther T, von Kobyletzki G, Freitag M, Dirschka T and Altmeyer P **Low-dose UVA phototherapy for treatment of localized scleroderma.** *J Am Acad Dermatol* 1998, **38**:21-26
- Kreuter A, Gambichler T, Avermaete A, Happe M, Bacharach-Buhles M, Hoffmann K, Jansen T, Altmeyer P and von Kobyletzki G **Low-dose ultraviolet A1 phototherapy for extragenital lichen sclerosus: results of a preliminary study.** *J Am Acad Dermatol* 2002, **46**:251-255
- Yin L, Yamauchi R, Tsuji T, Krutmann J and Morita A **The Expression of Matrix Metalloproteinase-1 mRNA Induced by Ultraviolet A1 (340-400 nm) Is Phototherapy Relevant to the Glutathione (GSH) Content in Skin Fibroblasts of Systemic Sclerosis.** *J Dermatol* 2003,
- Morita A and Krutmann J **Ultraviolet A radiation-induced apoptosis.** *Methods Enzymol* 2000, **319**:302-309
- Sobue M, Nakashima N, Fukatsu T, Nagasaka T, Katoh T, Ogura T and Takeuchi J **Production and characterization of monoclonal antibody to dermatan sulfate proteoglycan.** *J Histochem Cytochem* 1988, **36**:479-485
- Sawada H, Shinomura T, Kimata K, Takeuchi J, Tsuji T and Watanabe H **Characterization of an anti-decorin monoclonal antibody, and its utility.** *J Biochem (Tokyo)* 2002, **132**:997-1000

Pre-publication history

The pre-publication history for this paper can be accessed here:

<http://www.biomedcentral.com/1471-5945/3/2/prepub>

Publish with **BioMed Central** and every scientist can read your work free of charge

"BioMed Central will be the most significant development for disseminating the results of biomedical research in our lifetime."

Sir Paul Nurse, Cancer Research UK

Your research papers will be:

- available free of charge to the entire biomedical community
- peer reviewed and published immediately upon acceptance
- cited in PubMed and archived on PubMed Central
- yours — you keep the copyright

Submit your manuscript here:
http://www.biomedcentral.com/info/publishing_adv.asp

