

Research article

Open Access

Overexpression of inhibitor of DNA-binding (ID)-I protein related to angiogenesis in tumor advancement of ovarian cancers

Min Khine Maw, Jiro Fujimoto* and Teruhiko Tamaya

Address: Department of Obstetrics and Gynecology, Graduate School of Medicine, Gifu University School of Medicine, 1-1 Yanagido, Gifu City 501-1194, Japan

Email: Min Khine Maw - minkhinemaw@yahoo.com; Jiro Fujimoto* - jf@gifu-u.ac.jp; Teruhiko Tamaya - san@gifu-u.ac.jp

* Corresponding author

Published: 10 December 2009

Received: 24 April 2009

BMC Cancer 2009, 9:430 doi:10.1186/1471-2407-9-430

Accepted: 10 December 2009

This article is available from: <http://www.biomedcentral.com/1471-2407/9/430>

© 2009 Maw et al; licensee BioMed Central Ltd.

This is an Open Access article distributed under the terms of the Creative Commons Attribution License (<http://creativecommons.org/licenses/by/2.0>), which permits unrestricted use, distribution, and reproduction in any medium, provided the original work is properly cited.

Abstract

Background: The inhibitor of DNA-binding (ID) has been involved in cell cycle regulation, apoptosis and angiogenesis. This prompted us to study ID functions in tumor advancement of ovarian cancers.

Methods: Sixty patients underwent surgery for ovarian cancers. In ovarian cancers, the levels of ID-1, ID-2 and ID-3 mRNAs were determined by real-time reverse transcription-polymerase chain reaction. The histoscore with the localization of ID-1 was determined by immunohistochemistry. Patient prognosis was analyzed with a 36-month survival rate. Microvessel counts were determined by immunohistochemistry for CD34 and factor VIII-related antigen.

Results: ID-1 histoscores and mRNA levels both significantly ($p < 0.001$) increased in ovarian cancers according to clinical stage, regardless of histopathological type. Furthermore, 30 patients with high ID-1 expression had a lower survival rate (53%) compared to patients with low ID-1 expression (80%). ID-1 histoscores and mRNA levels significantly ($p < 0.0001$) correlated with microvessel counts in ovarian cancers.

Conclusion: ID-1 increased in ovarian cancer cells during tumor progression. Moreover, ID-1 expression levels correlated with microvessel counts. Therefore, ID-1 might work on tumor advancement via angiogenesis and is considered to be a candidate for a prognostic indicator in ovarian cancers.

Background

Inhibitor of DNA binding (ID) proteins are members of a family of basic helix-loop-helix (bHLH) transcription factors lacking the DNA-binding domain [1]. ID acts as dominant-negative regulators of bHLH proteins by forming transcriptionally inactive Id-bHLH protein complexes [2,3]. ID has been implicated in different steps in tumorigenesis, differentiation and metastasis [4-9].

ID-1 induces cell proliferation, increases DNA synthesis, and immortalizes mammalian cells in corporation with some oncogenes [10,11]. Overexpression of ID-1 inhibits expression of p16 [12,13], p21 [14] and p27 [15], which leads to increased activity of cyclin dependent kinase 2 (CDK2) and increased phosphorylation of retinoblastoma protein. Therefore, the increased liberation of ID-2 from retinoblastoma protein and more free-ID-2 is avail-

able for the inhibition of E proteins to facilitate proliferation [16]. ID-1 interacts with various cell cycle regulators [12,17] and causes cells to pass a mitogen-restricted point in late G1 phase [18]. Therefore, ID-1 is responsible for some changes in gene expression that lead to growth and invasion of tumor cells [19]. Moreover, ID-1 plays various roles such as markers for progression, metastasis and prognosis in prostate [20,21], breast [22,23], gastric [24,25], esophageal [26] and uterine cervical cancers [27].

In a previous study, expression of ID-1 was shown as an independent prognostic factor in ovarian cancer with long-time follow-up. Overexpression of ID-1 is associated with more aggressive behavior of tumor cells in ovarian cancer [28]. However, no study has investigated the molecular function of ID-induced tumor progression in ovarian cancer. This prompted us to study the expression manner of ID proteins in ovarian cancers against clinical backgrounds with angiogenic potential in the tumors.

Methods

Patients and tissues

Prior informed consent for the following studies was obtained from all patients and approval was given by the Research Committee for Human Subjects, Gifu University School of Medicine. Sixty patients ranging from 34 to 83 years of age with ovarian cancers [stage I, 18 cases; stage II, 13 cases; and stage III, 15 cases; stage IV, 14 cases; 23 cases of serous papillary cystadenocarcinoma (SPCY), 8 cases of serous cystadenocarcinoma (SCY), 10 cases of mucinous cystadenocarcinoma (MCY), 8 cases of clear cell adenocarcinoma (C) and 11 cases of endometrioid adenocarcinoma (E)] underwent surgery at the Department of Obstetrics and Gynecology, Gifu University School of Medicine, between December 1997 and January 2004. Patient prognosis was analyzed in relation to a 36-month survival rate. None of the patients had received any pre-operative therapy before the ovarian cancer tissue was taken in surgery. A part of each tissue of ovarian cancers was snap-frozen in liquid nitrogen and stored at -80°C to determine ID-1, ID-2 and ID-3 mRNA levels and those for immunohistochemistry were fixed with 10% formalin and embedded in paraffin wax. The clinical stage of ovarian cancers was determined by International Federation of Obstetrics and Gynecology (FIGO) classification [29].

Immunohistochemistry

Sections ($4\ \mu\text{m}$) of formalin-fixed paraffin-embedded tissue samples from ovarian cancers were cut with a microtome and dried overnight at 37°C on a silanized-slide (Dako, Carpinteria, CA, USA). The protocol of universal Dako-Labelled Streptavidin-Biotin kit (Dako, Carpinteria, CA, USA) was followed for each sample. Samples were deparaffinized in xylene at room temperature for 30 min, rehydrated with graded ethanol and washed in phos-

phate-buffered saline (PBS). The samples were then placed in 10 mM citrate buffer (pH 6.0) and boiled in a microwave for 10 min for epitope retrieval. Endogenous peroxidase activity was quenched by incubating tissue sections in 3% H_2O_2 for 10 min. The primary antibodies, rabbit antihuman ID-1 (SC-734, Santa Cruz Biotechnology Inc., Santa Cruz, CA, USA), mouse CD34 (Dako, Glostrup, Denmark) and rabbit anti-factor VIII-related antigen (Zymed, San Francisco, CA, USA) were used overnight at 4°C at dilutions of 1:50, 1:40 and 1:2, respectively. The slides were washed and biotinylated secondary antibody (Dako, Carpinteria, CA, USA) was applied for 30 min after rinsing in PBS, after which streptavidin-conjugated horseradish peroxidase (Dako, Carpinteria, CA, USA) was added for 30 min. Slides were then washed and treated with the chromogen 3,3'-diaminobenzidine (Dako, Carpinteria, CA, USA) for 5 min, then rinsed in PBS, and counterstained with Mayer's haematoxylin, dehydrated in graded ethanols, cleared in xylene and cover-slipped with a mounting medium, Entellan New (Merck, Darmstadt, Germany). For confirmation of the specificity for ID-1 antigen, we also used another ID-1 (SC-488) rabbit polyclonal antibody (Santa Cruz Biotechnology Inc., Santa Cruz, CA, USA) and we have observed the exact identified intensity and localization of staining for ID-1 expression in tumor cells as ID-1 (SC-734) antibody. For the negative controls, the primary antibodies of ID-1, CD34 and factor VIII-related antigen were omitted and the corresponding preimmune animal serums (rabbit, mouse and rabbit, respectively) (Dako, Carpinteria, CA, USA) were used instead.

Assessment of histochemical score (histoscore)

All sections of immunohistochemical staining for ID-1 were evaluated in a semiquantitative fashion according to the method described by McCarty et al. [30], which considers both the intensity and the percentage of cells stained in each of five intensity categories. Intensities were classified as 0 (no staining), 1 (weak staining), 2 (distinct staining), 3 (strong staining) and 4 (very strong staining). For each stained section, a value-designated histoscore was obtained by application of the following algorithm: $\text{histoscore} = \sum(i+1) \times P_i$, where i and P_i represent intensity and percentage of cells that stain at each intensity, respectively, and corresponding histoscores were calculated separately. Results were assigned to four groups according to their overall scores: weak, <160 ; distinct, $161 <$, >220 ; strong, $221 <$, >280 ; very strong, $280 <$.

Assessment of microvessel density (MVD)

The MVD was assessed with microvessel counts (MVCs) in sequential tissue sections stained with mouse CD34 and rabbit factor VIII-related antigen antibodies. Blood vessels with a clearly defined lumen or a well defined linear vessel shape, but not single endothelial cells, were taken into

account for microvessel counting [31]. Fives areas of highest vascular density were chosen and microvessel counting was performed at $\times 200$ magnification by two investigators. The MVCs were determined as the mean of the vessel counts obtained from these fields [32].

Preparation of standard template for real-time reverse transcription-polymerase chain reaction (RT-PCR)

Internal standard template for real-time PCR was produced by PCR amplification using the primers of ID-1 gene, 418-782 in the cDNA (ID-1-TS: 5'-TTGAGCTGAAGCTCGGAA-3' and ID-1-TAS: 5'-TCTCTGGTACTAGTAGGT-3'); ID-2 gene, 907-1253 in the cDNA (ID-2-TS: 5'-CTAAGCAGACTTTGCCTT-3' and ID-2-TAS: 5'-CTGAAATAAAGCAGGCAATC-3'); ID-3 gene, 686-1009 in the cDNA (ID-3-TS: 5'-GAAGTTGTCATCTCCAACGA-3' and ID-3-TAS: 5'-CACGCTCTGAAAAGACCT-3'). The DNA template was purified using a GeneClean II kit (Qbiogene, Irvine, CA, USA). The copy numbers of the standard template were determined to quantitate ID-1, ID-2 and ID-3 mRNA level in samples for real-time RT-PCR.

Real-time RT-PCR to amplify ID-1, ID-2 and ID-3 mRNAs

Total RNA was extracted with the acid guanidinium thiocyanate-phenol-chloroform method [33]. The total RNA (3 μ g) was reverse transcribed using Moloney murine leukemia virus reverse transcriptase (MMLV-RT, 200 U/ μ l, Invitrogen, Carlsbad, CA, USA) and the following reagents: 250 mM Tris-HCl, pH 8.3, 375 mM KCl, 15 mM MgCl₂, 0.1 M dithiothreitol, 10 mM deoxynucleotide [deoxyadenosine, deoxythymidine, deoxyguanosine and deoxycytidine] tri-phosphates (dNTPs) mixture and random hexamers (Invitrogen) at 37°C for 1 h. The reaction mixture was heated for 5 min at 94°C to inactivate MMLV-RTase.

Real-time PCR reaction was performed with a Takara Premix Ex Taq (Perfect Real Time) R-PCR kit (Takara, Otsu, Japan), using a smart cycler system (Cepheid, Sunnyvale, CA, USA). The reaction solution (25 μ l) contained Takara Premix Ex Taq (2 \times), SYBR Green I (1:1000 dilution; CambrexBio Science, Rockland Inc., Rockland, ME, USA) and 20 μ M of the primers of ID-1 gene, 545-675 in the cDNA (ID-1-S: 5'-ACGATCGCATCTTGTGTC-3' and ID-1-AS: 5'-CTTGTCTCCCTCAGATCC-3'); ID-2 gene, 907-1026 in the cDNA (ID-2-S: 5'-CTAAGCAGACTTTGCCTT-3' and ID-2-AS: 5'-CATTCAGTAGGCTTGTGTC-3'); ID-3 gene, 709-873 in the cDNA (ID-3-S: 5'-AAGGAGCTTTGCCACTGA-3' and ID-3-AS: 5'-CCAGGAAGGATTTGGTGAA-3') with the transcribed total RNA from the tissue and a serially diluted standard template. The real-time PCR reactions were initially denatured by heating at 95°C for 30 s, followed by 40 cycles consisting of denaturation at 94°C for 10 s, annealing at 55°C for 5 s

and extension at 72°C for 20 s. A strong linear relationship between the threshold cycle and the log concentration of the starting DNA copy number was always shown (correlation coefficient > 0.99). Quantitative analysis was performed to determine the copy number of each sample.

Statistical analysis

ID-1, ID-2 and ID-3 mRNA levels were determined from three parts taken from each tumor, and each sample was analyzed in triplicate. Statistical analysis was performed using MedCalc Software version 9.2.0.1. ID-1 histoscores and mRNA levels were compared using the Mann-Whitney test and the Kruskal-Wallis test as appropriate. The 36-month survival rate was calculated according to the Kaplan-Meier method. The log-rank test and the Cox proportional hazards model were used for univariate and multivariate analyses of overall survival, respectively. The correlations between ID-1 histoscores and mRNA levels with MVCs were performed with Spearman's coefficient of correlation just for descriptive analysis. Differences were considered significant when *P* was less than 0.05.

Results

ID-1 mRNA levels significantly increased with increasing clinical stages ($p < 0.001$) of ovarian cancers, regardless of histopathological type (Figure 1). However, there was no significant difference in ID-2 or ID-3 mRNA levels according to clinical stage or histopathological type in ovarian cancers, as shown in Figure 1. These results prompted us to concentrate our investigation on ID-1 in ovarian cancers.

Although ID-1 expression in stroma cells was negative, ID-1 staining was diffusely located in the cancer cells (Figure 2, a representative case of clear cell carcinoma of ovary). Because ID-1 is not a transcription factor *per se*, it lacks the nuclear localization signal found on many basic HLH proteins but gives a cytoplasmic signal instead [34,35]. ID-1 diffuse cytoplasmic staining was seen from moderate to strong intensity in most cases whereas nuclear staining was observed only occasionally (Figure 2).

ID-1 histoscore in cancer cells significantly ($p < 0.001$) correlated with the corresponding mRNA levels in each tissue, as shown in Figure 3. Although there was no significant difference in ID-1 histoscores in cancer cells according to histopathological type, ID-1 histoscores significantly ($p < 0.001$) increased with increased clinical stages of ovarian cancers (Figure 4), as did ID-1 mRNA.

Furthermore, the 60 patients who underwent surgery were divided into two equal groups based on ID-1 histoscores and mRNA levels, with the midpoint being a histoscore of 160 and mRNA of 6.2×10^6 copies/ μ g total RNA, respec-

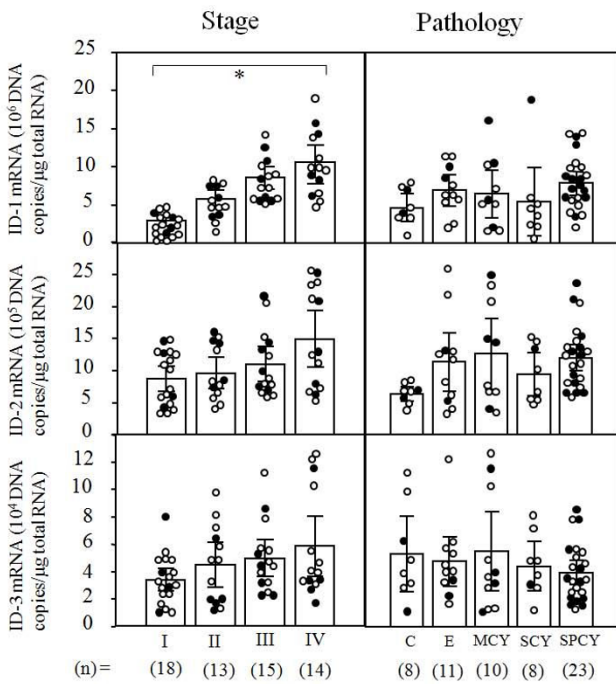


Figure 1
ID-1, ID-2 and ID-3 mRNA levels in ovarian cancers classified according to clinical stage and histopathological type. Clinical staging of ovarian cancers was done according to FIGO. Each level is the mean ± SD of nine determinations. C, clear cell carcinoma; E, endometrioid adenocarcinoma; MCY, mucinous cystadenocarcinoma; SCY, serous cystadenocarcinoma, SPCY, serous papillary cystadenocarcinoma. Alive and deceased cases are numbered in open circles and closed circles, respectively. * p < 0.001.

tively. The two groups, determined independently by the ID-1 histoscores and mRNA levels, consisted of exactly the same patients. The prognosis of the 30 patients with high ID-1 (> 160 histoscore and > 6.2 × 10⁶ copies/μg total RNA) in ovarian cancers was poor (53%), whereas the 36-

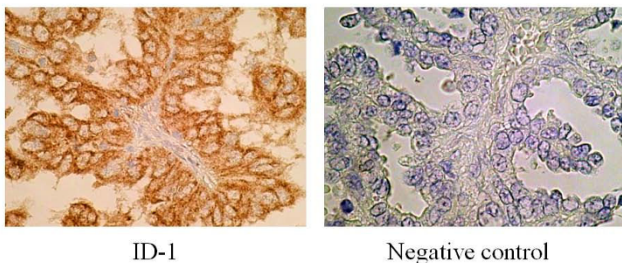


Figure 2
Immunohistochemical staining for ID-1 with negative control in ovarian cancers. A representing case of clear cell carcinoma of the ovary. Rabbit anti-human ID-1 (SC-734, Santa Cruz Biotechnology Inc., Santa Cruz, CA, USA) was used at a dilution of 1:50 as the primary antibody. (original magnification ×400).

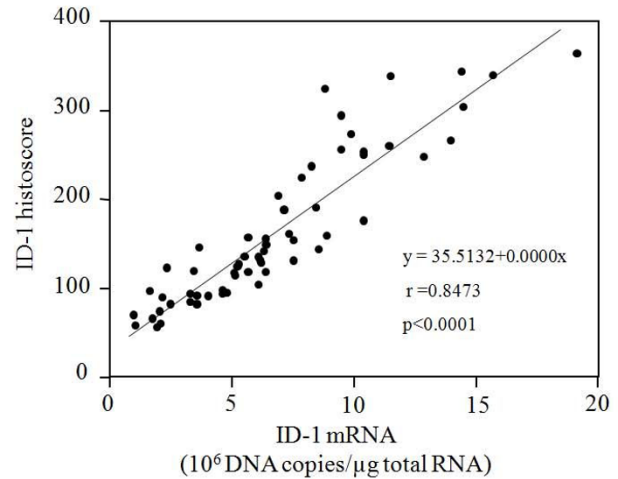


Figure 3
Correlation between ID-1 histoscores in cancer cells and mRNA (10⁶ DNA copies/μg total RNA) levels in ovarian cancers. ID-1 histoscores and mRNA levels were determined by immunohistochemistry and real-time RT-PCR, respectively. Each level is the mean ± SD of nine determinations.

month survival rate of the other 30 patients with low ID-1 (< 160 histoscore and < 6.2 × 10⁶ copies/μg total RNA) was higher (80%), as shown in Figure 5.

ID-1 expression was negative in endothelial cells, although CD34 and Factor VIII-related antigen expressions were strong. ID-1 histoscores significantly correlated with MVC-CD34 (MVCs determined by immunohistochemistry for CD34; r = 0.6296, p < 0.0001) and MVC-FVIII (MVCs determined by immunohistochemistry for

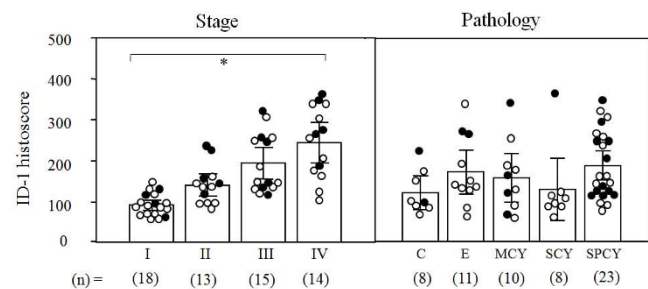


Figure 4
ID-1 histoscores in ovarian cancers classified according to clinical stage and histopathological type. Clinical staging of ovarian cancers was done according to FIGO. Each level is the mean ± SD of nine determinations. C, clear cell carcinoma; E, endometrioid adenocarcinoma; MCY, mucinous cystadenocarcinoma; SCY, serous cystadenocarcinoma, SPCY, serous papillary cystadenocarcinoma. Alive and deceased cases are numbered in open circles and closed circles, respectively. * p < 0.001.

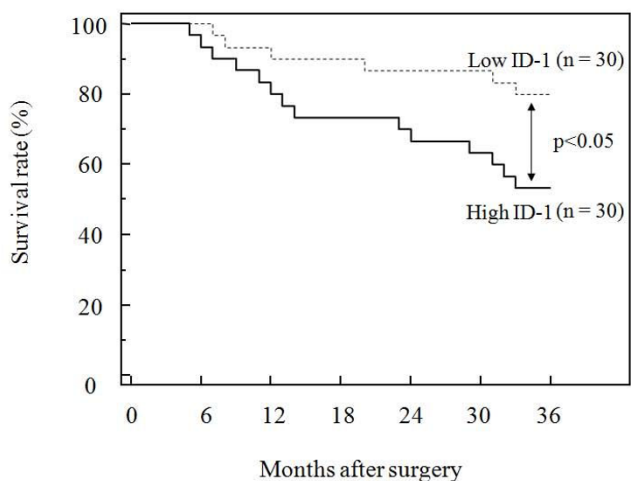


Figure 5
Survival rate after surgery for ovarian cancers. Patient prognosis was analyzed with a 36-month survival rate. High ID-1, cases with high histoscores and mRNA levels (> 160 histoscore and $> 6.2 \times 10^6$ copies/ μ g total RNA, respectively). Low ID-1, cases with low histoscores and mRNA levels (< 160 histoscore and $< 6.2 \times 10^6$ copies/ μ g total RNA, respectively).

factor VIII-related antigen; $r = 0.5698$, $p < 0.0001$), and ID-1 mRNA levels also correlated with MVC-CD34 ($r = 0.7686$, $p < 0.0001$) and MVC-F-VIII ($r = 0.5792$, $p < 0.0001$), as shown in Figure 6.

Discussion and conclusion

In the present study, ID-1 expression increased with tumor advancement of ovarian cancers and patients with high ID-1 expression had a lower survival rate compared

to patients with low ID-1 expression. Previously, no correlation between expression of ID proteins and angiogenesis, assessed by MVD was observed in ovarian cancers [28].

Ectopic expression of ID-1 in a prostate cancer cell line that express low levels of both ID-1 and VEGF protein resulted increase in VEGF secretion by the cells, which is associated with increased VEGF gene transcription, after ID-1 gene transfection [36]. ID-1 promotes tumor angiogenesis through VEGF gene transcription and protein expression. In addition, VEGF is a downstream target of the ID-1 protein [36]. ID-1 promotes tumor angiogenesis through induction of the VEGF gene transcription and protein expression [37-39], leading to proliferation and endothelial tube formation of the vascular endothelial cells. ID-1 induces activity of HIF-1 α in human endothelial and breast cancer cells [40,41]. Furthermore, ID-1 enhanced nuclear translocation and the transcriptional activity of HIF-1 α [42]. In a previous study, increased HIF-1 α levels were observed with tumor advancement and poor patient prognosis in uterine cervical cancers [43].

When tumor xenografts were implanted into ID-1/ID-3 mice, decreased tumor growth as well as loss of metastasis were observed, which were associated with impaired neo-vascularization of tumor [19]. In ID-1/- mice, up-regulation of a potent angiogenic inhibitor thrombospondin-1 in null embryonic fibroblasts was observed [44]. This showed ID-1 alone was sufficient to impair tumor angiogenesis. In the present study, ID-1 expression correlated with microvessel counts indicating that ID-1 overexpression contributed to tumor angiogenesis in ovarian cancer. Therefore, ID-1 is a candidate for angiogenic mediator as the clinical relevance of angiogenesis assessed by MVC.

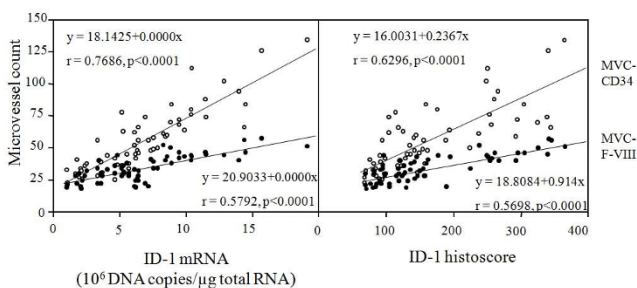


Figure 6
Correlation of ID-1 histoscores in cancer cells and mRNA levels in ovarian cancers with microvessel counts (MVCs). White circles, (MVC-CD34) by immunohistochemical staining for CD34; black circles, (MVC-FV-III) by immunohistochemical staining for factor VIII-related antigen. Each level is the mean \pm SD of nine determinations.

In conclusion, this study demonstrates the functional role of ID-1 overexpression in tumor advancement via angiogenesis and ID-1 can be a useful prognostic indicator in ovarian cancers. In addition, ID-1 protein might be an important new target molecule for anti-angiogenic drug design in cancer treatment.

Competing interests

The authors declare that they have no competing interests.

Authors' contributions

MKM has made substantial contributions to conception and design, acquisition of data, analysis and interpretation of data. JF conceived of the study, participated in its design and in drafting the manuscript and revising it critically for important intellectual content. TT has given final approval of the version to be published. All authors read and approved the final manuscript.

References

- Norton JD, Deed RW, Craggs G, Sablitzky F: **Id helix-loop-helix proteins in cell growth and differentiation.** *Trends Cell Biol* 1998, **8(2)**:58-65.
- Riechmann V, Sablitzky F: **Mutually exclusive expression of two dominant-negative helix-loop-helix (dnHLH) genes, Id4 and Id3, in the developing brain of the mouse suggests distinct regulatory roles of these dnHLH proteins during cellular proliferation and differentiation of the nervous system.** *Cell Growth Differ* 1995, **6(7)**:837-843.
- Riechmann V, van Cruchten I, Sablitzky F: **The expression pattern of Id4, a novel dominant negative helix-loop-helix protein, is distinct from Id1, Id2 and Id3.** *Nucleic Acids Res* 1994, **22(5)**:749-755.
- Benezra R, Rafii S, Lyden D: **The Id proteins and angiogenesis.** *Oncogene* 2001, **20(58)**:8334-8341.
- Fong S, Debs RJ, Desprez PY: **Id genes and proteins as promising targets in cancer therapy.** *Trends Mol Med* 2004, **10(8)**:387-392.
- Hasskarl J, Munger K: **Id proteins--tumor markers or oncogenes?** *Cancer Biol Ther* 2002, **1(2)**:91-96.
- Sikder HA, Devlin MK, Dunlap S, Ryu B, Alani RM: **Id proteins in cell growth and tumorigenesis.** *Cancer Cell* 2003, **3(6)**:525-530.
- Wong YC, Wang X, Ling MT: **Id-1 expression and cell survival.** *Apoptosis* 2004, **9(3)**:279-289.
- Zebedee Z, Hara E: **Id proteins in cell cycle control and cellular senescence.** *Oncogene* 2001, **20(58)**:8317-8325.
- Alani RM, Hasskarl J, Grace M, Hernandez MC, Israel MA, Munger K: **Immortalization of primary human keratinocytes by the helix-loop-helix protein, Id-1.** *Proc Natl Acad Sci USA* 1999, **96(17)**:9637-9641.
- Norton JD, Atherton GT: **Coupling of cell growth control and apoptosis functions of Id proteins.** *Mol Cell Biol* 1998, **18(4)**:2371-2381.
- Ohtani N, Zebedee Z, Huot TJ, Stinson JA, Sugimoto M, Ohashi Y, Sharrocks AD, Peters G, Hara E: **Opposing effects of Ets and Id proteins on p16INK4a expression during cellular senescence.** *Nature* 2001, **409(6823)**:1067-1070.
- Ouyang XS, Wang X, Ling MT, Wong HL, Tsao SW, Wong YC: **Id-1 stimulates serum independent prostate cancer cell proliferation through inactivation of p16(INK4a)/pRB pathway.** *Carcinogenesis* 2002, **23(5)**:721-725.
- Prabhu S, Ignatova A, Park ST, Sun XH: **Regulation of the expression of cyclin-dependent kinase inhibitor p21 by E2A and Id proteins.** *Mol Cell Biol* 1997, **17(10)**:5888-5896.
- Everly DN Jr, Mainou BA, Raab-Traub N: **Induction of Id1 and Id3 by latent membrane protein 1 of Epstein-Barr virus and regulation of p27Kip and cyclin-dependent kinase 2 in rodent fibroblast transformation.** *J Virol* 2004, **78(24)**:13470-13478.
- Perk J, Iavarone A, Benezra R: **Id family of helix-loop-helix proteins in cancer.** *Nat Rev Cancer* 2005, **5(8)**:603-614.
- Alani RM, Young AZ, Shifflett CB: **Id1 regulation of cellular senescence through transcriptional repression of p16/Ink4a.** *Proc Natl Acad Sci USA* 2001, **98(14)**:7812-7816.
- Le Jossic C, Ilyin GP, Loyer P, Glaize D, Cariou S, Guguen-Guillouzo C: **Expression of helix-loop-helix factor Id-1 is dependent on the hepatocyte proliferation and differentiation status in rat liver and in primary culture.** *Cancer Res* 1994, **54(23)**:6065-6068.
- Lyden D, Young AZ, Zagzag D, Yan W, Gerald W, O'Reilly R, Bader BL, Hynes RO, Zhuang Y, Manova K, et al.: **Id1 and Id3 are required for neurogenesis, angiogenesis and vascularization of tumour xenografts.** *Nature* 1999, **401(6754)**:670-677.
- Ouyang XS, Wang X, Lee DT, Tsao SW, Wong YC: **Over expression of ID-1 in prostate cancer.** *J Urol* 2002, **167(6)**:2598-2602.
- Yuen HF, Chua CW, Chan YP, Wong YC, Wang X, Chan KW: **Id proteins expression in prostate cancer: high-level expression of Id-4 in primary prostate cancer is associated with development of metastases.** *Mod Pathol* 2006, **19(7)**:931-941.
- Fong S, Itahana Y, Sumida T, Singh J, Coppe JP, Liu Y, Richards PC, Bennington JL, Lee NM, Debs RJ, et al.: **Id-1 as a molecular target in therapy for breast cancer cell invasion and metastasis.** *Proc Natl Acad Sci USA* 2003, **100(23)**:13543-13548.
- Jang KS, Han HX, Paik SS, Brown PH, Kong G: **Id-1 overexpression in invasive ductal carcinoma cells is significantly associated with intratumoral microvessel density in ER-negative/node-positive breast cancer.** *Cancer Lett* 2006, **244(2)**:203-210.
- Jang TJ, Jung KH, Choi EA: **Id-1 gene downregulation by sulindac sulfide and its upregulation during tumor development in gastric cancer.** *Int J Cancer* 2006, **118(6)**:1356-1363.
- Tsuchiya T, Okaji Y, Tsuno NH, Sakurai D, Tsuchiya N, Kawai K, Yazawa K, Asakage M, Yamada J, Yoneyama S, et al.: **Targeting Id1 and Id3 inhibits peritoneal metastasis of gastric cancer.** *Cancer Sci* 2005, **96(11)**:784-790.
- Yuen HF, Chan YP, Chan KK, Chu YY, Wong ML, Law SY, Srivastava G, Wong YC, Wang X, Chan KW: **Id-1 and Id-2 are markers for metastasis and prognosis in oesophageal squamous cell carcinoma.** *Br J Cancer* 2007, **97(10)**:1409-1415.
- Maw MK, Fujimoto J, Tamaya T: **Expression of the inhibitor of DNA-binding (ID)-1 protein as an angiogenic mediator in tumour advancement of uterine cervical cancers.** *Br J Cancer* 2008, **99(10)**:1557-1563.
- Schindl M, Schoppmann SF, Strobel T, Heinzl H, Leisser C, Horvat R, Birner P: **Level of Id-1 protein expression correlates with poor differentiation, enhanced malignant potential, and more aggressive clinical behavior of epithelial ovarian tumors.** *Clin Cancer Res* 2003, **9(2)**:779-785.
- International Federation of Obstetrics and Gynecology (FIGO) News. In *Int J Gynecol Obstet Volume 28*. FIGO News; 1989:189-193.
- McCarty KS Jr, Miller LS, Cox EB, Konrath J, McCarty KS Sr: **Estrogen receptor analyses. Correlation of biochemical and immunohistochemical methods using monoclonal antireceptor antibodies.** *Arch Pathol Lab Med* 1985, **109(8)**:716-721.
- Giatromanolaki A, Sivridis E, Brekken R, Thorpe PE, Anastasiadis P, Gatter KC, Harris AL, Koukourakis MI: **The angiogenic "vascular endothelial growth factor/flk-1(KDR) receptor" pathway in patients with endometrial carcinoma: prognostic and therapeutic implications.** *Cancer* 2001, **92(10)**:2569-2577.
- Maeda K, Chung YS, Ogawa Y, Takatsuka S, Kang SM, Ogawa M, Sawada T, Onoda N, Kato Y, Sowa M: **Thymidine phosphorylase/platelet-derived endothelial cell growth factor expression associated with hepatic metastasis in gastric carcinoma.** *Br J Cancer* 1996, **73(8)**:884-888.
- Chomczynski P, Sacchi N: **Single-step method of RNA isolation by acid guanidinium thiocyanate-phenol-chloroform extraction.** *Anal Biochem* 1987, **162(1)**:156-159.
- Lin CQ, Singh J, Murata K, Itahana Y, Parrinello S, Liang SH, Gillett CE, Campisi J, Desprez PY: **A role for Id-1 in the aggressive phenotype and steroid hormone response of human breast cancer cells.** *Cancer Res* 2000, **60(5)**:1332-1340.
- Maruyama H, Kleeff J, Wildi S, Friess H, Buchler MW, Israel MA, Korc M: **Id-1 and Id-2 are overexpressed in pancreatic cancer and in dysplastic lesions in chronic pancreatitis.** *Am J Pathol* 1999, **155(3)**:815-822.
- Ling MT, Lau TC, Zhou C, Chua CW, Kwok WK, Wang Q, Wang X, Wong YC: **Overexpression of Id-1 in prostate cancer cells promotes angiogenesis through the activation of vascular endothelial growth factor (VEGF).** *Carcinogenesis* 2005, **26(10)**:1668-1676.
- Cheung HW, Ling MT, Tsao SW, Wong YC, Wang X: **Id-1-induced Raf/MEK pathway activation is essential for its protective role against taxol-induced apoptosis in nasopharyngeal carcinoma cells.** *Carcinogenesis* 2004, **25(6)**:881-887.
- Lin JC, Chang SY, Hsieh DS, Lee CF, Yu DS: **The association of Id-1, MIF and GSTpi with acquired drug resistance in hormone independent prostate cancer cells.** *Oncol Rep* 2005, **13(5)**:983-988.
- Zhang X, Ling MT, Wang X, Wong YC: **Inactivation of Id-1 in prostate cancer cells: A potential therapeutic target in inducing chemosensitization to taxol through activation of JNK pathway.** *Int J Cancer* 2006, **118(8)**:2072-2081.
- Forsythe JA, Jiang BH, Iyer NV, Agani F, Leung SW, Koos RD, Semenza GL: **Activation of vascular endothelial growth factor gene transcription by hypoxia-inducible factor 1.** *Mol Cell Biol* 1996, **16(9)**:4604-4613.
- Shweiki D, Itin A, Soffer D, Keshet E: **Vascular endothelial growth factor induced by hypoxia may mediate hypoxia-initiated angiogenesis.** *Nature* 1992, **359(6398)**:843-845.

42. Kim HJ, Chung H, Yoo YG, Kim H, Lee JY, Lee MO, Kong G: **Inhibitor of DNA binding 1 activates vascular endothelial growth factor through enhancing the stability and activity of hypoxia-inducible factor-1alpha.** *Mol Cancer Res* 2007, **5(4)**:321-329.
43. Fujimoto J, Alam SM, Jahan I, Sato E, Toyoki H, Hong BL, Sakaguchi H, Tamaya T: **Plausible linkage of hypoxia inducible factor-1alpha in uterine cervical cancer.** *Cancer Sci* 2006, **97(9)**:861-867.
44. Volpert OV, Pili R, Sikder HA, Nelius T, Zaichuk T, Morris C, Shiflett CB, Devlin MK, Conant K, Alani RM: **Id1 regulates angiogenesis through transcriptional repression of thrombospondin-1.** *Cancer Cell* 2002, **2(6)**:473-483.

Pre-publication history

The pre-publication history for this paper can be accessed here:

<http://www.biomedcentral.com/1471-2407/9/430/prepub>

Publish with **BioMed Central** and every scientist can read your work free of charge

"BioMed Central will be the most significant development for disseminating the results of biomedical research in our lifetime."

Sir Paul Nurse, Cancer Research UK

Your research papers will be:

- available free of charge to the entire biomedical community
- peer reviewed and published immediately upon acceptance
- cited in PubMed and archived on PubMed Central
- yours — you keep the copyright

Submit your manuscript here:
http://www.biomedcentral.com/info/publishing_adv.asp

