

RESEARCH

Open Access



Exome sequencing implicates a novel heterozygous missense variant in *DSTYK* in autosomal dominant lower urinary tract dysfunction and mild hereditary spastic paraparesis

Clara Vidic^{1†}, Marcin Zaniew^{2†}, Szymon Jurga³, Holger Thiele⁴, Heiko Reutter⁵ and Alina C. Hilger^{1,6*} 

Abstract

Introduction: *DSTYK* encodes dual serine/threonine and tyrosine protein kinase. *DSTYK* has been associated with autosomal-dominant congenital anomalies of the kidney and urinary tract and with autosomal-recessive hereditary spastic paraplegia type 23. Here, we report a father and his two dizygotic twin sons carrying a novel heterozygous missense variant in *DSTYK*, presenting with early onset lower urinary tract dysfunction due to dysfunctional voiding. Moreover, in the later course of the disease, both sons presented with bilateral spasticity in their lower limbs, brisk reflexes, and absence seizures.

Materials and methods: Exome sequencing in the affected father and his affected sons was performed. The sons presented clinically with urinary hesitancy, dysfunctional voiding, and night incontinence till adolescence, while the father reported difficulty in voiding. In the sons, cystoscopy excluded urethral valves and revealed hypertrophy of the bladder neck and trabeculated bladder. Additionally, both sons were diagnosed with absence epilepsy in early childhood. Filtering of exome data focused on rare (MAF < 0.01%), autosomal-dominant variants, predicted to be deleterious, residing in highly conserved regions of the exome.

Results: Exome analysis identified a novel, heterozygous missense variant (c.271C>A (p.Leu91Met)) in *DSTYK* segregating with the disease. In silico prediction analyses uniformly rated the variant to be deleterious suggesting the variant to be disease-causing in the family.

Conclusion: To the best of our knowledge, this is the first report of early onset dysfunctional voiding, seizures, and bilateral spasticity of the lower limbs associated with a novel heterozygous dominant missense variant in *DSTYK*.

Keywords: *DSTYK*, Functional urinary bladder disturbance, HSP23, Hereditary spastic paraparesis, Epilepsy, CAKUT

* Correspondence: alina.hilger@uni-bonn.de

†Clara Vidic and Marcin Zaniew contributed equally to this work.

¹Institute of Human Genetics, University of Bonn, Bonn, Germany

⁶Department of Pediatrics, Children's Hospital, University of Bonn, Bonn, Germany

Full list of author information is available at the end of the article



© The Author(s). 2021 **Open Access** This article is licensed under a Creative Commons Attribution 4.0 International License, which permits use, sharing, adaptation, distribution and reproduction in any medium or format, as long as you give appropriate credit to the original author(s) and the source, provide a link to the Creative Commons licence, and indicate if changes were made. The images or other third party material in this article are included in the article's Creative Commons licence, unless indicated otherwise in a credit line to the material. If material is not included in the article's Creative Commons licence and your intended use is not permitted by statutory regulation or exceeds the permitted use, you will need to obtain permission directly from the copyright holder. To view a copy of this licence, visit <http://creativecommons.org/licenses/by/4.0/>.

Introduction

Lower urinary tract dysfunction may manifest as dysfunctional voiding describing the difficulty to void the urinary bladder due to a dyssynergic striated urethral sphincter-pelvic floor complex but with no clear neurological or anatomical abnormalities [1]. It can occur in any gender [2] at any age. Prevalence data vary widely in different studies (4.2 to 32% in children with wetting problems [3]), mainly because of different study designs and unspecific definitions of the disease. Patients present with difficulty in initiating a void, urinary frequency, urgency, incontinence, and large residual urine volume [1]. This may lead to recurrent urinary tract infections [4] or, in about one third of the cases, to vesicoureteral reflux [5]. Severe complications as hydronephrosis or end stage renal failure occur in about 8% [6].

The causes of voiding dysfunction are heterogeneous. Although learnt and habitual patterns are more frequent [4], congenital cases are reported [7].

Here, we studied a father and his dizygotic twin sons, all presenting with early onset of dysfunctional voiding, indicating an inherited mode of the disease. In addition, both sons presented with absence seizures and bilateral spasticity of their lower limbs in the later course. This prompted us to perform whole exome sequencing (WES) in all three, the father and his twin sons.

Materials and methods

Patients

We examined a previously unreported family from Poland (Fig. 1A). Written informed consent was obtained prior to the analysis. The study was approved by the Ethics Committee of the Medical Faculty of the University of Bonn.

The father and his two dizygotic twin sons presented with voiding dysfunction due to overactivity of the external urethral sphincter during voiding (dysfunctional voiding).

Patient I.1

The father presented with difficulty in voiding, which had started in his thirties. Prostate enlargement was excluded. Furthermore, urolithiasis was diagnosed. Besides the known medical history, the father refused to undergo any further examination.

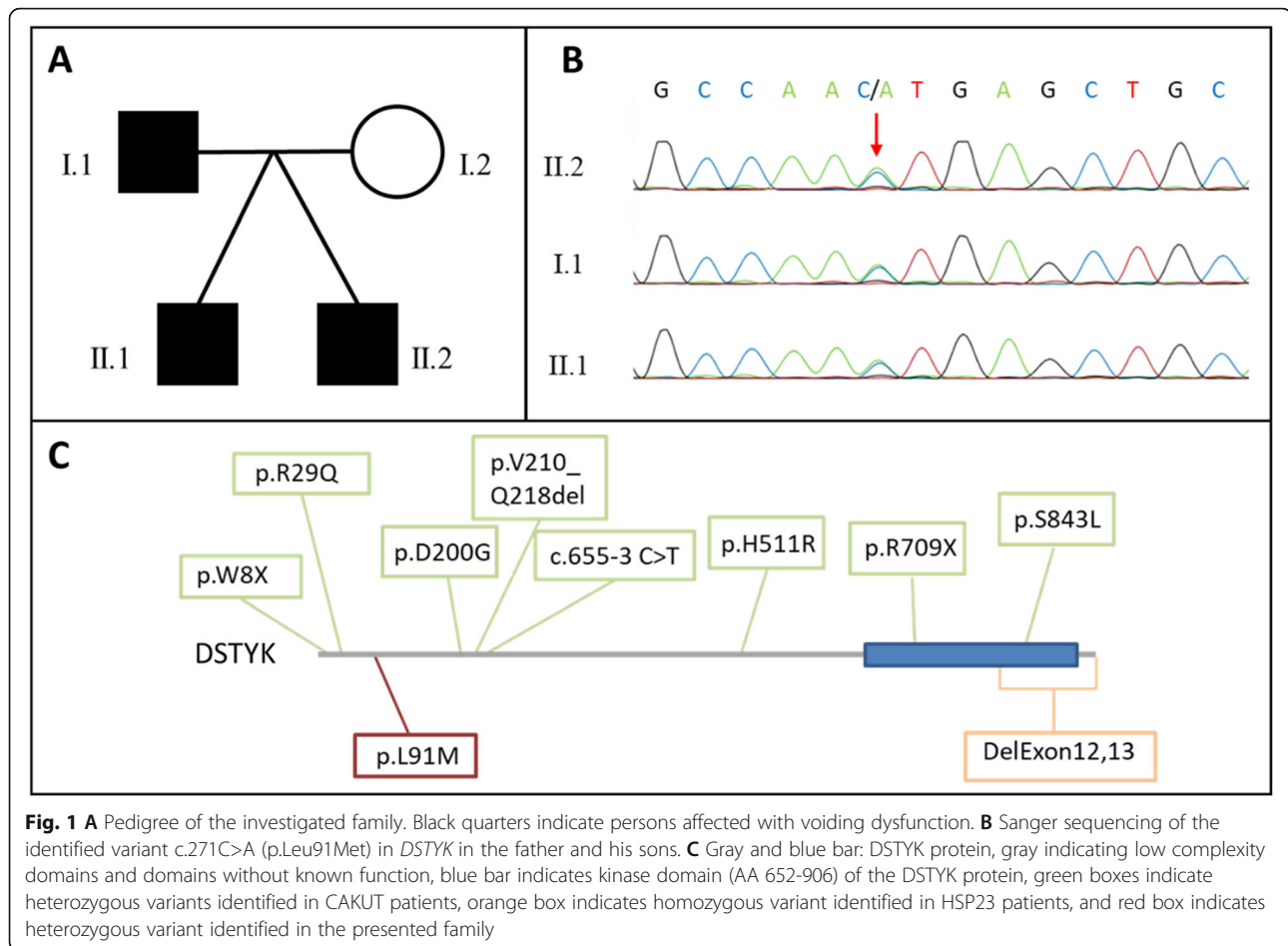
Patient II.1

Patient II.1 presented to out-patient pediatric nephrology clinic with suspected urinary tract infections in the first year of life. Due to lack of febrile infections, no voiding cystourethrography was performed. By the age of 10, he was diagnosed with symptoms of voiding dysfunction by hesitancy, difficulty to urinate, prolonged voiding, and occasional night-time urine incontinence.

Uroflowmetry showed a staccato pattern; no post-void residual urine was found (Suppl. Fig. 1A). Two years later, his renal function was normal, and renal scintigraphy (DMSA) scan showed no scars (Suppl. Fig. 1B). Based on persistence of voiding dysfunction, cystoscopy was performed at the age of 13 and showed trabeculation of the bladder wall, hypertrophy of the bladder neck, and anatomical bladder volume of 300 ml. Alpha-blocker treatment was started at 15 years of age but discontinued 2 years later by the parents because it had not relieved the symptoms. At the last urological follow-up, the patient (19 years) presented with nycturia but no incontinence. Ultrasound of kidneys was normal (Suppl. Fig. 2A, B), but bladder wall appeared in irregular shape (Suppl. Fig. 2C, D). Uroflowmetry was normal. Besides voiding dysfunction, he presented with dizziness, headaches, fainting, and absence seizures starting at 4 years of age and was subsequently diagnosed with an abnormal EEG for occipital epilepsy. Neurologic examination and brain CT scans showed no morphological abnormalities (Suppl. Fig. 4A, B). The anti-epileptic treatment consisted of oxcarbazepine, which was switched to valproic acid due to no improvement. However, side-effects of the therapy resulted in an initiation of levetiracetam treatment. Despite this, his mother reports short in duration episodes of absence. At the last follow-up visit (19 years), neurological examination revealed bilateral spasticity in lower limbs and brisk reflexes. The upper limbs showed normal reflexes. Furthermore, a negative Babinski's sign and mild proximal muscle wasting was observed; still gait appeared normal. Cranial nerves showed normal function. Besides the here described phenotype, no other particular variations, especially concerning abnormal skin patterning, could be observed.

Patient II.2

The second twin also presented to out-patient clinic with recurrent urinary tract infections since his first year of life. Being more severely affected than his brother, a voiding cystourethrography at 2 years of age was performed but showed no abnormalities. At 10 years of age, he was diagnosed with voiding dysfunction showing hesitancy, difficulty to urinate, prolonged voiding, and night urine incontinence. Overall, all symptoms presented to be more severe than in his brother. Hence, uroflowmetry displayed a staccato pattern, voiding time was prolonged, and enlarged urine volume was voided; no post-void residual urine was found (Suppl. Fig. 1C). The assessment of renal function showed normal glomerular filtration rate and no renal scarring on DMSA scan (Suppl. Fig. 1D). Further follow-up studies (at 13 years of age) included voiding cystourethrography, urodynamic study, and cystometry showing an increased bladder volume, decreased bladder sensation, and



normal bladder compliance. A uroflowmetry study displayed a depressed and prolonged flow curve and voiding with abdominal straining. About the same time cystoscopy showed trabeculation of the bladder wall and hypertrophy of the bladder neck. Alpha-blocker treatment was initiated at 15 years of age and discontinued 2 years later for the same reasons as in his brother. At 19 years of age, ultrasound of his kidneys and bladder was normal (Suppl. Fig. 3A, B, C). Still, the patient presented with nycturia and hesitancy to urinate but no incontinence. The uroflowmetry study remains abnormal (Suppl. Fig. 3D). Besides the urological symptoms, he appeared with headaches at 4 years of age. An abnormal EEG led to the diagnosis of epilepsy and brain CT showed focal cortical atrophy. Later on, he developed absence seizures. He is on therapy with topiramate and levetiracetam since the diagnosis of epilepsy. At 18 years of age, EEG still showed abnormalities (Suppl. Fig. 4C, 4D). At the last neurological follow-up (age 19), a spastic paraparesis grade 4/5 in the lower limbs was observed leading to a spastic gait. Babinski's sign was negative, and a mild proximal muscle wasting was noticed. The patient's upper limbs tone and muscle strength were normal and

reflexes brisk. Examination of the cranial nerves displayed no abnormalities. He shows signs of a mild intellectual disability and dysarthria. As mentioned in the brother, no other particular variations, especially concerning abnormal skin patterning, could be observed.

Exome sequencing

WES was performed on all three affected family members at the Next Generation Sequencing Laboratory of the Institute of Human Genetics of the University of Bonn. Genomic DNA was extracted from peripheral blood, captured (Agilent SureSelect Human All Exon v6), and sequence data were generated by a 100 bp paired-end read protocol on an Illumina HiSeq2500 sequencer. Data analysis and filtering of mapped target sequences was accomplished with "Varbank2" (<https://varbank.ccg.uni-koeln.de/varbank2/>), an exome and genome analysis pipeline from the Cologne Center of Genomics.

Based on the pedigree filtering focused on autosomal-dominant variants segregating with disease in all three affected family members, only variants with a minor allele frequency < 0.0001 were considered. Ranking of all

variants contained predicted deleteriousness by four different in silico prediction tools (SIFT, Polyphen2_HVAR, CADD_PHRED, MutationTaster), all provided by Varbank2, and conservation of the amino acid among different vertebrae. Visual inspection of read quality and coverage was performed. Further, in patient II.1 and II.2, the genes known to be causative for hereditary spastic paraplegia were screened according to their predescribed mode of inheritance [8]. A complete list of the screened genes can be found in Suppl. Table 1.

Confirmation of variant detected by WES

The variants identified by WES and prioritized as probably disease causing with the above-mentioned filter were validated via Sanger sequencing. PCR-amplified DNA products were subjected to direct automated sequencing using a 3130XL Genetic Analyzer (Applied Biosystems, Foster City, USA), according to the manufacturer's specifications, with PCR primers also served as sequencing primers.

Results

By WES and subsequent filtering, we identified 13 heterozygous variants segregating between father and sons (Suppl. Table 2). Among these variants, we prioritized a novel, missense variant c.271C>A (p.Leu91Met) in *DSTYK* as probably disease-causing. The other 12 variants were either not novel or located in genes that are known to cause diseases not overlapping our patients' phenotypes. For variants in two genes (*HSF3*, *EYA3*), a correlation with a certain phenotype is not identified (Suppl. Table 1). Reported patients with *DSTYK* variants in literature, however, have similarities with our patients [9–11]. This variant is neither reported in gnomAD v2.1.1./v3.1 nor in dbSNP (last check: 19.02.2021). The amino acid change affects a highly conserved leucine present down to *X. tropicalis* and zebrafish but absent in birds. The variant was predicted to be deleterious by three different prediction programs (SIFT (0,02), PolyPhen (0,794), and MutationTaster (damaging)) and reached a CADD-PHRED score of 24.5. Sanger sequencing confirmed the variant in all three, the father and his two sons (Fig. 1B). Potentially disease-causing variants in genes, known to be causative for hereditary spastic paraplegia (according to Mackay-Sim) [8], could not be identified in the brothers.

Discussion

Here, we report a father and his two dizygotic twin sons presenting with early onset lower urinary tract dysfunction due to dysfunctional voiding. Moreover, in the later course of the disease, both sons presented with bilateral spasticity in their lower limbs, brisk reflexes, and

seizures. Exome analysis identified a novel, heterozygous missense variant in *DSTYK*.

DSTYK encodes dual serine/threonine and tyrosine protein kinase. Hitherto, it has been associated with autosomal-dominant congenital anomalies of the kidney and urinary tract (CAKUT) (MIM:610805) comprising solitary kidney, renal hypodysplasia, ureteropelvic junction obstruction, vesicoureteral reflux, and congenital hydronephrosis [9, 10]. Interestingly, Sanna-Cherchi et al. (2013) reported three patients with epilepsy from a family of seven affected CAKUT patients, all carrying a heterozygous splice site variant in exon 2, and one with early-onset ataxia additional to an ureteropelvic junction obstruction, carrying a heterozygous stop variant in exon 1 (Fig. 1C, Suppl. Table 3) [9]. However, it must be mentioned that the splice site variant has also been found in patients with no renal pathologies [12]. If this is explained through incomplete penetrance is not yet fully understood. Therefore, pathogenic *DSTYK* variants in CAKUT patients were reclassified as variants of unknown significance [13]. Here, the two affected sons presented with absence epilepsy. At the time of writing, the father denied an EEG examination for himself, not allowing for a final statement on the presence or absence of epilepsy in the father. As mentioned earlier, mutations in *DSTYK* have been described to cause autosomal-recessive hereditary spastic paraplegia 23 (HSP23) (MIM:270750) [11]. The disease spectrum contains spastic paralysis of the lower limbs, scoliosis, peripheral neuropathy, and abnormal skin and hair pigmentation, but no patients with epilepsy are reported so far [11, 14–17]. The phenotypic spectrum occurring in the presented family neither overlaps the classical CAKUT spectrum, as anatomical causes for the voiding dysfunction were excluded, nor does it present with the so far known genetic inheritance model of HSP23. Still, the neurological abnormalities of the lower limbs and the voiding dysfunction are suggestive of a HSP23-related phenotype.

Previous, functional studies on *DSTYK* revealed that it is expressed in mesenchymal-derived cells of all major organs (heart, lung, liver, colon, kidney, skin) [9]. In the genitourinary tract, expression was detected in developing mouse kidney as well as in human pediatric renal tubular epithelia and urothelium and smooth muscle of the ureter [9]. It is also widely expressed in central nervous system structures, but remarkably high in cerebellum and cerebral cortex [18]. Thus, suggesting that involvement in organ development and organ maintenance could be possible. Functional studies showed that it is a positive regulator of ERK phosphorylation downstream of fibroblast growth factor receptor activation and further is involved in the induction of caspase-dependent apoptosis as well as caspase-independent cell

death pathways [19]. *Dstyk* KO mouse model are fertile and have no significant morphological defects. While only sections of the brain were conducted and the urinary tract was not assessed separately, homozygous mice show impaired capabilities of learning and memory [20]. Zebrafish Morpholino knockdown showed growth retardation, abnormal morphogenesis of the tail, cloacal malformations, defects in jaw development, and loss of the median fin fold. Pericardial effusion in 5-day-old morphant larvae was interpreted as attributable to both heart and kidney failure [9].

While patients expressing HSP23 phenotype only were found to carry deletions of the last two exons, the variants identified in *CAKUT* patients do not seem to cluster to a certain domain or part of the gene (Fig. 1C). Therefore, further functional studies of *DSTYK* exploring function and regulation are needed to determine the effects of heterozygous stop and missense variants as well as the homozygous deletions. Until then, the exact pathomechanism that would explain recessive deletions and dominant missense variants to cause the same phenotype remains speculative. Nevertheless, over 30 disease genes have been described so far with both recessive and dominant causative variants within the same gene [21]. As allelic heterogeneity may be explained in part by the functional consequences of pathogenic variants, we assume that the protein harboring deletions undergo nonsense mediated decay. Therefore, heterozygous carrier of this variant might not develop a phenotype as regulatory processes possibly could increase the amount of transcription, whereas, with missense variants, only half of the transcribed protein is fully functional and therefore already pathogenic in a heterozygous state. Regarding to a possible overlap of the phenotypes, it is also interesting to note that almost 10% of the highly expressed genes in early kidney development (in ureteric bud and metanephric mesenchyme) are also associated with neuronal growth and/or differentiation [22].

Until now, it remains unclear if *CAKUT* patients with a variant in *DSTYK* might develop neurological problems with late onset as the three patients described by Sanna-Cherchi et al. (2013) were diagnosed for epilepsy in their thirties [9]. Moreover, incomplete penetrance in this family was suggested (Suppl. Table 3). Also, in the sons of the here described family, besides being diagnosed for epilepsy in first decade of life, further neurological problems hinting towards HSP first became obvious at the end of second decade of life. Therefore, they were not considered as HSP patients until WES was performed and did not receive any specific HSP treatment.

Conclusion

Thus, it might be discussed whether *CAKUT* patients with potentially causative variants in *DSTYK* should be

additionally investigated and monitored towards neurological symptoms. Further, patients with bladder dysfunction should be investigated for additional neurological symptoms, possibly occurring in the further course.

To the best of our knowledge, this is the first report of early onset dysfunctional voiding, seizures, and bilateral spasticity of the lower limbs associated with a novel heterozygous dominant missense variant in *DSTYK*.

Abbreviations

CAKUT: Congenital anomalies of the kidney and urinary tract; HSP23: Hereditary spastic paraplegia 23; WES: Whole exome sequencing

Supplementary Information

The online version contains supplementary material available at <https://doi.org/10.1186/s40348-021-00122-y>.

Additional file 1.

Additional file 2.

Additional file 3.

Additional file 4.

Acknowledgements

We thank the family for participating in this study. We also acknowledge help from Dr. Andrzej Haliński.

Authors' contributions

Conceptualization: A.C.H. Data curation: C.V., M.Z., S.J., A.C.H. Formal analysis: C.V., H.T., A.C.H. Investigation: C.V., M.Z., S.J., A.C.H. Methodology: C.V., A.C.H. Resources: C.V., H.R., A.C.H. Writing—original draft: C.V., M.Z. H.R. A.C.H. Writing—review and editing: C.V., A.C.H. All authors have read and approved the manuscript.

Funding

C.V. is supported by BONFOR grant O-149.0133. A.C.H. is supported by BONFOR grant O-149.0123.

Availability of data and materials

Molecular findings are provided in Supplementary Table 1 and clinical descriptions are provided in the main text. All data not included in the manuscript or supplemental material, such as primer sequences, can be obtained upon request.

Declarations

Ethics approval and consent to participate

The research project was approved by the Ethics Committee of the Medical Faculty of the University of Bonn (number 031/19). Written informed consent was obtained prior to the analysis. The study was approved by the Ethics Committee of the Medical Faculty of the University of Bonn. Consent for publication was obtained.

Competing interests

The authors declare that they have no competing interests.

Author details

¹Institute of Human Genetics, University of Bonn, Bonn, Germany.

²Department of Pediatrics, University of Zielona Góra, Zielona Góra, Poland.

³Department of Neurology, University of Zielona Góra, Zielona Góra, Poland.

⁴Cologne Center for Genomics, University of Cologne, Cologne, Germany.

⁵Department of Neonatology and Paediatric Intensive Care, University Hospital Erlangen, Erlangen, Germany. ⁶Department of Pediatrics, Children's Hospital, University of Bonn, Bonn, Germany.

Received: 2 June 2021 Accepted: 25 August 2021
Published online: 04 October 2021

References

- Sinha S (2011) Dysfunctional voiding: a review of the terminology, presentation, evaluation and management in children and adults. *Indian J Urol* 27(4):437–447. <https://doi.org/10.4103/0970-1591.91429>
- Groutz A, Blaivas JG, Pies C, Sassone AM (2001) Learned voiding dysfunction (non-neurogenic, neurogenic bladder) among adults. *Neurourol Urodyn* 20(3):259–268. <https://doi.org/10.1002/nau.1003>
- Chase J, Austin P, Hoebeke P, McKenna P, International Children's Continence Society (2010) The management of dysfunctional voiding in children: a report from the Standardisation Committee of the International Children's Continence Society. *J Urol* 183:1296–1302
- Clothier JC, Wright AJ (2018) Dysfunctional voiding: the importance of non-invasive urodynamics in diagnosis and treatment. *Pediatr Nephrol* 33(3):381–394. <https://doi.org/10.1007/s00467-017-3679-3>
- Glassberg KI, Combs AJ, Horowitz M (2010) Nonneurogenic voiding disorders in children and adolescents: clinical and videourodynamic findings in 4 specific conditions. *J Urol* 184(5):2123–2127. <https://doi.org/10.1016/j.juro.2010.07.011>
- Sandri S (2017) 470 - Adult follow up of major dysfunctional voiding in children. *Eur Urol Suppl* 16(3):e817–e818. [https://doi.org/10.1016/S1569-9056\(17\)30531-6](https://doi.org/10.1016/S1569-9056(17)30531-6)
- Vidal I, Héloüry Y, Ravasse P, Lenormand L, Leclair M-D (2009) Severe bladder dysfunction revealed prenatally or during infancy. *J Pediatr Urol* 5(1):3–7. <https://doi.org/10.1016/j.jpuro.2008.11.004>
- Mackay-Sim A (2021) Hereditary spastic paraplegia: from genes, cells and networks to novel pathways for drug discovery. *Brain Sci* 11(3):403. <https://doi.org/10.3390/brainsci11030403>
- Sanna-Cherchi S, Sampogna RV, Papeta N, Burgess KE, Nees SN, Perry BJ, Choi M, Bodria M, Liu Y, Weng PL, Lozanovski VJ, Verbitsky M, Lugani F, Sterken R, Paragas N, Caridi G, Carrea A, Dagnino M, Materna-Kirylyuk A, Santamaria G, Murtas C, Ristoska-Bojkovska N, Izzi C, Kakac N, Bianco B, Giberti S, Gigante M, Piaggio G, Gesualdo L, Kosuljandic Vukic D, Vukojevic K, Saraga-Babic M, Saraga M, Gucev Z, Allegri L, Latos-Bielenska A, Casu D, State M, Scolari F, Ravazzolo R, Kiryluk K, al-Awqati Q, D'Agati VD, Drummond IA, Tasic V, Lifton RP, Ghiggeri GM, Gharavi AG (2013) Mutations in DSTYK and dominant urinary tract malformations. *N Engl J Med* 369(7):621–629. <https://doi.org/10.1056/NEJMoa1214479>
- Wu H, Xu Q, Xie J, Ma J, Qiao P, Zhang W, Yu H, Wang W, Qian Y, Zhang Q, Guo Y, Tang Y, Chen XN, Wang Z, Chen N (2017) Identification of 8 novel mutations in nephrogenesis-related genes in chinese han patients with unilateral renal agenesis. *Am J Nephrol* 46(1):55–63. <https://doi.org/10.1159/000477590>
- Lee JW, Hsu C-K, Michael M, Nanda A, Liu L, McMillan JR, Pourreyron C, Takaichi T, Tolar J, Reid E, Hayday T, Blumen SC, Abu-Mouch S, Straussberg R, Basel-Vanagaite L, Barhum Y, Zouabi Y, al-Ajmi H, Huang HY, Lin TC, Akiyama M, Lee JYY, McLean WHI, Simpson MA, Parsons M, McGrath JA (2017) Large intragenic deletion in DSTYK underlies autosomal-recessive complicated spastic paraparesis, SPG23. *Am J Hum Genet* 100(2):364–370. <https://doi.org/10.1016/j.ajhg.2017.01.014>
- Heidet L, Morinière V, Henry C, De Tomasi L, Reilly ML, Humbert C, Alibeu O, Fourrage C, Bole-Feysot C, Nitschké P et al (2017) Targeted exome sequencing identifies PBX1 as involved in monogenic congenital anomalies of the kidney and urinary tract. *J Am Soc Nephrol* 28(10):2901–2914. <https://doi.org/10.1681/ASN.2017010043>
- Knoers N, Antignac C, Bergmann C, Dahan K, Giglio S, Heidet L, Lipska-Ziętkiewicz BS, Noris M, Remuzzi G, Vargas-Poussou R, Schaefer F, ERA-EDTA Working Group for Inherited Kidney Diseases (WGKID) and the Molecular Diagnostics Taskforce of the European Rare Kidney Disease Reference Network (ERKNet) (2021) Genetic testing in the diagnosis of chronic kidney disease: recommendations for clinical practice. *Nephrol Dial Transplant* gfab218. <https://doi.org/10.1093/ndt/gfab218>
- Bamforth JS (2003) Vitiligo-spasticity syndrome: new case. *Clin Dysmorphol* 12(2):137–139. <https://doi.org/10.1097/00019605-200304000-00013>
- Blumen SC, Bevan S, Abu-Mouch S, Negus D, Kahana M, Inzelberg R, Mazarib A, Mahamid A, Carasso RL, Slor H, Withers D, Nisipeanu P, Navon R, Reid E (2003) A locus for complicated hereditary spastic paraplegia maps to chromosome 1q24-q32. *Ann Neurol* 54(6):796–803. <https://doi.org/10.1002/na.10768>
- Daras M, Tuchman AJ, David S (1983) Familial spinocerebellar ataxia with skin hyperpigmentation. *J Neurol Neurosurg Psychiatry* 46(8):743–744. <https://doi.org/10.1136/jnnp.46.8.743>
- Lison M, Kornbrut B, Feinstein A, Hiss Y, Boichis H, Goodman RM (1981) Progressive spastic paraparesis, vitiligo, premature graying, and distinct facial appearance: a new genetic syndrome in 3 sibs. *Am J Med Genet* 9(4):351–357. <https://doi.org/10.1002/ajmg.1320090411>
- Peng J, Dong W, Chen Y, Mo R, Cheng J-F, Hui C-C, Mohandas N, Huang C-H (2006) Dusty protein kinases: primary structure, gene evolution, tissue specific expression and unique features of the catalytic domain. *Biochim Biophys Acta* 1759(11-12):562–572. <https://doi.org/10.1016/j.bbexp.2006.10.004>
- Zha J, Zhou Q, Xu L-G, Chen D, Li L, Zhai Z, Shu H-B (2004) RIP5 is a RIP-homologous inducer of cell death. *Biochem Biophys Res Commun* 319(2):298–303. <https://doi.org/10.1016/j.bbrc.2004.04.194>
- Li K, Liu J-W, Zhu Z-C, Wang H-T, Zu Y, Liu Y-J, Yang Y-H, Xiong Z-Q, Shen X, Chen R, Zheng J, Hu ZL (2014) DSTYK kinase domain ablation impaired the mice capabilities of learning and memory in water maze test. *Int J Clin Exp Pathol* 7(10):6486–6492
- Dworschak GC, Punetha J, Kalanithy JC, Mingardo E, Erdem HB, Akdemir ZC, Karaca E, Mitani T, Marafi D, Fatih JM, Jhangiani SN, Hunter JV, Dakal TC, Dhabhai B, Dabbagh O, Alsaif HS, Alkuraya FS, Maroofian R, Houlden H, Efthymiou S, Dominik N, Salpietro V, Sultan T, Haider S, Bibi F, Thiele H, Hoefele J, Riedhammer KM, Wagner M, Guella I, Demos M, Keren B, Buratti J, Charles P, Nava C, Héron D, Heide S, Valkanas E, Waddell LB, Jones KJ, Oates EC, Cooper ST, MacArthur D, Syrbe S, Ziegler A, Platzer K, Okur V, Chung WK, O'Shea SA, Alcalay R, Fahn S, Mark PR, Guerrini R, Vetro A, Hudson B, Schnur RE, Hoganson GE, Burton JE, McEntagart M, Lindenbergt T, Yilmaz Ö, Odermatt B, Pehlivan D, Posey JE, Lupski JR, Reutter H (2021) Biallelic and monoallelic variants in PLXNA1 are implicated in a novel neurodevelopmental disorder with variable cerebral and eye anomalies. *Genet Med*. <https://doi.org/10.1038/s41436-021-01196-9>
- Stuart HM, Roberts NA, Hilton EN, McKenzie EA, Daly SB, Hadfield KD, Rahal JS, Gardiner NJ, Tanley SW, Lewis MA, Sites E, Angle B, Alves C, Lourenço T, Rodrigues M, Calado A, Amado M, Guerreiro N, Serras I, Beetz C, Varga RE, Silay MS, Darlow JM, Dobson MG, Barton DE, Hunziker M, Puri P, Feather SA, Goodship JA, Goodship THJ, Lambert HJ, Cordell HJ, the UK VUR Study Group, Saggari A, Kinali M, the 4C Study Group, Lorenz C, Moeller K, Schaefer F, Bayazit AK, Weber S, Newman WG, Woolf AS (2015) Urinary tract effects of HPSE2 mutations. *J. Am. Soc. Nephrol.* 26(4):797–804. <https://doi.org/10.1681/ASN.2013090961>

Publisher's Note

Springer Nature remains neutral with regard to jurisdictional claims in published maps and institutional affiliations.

Submit your manuscript to a SpringerOpen journal and benefit from:

- Convenient online submission
- Rigorous peer review
- Open access: articles freely available online
- High visibility within the field
- Retaining the copyright to your article

Submit your next manuscript at ► [springeropen.com](https://www.springeropen.com)