

REVIEW

The role of imaging in the management of primary pleural malignancies

C S Ng

Department of Radiology, MD Anderson Cancer Center, Houston, USA

Corresponding address: C S Ng, Department of Radiology, Box 57, MD Anderson Cancer Center, 1515 Holcombe Boulevard, Houston, TX 77030-4009, USA. E-mail: cng@mdanderson.org

Date accepted for publication 2 July 2003

Abstract

Malignant pleural mesothelioma is a rare tumour, but its incidence is increasing. Imaging is invariably involved in its diagnosis, staging, and follow-up. Although there are some characteristic radiological signs, none are pathognomonic. Computed tomography (CT) and magnetic resonance (MR) have similar local staging accuracies, but have distinct limitations; MR has marginal superiority in specific areas and should probably be offered to surgical candidates. The capabilities of multidetector CT await evaluation. The role of positron emission tomography (PET), and PET-CT is undefined, but will likely have a major contribution. The challenges in imaging are matched by controversies in staging and treatment, which require future close multidisciplinary and multicentre collaboration.

Keywords: Malignant pleural mesothelioma; staging; imaging; CT; MRI; PET.

Introduction

Primary malignant pleural tumours include diffuse malignant pleural mesothelioma (MPM), localised fibrous tumour, and pleural sarcoma, of which MPM is by far the commonest (approximately 90%), and is the focus of this article. Although a rare tumour, accounting for less than 1% of all thoracic neoplasms, diffuse MPM is assuming increasing importance because of its rising incidence. In Western Europe the incidence of MPM is expected to continue rising for the next 2 decades.

MPM is a locally aggressive tumour that has historically been associated with refractoriness to most standard forms of therapy and a dismal prognosis. However, in more recent years there have been reports of improving chemotherapy regimes, and some indication that multimodality therapy may offer some promise in selected patients.

Imaging is crucial in the diagnosis of MPM, and it also plays an important role in staging and follow-up.

Epidemiology and pathology

In Western Europe, the incidence of MPM is estimated to be 2–15 per million, with 5000 deaths in 1998. In the UK, there are approximately 1600 deaths/year. In the USA, the incidence is approximately 7–13 per million white males, with approximately 2300 deaths at the millennium^[1].

The incidence and mortality rates have been consistently rising, at about 5–10% per year, and is expected to continue rising to peak in Western Europe in the period 2010–20, with an estimated 9000 deaths in 2018^[2]. The incidences reflect population exposures to asbestos, with a 20–40 year time lag. The peak incidence in USA may have been reached because maximum exposures to asbestos were in 1930–60, while in the UK this was in the 1970s. Incidences may continue to rise beyond the next 2 decades in developing countries in which appropriate regulations have been, or are, less stringent.

The median age of disease is 60 years, and is more common in men (two to six-fold), largely because of the

occupational association discussed below. Women, however, may be involved by 'collateral' exposure through their spouses, or environmental exposure. Spontaneous occurrences are comparatively rare in both men and women, and extremely rare in children.

Development of the tumour is essentially causally associated with occupational exposure to asbestos: a mineral fibre with heat and fire resistant properties. The risk of MPM is a function of the dose of asbestos exposure, and time to first exposure to the power of 3–4.

The most tumourigenic asbestos fibre is thought to be crocidolite, with other subtypes including amosite and chrysotile ('blue', 'brown', and 'white' asbestos, respectively). The microscopic presence of 'asbestos (ferruginous) bodies' is evidence of previous exposure to asbestos. Other suggested aetiological factors include exposure to other mineral fibres (e.g. zeolite or erionite), chronic inflammation and scarring (e.g. TB and empyemas), irradiation and intrapleural thorium dioxide, genetic factors, and the viral oncogene Simian virus SV40 (a contaminant in a number of human vaccines).

Mesotheliomas are tumours that arise from the serosal lining of body cavities. The precise patho-physiological origin of the tumour is not known. In the thorax, MPM is thought initially to involve the parietal pleura, forming grey–white pleural plaques and nodules ranging from 0.5 to 3 cm in thickness, and to subsequently involve the visceral pleura, frequently fusing the two surfaces. The tumour typically spreads locally along pleural surfaces, including the interlobar fissures, in a confluent sheet-like, lobulated or nodular form, eventually creating a pleural 'rind' and encasing and compressing the underlying lung. The tumour is usually diffuse rather than focal. Pleural effusions, sometimes large, may be a dominant feature. The tumour is typically locally invasive, with a tendency to involve the diaphragm, soft tissues and ribs of the chest wall, pericardium and heart. The tumour more commonly affects the inferior hemithorax (probably because of gravitational effects), and the right side (60%, probably because of the greater pleural surface on this side). Bilateral disease is rare (<5%).

Contiguous spread to loco-regional lymph nodes has hitherto been considered comparatively uncommon, but recent studies have suggested involvement in up to 50% of cases^[3]. Lymphangitic spread may also occur. Nodal metastases are present in 40–45% of cases, with abdominal nodal metastases in 8%^[4]. Similarly, haematogenous spread, also previously considered uncommon, is prevalent at post-mortem (50–67%) and is being increasingly recognized as a mode of dissemination at the time of staging and follow-up^[5]. Metastases may occur to the contralateral lung (20–80% at autopsy), abdominal contents, bones, and brain. Liver metastases are rare and may calcify. The diaphragm is frequently invaded, and transdiaphragmatic spread to involve the peritoneal cavity has been reported in one-third of cases at post-mortem.

Of note, asbestos exposure is also associated with benign pleural conditions, including benign pleural plaques (hyalinized collagen fibres), diffuse pleural fibrosis/thickening, and pleural effusions of benign asbestos pleurisy. There is no evidence that benign pleural plaques are premalignant or precursors to MPM^[4]. Asbestos-related mesothelioma may also involve the peritoneal linings, but is less common.

Pathological variants include epithelial ('carcinomatoid', 55–65%), sarcomatoid (10–15%), or mixed ('biphasic', 20–35%) subtypes. Pleural effusions are more common in epithelial variants, while sarcomatoid subtypes carry a worse prognosis.

Differential diagnosis

Differential considerations on gross morphology include an organising pleural effusion, chronic infection (e.g. tuberculosis), connective-tissue disease, and talcosis. The diagnosis is made more challenging because asbestos exposure, as indicated above, is associated with a range of benign pleural diseases, which are in fact *more common* than MPM.

MPM can also be a challenging pathological diagnosis, for example: epithelial mesothelioma vs. metastatic adenocarcinoma (e.g. from lung, breast, stomach, kidney, ovary or prostate), sarcomatoid mesothelioma vs. sarcoma (e.g. fibrosarcoma), and mixed/biphasic mesothelioma vs. sarcomatoid carcinoma or synovial sarcoma. Differentiation of MPM from benign disease can also be challenging, for example: well-differentiated epithelial mesothelioma vs. reactive mesothelial proliferation, sarcomatoid or desmoplastic mesothelioma vs. benign reactive pleural fibrosis, and benign vs. malignant mesothelial proliferation. Diagnosis may require special histological stains, immuno-histochemistry, ultrastructural and/or cytogenetic analysis^[4,6].

Treatment and prognosis

The prognosis has historically been extremely bleak, with median survivals of less than 1 year without treatment from the time of diagnosis, and with most dying within 2 years of diagnosis. Death typically occurs from respiratory failure, cardiac dysfunction secondary to local invasion, or bowel obstruction from transdiaphragmatic spread. There is no consensus on treatment, which includes supportive and palliative therapy, and single modality to aggressive multimodality strategies^[5].

Radical surgery offers the best hope of long-term survival. Surgical options include extrapleural pneumonectomy (EPP, 'pleuropneumonectomy') or decortication ('pleurectomy'). EPP involves the en-bloc resection of the parietal pleura, lung, ipsilateral hemidiaphragm, and ipsilateral pericardium, typically with prosthetic reconstruction or reinforcement of the diaphragm and

pericardium. Decortication, which is associated with lower peri-operative morbidity, involves stripping of the pleura, but typically the diaphragmatic and mediastinal pleura cannot be completely removed. It is employed in extremely limited disease, or conversely, in advanced disease as a cytoreductive or palliative procedure, the latter most commonly being an attempt to prevent recurrent pleural effusions. Sadly, few patients have operable disease. Furthermore, local recurrences are common because microscopic clearance is difficult to achieve. Although some isolated long-term survivals following surgery have been reported, they are distinctly uncommon.

Radiotherapy is limited by the typically large target volumes involved and consequent toxicity to adjacent organs. Furthermore, the tumour tends to be relatively radio-resistant, with local tumour progression reported with substantial doses of up to 70 Gray. The tumour is also relatively chemo-insensitive, with typical response rates of less than 20%^[4], although more promising response rates of greater than 40% have recently been reported with combinations of pemetrexed or gemcitabine with cisplatin.

Combinations of surgery and radiotherapy and/or chemotherapy have been undertaken in varying patient groups. A study of 183 patients has raised the possibility that multimodality treatment with EPP, followed by adjuvant chemotherapy and radiotherapy, can improve median survival to 19 months, with survivals of 38% at 2 years, and 15% at 5 years^[7]. One advantage of this approach is that higher doses of radiotherapy can be delivered, as one of the limiting factors in radiation delivery is the toxic effects on lung parenchyma. It should, however, be noted that these results were achieved in a highly selected group of patients.

Other more experimental treatments include immunotherapy, gene therapy, photodynamic therapy, and tyrosine kinase and angiogenesis inhibitors.

A number of prognostic factors have been proposed including the presence of pain, weight loss, anaemia, leucocytosis, thrombocytosis, and poor performance status and age. However, there is uniform agreement that non-epithelial histology and advanced stage disease carry a poor prognosis^[3,7].

Staging

A number of staging systems have been proposed, but have been under debate for their prognostic validity and clinical utility. Probably the most widely used system historically was that proposed by Butchart in 1976; for comparative purposes, a more recent 'Brigham' system, which is essentially a surgically based system, is also presented (Table 1).

A TNM-based system proposed by the International Mesothelioma Interest Group (IMIG) in 1995, has recently been adopted by the American Joint Committee on Cancer (AJCC/UICC, 2002), and is presented in

Table 2. Excellent diagrams illustrating the T-staging can be reviewed elsewhere^[8].

It should be noted that most patients have advanced disease at presentation, 70–80% Stage III disease; and only 8–18% Stage I.

Role of imaging at diagnosis

The onset of symptoms of MPM is typically insidious and non-specific, including dyspnoea, chest pain, cough, weight loss, and general malaise, which contributes to the late presentation in most cases. Chest radiography is generally the first radiological investigation, and allows radiologists the opportunity to be instrumental in suggesting the diagnosis at outset.

The typical features of MPM are of pleural thickening, which may be focal or diffuse, uniform or nodular, and may extend into the interlobar fissures. On occasions, the pleural thickening may be comparatively minor and, indeed, may be obscured by what appears to be a simple pleural effusion. Pleural fluid, which may be large at the time of presentation, may be loculated in the pleural cavity or fissures. One suggested clue to the possibility of MPM is the lack of mediastinal shift in the presence of extensive pleural disease, attributed to the encasement of the pleura by the solid rind and fixation of the mediastinum.

Computed tomography

Computed tomography (CT) of the chest is the next most appropriate investigation, as it allows better delineation of the pleural disease, differentiation of pleural thickening and pleural fluid, and extent of local disease within the thorax, and is the primary staging modality.

The findings reflect those described on gross pathology above, but are unfortunately entirely non-specific, and differentiation of malignant from benign disease is challenging, let alone differentiation of MPM from other malignant pleural diseases, such as metastases, which are in fact more common. Features that suggest a malignant aetiology include a circumferential distribution or lung encasement, nodular morphology, pleural thickening of greater than 1 cm, and involvement of the mediastinal pleura.

Co-existent stigmata of previous asbestos exposure, e.g. pleural calcification and interstitial lung disease (asbestosis), which in principle would be useful clues, are not frequently seen. A further difficulty in diagnosis is that asbestos exposure itself is also associated with the production of benign pleural plaques, which can be difficult to differentiate from MPM, although the former characteristically have sharp edges, and is separate from the extrapleural fat and endothoracic fascia. Diffuse pleural thickening may also occur in association with asbestos-related pulmonary fibrosis, i.e. asbestosis.

Table 1 Comparative staging systems for MPM: Butchart and 'Brigham' systems

Stage	Butchart system	'Brigham' system
I	Tumour confined within the 'capsule' of the parietal pleura, i.e. ipsilateral lung, pericardium	Disease completely resected within the capsule of the parietal pleura without adenopathy; ipsilateral pleura, lung, pericardium, diaphragm, or chest-wall disease limited to previous biopsy sites
II	Tumour invading chest wall or involving mediastinal structures, e.g. oesophagus, heart; intrathoracic nodal involvement	All of stage I with positive resection margins and/or intrapleural adenopathy
III	Tumour penetrating diaphragm to involve peritoneum directly, extrathoracic nodal involvement	Local extension of disease into chest wall or mediastinum, heart, or through diaphragm, peritoneum, or with extrapleural lymph node involvement
IV	Distant haematogenous metastases	Distant metastatic disease

Table 2 TNM (IMIG) and (AJCC/UICC) staging system for diffuse MPM

Stage	Findings		
T stage	T1a T1b T2	Tumour limited to parietal pleura Tumour involving parietal pleura, with foci in visceral pleura Tumour involving pleura with one of the following: involvement of diaphragmatic muscle confluent visceral pleural tumour (including fissures) or extension of tumour from visceral pleura into underlying pulmonary parenchyma	
	T3	Locally advanced, but potentially resectable tumour. Tumour involving all pleural surfaces with at least one of the following: involvement of endothoracic fascia; extension into mediastinal fat; solitary, completely resectable focus of tumour extending into soft tissues of chest wall; non-transmural involvement of pericardium	
	T4	Locally advanced, but technically unresectable. Tumour involving all pleural surfaces with at least one of the following: Diffuse extension or multifocal masses of tumour in chest wall, with or without associated rib destruction; direct transdiaphragmatic extension of tumour to peritoneum; direct extension of tumour to contralateral pleura; direct extension to one or more mediastinal organs, e.g. direct extension of tumour into spine; extension through internal surface of pericardium, with or without pericardial effusion, or involvement of myocardium	
	N stage	NX N0 N1 N2 N3	Not assessable No regional nodal metastases Ipsilateral bronchopulmonary or hilar metastases Ipsilateral mediastinal or subcarinal metastases Contralateral mediastinal, contralateral internal mammary, or ipsilateral or contralateral supraclavicular metastases
		M stage	MX M0 M1
Stage grouping			TNM equivalent
Ia			T1a N0 M0
Ib		T1b N0 M0	
II	T2 N0 M0		
III	Any T3 M0 Any N1 M0 Any N2 M0		
	IV	Any T4 Any N3 Any M1	

As with other pathological processes, abutment (indicated by loss of fat planes between the tumour and adjacent organs), even with displacement of structures, does not necessarily indicate invasion; conversely, involvement cannot be excluded in these circumstances (Fig. 1). Infiltration into adjacent organs is more definitive evidence of involvement, and can sometimes be more

clearly appreciated following intravenous (IV) contrast administration. Again, however, caution should be exercised, as post-contrast enhancement in adjacent tissues may be seen as a reactive response.

Signs of rib destruction and invasion into the chest-wall musculature are strong evidence of chest-wall involvement (Fig. 2). Assessment for pericardial invasion

can be difficult, although the presence of pericardial thickening, especially if nodular, or a pericardial effusion is suggestive of involvement, although again not specific.

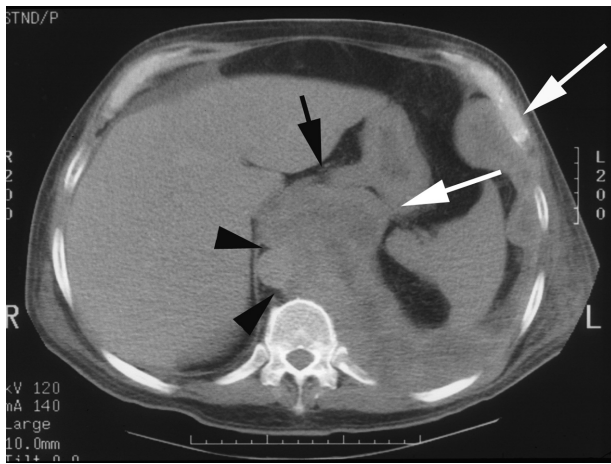


Figure 1 CT showing left MPM with extensive involvement of the diaphragm, including diaphragmatic crus and slips (*long arrows*). There is abutment and displacement of the descending thoracic aorta (*arrow heads*) and distal oesophagus (*short arrow*), highly suggestive (but not conclusive) of invasion.

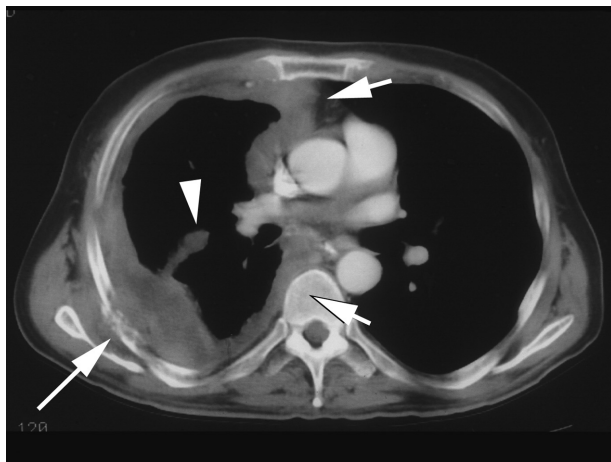


Figure 2 CT showing right MPM with characteristic diffuse pleural thickening, including involvement of the mediastinal pleura (*short arrows*) and oblique fissure (*arrow head*), with encasement of the lung and associated rib destruction (*long arrow*).

In an early study of 41 patients, evaluating the accuracy of CT in predicting resectability in three major anatomic regions (diaphragm, chest wall, and mediastinum), Patz *et al.*^[9] reported high sensitivities of greater than 90%. Noticeably, specificity was less than 50%. It should be noted that just under half the CT examinations in this study were obtained at 8–10 mm sections on conventional (non-helical) scanners, and without IV

contrast. Interestingly, no nodal disease was identified in the patients who had surgery (34 patients).

In a subsequent prospective study of 65 patients evaluating the accuracy of CT in staging, Heelan *et al.*^[10] reported accuracies for T stage less than 73% (but mostly in the 50–60% range), and for nodal N1 or N2 disease less than 50%. In this study, CTs were acquired with IV contrast media, but from a mixture of conventional (10 mm collimation), and helical scanners (7 mm collimation, 1.5 pitch).

Magnetic resonance imaging

Magnetic resonance imaging (MRI) offers better soft-tissue contrast compared to CT, and also has a direct multiplanar capability, which is potentially useful when trying to assess local invasion. The signs of adjacent organ involvement are similar to CT.

Typical MRI protocols include axial T1 and T2-weighted spin-echo sequences, together with coronal and/or sagittal planes of the affected side. Cardiac gating and respiratory compensation improve image quality, but prolong examination times. The tumour is typically of intermediate signal intensity on T1 weighting (similar to muscle), and of moderately increased signal on T2 weighting compared to muscle. Some authors advocate including IV contrast enhanced breath-hold T1-weighted fat-suppressed 2D FLASH (fast low angle shot) sequences^[11].

There are some suggestions that MRI may be able to assist in the differentiation of benign from malignant disease. A study of 45 patients has suggested that hypointensity on long TR sequences is a sign of benignity^[12]. A further study of 34 patients has reported that focal thickening and enhancement of interlobar fissures is more suggestive of malignancy than benignity^[11]. These authors also found that enhancement of interlobar fissures, and invasion of the diaphragm, soft tissues of the mediastinum and chest wall was more indicative of MPM than metastatic pleural disease.

An early comparative study of CT (using conventional scanners) and MRI showed no significant differences in the accuracy of these two modalities with respect to predicting resectability of the diaphragm, chest wall, and mediastinum, with sensitivities of greater than 90% for both CT and MRI. Noticeably, specificities for both modalities were less than 50%^[9].

A subsequent prospective study has confirmed similar staging accuracies between CT and MRI, with T-stage accuracies in the range 50–60% for CT and MRI, and nodal (N1 or N2) stage disease of less than 50%^[10]. Noticeably, however, MR was significantly more accurate than CT in two areas: diaphragmatic invasion (82% vs. 55%, $P = 0.01$) and invasion of lung parenchyma (69% vs. 46%, $P = 0.05$). Comparative studies utilizing more modern multidetector CT scanners are awaited.

Positron emission tomography

The increased metabolic activity of MPM, as with other malignancies, is reflected in increased ^{18}F -FDG activity, which can be detected by both positron emission tomography (PET) and dual-headed gamma-camera coincidence scanners. In one study of 18 surgical candidates with MPM, PET showed increased activity in all subjects^[13]. It identified extrathoracic disease in two patients. It was also more accurate than CT in identifying mediastinal nodal disease, correctly identifying involvement in four out of four patients, while CT only identified nodal enlargement in two of these patients. Furthermore, CT demonstrated enlarged, but benign, nodes in two other cases. PET, however, can generate false-positive (e.g. inflammatory lesions) and false-negative results (e.g. small lesions). A study of 28 patients has suggested that standardized uptake value (SUV) levels may have some prognostic significance.

PET may have a role in assisting in differentiating MPM from other benign processes. A small study of 18 patients has a suggested sensitivity of 92%, specificity of 75% and accuracy of 89% for detecting MPM^[14]. However, it is unlikely to be able to differentiate between the malignancies, e.g. metastatic pleural disease.

Percutaneous image-guided biopsy

Cytologic examination and fine-needle biopsies are extremely unreliable in the diagnosis of MPM because of the difficulties in pathological diagnosis discussed above. As a result, some surgeons advocate open or thoroscopic biopsy. Such invasiveness is perhaps unnecessary, since the reported sensitivities and specificities of CT-guided biopsies, utilizing 14 or 18-gauge needles, is 86 and 100%, respectively, albeit in a small series of only 21 cases of MPM. In this study, biopsies were reportedly achievable from pleural thicknesses of less than 5 mm^[15]. Imaging guidance can also be obtained with ultrasound. The risks of percutaneous tract seeding have been suggested at 22%, but are probably overstated. Nevertheless, prophylactic radiotherapy to the site of biopsy is generally offered.

Imaging in follow-up

Following an EPP, the pneumonectomy space fills with fluid more rapidly than following a standard pneumonectomy (several days, rather than weeks, following surgery). The mediastinum usually remains midline, typically becoming fixed in position within 7–10 days; contralateral shift may occur if fluid accumulation is rapid^[16]. An early post-operative CT typically shows a thin soft-tissue rind surrounding the hemithorax. Recurrent disease on thoracic CT typically appears as pleural thickening or a mass, and mediastinal or hilar adenopathy.

Following pneumonectomy, recurrences may be local, but are more commonly distant^[3,4].

There is debate about the appropriate interval and modality for follow-up. Some argue that routine radiographs are adequate for follow-up, with CT reserved for new symptoms or radiographic findings (e.g. new air-fluid level, mediastinal shift, or pulmonary nodules in the contralateral lung), because it is argued, treatment options for recurrent disease are limited. Others argue that the poorer sensitivity of radiographs in relation to CT do not allow adequate evaluation of disease status and therapy, and advocate CT every 3 months^[5].

There is probably no role for MRI in follow-up. The role of PET in post-treatment follow-up is undefined; one potential advantage is its ability to evaluate for local recurrence and metastatic disease in one study.

Challenges in imaging

The limitations of CT and MRI in pre-operative staging have been illustrated in a number of clinical series. In one study of 131 patients, considered to be operable following CT, 24% were found to be technically unresectable (i.e. T4 disease), and 35% had mediastinal nodal involvement^[3]. In another study of 32 patients considered operable following *both* CT and MRI, 16 patients were under staged (nine had N2, and seven had T4 disease); the authors concluded 'pre-operative staging based on CT/MR looks rather inaccurate'^[17].

There are several contributing factors. As is borne out in previous sections, the evaluation of mediastinal and hilar nodal status by both CT and MRI is challenging. This is in part because nodal size, as in other tumours, is not a reliable determinant of disease status: small nodes may contain metastatic disease, and large nodes may simply be reactive. In addition, in MPM the primary pleural tumour generally spreads in a confluent, sheet-like manner, and in the hilar and mediastinal regions can become inseparable from adjacent nodes; a hilar mass may represent adenopathy or the pleural tumour itself.

Tumour seedlings, either in the pleura or peritoneum, are impossible to detect by any current imaging modality. The differentiation of T1a (limited parietal disease) and T1b (parietal and visceral disease) also currently cannot be made radiologically.

These limitations have led some clinicians to advocate that pre-operative evaluation should include thoracoscopy, bronchoscopy with transbronchial biopsy, mediastinoscopy, and/or laparoscopy^[7,17].

Summary and future perspectives

Imaging can be invaluable in first suggesting the diagnosis of MPM. However, unfortunately, there are

no pathognomonic plain film or cross-sectional imaging findings, and it is generally not possible to distinguish MPM from metastatic pleural disease nor, at times, from benign pleural disease. Equally, pathological diagnosis can also be challenging.

CT is the mainstay of staging, but it probably underestimates early chest wall and diaphragmatic invasion. The multiplanar capability of MRI is superior in these areas, and should probably be offered to patients being considered for surgery. However, both have limitations in local staging. The capabilities of thin-section, multidetector CT together with the possibilities for high-quality multiplanar reformation have yet to be explored.

The scope and extent of initial staging work-up and follow-up, especially with respect to distant disease, is undefined and deserves further evaluation, particularly given the increasing recognition of the prevalence of distant disease. Unreliable staging is not only detrimental to surgical candidates, but it inevitably confounds the accuracy of treatment stratification and evaluations.

Preliminary studies suggest that FDG-PET may be useful in assessing both local and distant disease at staging, and potentially also in follow-up. It may also be useful in distinguishing benign from malignant disease, and may have some prognostic value.

The utility of PET-CT scanners has yet to be determined; it holds the promise of combining the high morphological detail provided by CT and the metabolic information derived from FDG.

The above challenges in imaging are matched by controversies in therapy. The main handicap has been the lack of clinical trials, due largely to the comparative rarity of the disease and the rapidity of its progression. Given the expected continuing rise in incidence of MPM in the coming decades, it would seem vital that all parties combine forces in a collaborative multidisciplinary and multicentre effort to determine efficacious staging, treatment and follow-up protocols.

References

- [1] Robinson BWS, Chahinian AP. Mesothelioma, London: Martin Dunitz, 2002.
- [2] Peto J, Decarli A, La Vecchia C, Levi F, Negri E. The European mesothelioma epidemic. *Br J Cancer* 1999; 79: 666.
- [3] Rusch VW, Venkatraman E. The importance of surgical staging in the treatment of malignant pleural mesothelioma. *J Thorac Cardiovasc Surg* 1996; 111: 815.
- [4] Miller BH, Rosado-de-Christenson ML, Mason AC *et al*. From the archives of the AFIP. Malignant pleural mesothelioma: radiologic-pathologic correlation. *Radiographics* 1996; 16: 613.
- [5] Lee YC, Light RW, Musk AW. Management of malignant pleural mesothelioma: a critical review. *Curr Opin Pulm Med* 2000; 6: 267.
- [6] Churg A, Colby TV, Cagle P *et al*. The separation of benign and malignant mesothelial proliferations. *Am J Surg Pathol* 2000; 24: 1183.
- [7] Sugarbaker DJ, Garcia JP, Richards WG *et al*. Extrapleural pneumonectomy in the multimodality therapy of malignant pleural mesothelioma. Results in 120 consecutive patients. *Ann Surg* 1996; 224: 288.
- [8] Desai S, Hansell DM. Pleural tumours. In: *Imaging in oncology*, Husband JE, Reznick RH, eds. Oxford: Isis Medical Media, 1998: p. 79.
- [9] Patz EF Jr, Shaffer K, Pivnicka-Worms DR *et al*. Malignant pleural mesothelioma: value of CT and MR imaging in predicting resectability. *AJR Am J Roentgenol* 1992; 159: 961.
- [10] Heelan RT, Rusch VW, Begg CB *et al*. Staging of malignant pleural mesothelioma: comparison of CT and MR imaging. *AJR Am J Roentgenol* 1999; 172: 1039.
- [11] Knuutila A, Kivisaari L, Kivisaari A *et al*. Evaluation of pleural disease using MR and CT. With special reference to malignant pleural mesothelioma. *Acta Radiol* 2001; 42: 502.
- [12] Falaschi F, Battolla L, Mascalchi M *et al*. Usefulness of MR signal intensity in distinguishing benign from malignant pleural disease. *AJR Am J Roentgenol* 1996; 166: 963.
- [13] Schneider DB, Clary-Macy C, Challa S *et al*. Positron emission tomography with f18-fluorodeoxyglucose in the staging and preoperative evaluation of malignant pleural mesothelioma. *J Thorac Cardiovasc Surg* 2000; 120: 128.
- [14] Benard F, Sterman D, Smith RJ *et al*. Metabolic imaging of malignant pleural mesothelioma with fluorodeoxyglucose positron emission tomography. *Chest* 1998; 114: 713.
- [15] Adams RF, Gray W, Davies RJ, Gleeson FV. Percutaneous image-guided cutting needle biopsy of the pleura in the diagnosis of malignant mesothelioma. *Chest* 2001; 120: 1798.
- [16] Marom EM, Erasmus JJ, Pass HI, Patz EF Jr. The role of imaging in malignant pleural mesothelioma. *Semin Oncol* 2002; 29: 26.
- [17] Maggi G, Casadio C, Cianci R, Rena O, Ruffini E. Trimodality management of malignant pleural mesothelioma. *Eur J Cardiothorac Surg* 2001; 19: 346.