



Management of recurrent sebaceous gland carcinoma

Lindsay A. McGrath¹  · Zanna I. Currie¹ · Hardeep Singh Mudhar² · Jennifer H. Y. Tan¹ · Sachin M. Salvi¹

Received: 14 August 2019 / Revised: 12 November 2019 / Accepted: 28 November 2019 / Published online: 2 January 2020

© The Author(s), under exclusive licence to The Royal College of Ophthalmologists 2020

Abstract

Objective To evaluate the incidence and management of recurrent periocular sebaceous gland carcinoma at a tertiary ocular oncology service in the United Kingdom.

Methods This was a retrospective cohort study of 62 patients with sebaceous gland carcinoma treated between 2004 and 2017. A total of 10 eyes were treated for local recurrence. The following variables were recorded: age and sex of patient; tumour location, histological subtype; recurrence type; treatment and outcome.

Results Of the 62 cases with eyelid SGC, 10 (16%) had recurrences during the study period and satisfied inclusion criteria. There were six (60%) females and four males in the recurrent group. The mean time interval between initial excision and tumour recurrence was 37 months (median 23 months; range 4 to 84 months). Four patients received cryotherapy to the lids and conjunctiva to control recurrent disease and two patients were treated with topical or intralesional chemotherapy. Four patients (40%) underwent orbital exenteration during the study period. Metastasis occurred in 20% over a mean follow-up of 113 months (median 106; range 47–184 months).

Conclusions The risk factors for local recurrence of SGC after wide excision with paraffin section control were reported, and an approach to these recurrent lesions was proposed. The results of this study will help guide surgeons dealing with the medical and surgical conundrum of recurrent disease. The risk of recurrence is highest in the first 2 years after initial excision.

Introduction

Sebaceous gland carcinoma (SGC) of the ocular adnexa most frequently arises in the sebaceous glands of the eyelids, with a predilection for the upper. It can present as either in situ or invasive disease. In the in situ form, SGC is often pagetoid in distribution, covering a diffuse area and causing ocular surface irritation, but does not metastasise. Invasive SGC on the other hand is a malignant neoplasm, which is locally invasive in the eyelid and conjunctiva, and can metastasise to regional lymph nodes and distant organs [1]. Invasive SGC can be localised to a well-defined area or can undergo pagetoid spread through the conjunctival

epithelium. Putterman was the first to describe mapping biopsies to determine the extent of involvement, in 1986 [2]. The rate of pagetoid spread has been reported between 8 and 44% [3–6].

Although both the clinical and pathologic diagnostic difficulties associated with SGC have been well described in the literature, the therapeutic challenges posed by local recurrence remain to be resolved. Wide surgical excision remains the gold standard in the treatment of localised disease, but despite advances in adjuvant therapies, rates of local recurrence in SGC remains considerably higher than other types of eyelid carcinoma (up to 25%) [1, 4, 7, 8]. Further, the mortality rate is reported to be as high as 10% in recent publications [5, 9, 10]. This is likely to be due to the late diagnosis of this clinical masquerade, and no formal algorithms for treatment of recurrences and metastases.

As a national referral centre for ocular oncology in the United Kingdom, we have unique experiences in the management of recurrent SGC. Given the aggressive nature of some treatment options in this disease, management depends on tumour location, extent and systemic status of the patient. We report herein our outcomes in the

✉ Lindsay A. McGrath
lindsay.mcg@gmail.com

¹ Sheffield Ocular Oncology Service, Royal Hallamshire Hospital, Sheffield S10 2JF, UK

² National Specialist Ophthalmic Pathology Service (NSOPS), Histopathology Department, Royal Hallamshire Hospital, Sheffield S10 2JF, UK

management of recurrent SGC and propose a graded protocol to managing these entities.

Methods

This was a retrospective case review study, performed in accordance with the Declaration of Helsinki. The case notes and histopathology reports from a consecutive series of patients with primary periocular SGC diagnosed between January 2004 and December 2017 at the Royal Hallamshire Hospital, Sheffield were assessed. Electronic and paper medical records were searched for the diagnosis of SGC confirmed by histopathological examination in all cases. The medical records were reviewed for demographic and clinical data. Histology reports and slides were reviewed by an ophthalmic pathologist (HSM). All tumours were histopathologically staged using the Union for International Cancer Control staging system, 8th Edition [11]. Inclusion criteria were a diagnosis of SGC with confirmed recurrence during the study period. Exclusion criteria were patients who had initial or subsequent management at different centres and those lost to follow-up.

Management of primary SGC

At surgery, clinically clear margins were marked around eyelid tumours by noting transition in surface contour, colour and texture. Margins of 4 mm were marked under tension. Local anaesthesia was obtained with a subcutaneous injection of 0.5% bupivacaine with adrenaline 1 in 200000. Our technique of full thickness excision with delayed reconstruction has been previously described [12]. As well as primary lesions, 8–10 conjunctival mapping biopsies were also taken from all quadrants of bulbar and tarsal conjunctiva and sent separately on microsponge pieces, in formalin with a diagram (see Fig. 1 for representative image).

All histology specimens were fixed in standard 10% buffered formalin. Tissue was processed to wax, 4 micron sections cut and stained with haematoxylin and eosin. Cases requiring immunohistochemistry were exposed to the following antibody panel: androgen receptor (Cell Marque rabbit monoclonal EP120, diluted 1:200. Retrieval method: HIER using Leica Bond Epitope Retrieval solution 2 (high pH, Leica, AR9640) for 30 min)) and adipophylin (Cell Marque rabbit polyclonal antibody CM2158, diluted 1:100. Retrieval method: HIER using Ventana CC1 for 52 min).

Follow-up and surveillance

All patients including those with in situ or invasive SGC were followed up at 2, 12 and 26 weeks after surgery, then

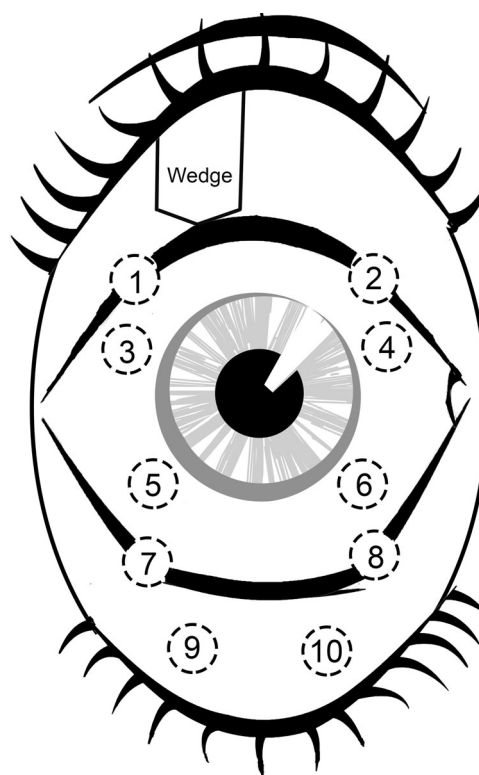


Fig. 1 Conjunctival map biopsy specimen locations. Upper eyelid wedge resection. (1 and 2): Corresponding forniceal map biopsies; (3–6): Bulbar conjunctival biopsies in four quadrants; (7 and 8): Inferior forniceal map biopsies; (9 and 10): Inferior palpebral conjunctival biopsies. Plica and caruncle rarely biopsied unless suspicious appearance.

at 6 monthly intervals for 5 years and yearly thereafter for at least 10 years. At every clinic visit meticulous slit lamp examination with eyelid eversion was performed to check for local recurrence or surgical complications. Any new area of loss of lashes, blunting of eyelid margin, thickening of eyelid margin, dilation of meibomian orifices or chalazion formation was thought to be suspicious. The bulbar conjunctiva and cornea were examined for pagetoid changes. The lacrimal gland orifices as well as upper and lower canaliculi were examined for any abnormality. The tear film was checked, and orbital rim was palpated for any mass.

Clinical examination for preauricular and submandibular lymphadenopathy was performed, and testing of V1 and V2 divisions of trigeminal nerves was checked to assess for perineural invasion. Patients were advised to report any change such as progressive redness or swelling of the eyelid, or increasing pain and dryness of the eye.

At diagnosis, patients with invasive disease underwent systemic staging with baseline magnetic resonance imaging (MRI) of the head and neck to ensure no orbital invasion or lymph node metastasis. At follow-up, patients with high-risk invasive disease (tumour diameter more than 10 mm or extensive pagetoid disease involving both upper and lower

eyelids) [3, 9, 13] also underwent 6 monthly neck imaging (usually alternating neck MRI and ultrasound scans) for 5 years, and then yearly for 5 years as surveillance. Patients with clinical or radiological evidence of lymph node disease were discussed at our Head and Neck multidisciplinary team meeting, and underwent lymph node biopsy. Those with positive lymph nodes were recommended for radical neck dissection surgery. If lymph node metastasis was detected, whole body screening with Computerised Tomography (CT) chest abdomen pelvis or Positron Emission Tomography (PET) CT scan was carried out for staging and to rule out distant spread and the patient was referred to a medical oncologist.

Management of recurrent SGC

A low threshold to perform incisional full thickness wedge biopsy and repeat conjunctival mapping biopsies was maintained if there was any suspicion of recurrence at follow-up. Double freeze-thaw cryotherapy (-65 °C) was also applied to all suspicious areas at the time of biopsy. The cryoprobe was applied to tissue until an iceball formed (usually 3–5 s). The freezing was then ceased, and the ball was allowed to defrost at room temperature. This was repeated across all suspicious areas.

The results of the biopsies were discussed at our ocular oncology multidisciplinary team meeting and the patient treated with our departmental treatment algorithm

depending on the extent of involvement and recurrence type (Fig. 2).

Patients with pagetoid disease were re-mapped 4 months after treatment to identify success of treatment and a different modality of treatment considered if disease was still active.

Results

Of the 62 cases with eyelid SGC diagnosed between January 2004 to December 2017, 11 had biopsy proven recurrence of SGC at last follow-up in August 2018. Of these 11 cases, 10 (16%) were included in our study based on our inclusion criteria. One patient was excluded due to multiple treatments performed at a different centre. All patients were Caucasian and one patient had Muir-Torre syndrome. Patient demographics are summarised in Table 1.

The mean age at presentation of eyelid SGC was 68 years (median 68 years; range 49–91 years) and the mean age of recurrence was 71 years (median 72 years; range 55 to 92 years). There were 6 (60%) females and 4 males in the recurrent group. The most common presenting symptom was appearance of an eyelid mass ($n = 5$) or irritation ($n = 5$). The tumour was located on the upper eyelid in 6 cases, the lower eyelid in 2 cases and was localised to the bulbar conjunctiva in 3. There were associated signs of eyelid margin thickening ($n = 5$), palpable nodule ($n = 4$) and

Fig. 2 Proposed treatment flowchart for recurrent SGC.

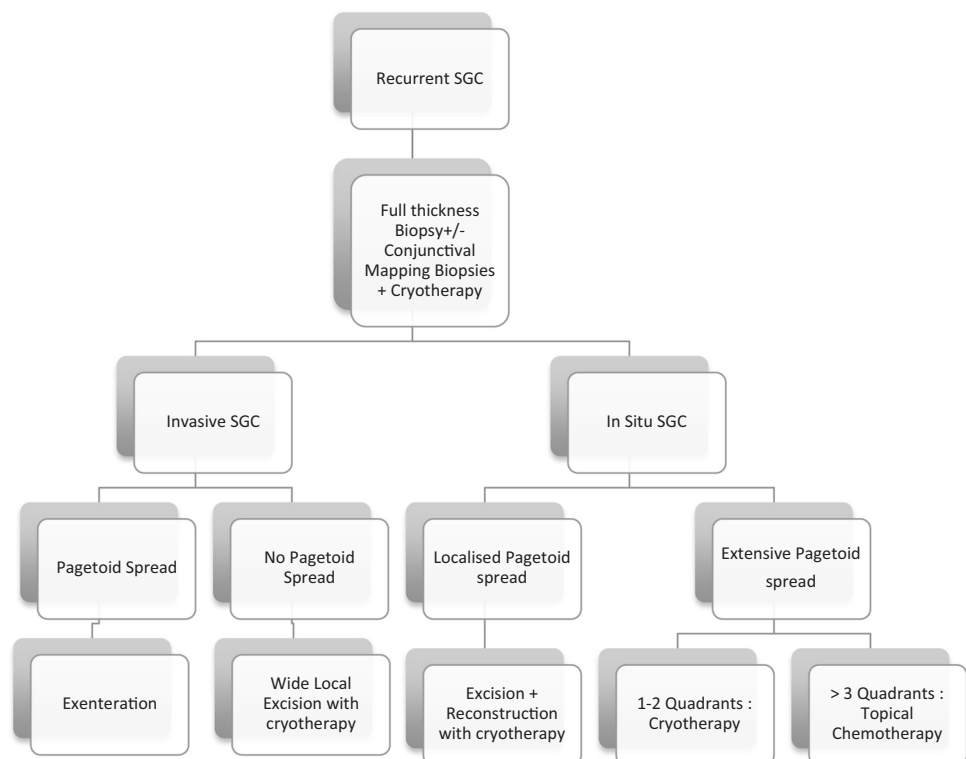
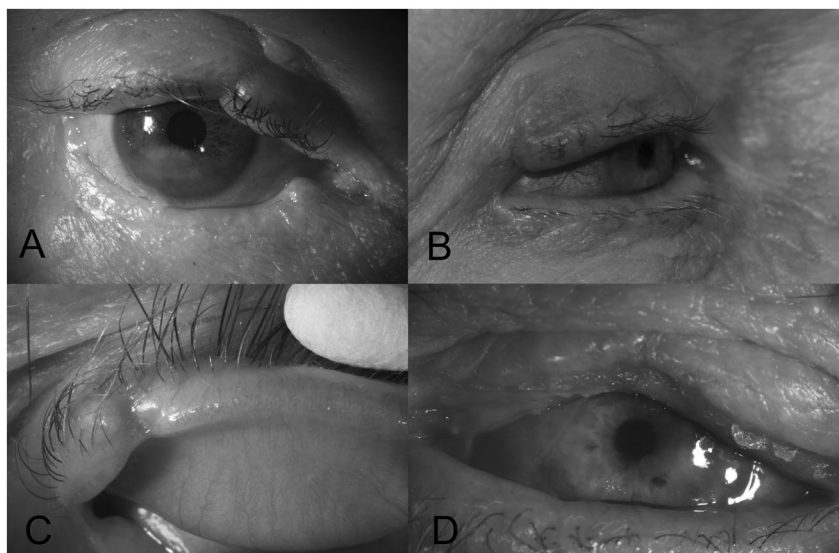


Table 1 Recurrent sebaceous gland carcinoma in 15 patients.

Patient	Age (years)/ Gender	Tumour location	TNM staging	Time to recurrence (months)	Intervention	Further recurrence	Lid /orbital outcome	Metastases (months)	Final outcome	Follow-up (months)
1	56/M	Lower lid	pT _{is}	22	Cryotherapy	Yes	Notched Lid	Yes (59)	Alive	168
2	81/F	Upper lid	pT _{is}	24	IFN2a	Yes	Notched Lid	No	Alive	106
3	63/F	Upper lid	pT _{is}	84	Excision	No	Exenteration	No	Alive	192
4	75/F	Upper lid	Not possible	23	Excision	No	Notched Lid	No	Alive	167
5	91/M	Upper lid	pT _{1b}	20	Cryotherapy	Yes	Exenteration	No	Dead	47
6	49/M	Upper lid	pT _{4a}	78	Exenteration	No	Exenteration	No	Alive	91
7	75/F	Lower lid	pT _{1b}	14	Cryotherapy +IFN2a	Yes	Exenteration	Yes (42)	Dead	51
8	55/M	Upper lid	pT _{is}	75	Cryotherapy	Yes	Entropion	No	Alive	107
9	68/F	Bulbar conj	pT _{1a}	14	Cryotherapy	No	Entropion	No	Alive	149
10	67/F	Bulbar conj	pT _{is}	14	IFN2a	Yes	–	No	Alive	34

Fig. 3 Recurrent SGC. **a** Medial upper eyelid recurrence at site of previous wedge excision; **b** Thickening and erythema representing recurrence at lateral upper lid margin; **c** New eyelid margin nodule lateral to previous wedge excision site; **d** diffuse madarosis and upper eyelid margin ulceration.



adjacent tarsal or bulbar conjunctival involvement ($n = 1$) (Fig. 3). The mean time interval between initial excision and tumour recurrence was 37 months (median 22 months; range 14 to 84 months). Tumour ‘recurrences’ within 12 months of initial treatment were considered treatment failures. This occurred in five cases.

All ten cases of recurrent SGC were confirmed histologically at presentation (Table 2). Most of the tumours were in situ sebaceous carcinomas (56%). There was no significant trend for a particular growth pattern or gland of origin. The invasive tumour differentiation was predominantly poor.

At initial presentation, one case was unable to be staged (Table 1). Of the remaining 9, 5 were in situ (pT_{is}). There was one case staged as pT_{1a}, two cases pT_{1b} and a single case of pT_{4a}. The case of pT_{4a} did not develop metastases, and they remained well at final follow-up of 47 months.

Metastatic disease was diagnosed in two patients—one initially diagnosed with in situ SGC. The patient developed invasive recurrent disease, and metastasis at 59 months. The patient remained well at final follow-up of 168 months.

Four patients with localised involved area of the eyelids and conjunctiva (1–2 quadrants) received triple freeze-thaw cryotherapy to control recurrent disease. Two patients with diffuse pagetoid spread (≥ 3 quadrants) had intralesional or topical Interferon alpha-2a (IFN2a).

Five of the ten patients had further rerecurrence and multiple treatments. Four patients underwent orbital exenteration during the study period, due to inadequate disease control, invasive SGC with extensive non resectable pagetoid spread, pagetoid in situ SGC causing a painful blind eye due to limbal stem cell failure or cosmetically embarrassing red inflamed eye. External beam radiotherapy to the orbit was performed in one case after exenteration. Two of

Table 2 Histological findings from ten recurrent SGCs.

Feature	Number of patients (%)
Type	
In-situ	5 (56)
Invasive	4 (44)
Tumour differentiation (Invasive, <i>n</i> = 4)	
Well	1 (25)
Poorly	3 (75)
Gland of origin (Invasive and in situ)	
Meibomian	1 (10)
Zeis	1 (10)
Uncertain	8 (80)

the ten patients developed metastases. Two patients passed away during the study period, one with evidence of metastases and one death was not tumour related. The overall mean follow-up was 113 months (median 106; range 47–184 months).

Discussion

SGC is an uncommon malignancy that occurs most commonly in the periocular region. The referral diagnosis is incorrect in ~50% of cases, and thus tumours can have quite extensive local invasion at time of diagnosis [10]. It is estimated that 41–80% of SGC have associated pagetoid spread [14]. Contemporary studies report local tumour recurrence in 12–25% of patients [1, 5, 10, 12, 15].

In our cohort of recurrent cases, 56% were in situ (with a pagetoid pattern of spread) at initial excision, whereas 44% had evidence of invasion. The demographics of SGC in previous reports were mirrored in our study of recurrent tumours, with a prevalence in females (60%) and an average age at recurrence of 68 years [10].

The recurrence rate in the current study was 16% (10/62 patients). This is in keeping with the upper limits recorded in previous studies. This may be due to the close follow-up and low threshold of mapping biopsies done at our unit allowing early pick up of recurrence, as well as the more complex patient cohort seen at our tertiary referral centre. This recurrence rate may reflect the incidence of diffuse pagetoid in situ SGC seen in our cohort (30%)—and compares well to a recent study by Zhou and coworkers, who report a recurrence rate of 44.1% with Mohs micrographic surgery when pagetoid spread is present [16]. A recent study validating the 8th Edition of the American Joint Cancer Classification found significantly longer time to local recurrence for T1/T2 tumours than T3/T4 disease ($p = 0.01$) [9]. Although not a criterion for determining

tumour category in staging, pagetoid spread has been shown to be significantly associated with recurrence [9, 10].

Previously reported prognostic risk factors include a prolonged interval from symptom appearance to the correct diagnosis, tumour location [17], tumour origin [3, 10], the staging T category (as defined by the AJCC) [8–10], tumour size [7, 17–19], pagetoid spread [10], tumour differentiation [3, 7] and tumour growth pattern [6, 9, 15, 18]. In the largest population study to date evaluating prognostic factors for sebaceous carcinoma, Lee and Koh reported older age and tumour size greater than 20 mm are independently correlated with decreased overall survival [19]. Even in the absence of significant risk factors listed herein, scheduled map biopsies at the time of wide excision with paraffin section control are recommended to improve the reliability of complete excision [18, 20].

In cases where there is histological uncertainty about whether the case is in situ squamous or sebaceous carcinoma (particularly when cytoplasmic microvacuolation is not well developed), a select panel that includes androgen receptor and adipophyllin is useful to secure a diagnosis [21–23].

Although it has been reported that tumours arising from Zeiss glands have less tendency to recur [1, 3], we did not see a difference between the number of cases arising from Meibomian or Zeiss gland in our series of recurrent tumours. This is likely due to the small number of cases in this series and the focus on recurrent tumours only. Lobular growth patterns are also seen most commonly in SGC [1, 10]. Our series reported no significant prevalence of a particular growth pattern in recurrent SGC.

Mitomycin C was first shown to be an effective treatment for pagetoid invasion of the conjunctiva by SGC by Shields et al. [24]. They recommended delay of treatment until all surgical wounds were healed, due to the risk of wound breakdown, iridocyclitis and scleral necrosis. They also noted that this therapy was inadequate for nodular SGC with tumour deep to the epithelium [24]. Further case series' have confirmed the utility of this alkylating agent in the management of pagetoid spread, and as adjuvant therapy in the presence of adverse prognostic features [25, 26]. Interferon alpha-2a is widely used in the management of topical squamous neoplasia of the conjunctiva by inducing apoptosis and its antiproliferative and immunomodulatory effects. To our knowledge, there are no studies reporting its use in pagetoid SGC. We used this medication both topically and intra-lesionally in some patients when MMC was not tolerated, if MMC was used previously and there was risk of limbal stem cell failure, or in a patient who declined further surgery. IFN2a is widely used in adjuvant and prophylactic therapy models for other skin malignancies, and has been shown to reduce development of new SGC in Muir-Torre syndrome in a case study [27]. In our series,

IFN2a was well tolerated and was effective in regressing recurrent SGC.

While wide excision with margin control is well accepted for the management of SGC, further adjuvant therapy is highly recommended for patients who have risk factors for local recurrence [9, 12]. Recent studies have shown that pagetoid intraepithelial neoplasia limits the beneficial effect of Mohs micrographic surgery in recurrence control [16]. Complication rates of conjunctival map biopsies are negligible, although there is significant variation in map biopsy techniques (number, location and size of biopsy specimens) reported in the literature [8, 10, 20]. A recent review of the literature and their own clinical practice by Sa et al. concluded that routine non-targeted conjunctival map biopsies may not be necessary in all cases, particularly when there is no clinical suspicion of pagetoid spread [8]. The authors advocated targeted map biopsies in suspicious areas and careful evaluation of the main surgical specimen for evidence of pagetoid spread [8]. We routinely perform map biopsies, and suggest 8–10 map biopsies at initial excision (Fig. 1). This is particularly recommended for practitioners not experienced in the clinical detection of pagetoid spread (injection, thickening, corneal neovascularisation).

Simultaneous cryosurgery may be effective for removing residual pagetoid involvement after excision [8, 17, 18, 28]. There continues to be a paucity of survival data regarding this therapy, however, it appears effective in the control of pagetoid spread outside of excision margins. Lisman et al. were the first to demonstrate the utility of cryotherapy as an adjuvant in SGC [29]. They comment that if the entire conjunctival sac is affected by pagetoid spread, cryotherapy will not be curative because healing from staged procedures will recruit adjacent epithelium that is already involved with sebaceous carcinoma cells [29]. Side effects include dry eye symptoms, symblepharon and corneal vascularisation in those undergoing more than 2 quadrants of therapy [29].

Patients with invasive SGC who develop orbital invasion, multifocal tumour or extensive pagetoid spread may need orbital exenteration [15]. Patients with in situ SGC can be managed with local treatment measures alone and exenteration surgery can be delayed until a time when conversion to invasive disease is suspected or patient wish surgery for a painful or inflamed eye. Exenteration rates in our institution have reduced over time due to employment of large resections and reconstruction with auto- or amniotic membrane grafts. These more conservative approaches are usually in elderly patients unwilling to undergo complex and disfiguring surgery.

Conjunctival epithelium does not contain blood vessels or lymphatics, which are found within the substantia propria (beneath the epithelium) [29]. In-situ lesions, by definition have not invaded through the epithelial basement membrane, and thus do not metastasise. Even pagetoid spread of in situ

SGC does not tend to metastasise for this reason, however cases of invasive SGC must be screened for potential metastasis to submandibular or parotid lymph nodes. The rate of metastasis of primary SGC ranges from 8 to 21% in contemporary studies [1, 9, 15, 18]. Lam et al. found a potential association of stage T2b and greater to have metastases, and a poorer survival with tumours T3b and greater [15]. Such a trend was not noted in this study, likely due to early stage tumours at diagnosis, and small sample size, however our overall rate of metastasis of 20% for recurrent tumours suggests that there is little increased risk in this cohort compared to the rates seen in primary SGC.

In general, surgical excision is preferable for the definitive management of SGC, and the use of irradiation as a primary treatment modality remains controversial. Some authors have shown good results with irradiation, and advocate it as an alternative to orbital exenteration in older or debilitated patients and for selected cases of recurrence after exenteration [20, 28, 30]. In the past, SGCs were thought to be radioresistant, however Hata et al. postulated that conventional doses may be insufficient to control the gross tumour, and they showed in a small series that a dose of 60 Gy or greater in conventional fractions was required to eradicate disease [30]. Neoadjuvant chemotherapy for eyelid SGC has recently been shown to have promise in eyelid and globe preservation by significant tumour volume reduction [31, 32].

A recent study by Cheung et al. reporting the practice patterns of the management of sebaceous carcinoma in the Asia Pacific region found that the majority of surgeons prefer surgical excision with adjuvant treatment for recurrent disease (48%) [33]. This was followed in popularity by exenteration combined with radiotherapy (23%), and exenteration alone (10%). Most did not use any neoadjuvant therapy for globe preserving surgical excision in advanced cases, but those who did, preferred mitomycin C (21%) [33]. Our proposed management algorithm for recurrent SGC (Fig. 2) details globe preserving therapy in all cases, except invasive SGC with pagetoid spread, which can be very difficult to manage with cryo- or chemotherapy. We advocate the use of these adjuvant therapies in the first instance of biopsy confirmed recurrent in situ SGC and invasive SGC without pagetoid spread.

The mean interval between treatment and recurrence was 37 months. Other authors have found that the majority of recurrences occur within the first 2 years after initial diagnosis [9]. Given this information, we recommend close surveillance (every 3–4 months) for the first 2 years after diagnosis, with a potential to increase time between visits after a disease-free interval of 2 years. Patients should be followed up for 5 to 10 years to ensure no local recurrence.

There was regional lymph node involvement detected in 20% of our patients with recurrent SCC. We therefore

recommend patients with recurrent invasive SGC should have 6 monthly neck imaging, similar to patients with other clinical high risk factors (tumour diameter more than 10 mm or extensive pagetoid disease involving both upper and lower eyelids). Recent recommendations from Sa et al. encourage surgeons to perform testing for regional nodal and systemic metastases in patients with eyelid sebaceous carcinoma with T2c or worse category and/or N1 disease at presentation [9].

This study had several limitations. The retrospective design including only a small number of patients may limit the validity of the results. Our ocular oncology service is a tertiary care centre experienced in treating this rare disease, and thus the patient population may be atypical compared to other centres. Interestingly, all patients were Caucasian, despite this disease known to occur more commonly in Asian populations. The application of our results may be limited, given some clinicopathologic findings of SGC are influenced by racial differences [34]. Further prospective studies should be carried out to assess the proposed management paradigm for recurrent SGC.

To the best of our knowledge, this is the first series of eyelid SGC focusing on the management of recurrent tumours. Our findings have led to the development of recommendations for surgeons both clinically and regarding surveillance (Fig. 2). Patients should be counselled that there is up to a 1:5 risk of recurrence at time of initial diagnosis and should be followed closely for the first 2 years after initial diagnosis, with a low threshold for re-biopsy and adjuvant therapy if required. Recurrent SGC can be successfully managed with globe preserving local treatment options and exenteration surgery considered only in severe cases of in situ or invasive SGC. We recommend use of our biopsy and treatment protocol in patients with SGC. Recurrence of SGC does not appear to harbour an increased risk of metastasis.

Summary

What was known before

- SGC of the eyelid is a malignant neoplasm which frequently recurs.
- Recurrent SGC can be treated with surgery or medical therapy.

What this study adds

- Recurrent SGC of the eyelid is difficult to treat, and it is important to consider the histological features of the disease when deciding on treatment regime.

- There is up to 20% risk of recurrence, with most occurring in the first 2 years after initial treatment.

Compliance with ethical standards

Conflict of interest The authors declare that they have no conflict of interest.

Publisher's note Springer Nature remains neutral with regard to jurisdictional claims in published maps and institutional affiliations.

References

1. Shields JA, Demirci H, Marr BP, Eagle RC, Shields CL. Sebaceous carcinoma of the eyelids: personal experience with 60 cases. *Ophthalmology*. 2004;111:2151–7. <https://doi.org/10.1016/j.ophtha.2004.07.031>.
2. Putterman AM. Conjunctival map biopsy to determine pagetoid spread. *Am J Ophthalmol*. 1986;102:87–90.
3. Rao NA, Hidayat AA, McLean IW, et al. Sebaceous carcinomas of the ocular adnexa: a clinicopathologic study of 104 cases, with five-year follow-up data. *Hum Pathol*. 1982;13:113–22.
4. Song A, Carter KD, Syed NA, et al. Sebaceous cell carcinoma of the ocular adnexa: clinical presentations, histopathology, and outcomes. *Ophthalmic Plast Reconstr Surg*. 2008;24:194–200. <https://doi.org/10.1097/IOP.0b013e31816d925f>.
5. Yoon JS, Kim SH, Lee CS, et al. Clinicopathological analysis of periorcular sebaceous gland carcinoma. *Ophthalmologica*. 2007;221:331–9. 10.1159/000104764 [published Online First: 2007/08/31]
6. Zurcher M, Hintschich CR, Garner A, et al. Sebaceous carcinoma of the eyelid: a clinicopathological study. *Br J Ophthalmol*. 1998;82:1049–55.
7. Muqit MM, Roberts F, Lee WR, et al. Improved survival rates in sebaceous carcinoma of the eyelid. *Eye*. 2004;18:49–53. <https://doi.org/10.1038/sj.eye.6700523>.
8. Sa HS, Tetzlaff MT, Esmaeli B. Predictors of local recurrence for eyelid sebaceous carcinoma: questionable value of routine conjunctival map biopsies for detection of pagetoid spread. *Ophthalmic Plast Reconstr Surg*. 2019. <https://doi.org/10.1097/IOP.0000000000001343>.
9. Sa HS, Rubin ML, Xu S, et al. Prognostic factors for local recurrence, metastasis and survival for sebaceous carcinoma of the eyelid: observations in 100 patients. *Br J Ophthalmol*. 2018. <https://doi.org/10.1136/bjophthalmol-2018-312635>.
10. Chao AN, Shields CL, Krema H, et al. Outcome of patients with periorcular sebaceous gland carcinoma with and without conjunctival intraepithelial invasion. *Ophthalmology*. 2001;108:1877–83.
11. *Carcinoma Skin of the Eyelid*. TNM classification of malignant tumours. 8th ed. Wiley-Blackwell; United Kingdom. 2016:136.
12. While B, Salvi S, Currie Z, et al. Excision and delayed reconstruction with paraffin section histopathological analysis for periorcular sebaceous carcinoma. *Ophthalmic Plast Reconstr Surg*. 2014;30:105–9. <https://doi.org/10.1097/IOP.000000000000013>.
13. Esmaeli B, Nasser QJ, Cruz H, et al. American Joint Committee on Cancer T category for eyelid sebaceous carcinoma correlates with nodal metastasis and survival. *Ophthalmology*. 2012;119:1078–82. <https://doi.org/10.1016/j.ophtha.2011.11.006>.
14. Kass LG, Hornblass A. Sebaceous carcinoma of the ocular adnexa. *Surv Ophthalmol*. 1989;33:477–90.
15. Lam SC, Li EYM, Yuen HKL. 14-Year case series of eyelid sebaceous gland carcinoma in Chinese patients and review of

- management. *Br J Ophthalmol*. 2018. <https://doi.org/10.1136/bjophthalmol-2017-311533>.
16. Zhou C, Wu F, Chai P, et al. Mohs micrographic surgery for eyelid sebaceous carcinoma: A multicenter cohort of 360 patients. *J Am Acad Dermatol*. 2019. <https://doi.org/10.1016/j.jaad.2018.12.053>.
 17. Kaliki S, Ayyar A, Dave TV, et al. Sebaceous gland carcinoma of the eyelid: clinicopathological features and outcome in Asian Indians. *Eye*. 2015;29:958–63. <https://doi.org/10.1038/eye.2015.79>.
 18. Takahashi Y, Takahashi E, Nakakura S, et al. risk factors for local recurrence or metastasis of eyelid sebaceous gland carcinoma after wide excision with paraffin section control. *Am J Ophthalmol*. 2016;171:67–74. <https://doi.org/10.1016/j.ajo.2016.08.028>.
 19. Lee IJ, Koh JY. Impact of clinicopathologic factors on survival in patients with sebaceous carcinoma of the eyelid—a population-based analysis. *Orbit*. 2018;1–8. <https://doi.org/10.1080/01676830.2018.1505922>.
 20. Shields JA, Saktanasate J, Lally SE, et al. Sebaceous carcinoma of the ocular region: The 2014 Professor Winifred Mao lecture. *Asia Pac J Ophthalmol*. 2015;4:221–7. <https://doi.org/10.1097/APO.000000000000105>.
 21. Jakobiec FA, Werdich X. Androgen receptor identification in the diagnosis of eyelid sebaceous carcinomas. *Am J Ophthalmol*. 2014;157:687–96 e1-2. <https://doi.org/10.1016/j.ajo.2013.12.009>.
 22. Mulay K, White VA, Shah SJ, et al. Sebaceous carcinoma: clinicopathologic features and diagnostic role of immunohistochemistry (including androgen receptor). *Can J Ophthalmol*. 2014;49:326–32. <https://doi.org/10.1016/j.cjco.2014.04.004> [published Online First: 2014/08/12]
 23. Plaza JA, Mackinnon A, Carrillo L, et al. Role of immunohistochemistry in the diagnosis of sebaceous carcinoma: a clinicopathologic and immunohistochemical study. *Am J Dermatopathol*. 2015;37:809–21. <https://doi.org/10.1097/DAD.0000000000000255> [published Online First: 2015/10/21]
 24. Shields CL, Naseripour M, Shields JA, et al. Topical mitomycin-C for pagetoid invasion of the conjunctiva by eyelid sebaceous gland carcinoma. *Ophthalmology*. 2002;109:2129–33. [published Online First: 2002/11/05]
 25. Rudkin AK, Muecke JS. Mitomycin-C as adjuvant therapy in the treatment of sebaceous gland carcinoma in high-risk locations. *Clin Exp Ophthalmol*. 2009;37:352–6. <https://doi.org/10.1111/j.1442-9071.2009.02048.x> [published Online First: 2009/07/15]
 26. Tumuluri K, Kourt G, Martin P. Mitomycin C in sebaceous gland carcinoma with pagetoid spread. *Br J Ophthalmol*. 2004;88:718–9.
 27. Graefe T, Wollina U, Schulz H, et al. Muir-Torre syndrome—treatment with isotretinoin and interferon alpha-2a can prevent tumour development. *Dermatology*. 2000;200:331–3. <https://doi.org/10.1159/000018399>.
 28. Shields JA, Demirci H, Marr BP, et al. Sebaceous carcinoma of the ocular region: a review. *Surv Ophthalmol*. 2005;50:103–22. <https://doi.org/10.1016/j.survophthal.2004.12.008>.
 29. Lisman RD, Jakobiec FA, Small P. Sebaceous carcinoma of the eyelids. The role of adjunctive cryotherapy in the management of conjunctival pagetoid spread. *Ophthalmology*. 1989;96:1021–6.
 30. Hata M, Koike I, Omura M, et al. Noninvasive and curative radiation therapy for sebaceous carcinoma of the eyelid. *Int J Radiat Oncol Biol Phys*. 2012;82:605–11. <https://doi.org/10.1016/j.ijrobp.2010.12.006>.
 31. Kaliki S, Ayyar A, Nair AG, et al. Neoadjuvant systemic chemotherapy in the management of extensive eyelid sebaceous gland carcinoma: a study of 10 cases. *Ophthal Plast Reconstr Surg*. 2016;32:35–9. <https://doi.org/10.1097/IOP.0000000000000398>.
 32. Lee SH, Jung YH, Yoo JY, et al. A case report of recurrent metastatic sebaceous carcinoma which showed favorable response to non-fluorouracil based chemotherapy. *Am J Case Rep*. 2018;19:1192–6. <https://doi.org/10.12659/AJCR.912552>.
 33. Cheung JJC, Esmaeli B, Lam SC, et al. The practice patterns in the management of sebaceous carcinoma of the eyelid in the Asia Pacific region. *Eye*. 2019. <https://doi.org/10.1038/s41433-019-0432-0>.
 34. Khan JA, Doane JF, Grove AS Jr. Sebaceous and meibomian carcinomas of the eyelid. Recognition, diagnosis, and management. *Ophthal Plast Reconstr Surg*. 1991;7:61–6.