

## ORIGINAL ARTICLE

## A case of bilateral aldosterone-producing adenomas differentiated by segmental adrenal venous sampling for bilateral adrenal sparing surgery

R Morimoto<sup>1</sup>, N Satani<sup>2</sup>, Y Iwakura<sup>1</sup>, Y Ono<sup>1</sup>, M Kudo<sup>1</sup>, M Nezu<sup>1</sup>, K Omata<sup>1,3</sup>, Y Tezuka<sup>1,3</sup>, K Seiji<sup>2</sup>, H Ota<sup>2</sup>, Y Kawasaki<sup>4</sup>, S Ishidoya<sup>4</sup>, Y Nakamura<sup>5</sup>, Y Arai<sup>4</sup>, K Takase<sup>2</sup>, H Sasano<sup>5</sup>, S Ito<sup>1</sup> and F Satoh<sup>1,3</sup>

Primary aldosteronism due to unilateral aldosterone-producing adenoma (APA) is a surgically curable form of hypertension. Bilateral APA can also be surgically curable in theory but few successful cases can be found in the literature. It has been reported that even using successful adrenal venous sampling (AVS) via bilateral adrenal central veins, it is extremely difficult to differentiate bilateral APA from bilateral idiopathic hyperaldosteronism (IHA) harbouring computed tomography (CT)-detectable bilateral adrenocortical nodules. We report a case of bilateral APA diagnosed by segmental AVS (S-AVS) and blood sampling via intra-adrenal first-degree tributary veins to localize the sites of intra-adrenal hormone production. A 36-year-old man with marked long-standing hypertension was referred to us with a clinical diagnosis of bilateral APA. He had typical clinical and laboratory profiles of marked hypertension, hypokalaemia, elevated plasma aldosterone concentration (PAC) of 45.1 ng dl<sup>-1</sup> and aldosterone renin activity ratio of 90.2 (ng dl<sup>-1</sup> per ng ml<sup>-1</sup> h<sup>-1</sup>), which was still high after 50 mg-captopril loading. CT revealed bilateral adrenocortical tumours of 10 and 12 mm in diameter on the right and left sides, respectively. S-AVS confirmed excess aldosterone secretion from a tumour segment vein and suppressed secretion from a non-tumour segment vein bilaterally, leading to the diagnosis of bilateral APA. The patient underwent simultaneous bilateral sparing adrenalectomy. Histopathological analysis of the resected adrenals together with decreased blood pressure and PAC of 5.2 ng dl<sup>-1</sup> confirmed the removal of bilateral APA. S-AVS was reliable to differentiate bilateral APA from IHA by direct evaluation of intra-adrenal hormone production.

*Journal of Human Hypertension* (2016) 30, 379–385; doi:10.1038/jhh.2015.100; published online 5 November 2015

## INTRODUCTION

Primary aldosteronism (PA) is one of the most frequent causes of secondary hypertension and patients with PA are generally at a markedly higher risk of both cardiovascular and renal morbidity than those with essential hypertension.<sup>1,2</sup> Adrenal venous sampling (AVS) via bilateral adrenal central veins (C-AVS) is indispensable to discriminate unilateral from bilateral diseases in patients with PA.<sup>3–5</sup> In general, unilateral disease is considered surgically curable, whereas bilateral disease should be medically treated with mineralocorticoid receptor antagonists. Idiopathic hyperaldosteronism (IHA) is the most common subtype of bilateral forms of PA, and sometimes can harbour unilateral or bilateral clinically non-functioning adrenocortical nodules.<sup>3–4</sup> To date, only few patients with bilateral aldosterone-producing adenoma (APA) have been reported to have undergone surgery<sup>6–8</sup> and these patients been cured. C-AVS can detect the laterality of hyperaldosteronism but it is still nearly impossible to precisely differentiate IHA with bilateral non-functioning adrenocortical nodules from bilateral APA. Blood sampling from the central veins (CV) of bilateral adrenal glands could determine whether PA is due to unilateral or bilateral over-secretion of aldosterone, but by no means can determine which intra-adrenal segment is responsible for excessive aldosterone production. Therefore, to improve

differential diagnosis, segmental AVS (S-AVS) or sampling blood via intra-adrenal first-degree tributary veins to evaluate the intra-adrenal distribution of hormone production was developed.<sup>9</sup>

In this case report, we demonstrated that S-AVS made it possible to diagnose functionality of bilateral tumours. Subsequently, S-AVS-guided sparing surgery was performed and the definitive diagnosis of bilateral APA was confirmed based on immunohistochemical analysis of steroidogenic enzymes involved in aldosterone biosynthesis using isoform-specific monoclonal antibodies as well as improvement of clinical features and laboratory data characteristic of PA.

## MATERIALS AND METHODS

## Patient evaluation

The patient was instructed not to restrict salt intake during out-of-hospital settings and was fed at least 10 g of salt daily during in-hospital periods to avoid interference of the renin–angiotensin–aldosterone system. All anti-hypertensive agents other than calcium channel blockers and alpha-adrenergic antagonists were withdrawn before hormonal examination.<sup>10</sup> Hypokalaemia was actively corrected by prescribing oral potassium replacement to avoid underestimation of aldosterone secretion.<sup>3</sup>

Both plasma and urinary concentrations of aldosterone were measured by radioimmunoassay using the commercially available SPAC-S Aldosterone

<sup>1</sup>Division of Nephrology, Endocrinology and Vascular Medicine, Department of Medicine, Tohoku University Hospital, Sendai, Japan; <sup>2</sup>Department of Diagnostic Radiology, Tohoku University Hospital, Sendai, Japan; <sup>3</sup>Division of Clinical Hypertension, Endocrinology and Metabolism, Tohoku University Graduate School of Medicine, Sendai, Japan; <sup>4</sup>Department of Urology, Tohoku University Hospital, Sendai, Japan and <sup>5</sup>Department of Pathology, Tohoku University Hospital, Sendai, Japan. Correspondence: Dr F Satoh, Division of Nephrology, Endocrinology and Vascular Medicine, Department of Medicine or Division of Clinical Hypertension, Endocrinology and Metabolism, Tohoku University Graduate School of Medicine, Miyagi, Sendai 980-8574, Japan.

E-mail: fsatoh@hosp.med.tohoku.ac.jp

Received 13 May 2015; revised 16 August 2015; accepted 27 August 2015; published online 5 November 2015

Kit (TFB Inc., Tokyo, Japan) and plasma renin activity was measured by radioimmunoassay of angiotensin I using the commercially available Renin RIABEAD Kit (Dainabot Co. LTD, Tokyo, Japan). Plasma and urinary levels of aldosterone were set at 12 ng dl<sup>-1</sup> and 10 µg per day, respectively, as the upper limit of normal in the local reference range. Plasma renin activity was set at 1–3 ng ml<sup>-1</sup> h<sup>-1</sup> as normal in a recumbent position. Plasma adrenocorticotrophic hormone (ACTH) concentration was measured by electrochemiluminescent immunoassay using the commercially available ECLusys ACTH kit (Roche Diagnostics K.K., Tokyo, Japan) and the local reference range was defined as 12–45 pg ml<sup>-1</sup>. Both serum and urinary free cortisol levels were measured by chemiluminescent immunoassay using the commercially available Chemilumi ACS-E Cortisol Kit (Siemens Healthcare Diagnostics, Inc., Tokyo, Japan) and the local reference ranges of serum and urinary free cortisol were defined as 7.0–15.0 µg dl<sup>-1</sup> and 55.5–285 µg per day, respectively. Informed consent was obtained from the patient and the present study was approved by the ethics committee of Tohoku University Graduate School of Medicine (#2014-1-758).

### Imaging study and S-AVS

The patient underwent dynamic computed tomography (CT) scans with non-ionic contrast material before the AVS procedure.<sup>11</sup> We evaluated the presence or absence of adrenal tumours and identified bilateral adrenal veins on CT. These CT findings were also used as a reference of the AVS procedure and catheter selection. The commercially available stand-alone workstation (Ziostation 2, Amin, Tokyo, Japan) was used to process multi-planar reconstruction and volume rendering images. At the beginning of the AVS procedure, 6.5 Fr catheters were inserted via the bilateral common femoral veins into the adrenal central veins. Under cosyntropin stimulation, we collected adrenal effluents from bilateral adrenal central and tributary veins using micro-catheters. We employed the commercially available micro-catheter 'Gold Crest micro-catheter split-tip' (HI-LEX Co. LTD, Hyogo, Japan). A peripheral blood sample was obtained via a catheter introducer with its end located within the external iliac vein (EIV). At the beginning of the S-AVS, 200 µg of cosyntropin was administered as an intravenous bolus injection. Thirty minutes later, continuous infusion of cosyntropin at a rate of 50 µg h<sup>-1</sup> was initiated. Blood was simultaneously sampled from the EIVs and bilateral adrenal central veins 15 min after the bolus administration of cosyntropin and then it was sequentially sampled from bilateral tributaries. Cannulation of the CV was determined as successful using a selectivity index (SI) with a cut-off equal to or >5.0.<sup>3–5,10</sup> Laterality of hyperaldosteronism was diagnosed based on the lateralization index.<sup>10</sup> Contralateral suppression index, which was defined as the ratio of aldosterone-over-cortisol (A/C) value in the non-dominant side divided by that in the periphery, was employed with cut-off of 1.0 to evaluate suppression of aldosterone secretion.<sup>3</sup>

### Histopathological analysis with combined immunohistochemical analysis of steroidogenic enzymes

Histopathological evaluation was performed as previously reported.<sup>12,13</sup> In brief, 5-µm-thick sections were cut using a microtome and deparaffinized with xylene and ethanol. For immunodetection of type 1 3β-hydroxysteroid dehydrogenase (HSD3B1) and type 2 3β-hydroxysteroid dehydrogenase (HSD3B2), antigen retrieval was performed in citric acid buffer (pH 6.0) using an autoclave as the heating source. Immunoreactivity was visualized by the colorimetric action of 3,3'-diaminobenzidine (brown staining) with a peroxidase-based Histofine Simple Stain Kit (Nichirei, Tokyo, Japan) and counterstained with hematoxylin. For immunodetection of aldosterone synthase (CYP11B2) and type 1 11β-hydroxylase (CYP11B1), antigen retrieval was performed in EDTA buffer (pH 9.0), and using an autoclave for heating; immunostaining was performed using the ImmPRESS REAGENT (VECTOR, Burlingame, CA, USA). All resected adrenal tumours were considered adrenocortical adenomas based on the criteria of Weiss.<sup>14,15</sup>

## RESULTS

### A case of bilateral APA

A 36-year-old man was referred to our hospital for evaluation of PA. He had first been diagnosed with hypertension at age 28 due to a systolic blood pressure (BP) of nearly 190 mm Hg and had been started on anti-hypertensive agents. After discontinuation of pharmacological treatment for ~5 years, he sought treatment for hypertension when he was 36 because his systolic BP had

**Table 1.** Clinical parameters before and after surgery

	Baseline	Days after adrenalectomy	
		7	233
Plasma aldosterone (ng dl <sup>-1</sup> )	45.1	5.2	16.6
Plasma renin activity (ng ml <sup>-1</sup> h <sup>-1</sup> )	0.5	0.8	2.7
ARR (ng dl <sup>-1</sup> per ng ml <sup>-1</sup> h <sup>-1</sup> )	90.2	6.5	6.1
Plasma ACTH (pg ml <sup>-1</sup> )	13.9	78.7	58.6
Serum cortisol (µg dl <sup>-1</sup> )	8.0	10.2	11.2
Urinary aldosterone (µg per day)	33.3	1.1	NA
Urinary free cortisol (µg per day)	148.6	118.0	NA
Captopril-challenged ARR (ng dl <sup>-1</sup> per ng ml <sup>-1</sup> h <sup>-1</sup> )	325.0	NA	NA
Cortisol with 1mg DST (µg dl <sup>-1</sup> )	0.9	NA	NA
SBP (mm Hg)	154	107	111
DBP (mm Hg)	107	77	82
HR (beat per minute)	60	73	81
Number of anti-hypertensive agents per day	4	1	1
BUN (mg dl <sup>-1</sup> )	13	13	19
SCr (mg dl <sup>-1</sup> )	1.21	1.20	1.39
eGFR (ml min <sup>-1</sup> 1.73 m <sup>2</sup> )	56.31	56.38	48.00
Na (mm)	140	136	141
K (mm)	4.0	5.3	4.8
Cl (mm)	106	104	106
TTKG	8.79	NA	NA
K replacement (mmol per day)	48.0	0	0
<i>Size of adrenal nodule</i>			
Right adrenal nodule (mm)	10	NA	NA
Left adrenal nodule (mm)	12	NA	NA

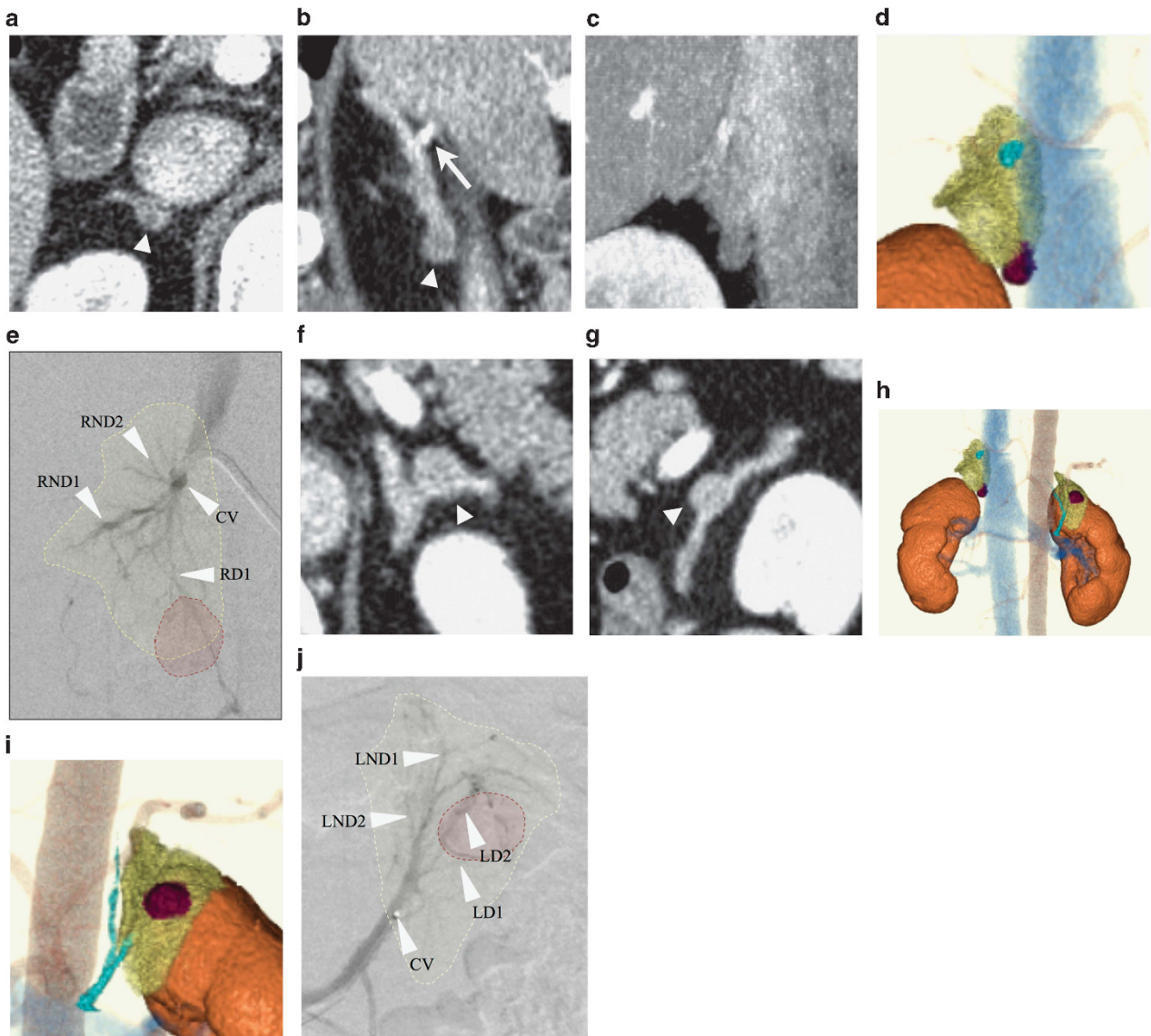
Abbreviations: ARR, aldosterone; BUN, blood urea nitrogen; DST, dexamethasone suppression test; DBP, diastolic blood pressure; eGFR, estimated glomerular filtration rate; HR, heart rate; NA, not applicable; SBP, systolic blood pressure; SCr, serum creatinine; TTKG, transtubular potassium gradient.

increased to >200 mm Hg. His hypertension was difficult to manage and his BP was persistently 160/120 mm Hg despite medication with amlodipine, atenolol and olmesartan. He also had hypokalaemia as his blood level of potassium was 3.2 mmol l<sup>-1</sup>.

At his first visit to us, his BP was 154/107 mm Hg despite medication with the three agents described above and his serum potassium level was 3.1 mmol l<sup>-1</sup>. He also had chronic kidney disease due to nephrosclerosis; his estimated glomerular filtration rate was 56.31 ml min<sup>-1</sup> 1.73 m<sup>-2</sup> and urinary albumin excretion was 168.6 mg per gram creatinine.

### Diagnosis of PA and imaging studies

After discontinuation of atenolol and olmesartan, and oral replacement of potassium with 48 mmol per day, his baseline plasma aldosterone and renin activity levels were 45.1 ng dl<sup>-1</sup> and 0.5 ng ml<sup>-1</sup> h<sup>-1</sup>, respectively, with an elevated aldosterone-over-renin activity ratio of 90.2 ng dl<sup>-1</sup> per ng ml<sup>-1</sup> h<sup>-1</sup> and serum potassium level of 4.0 mmol l<sup>-1</sup> (Table 1). Urinary excretion of aldosterone also increased to 33.3 µg per day (Table 1). Captopril-challenge test revealed an aldosterone-to-renin ratio of 325.0 ng dl<sup>-1</sup> per ng ml<sup>-1</sup> h<sup>-1</sup> at 120 min (Table 1). The patient was subsequently diagnosed as having PA based on the above findings. CT scan revealed bilateral adrenal tumours measuring 10 mm (right) and 12 mm (left) in diameter (Figure 1). Within-adrenal localization of the tumours and delineation of adrenal central veins was performed by reconstructing three-dimensional (3D) CT imaging before S-AVS (Figures 1d, h and i). The right tumour was localized in the caudal end (Figure 1d) and the left in the middle portion of the respective adrenal gland (Figure 1i). Analysis of the hypothalamic–pituitary–adrenal axis revealed



**Figure 1.** Imaging studies of bilateral APA. (a) Axial view of the right adrenal gland in contrast-enhanced CT. The arrowhead indicates the right adrenal tumour. (b) Sagittal view of the right adrenal gland in contrast-enhanced CT. The arrow indicates the CV and the arrowhead the tumour located in the caudal end of the gland. (c and d) Reconstructed 3D CT showing the right adrenal tumour (dark red) was localized in the caudal end of the gland (yellow). The inferior vena cava and kidneys are shown in blue and orange, respectively. A portion of the right adrenal central vein is shown in pale blue. (e) Segmental sampling points from tumour (RD1) and non-tumour segments (RND1 and RND2) of the right adrenal gland were superimposed on adrenal venography based on the 3D CT. The area circumscribed with a red dotted line delineates the tumour segment and that with a yellow dotted line indicates the outer line of the right adrenal gland. CV indicates a sampling point from a CV. (f and g) Axial and sagittal views of the left adrenal gland in contrast-enhanced CT. The arrowhead indicates the left adrenal tumour. (h) Reconstructed 3D CT showing the adrenal tumour (dark red) within each adrenal gland (yellow). Inferior vena cava, kidneys and abdominal aorta are depicted in blue, orange and light brown, respectively. (i) Magnified view of 3D CT showing the left adrenal gland in the centre. The tumour is shown in dark red and both the left adrenal vein and inferior phrenic vein are partly delineated in pale blue. (j) Segmental sampling points from tumour (LD1 and LD2) and non-tumour segments (LND1 and LND2) of the left adrenal gland were superimposed on adrenal venography based on the 3D CT. The area circumscribed with a red dotted line delineates the tumour segment and that with a yellow dotted line indicates the outer line of the left adrenal gland. CV indicates a sampling point from a CV.

baseline ACTH and cortisol levels of  $13.9 \text{ pg ml}^{-1}$  and  $8.0 \text{ } \mu\text{g dl}^{-1}$ , respectively, and urinary free cortisol of  $148.6 \text{ } \mu\text{g per day}$  (Table 1). Overnight dexamethasone suppression test revealed a cortisol of  $0.9 \text{ } \mu\text{g dl}^{-1}$  (Table 1).

#### Segmental AVS and clinical diagnosis of bilateral APA

Segmental AVS was performed without complication and samples from both APA and non-tumour segments of bilateral adrenal veins were successfully obtained (Table 2). The SI of right and left CV cannulation was 100.54 and 77.83, respectively, and judged as

successful. When we compared the A/C ratio obtained at bilateral CV, the lateralization index was 4.71 with predominance of the left adrenal gland. Based on anatomical localization obtained by 3D CT and venography, we cannulated one drainer (RD1) and two non-drainers (RND1 and RND2) segments in the right adrenal gland using a micro-catheter (Figure 1e). We also introduced a micro-catheter into two drainers (LD1 and LD2) and two non-drainer (LND1 and LND2) segments in the left adrenal gland (Figure 1j). All of the SI attained from bilaterally segmental tributaries were  $> 5.0$  with a median of 88.15 (range 76.41–104.6;

**Table 2.** Central and S-AVS

	A	C	A/C	SI	CSI
EIV	34.4	9.2	3.74	NA	NA
<i>Right adrenal</i>					
CV	1920	925	2.08	100.54	0.56
RD 1	2657	703	3.78	76.41	1.01
RND 1	712	782	0.91	85.00	0.24
RND 2	611	811	0.75	88.15	0.20
<i>Left adrenal</i>					
CV	7006	716	9.78	77.83	2.62
LD 1	25444	794	32.05	86.30	8.57
LD 2	10187	817	12.47	88.80	3.33
LND 1	2375	939	2.53	102.07	0.68
LND 2	1591	962	1.65	104.57	0.44

Abbreviations: A, aldosterone; A/C, a ratio of aldosterone-over-cortisol; C, cortisol; CSI, contralateral suppression index; CV, central vein; EIV, external iliac vein; LD, drainer segment of the left adrenal; RD, drainer segment of the right adrenal; RND, non-drainer segment of the right adrenal; LND, non-drainer segment of the left adrenal; S-AVS, segmental AVS; SI, selectivity index.

Table 2). Within the right adrenal gland, the aldosterone level and A/C obtained from RD1 were 2657 ng dl<sup>-1</sup> and 3.78, respectively, and A/C of RD1 (3.78) was higher than that of EIV (3.74; Table 2). However, aldosterone levels from RND1 and RND2 were 712 and 611 ng dl<sup>-1</sup>, respectively, and A/C of both RND1 (0.91) and RND2 (0.75) were lower than that of EIV (3.74; Table 2). In the left adrenal gland, aldosterone levels from LD1 and LD2 were as high as 25444 and 10187 ng dl<sup>-1</sup>, respectively, and A/C of both LD1 (32.05) and LD2 (12.47) were higher than that of EIV (3.74; Table 2). Then, compared with the data of the drainer segments, aldosterone levels from LND1 and LND2 were 2375 and 1591 ng dl<sup>-1</sup>, respectively, and A/C of both LND1 (2.53) and LND2 (1.65) were lower than that of EIV (3.74; Table 2). In each adrenal gland, A/C obtained from non-drainer segments were lower than that of EIV, indicating that aldosterone secretion was suppressed when employing contralateral suppression index in comparison between non-drainer segments and periphery. All the values of contralateral suppression index comparing non-drainer segments and EIV were 0.24, 0.20, 0.68 and 0.44 at RND1, RND2, LND1 and LND2, respectively (Table 2). In contrast, the A/C from a tumour segment was higher than that of EIV (Table 2), aldosterone secretion from the tumour segment was elevated.

Based on these findings, we finally interpreted that a matched combination of elevated and suppressed secretion of aldosterone within each adrenal gland should be considered a rationale for the clinical diagnosis of APA, but not hyperplasia, and an indication for partial adrenalectomy, that is, resection of the tumour with preservation of suppressed non-tumour segments.

Plan for adrenal sparing surgery and postoperative replacement  
We decided to undertake one-stage, laparoscopic adrenal sparing surgery under the clinical diagnosis of bilateral APA based on the results of S-AVS. According to 3D CT findings, we considered the right adrenal tumour, which was located in the caudal end of the gland, could be resected while preserving the rest of the gland (Figure 1d). As for the left adrenal tumour that was localized in the middle portion of the gland (Figure 1i), we considered it was difficult to remove it by partial adrenalectomy. Consequently, we performed partial adrenalectomy of the right gland and total adrenalectomy of the left.

In terms of glucocorticoid replacement, the patient was expected to have sufficient residual adrenal tissue left and was considered not to require replacement. This assumption

was based on 3D CT findings suggesting that the non-tumour portion, which had been estimated to be more than half of the unilateral gland (Figure 1d), could preserve endogenous glucocorticoid secretion.

#### Clinical outcome following the surgery

Surgery was performed without complication. Plasma ACTH and cortisol levels were 64.6 pg ml<sup>-1</sup> and 8.8 µg dl<sup>-1</sup>, respectively, early in the morning of the first day after the surgery, and we followed the patient without providing glucocorticoid replacement all throughout the follow-up period. The patient had no signs or symptoms of adrenal insufficiency until the latest follow-up evaluation. Plasma and urinary levels of aldosterone decreased to 5.2 ng dl<sup>-1</sup> and 1.1 µg per day on postoperative day 7, whereas plasma renin activity was 0.8 ng ml<sup>-1</sup> h<sup>-1</sup>. At the same time, plasma ACTH and cortisol levels were 78.7 pg ml<sup>-1</sup> and 10.2 µg dl<sup>-1</sup>, respectively, early in the morning, and urinary free cortisol decreased to 118.0 µg per day (Table 2). At the evaluation on postoperative day 233, plasma aldosterone and renin activity were 16.6 ng dl<sup>-1</sup> and 2.7 ng ml<sup>-1</sup> h<sup>-1</sup>, respectively, whereas plasma ACTH and cortisol levels were 58.6 pg ml<sup>-1</sup> and 11.2 µg dl<sup>-1</sup>, respectively (Table 2).

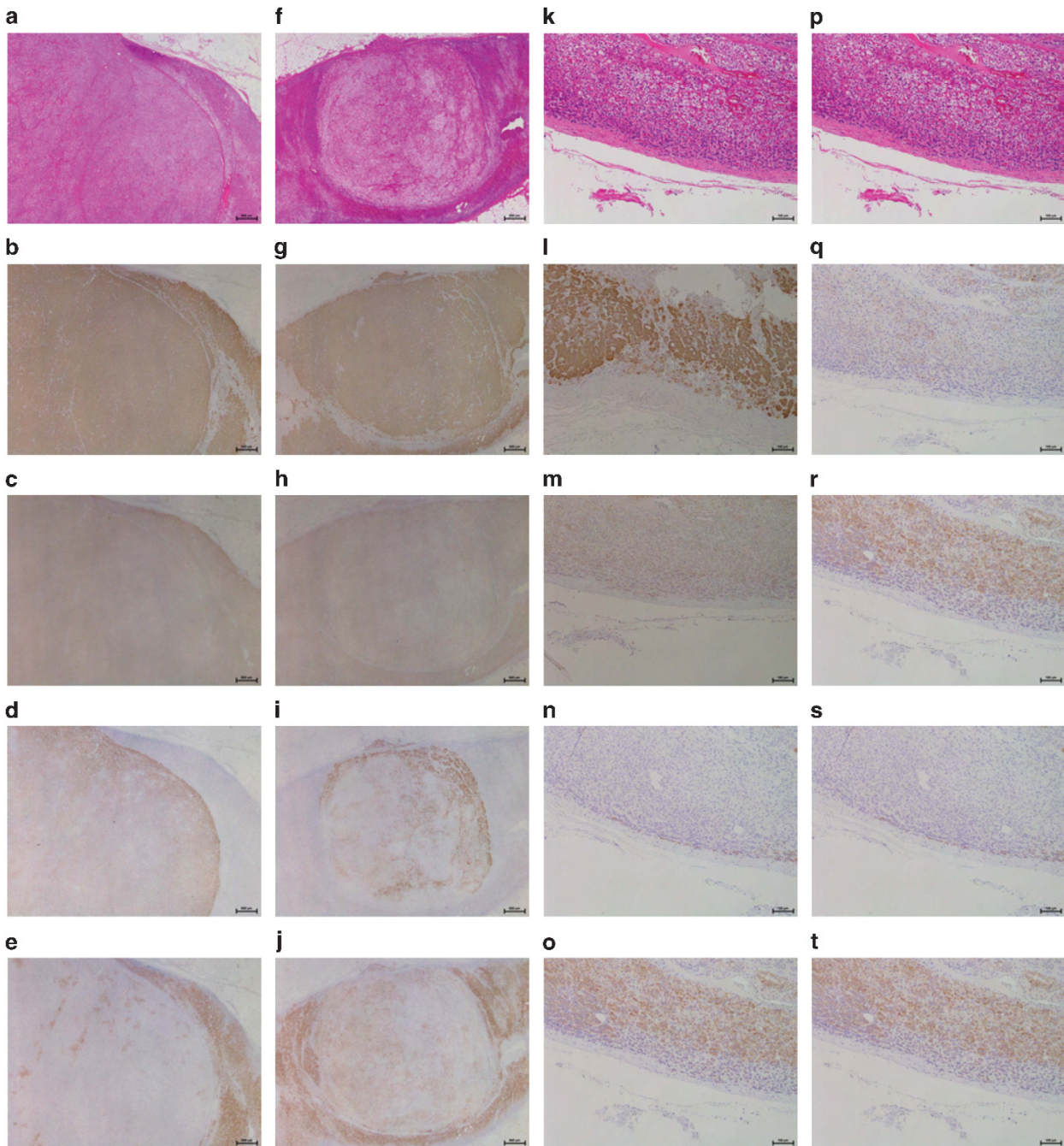
Serum potassium levels were normalized without replacement to 5.3 and 4.8 mmol l<sup>-1</sup> at 7 and 233 days after the surgery, respectively (Table 1). Control of his elevated BP also improved after surgery. His BP was 107/77 and 111/82 mm Hg at 7 and 233 days following the surgery, respectively, and requirement of anti-hypertensive agents was reduced to only nifedipine (Table 1).

#### Pathological evaluation of bilateral APA

Bilateral adrenocortical tumours were mainly composed of clear cortical cells (Figures 2a and f) and bilateral attached non-tumourous adrenal tissues showed hyperplasia of the zona glomerulosa (Figures 2k and p). Immunohistochemical analysis of steroidogenic enzymes revealed diffuse marked immunoreactivity of HSD3B2 (Figures 2b and g) in the tumours but only focal immunoreactivity to HSD3B1 (Figures 2c and h) in bilateral tumour tissues. CYP11B2 (Figures 2d and i) immunoreactivity was positive but in a heterogeneous fashion, whereas CYP11B1 (Figures 2e and j) immunoreactivity was focal and weak in bilateral tumour tissues. There was no difference in steroidogenic enzymes patterns between these two bilateral tumours. In bilateral attached non-neoplastic adrenal glands, immunoreactivity to both HSD3B2 (Figures 2l and q) and HSD3B1 (Figures 2m and r) was diffusely attenuated in the morphologically hyperplastic zona glomerulosa. Immunoreactivity to CYP11B2 (Figures 2n and s) and CYP11B1 (Figures 2o and t) was undetectable in the morphologically hyperplastic zona glomerulosa of bilateral attached adrenal glands.

#### DISCUSSION

To the best of our knowledge, this is the first reported case of bilateral APA confirmed by immunohistochemistry of aldosterone-producing enzymes, diagnosed by S-AVS and subsequently successfully treated by bilateral adrenal sparing surgery. According to prior reports of a total of 10 cases of bilateral APA,<sup>6-8</sup> bilateral APA was mainly diagnosed according to the results of imaging studies (CT) with or without NP-59 scintigram with dexamethasone suppression. Wu *et al.*<sup>6</sup> reported three patients diagnosed by combining CT, AVS and histopathological confirmation obtained by two-stage surgery. Yet, it has been widely accepted that imaging studies, including CT and scintigraphy, have far less diagnostic accuracy than AVS.<sup>3-5</sup> However, it is also true that C-AVS has only a limited diagnostic value regarding determination whether adrenocortical nodules, very frequently concurrent with APA, are actually functional or not.



**Figure 2.** Histopathological analysis of bilateral APA. Right (a–e) and left (f–j) adrenal tumours, respectively. Right (k–o) and left (p–t) adrenal non-neoplastic tissues, respectively. (a) and (f) Histopathological findings of the right and left adrenal tumours, respectively. (k) and (p) Histopathological findings of the attached non-neoplastic adrenal tissues of the right and left adrenal glands, respectively. (b) and (g), (c) and (h), (d) and (i), and (e) and (j); Immunohistochemistry of HSD3B2, HSD3B1, CYP11B2 and CYP11B1 in the tumours, respectively. (l) and (q), (m) and (r), (n) and (s), and (o) and (t); Immunohistochemistry of HSD3B2, HSD3B1, CYP11B2 and CYP11B1 in the non-neoplastic adrenal tissues, respectively.

Nevertheless, in our present case, S-AVS did enable us to make a functional diagnosis of bilateral APA by directly and quantitatively analysing secretion of aldosterone from both tumourous and non-tumourous segments of the same adrenal glands, and to design the surgical approach to totally remove the tumours and at the same time preserve the attached non-neoplastic adrenal tissue. This successful diagnosis and treatment was clinically confirmed by endocrinological remission of the disease, improved control of hypertension and correction of hypokalaemia after the surgery.

In addition, immunohistochemical analysis using the recently developed isoform-specific antibodies to steroidogenic enzymes involved in aldosterone biosynthesis also confirmed the diagnosis of bilateral APA, but not IHA, in our present case.<sup>12,13</sup> As reported in our previous studies, one pivotal difference between APA and IHA is the expression of HSD3B1 and HSD3B2 in the hyperplastic zona glomerulosa cells.<sup>12</sup> In IHA, the aldosterone-producing hyperplastic glomerular zone is characterized by prominent immunoreactivity of HSD3B1 and HSD3B2, although profoundly

attenuated expression of these isoforms is detected in the hyperplastic glomerular zone of adjacent adrenal attached to APA, indicating suppressed aldosterone production in this area ('paradoxical hyperplasia').<sup>12</sup> This immunosuppression of HSD3B1 and HSD3B2 in the zona glomerulosa of adrenal tissue adjacent to the tumour was also detected in our patient, pathologically supporting the absence of IHA.

The present case could have been possibly diagnosed as unilateral, left-sided disease based only on C-AVS findings, because both the lateralization index of 4.71 (9.78/2.08) and the right contralateral suppression index of 0.56 (2.08/3.74) could be interpreted as consistent with predominantly left PA accompanied by contralateral suppression, suggesting that the right adrenal cortical nodules could have been regarded as a clinically non-functioning tumour, in most of referral centres.<sup>5</sup> However, results of S-AVS first revealed that the right adrenal tumour was considered another APA based on the combination of elevated A/C from the drainer segment (3.78) and suppressed A/C from the non-drainer segments (0.91 and 0.75) compared with peripheral A/C (2.08). These results indicated that S-AVS could contribute to reduce the diagnostic discrepancy between CT and AVS findings, because S-AVS is expected to provide information as to whether CT-detectable tumours are aldosterone-producing or not by direct sampling from drainer tributary veins of the tumours. In our recent report on 159 patients who underwent S-AVS, we diagnosed four cases of bilateral APA, including the present case, and three cases of IHA with bilateral, clinically non-functioning tumours<sup>16</sup> and these cases were considered extremely difficult to differentiate one from the other based only on C-AVS findings.

In addition to differentiating bilateral APA from bilateral hyperplasia, S-AVS is considered to be useful for identifying APA in patients with multiple adrenocortical nodular lesions within a gland; S-AVS might make it possible to differentiate multiple APA from a single APA with non-functioning adenomas or nodules. Therefore, S-AVS might be useful in deciding an indication for partial adrenalectomy in patients with unilateral APA.

It might be true that S-AVS could provide better diagnostic capacity to differentiate bilateral APA from bilateral hyperplasia accompanied by bilateral clinically non-functioning adrenocortical tumours, but we should also consider pre-test probability of bilateral APA before performing S-AVS. The present patient had been judged as highly clinically suspected of having bilateral APA rather than bilateral non-functioning adenomas because of his relatively young age, that is, <40–50 years old, which led us to perform S-AVS. The incidence of adrenocortical tumours, especially non-functioning ones, is considered to increase as the population becomes older, and these tumours are difficult to distinguish from APA based solely on CT findings.<sup>3,17</sup> We therefore should assess the pre-test probability of bilateral APA based on demographic and endocrinological findings to justify the indication of S-AVS, which is considered to require higher skills, more costs, longer time to perform it and involve increased risks of complications compared with conventional C-AVS. In our experience, the incidence of adrenal haemorrhage during sampling procedures has been higher in case of S-AVS when compared with C-AVS.<sup>16</sup> Therefore, we must acknowledge that S-AVS is considered to have inherent risks of complications, such as adrenal haemorrhage and resultant partial adrenal infarct, whose incidence is expected to be higher than that seen in C-AVS. Based upon these risk-benefit correlations detected in S-AVS, an indication for S-AVS should be carefully enforced when selecting the patients.

In addition, we need to address three other clinically relevant and pivotal issues regarding S-AVS and adrenal sparing surgery in patients with bilateral APA. First, we should recognize that the present patient had compensated, but clinically inapparent, adrenal insufficiency based on the elevated, supra-physiological ACTH level compared with that before the surgery. We continued

to carefully watch the clinical course without glucocorticoid replacement based on persistently elevated ACTH despite the maintained cortisol level compared with baseline, but it should be pointed out that the patient was at obvious risks of adrenal crisis predisposed by acute illness. As reported to date, bilateral adrenal sparing surgery has not always been so successful that life-long glucocorticoid replacement could be necessary and/or the adrenal diseases may not be fully cured in some cases. We therefore need to make a prudent decision as to whether to perform adrenal sparing surgery on an individualized risk-benefit balance basis.

Second, we should consider the increased probability of persistent, and sometimes marked, hyperkalaemia following adrenalectomy. As indicated by Fischer *et al.*<sup>18</sup>, in those who underwent adrenalectomy for unilateral APA, insufficiency of zona glomerulosa with the resultant hyperkalaemia was detected in 5% of their study cohort and decreased renal function was reported to be one of the significant predictors of postoperative hyperkalaemia. We therefore should consider that the incidence of postoperative hyperkalaemia could be increased in patients who have undergone bilateral surgery, because the volume of the remnant adrenocortical tissue is presumed to be inevitably less than that following unilateral surgery. In addition, we should also expect increased risks of renal impairment based on the severity of end-organ damage caused by bilateral APA. As shown in Table 1, we detected a decreased estimated glomerular filtration rate ( $56.31 \text{ ml min}^{-1} 1.73 \text{ m}^{-2}$ ) and an increased urinary albumin excretion (168.6 mg per gram creatinine) in our present patient. We are therefore required to appropriately assess the post-operative risk of hyperkalaemia and to watch more carefully the postoperative course to prevent or take control of hyperkalaemia as a consequence of mineralocorticoid insufficiency in patients with APA subjected to bilateral surgery.

Third, we should discuss another surgical option for patients with bilateral PA. Sukor N *et al.*<sup>19</sup> reported that unilateral adrenalectomy was effective in some patients with bilateral PA diagnosed by conventional central AVS.<sup>19</sup> Although their study cohort could have included an unknown number of patients with bilateral APA, unilateral adrenalectomy subsequently treated using mineralocorticoid receptor antagonists did not harbour the risk of developing persistent, sometimes life-long, adrenal insufficiency with concomitant requirement for glucocorticoid replacement seen in those with bilateral surgery. Given the limitation that the present study is just a single case report, we need to perform further studies to thoroughly evaluate the clinical outcome of patients with bilateral APA depending on these two treatment options.

In summary, we reported a case of bilateral APA whose diagnosis was made based on S-AVS and pathological findings including immunohistochemistry of steroidogenic enzymes after bilateral adrenal sparing surgery. We consider that the present case was so unique in the following aspects: relatively young age of the patient, suitable localization of the tumours for the sparing surgery, fortunately asymptomatic postoperative course with compensated adrenal insufficiency, and no persistent episodes of hyperkalaemia despite the impaired renal function already detected at presentation. We therefore consider that the diagnostic and therapeutic approach followed in the present case cannot be applied in all cases of bilateral APA, rather we should make it clear which clinical characteristics suggest suitability of this approach in future studies. In addition, S-AVS-based sparing surgery could be eventually demonstrated to be clinically useful in a very limited number of bilateral APA cases. Until the time that sufficient clinical experience and evidence regarding the diagnosis and treatment strategies to determine which patients could benefit accumulates, we should prudently personalize therapeutic approaches on a clinical risk-benefit balance and thoroughly verify these approaches in larger cohorts of multiple PA centres in the future.

*What is known about topic*

- Adrenal venous sampling is crucial to evaluating laterality of hyperaldosteronism and subsequent decision on indication for adrenalectomy.
- It has been considered difficult to distinguish bilateral aldosterone-producing adenomas from bilateral hyperplasia with bilateral clinically non-functioning adenomas, based solely on findings of conventional sampling, that is, sampling from adrenal central veins.

*What this study adds*

- In combination with intra-adrenal localization of bilateral tumours, segmental adrenal venous sampling might make it possible to discriminate bilateral aldosterone-producing adenomas from bilateral hyperplasia.
- Segmental sampling might be clinically useful to design adrenal sparing surgery for bilateral aldosterone-producing adenomas.

**CONFLICT OF INTEREST**

The authors declare no conflict of interest.

**ACKNOWLEDGEMENTS**

We thank Yasuko Tsukada, Akane Sugawara, Mika Ainoya, Kumi Kikuchi and Hiroko Kato for their secretarial assistance.

**REFERENCES**

- 1 Savard S, Amar L, Plouin PF, Steichen O. Cardiovascular complications associated with primary aldosteronism: a controlled cross-sectional study. *Hypertension* 2013; **62**: 331–336.
- 2 Mulatero P, Monticone S, Bertello C, Viola A, Tizzani D, Iannaccone *et al*. Long-term cardio- and cerebrovascular events in patients with primary aldosteronism. *J Clin Endocrinol Metab* 2013; **98**: 4826–4833.
- 3 Funder JW, Carey RM, Fardella C, Gomez-Sanchez CE, Mantero F, Stowasser M *et al*. Case detection, diagnosis, and treatment of patients with primary aldosteronism: an endocrine society clinical practice guideline. *J Clin Endocrinol Metab* 2008; **93**: 3266–3281.
- 4 Young WF Jr, Stanson AW, Thompson GB, Grant CS, Farley DR, van Heerden JA. Role for adrenal venous sampling in primary aldosteronism. *Surgery* 2004; **136**: 1227–1235.
- 5 Rossi GP, Auchus RJ, Brown M, Lenders JW, Naruse M, Plouin PF *et al*. An expert consensus statement on use of adrenal vein sampling for the subtyping of primary aldosteronism. *Hypertension* 2014; **63**: 151–160.
- 6 Wu VC, Chueh SC, Chang HW, Lin WC, Liu KL, Li HY *et al*. Bilateral aldosterone-producing adenomas: differentiation from bilateral adrenal hyperplasia. *QJM* 2008; **101**: 13–22.
- 7 Chung SD, Huang KH, Yu HJ, Wu KD, Chueh SC. Diagnosis of bilateral aldosterone-producing adenomas. *Kidney Int* 2007; **72**: 228.
- 8 Watanabe N, Tsunoda K, Sasano H, Omata K, Imai Y, Ito S *et al*. Bilateral aldosterone-producing adenomas in two patients diagnosed by immunohistochemical analysis of steroidogenic enzymes. *Tohoku J Exp Med* 1996; **179**: 123–129.
- 9 Nishikawa T, Matsuzawa Y, Saito J, Omura M. Is it possible to extirpate cardiovascular events in primary aldosteronism after surgical treatment. *Jpn Clin Med* 2010; **1**: 21–23.
- 10 Satoh F, Abe T, Tanemoto M, Nakamura M, Abe M, Uruno *et al*. Localization of aldosterone-producing adrenocortical adenomas: significance of adrenal venous sampling. *Hypertens Res* 2007; **30**: 1083–1095.
- 11 Matsuura T, Takase K, Ota H, Yamada T, Sato A, Satoh F *et al*. Radiologic anatomy of the right adrenal vein: preliminary experience with MDCT. *AJR Am J Roentgenol* 2008; **191**: 402–408.
- 12 Doi M, Satoh F, Maekawa T, Nakamura Y, Fustin JM, Tainaka M *et al*. Isoform-specific monoclonal antibodies against 3 $\beta$ -hydroxysteroid dehydrogenase/isomerase family provide markers for subclassification of human primary aldosteronism. *J Clin Endocrinol Metab* 2014; **99**: E257–E262.
- 13 Nakamura Y, Maekawa T, Felizola SJ, Satoh F, Qi X, Velarde-Miranda C *et al*. Adrenal CYP11B1/2 expression in primary aldosteronism: immunohistochemical analysis using novel monoclonal antibodies. *Mol Cell Endocrinol* 2014; **392**: 73–79.
- 14 Weiss LM. Comparative histologic study of 43 metastasizing and nonmetastasizing adrenocortical tumors. *Am J Surg Pathol* 1984; **8**: 163–169.
- 15 Weiss LM, Medeiros LJ, Vickery AL Jr. Pathologic features of prognostic significance in adrenocortical carcinoma. *Am J Surg Pathol* 1989; **13**: 202–206.
- 16 Satoh F, Morimoto R, Seiji K, Satani N, Ota H, Iwakura Y *et al*. Is there a role for segmental adrenal venous sampling and adrenal sparing surgery in patients with primary aldosteronism? *Eur J Endocrinol* 2015; **173**: 465–477.
- 17 Kloos RT, Gross MD, Francis IR, Korobkin M, Shapiro B. Incidentally discovered adrenal masses. *Endocrine Reviews* 1995; **16**: 460–484.
- 18 Fischer E, Hanslik G, Pallauf A, Degenhart C, Linsenmaier U, Beuschlein F *et al*. Prolonged zona glomerulosa insufficiency causing hyperkalemia in primary aldosteronism after adrenalectomy. *J Clin Endocrinol Metab* 2012; **97**: 3965–3973.
- 19 Sukor N, Gordon RD, Ku YK, Jones M, Stowasser M. Role of unilateral adrenalectomy in bilateral primary aldosteronism: a 22-year single center experience. *J Clin Endocrinol Metab* 2009; **94**: 2437–2445.



This work is licensed under a Creative Commons Attribution-NonCommercial-NoDerivs 4.0 International License. The images or other third party material in this article are included in the article's Creative Commons license, unless indicated otherwise in the credit line; if the material is not included under the Creative Commons license, users will need to obtain permission from the license holder to reproduce the material. To view a copy of this license, visit <http://creativecommons.org/licenses/by-nc-nd/4.0/>