

Paper #33**CT Morphometric Analysis of Central Airways in Patients with Right Thoracic Scoliosis and Abnormal Sagittal Profile**

Enrique Garrido, James Farrell, Prashant Valluri

Summary: This retrospective study compared the airway morphology of normal patients with patients with juvenile and adolescent onset idiopathic scoliosis and abnormal sagittal profile.

Hypothesis: Lordoscoliosis causes right sided narrowing of bronchus intermedius and its bifurcation.

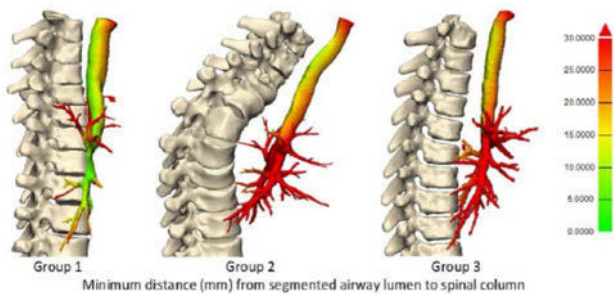
Design: Case controlled retrospective imaging study.

Introduction: Obstructive lung disease is prevalent in 39 % of patients with idiopathic scoliosis. We examine the morphology of central airways and its relationship to the spine as a possible causative factor.

Methods: 7 patients with a main right thoracic scoliosis with hypokyphosis of $< 10^\circ$ (Group 1); 7 patients with kyphoscoliosis $> 40^\circ$ (Group 2); and 7 age and sex matched patients without scoliosis (Group 3) were compared. Mean Cobb angle was 75° . Imaging software was used to segment the relevant anatomy. Airways and spine were normalised and referenced to the first thoracic vertebra. Cobb angles, anterior and lateral displacements of vertebra T6 & T7, spinal penetration index, airway volumes and cross-sections were measured.

Results: ANOVA analysis demonstrated a statistically significant reduction ($p < 0.01$) in Bronchus intermedius (BI) airway volumes and cross-sectional area when comparing Group 1 with Groups 2 & 3. The right bronchus intermedius bifurcated at T6 in Group 3 and at T7 in patients with scoliosis. In the frontal plain, the right main bronchus & bronchus intermedius had a more horizontal trajectory with increasing Cobb angle ($p < 0.05$). Cross sectional narrowing and volume loss of the bronchus intermedius correlated positively with the degree of thoracic kyphosis ($r = 0.6$), airway distance to spine ($r = 0.79$) and negatively with the degree of scoliosis ($r = -0.57$) and spinal penetration index ($r = -0.68$). Predictive variables including Cobb angle, kyphosis angle, were included to produce a multivariate linear regression to estimate the normalised right bronchus intermedius volume: $v = 0.7132 - 0.0016 \times \theta_{\text{scol}} + 0.0025 \times \theta_{\text{kyph}}$.

Conclusions: Scoliosis alters the position and shape of the central airways. In patients with severe scoliosis and hypokyphosis airway volumes and cross section are significantly reduced in the BI and its bifurcation. Airway obstruction is less likely to be implicated in the loss of lung capacity in patients with kyphoscoliosis.



Author disclosures: Enrique Garrido: None. James Farrell: K2M. Prashant Valluri: Research Grant.

Paper #34**Risk of Curve Progression in EOS after Surgical Decompression of Chiari Malformation**

Eric Davis, Michael Glotzbecker, Michael Troy, Lawrence Karlin, John Emans, M Timothy Hresko, Daniel Hedequist

Summary: The purpose of this study was to retrospectively 1) describe the natural history of EOS patients who undergo neurological decompression

to treat Chiari malformations 2) determine if neurological decompression effects the progression of EOS.

Hypothesis: Chiari malformations can be associated with scoliosis progression and prompt surgical decompression may alter the course of EOS progression preventing or delaying the need for future spinal surgeries.

Design: Retrospective Case Series.

Introduction: Chiari Malformations are known to be associated with scoliosis diagnosed at a young age. It is unclear if surgical decompression of Chiari malformations influences the natural history of EOS. Previous case series on this topic have been small and have not focused on decompression as a potential treatment for EOS. The purpose of this study was to describe EOS progression in patients who have prompt decompression of their Chiari malformations.

Methods: Patients < 10 years of age diagnosed with scoliosis and Chiari malformations that required surgical decompression over the past 20 years were identified using electronic medical records. Demographic data, pre- and post operative radiographic data were collected. Patients with congenital, syndromic or concomitant causes of neuromuscular curves were excluded. The major curves of each patient were measured before decompression and at last follow-up. Patients who required further scoliosis treatment or surgery were recorded.

Results: 42 patients including 29 females and 13 males with average age or 6.5 (2-9) years at presentation were included. The average age for neurosurgical decompression was 7 years (6 months after diagnosis). 21 (50%) patients were prescribed a scoliosis brace after their neurosurgical procedure. The mean Cobb at presentation was 27 degrees and was 30 degrees at a mean follow was 5 years. Following decompression 12 (29%) patients experienced long-term improvement in their curves (> 10 degrees), 19 (45%) experienced an insignificant change (< 10 degrees), 11 (26%) patients had a significant decline in their curves (> 10 degrees). Kyphosis and initial curve size were not predictive of curve progression or improvement. 5 patients in the study required spinal procedures (4 fusions and 1 growing rod followed by fusion).

Conclusions: Overall, 74% of patients with EOS and a Chiari malformation had no significant progression of their Cobb angles after surgical treatment of the Chiari.

Author disclosures: Eric Davis: None. Michael Glotzbecker: Depuy; Medtronic; Member of GSSG, CSSG, and HSG. Michael Troy: None. Lawrence Karlin: None. John Emans: Deputy Synthes; Medtronic; Journal of Children's Orthopedics. M Timothy Hresko: None. Daniel Hedequist: None.

Paper #35**Ventral Rod Migration of Posteriorly Applied Growing Rod Technology for Early Onset Scoliosis**

Patrick Kiely, Laura-Ann Lambert

Summary: As growing rod technology evolves, we discover complications of its use previously undescribed. Ventral rod migration (VRM) is a potentially catastrophic complication of growing rods. We defined VRM as ventral movement > 2 mm at the kyphotic apex, plotted from the posterior dorsal cortex of the apical lamina on axial CT. A review of CT imaging was conducted to assess for unidentified evidence of VRM. VRM was demonstrated in 3 patients, 1 of whom demonstrated rods positioned within the spinal canal.

Hypothesis: Where advanced imaging such as computed tomography is available in posteriorly applied growing rods, it should be examined for evidence of ventral rod migration (VRM).

Design: Retrospective observational cohort study.

Introduction: Growing rod technology has a known high incidence of complications. However, we describe the identification of a rare complication, in an asymptomatic patient with early onset scoliosis treated using modern growing rod technology. This patient experienced ventral rod migration of a single rod (in her dual growing rod construct) 2 years after her index surgery. Post-operative CT imaging demonstrated the rod resided within the thoracic portion of her spinal canal.

Methods: A retrospective review of all radiographic imaging was conducted for the growing rod cohort within a tertiary paediatric Orthopaedic