

- racy of dipyridamole technetium-99m labeled sestamibi myocardial tomography for detection of coronary artery disease. *J Nucl Cardiol* 1997;4:18-24.
27. Tamaki N, Yonekura Y, Mukai T, et al. Stress thallium-201 transaxial emission computed tomography: Quantitative versus qualitative analysis for evaluation of coronary artery disease. *J Am Coll Cardiol* 1984;4:1213-21.
28. Van Train K, Berman DS, Garcia EV, et al. Quantitative analysis of stress thallium-201 myocardial scintigrams: A multicenter trial. *J Nucl Med* 1986;27:17-25.
29. Mahmarian JJ, Boyce TM, Goldberg RK, Cocanougher MK, Roberts R, Verani MS. Quantitative exercise thallium-201 single photon emission computed tomography for the enhanced diagnosis of ischemic heart disease. *J Am Coll Cardiol* 1990;15:318-29.
30. Watson DD. Quantitative SPECT techniques. *Semin Nucl Med* 1999;XXIX:192-203.

CORRECTION

In the article "Acute chest pain imaging in the outpatient setting" (March/April 2000;7:190-1) by Rosenblatt et al, the two parts of Figure 1 were transposed. The top figure should be on the bottom, and the bottom figure should be on the top; the figure legend remains unchanged. Please see the correct figure below.

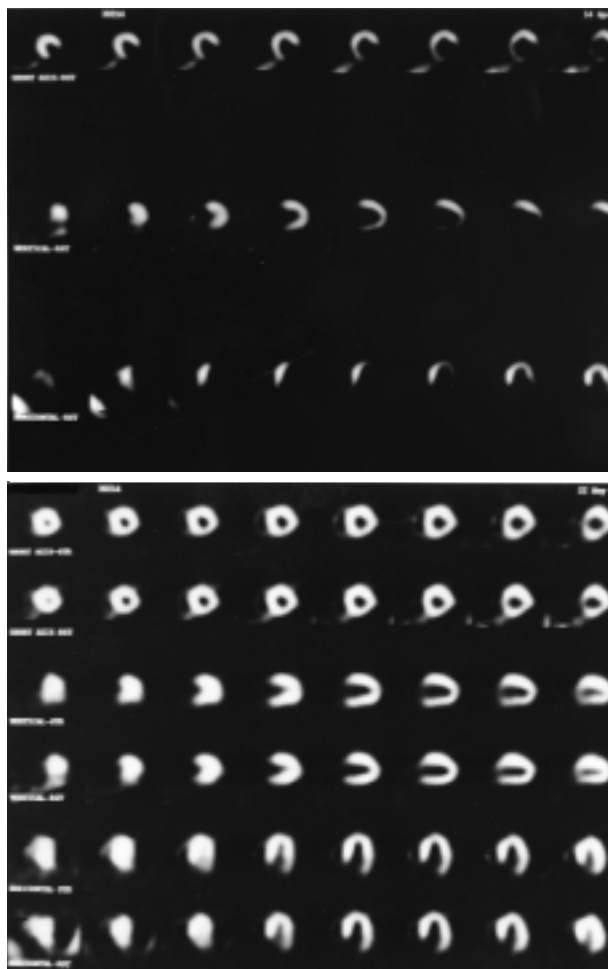


Figure 1. *Top*, Tc-99m sestamibi SPECT myocardial perfusion images of patient with pain at rest demonstrating large, severe lateral defect. *Bottom*, Exercise Tc-99m sestamibi SPECT image of same patient 1 month after successful percutaneous revascularization with a same-day, rest-stress protocol. The large, lateral defect has nearly completely normalized on both stress and rest images.