



Fournier's Gangrene in a Patient with Type 2 Diabetes Mellitus Treated with Empagliflozin: A Case Report

Yasunori Nagano¹ · Naomi Kashiwagi Yakame¹ · Hisae Aoki² · Tamaki Yamakawa³ · Naoko Iwahashi Kondo²

Published online: 18 October 2019
© The Author(s) 2019

Abstract

Sodium-glucose cotransporter-2 (SGLT2) inhibitors have been reported as possibly associated with Fournier's gangrene (FG). This case report describes a 34-year-old Japanese man who was diagnosed with FG after the administration of empagliflozin for type 2 diabetes mellitus (T2DM). He presented with pain and swelling in the perineum and groin 142 days after initiating empagliflozin. The clinical features, laboratory data, and computed tomographic findings were consistent with FG. Surgical drainage and debridement of necrotic tissues were performed immediately after admission to our hospital. The patient had no complications of diabetes before the onset of FG. Glycemic management was good at the time of FG onset. This case suggests a possible association between empagliflozin and FG. We report a case of FG in a patient during a period of good glycemic management following treatment with empagliflozin. We recommend further awareness of this relationship and suggest the need for additional research.

Key Points

Fournier's gangrene (FG) is a severe polymicrobial infection that results in necrosis of the perineal and genital fasciae, with rapid progression and a high mortality rate.

It is important to know that sodium-glucose cotransporter-2 (SGLT2) inhibitors, including empagliflozin, may potentially cause FG even when a patient has good glycemic management.

Introduction

Fournier's gangrene (FG), named by Jean Alfred Fournier in 1883 [1], is a severe polymicrobial infection that results in necrosis of the perineal and genital fasciae. The common symptoms of FG are perianal or genital pain, redness, swelling, and skin necrosis, followed by gangrenous changes. Reports of case series have indicated rapid progression and 20% mortality rates for patients with FG [2]. Alcoholism, liver or kidney failure, cancer, obesity, and smoking are known risk factors [3]. Diabetes mellitus is a comorbid condition in approximately 50% of cases. Early diagnosis is important, and standard management consists of broad-spectrum antibiotics, resuscitation, and aggressive debridement [4].

The mechanism of action of sodium glucose cotransporter-2 (SGLT2) inhibitors in the treatment of type 2 diabetes mellitus (T2DM) involves the inhibition of SGLT2 in the proximal convoluted tubule to prevent the reabsorption of glucose and facilitate its excretion in urine. As glucose is excreted, its plasma levels fall, leading to improvements in all glycemic parameters [5].

Several SGLT2 inhibitors, including dapagliflozin, canagliflozin, and empagliflozin, are already available in many countries. Empagliflozin is one of the SGLT2 inhibitors currently approved for use in adult patients with T2DM as an adjunct to diet and exercise to improve glycemic control [6].

✉ Yasunori Nagano
nagano8931@sanraku.or.jp

¹ Department of Pharmacy, Sanraku Hospital, 2-5 Kandasurugadai, Chiyoda-ku, Tokyo 1018326, Japan

² Department of Surgery, Sanraku Hospital, 2-5 Kandasurugadai, Chiyoda-ku, Tokyo 1018326, Japan

³ Department of Endocrinology and Metabolism, Sanraku Hospital, 2-5 Kandasurugadai, Chiyoda-ku, Tokyo 1018326, Japan

Similar to other SGLT2 inhibitors, empagliflozin is associated with a higher rate of genital infections and urinary tract infections [7].

Several case reports have suggested that SGLT2 inhibitors may be implicated as a possible cause of FG [8–13]. Here, we describe a Japanese male who developed FG during empagliflozin treatment.

Case Presentation

A 34-year-old Japanese man was referred to our hospital with a 3-day history of pain and swelling in the perineum and the groin. His T2DM had been moderately well managed for 2 years.

A general physician prescribed sitagliptin 50 mg/day, glibenclamide 2.5 mg/day, and empagliflozin 10 mg/day to this patient as first-line antidiabetic therapy. At 19 days after initiating these medications, the glibenclamide was increased to 5 mg/day. He had no complications of diabetes. His body mass index was 28 kg/m² and he was otherwise in good general health and had no history of genital or urinary infections. He had no significant past medical history and received no concomitant medications. He had a history of smoking but not of alcohol intake.

The first episode of pain in the perineal region occurred 142 days after medication initiation. On admission to our hospital, his body temperature was 38.0 °C. He was not in a state of shock and vital signs were stable: blood pressure 137/76 mmHg, heart rate 120 beats per min, and respiratory rate 13 breaths per min. Skin redness, induration, swelling, and tenderness were observed in the perineum, the scrotum, and the left inguinal region. There was no urinary tract infection or trauma.

Routine laboratory data revealed a white blood cell count $21.7 \times 10^9/L$, C-reactive protein 41 mg/L, and glycosylated hemoglobin 6.5% (per the National Glycohemoglobin Standardization Program). Table 1 summarizes the patient's baseline clinical data. Computed tomography scan of the lower abdomen and pelvis revealed findings consistent with FG (Fig. 1).

The patient underwent emergency surgery under general anesthesia, consisting of incision, debridement, and drainage. Intravenous administration of meropenem 3 g/day and clindamycin 1800 mg/day was initiated. The patient's antibiotic was changed from a combination of meropenem and clindamycin to intravenous vancomycin 2 g/day because methicillin-resistant *Staphylococcus aureus* (MRSA) was cultured from the resected tissue on the second postoperative day (Fig. 2).

We suspected empagliflozin as a possible cause of FG because the pharmacist in our hospital knew about the warning regarding the association of SGLT2 inhibitors with an

Table 1 Laboratory data at baseline

Clinical parameter (units)	Value
WBC (count/L)	21.7×10^9
RBC (count/L)	544×10^{10}
Hb (g/L)	165
Hct (/L)	0.48
Plt (count/L)	282×10^9
Na (mEq/L)	136
Cl (mEq/L)	100
K (mEq/L)	4.0
CRP (mg/L)	41
Alb (g/L)	45
AST (U/L)	12
ALT(U/L)	18
T-Bil (μmol/L)	15.4
CK (U/L)	97
Amy (U/L)	73
BUN (mg/dL)	5.7
Cr (mg/dL)	69
Glu (mg/dL)	6.1
HbA _{1c} , per NGSP (%)	6.5

Alb albumin, *ALT* alanine transaminase, *Amy* amylase, *AST* aspartate transaminase, *BUN* blood urea nitrogen, *CK* creatinine phosphokinase, *Cl* chloride, *Cr* creatinine, *CRP* C-reactive protein, *Glu* glucose, *Hb* hemoglobin, *HbA_{1c}* glycosylated hemoglobin, *Hct* hematocrit, *K* potassium, *Na* sodium, *NGSP* National Glycohemoglobin Standardization Program, *Plt* platelets, *RBC* red blood cell, *T-Bil* total bilirubin, *WBC* white blood cell

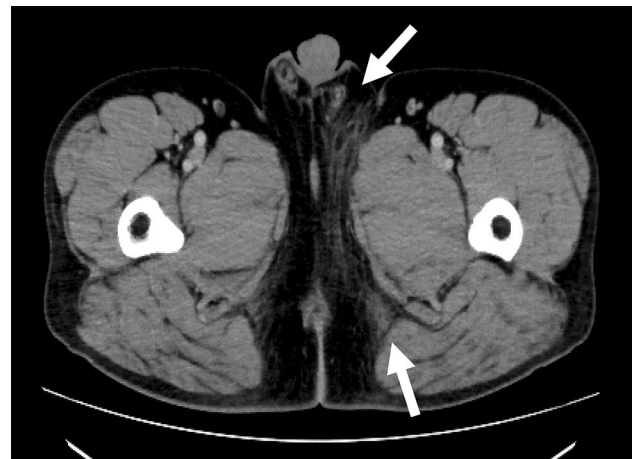


Fig. 1 A computed tomography scan of the lower abdomen and pelvis showing pathologic Fournier's gangrene. Evidence of fat stranding and gas (arrow) in the perineum, the scrotum, and the left inguinal region

increased risk of FG issued by the US FDA [13], although FG is not cited in the prescribing information for empagliflozin in Japan. In addition, assessment using the Naranjo Adverse

Days after the initiation of medications	Surgery			Discharged				
	Day 1	Day 19	Day 143	Day 1	Day 3	Day 9	Day 21	Day 41
Postoperative day			Day 1	Day 3	Day 9	Day 21	Day 41	
<i>Medications for diabetes mellitus</i>								
sitagliptin	50 mg/day				50 mg/day			
glibenclamide	2.5 mg/day	5 mg/day						
empagliflozin	10 mg/day							
metformin						500 mg/day		
insulin sliding scale			2 IU/day					
<i>Intravenous antibiotics</i>								
meropenem			3 g/day					
clindamycin			1800 mg/day					
vancomycin				2 g/day				
<i>Laboratory data</i>								
HbA _{1c} , per NGSP (%)	—	—	6.5	—	—	—	—	6.9
Glu (mmol/L)	—	—	6.1	6.5	7.1	6.3	7.2	
WBC (count/L)	—	—	21.7×10 ⁹	9.5×10 ⁹	7.5×10 ⁹	10×10 ⁹	9.5×10 ⁹	
CRP (mg/L)	—	—	41	103	12	0.4	0.2	

Fig. 2 Clinical course and laboratory data. *CRP* C-reactive protein, *Glu* glucose, *HbA_{1c}* glycated hemoglobin, *NGSP* National Glycohemoglobin Standardization Program, *RBC* red blood cell, *WBC* white blood cell

Drug Reaction Probability Scale indicated a probable relationship (score of 5) between FG and empagliflozin therapy in the patient [14]. However, “improvement after drug withdrawal”, as an axis of the Naranjo scale, cannot be considered truly informative, as factors other than the suspected drug, such as surgery and antibiotic treatment, may have caused resolution of the adverse event in this case. Furthermore, alternative causes could have contributed to the onset of FG, including diabetes, smoking habits, and obesity. Given this information, we downgraded the Naranjo scale score from “probable” to “possible”.

Postoperatively, the medications for T2DM were discontinued, and insulin injections were started according to a sliding scale. Sitagliptin 50 mg/day was restarted 9 days after surgery, and metformin 500 mg/day was started 21 days after surgery. The patient’s wounds healed gradually. He was discharged from the hospital 41 days after surgery and continued his treatment for T2DM.

Discussion

Empagliflozin was approved by the FDA in 2014 [6]. Similar to other SGLT2 inhibitors, empagliflozin is associated with high rates of genital infections, urinary tract infections, and lower limb amputations [7, 15]. In this case, we propose that empagliflozin facilitated the occurrence and/or progression of FG. Our rationale is outlined as follows.

First, 12 case reports (seven men and five women) of FG after treatment with SGLT2 inhibitors have been documented from May 2013 to May 2018, although FG is a rare disease [13]. SGLT2 inhibitors are associated with an increased risk for FG, according to an analysis performed by the FDA and an initial warning they issued in 2018 about the potential association [13]. A search of the FDA Adverse Event Reporting System (FAERS) database until January 2019 as per Bersoff-Matcha et al. [16], identified 55 cases of FG in patients receiving SGLT2 inhibitors between March 2013 and January 2019. In comparison, 19 cases of FG associated with other antihyperglycemic agents were identified between 1984 and 2019 [16]. There have been many previous reports of FG associated with SGLT2 inhibitors, compared with few reports of associations with

Table 2 Summary of 6 case reports of Fournier's gangrene associated with SGLT2 inhibitor treatment

Reference	Age, sex	SGLT2 inhibitor	Time to onset (weeks)	HbA1c (%)	Renal and hepatic function	Comorbidities	Concurrent drug therapy
Cecilia-Chi et al. [8]	67, male	Dapagliflozin	3	10.8	Unknown	Obesity	Unknown
Kumar et al. [9]	41, male	Empagliflozin	49	11.2	Unknown	Obesity, thrush	Metformin
Omer et al. [10]	60, male	Dapagliflozin	28	Unknown	Unknown	Unknown	Unknown
Onder et al. [11]	64, male	Dapagliflozin	42	7.4	BUN: 17 mmol/L; Cr: 162 μ mol/L; ALT: 21 U/L	Obesity	Premixed insulin, vildagliptin, metformin
Ghada et al. [12]	57, male	Empagliflozin	2	Unknown	Unknown	Obesity, peripheral neuropathy, Hashimoto's hypothyroidism	Glipizide, metformin, linagliptin
Our patient	34, male	Empagliflozin	20	6.5	BUN: 5.7 mmol/L; Cr: 69 μ mol/L; ALT: 18 U/L	Obesity	Sitagliptin, glibenclamide

SGLT2 sodium-glucose cotransporter-2, HbA1c glycated hemoglobin, BUN blood urea nitrogen, Cr creatinine, ALT alanine transaminase

other hypoglycemic drugs. However, there have been too few cases to be sure that FG is related to the use of SGLT2 inhibitors.

We searched the medical literature in PubMed and Google Scholar between May 2013 and July 2019 with the keywords SGLT2 inhibitors and Fournier's gangrene and retrieved five reports that were described in detail. Each report described a patient who developed FG after commencing treatment with dapagliflozin and empagliflozin (Table 2) [8–12]. Most of those cases involved patients who had T2DM that was reasonably or poorly managed [glycated hemoglobin (HbA_{1c}) > 7.0%], unlike our patient, who had good glycemic management (HbA_{1c} < 7.0%) at the time of FG onset. Thus, the risk for development of FG remains despite good glycemic management with SGLT2 inhibitors.

Second, the pharmacologically induced increased urinary glucose concentration associated with SGLT2 inhibitors might provide a favorable growth environment for otherwise commensal genital microorganisms and could potentially increase the risk for FG, although the mechanism through which SGLT2 inhibitors causes FG is unclear. It cannot be ruled out that the pharmacological effects of SGLT2 inhibitors, such as the stimulation of urinary glucose excretion, play a role in the onset of FG.

The patient in our case had T2DM, was obese, and had a smoking habit, all of which are factors that elevate the risk for FG [3]. These risk factors may have contributed to the development of FG during empagliflozin treatment, although there was no predisposing genital infection or urinary intervention.

Concomitant medications, such as sitagliptin and glibenclamide, may not have been related to the development and/or progression of FG in this case. The inflammatory reactions did not increase in severity when sitagliptin was

discontinued and subsequently reintroduced. To the best of our knowledge, a relationship between glibenclamide and FG has not been reported. The mechanism of action of glibenclamide consists of inhibition of the ATP-sensitive K⁺ channels, which leads to depolarization of the cells, insulin secretion, and a subsequent decrease in plasma glucose levels [17]. Although the mechanism by which FG occurs is unknown, given the pharmacological mechanism of glibenclamide, it may be less likely to be associated with FG. It can be conjectured that the FG likely developed in response to empagliflozin and not glibenclamide.

We report a case of FG in a patient whose glycemic management was good as a result of empagliflozin treatment. In addition, this is the first confirmed case report in Japan of FG that may have been related to treatment with SGLT2 inhibitors.

Conclusion

If FG is suspected in a patient receiving SGLT2 inhibitors, we recommend ceasing that medication and immediately starting combination treatment with broad-spectrum antibiotics and surgical debridement.

Author Contributions YN designed the study and wrote the manuscript. NIK contributed to the analysis and interpretation of the data and assisted in the preparation of the manuscript. NKY, HA, and TY contributed to data collection and interpretation and critically reviewed the manuscript. All authors approved the final version of the manuscript and agree to be accountable for all aspects of the work and to ensure that questions related to the accuracy or integrity of any part of the work are appropriately investigated and resolved.

Compliance with Ethical Standards

Funding No sources of funding were used to assist in the preparation of this case report.

Conflict of Interest Yasunori Nagano, Naomi Kashiwagi Yakame, Hisae Aoki, Tamaki Yamakawa, and Naoko Iwahashi Kondo have no conflicts of interest that are directly relevant to the content of this case report.

Patient Consent Written informed consent was obtained from the patient for the publication of this case report and any accompanying images. A copy of the written consent may be requested for review from the corresponding author.

Ethics Approval All procedures performed in studies involving human participants were in accordance with the ethical standards of the institutional and/or national research committee Ministry of Health, Labor and Welfare and with the 1964 Helsinki declaration and its later amendments or comparable ethical standards.

Open Access This article is distributed under the terms of the Creative Commons Attribution-NonCommercial 4.0 International License (<http://creativecommons.org/licenses/by-nc/4.0/>), which permits any noncommercial use, distribution, and reproduction in any medium, provided you give appropriate credit to the original author(s) and the source, provide a link to the Creative Commons license, and indicate if changes were made.

References

1. Fournier JA. Gangrène foudroyante de la verge (overwhelming gangrene). *Sem Med.* 1883. *Dis Colon Rectum.* 1988;31:984–8.
2. McCormack M, Valiquette AS, Ismail S. Fournier's gangrene: a retrospective analysis of 26 cases in a Canadian hospital and literature review. *Can Urol Assoc J.* 2015;9:E407–10.
3. Sorensen MD, Krieger JN. Fournier's gangrene: epidemiology and outcomes in the general US population. *Urol Int.* 2016;97:249–59.
4. Yanar H, Taviloglu K, Ertekin C, Guloglu R, Zorba U, Cabioglu N, Baspinar I. Fournier's gangrene: risk factors and strategies for management. *World J Surg.* 2006;30:1750–4.
5. Riser Taylor S, Harris KB. The clinical efficacy and safety of sodium glucose cotransporter-2 inhibitors in adults with Type 2 diabetes mellitus. *Pharmacotherapy.* 2013;33:984–99.
6. U.S. Food and Drug Administration. JARDIANCE 10 mg (Labeling-Medication Guide). In: Drugs@FDA. https://www.accessdata.fda.gov/drugsatfda_docs/label/2016/204629s0081b1.pdf. Accessed 22 July 2019.
7. Zinman B, Wanner C, Lachin JM, Fitchett D, Bluhmki E, Hantel S, Mattheus M, Devins T, Johansen OE, Woerle HJ, Broedl UC, Inzucchi SE, EMPA-REG OUTCOME Investigators. Empagliflozin, cardiovascular outcomes, and mortality in type 2 diabetes. *N Engl J Med.* 2015;373:2117–28.
8. Cecilia-Chi WC, Lim-Tio S. Fournier's syndrome: a life threatening complication of SGLT2 inhibition in poorly controlled diabetes mellitus. In: Presented at: ADS ADEA Annual Scientific Meeting; August 24–26, 2016. Abstract no. 265.
9. Kumar S, Costello AJ, Colman PG. Fournier's gangrene in a man on empagliflozin for treatment of type 2 diabetes. *Diabet Med.* 2017;34:1646–8.
10. Omer T, Dharan SS, Adler A. Sodium-glucose cotransporter 2 (SGLT-2) inhibitor dapagliflozin and Fournier's gangrene: a life threatening severe adverse outcome: case report. *Diabet Med.* 2018;35:100.
11. Onder CE, Gursoy K, Kuskonmaz SM, Kocer U, Culha C. Fournier's gangrene in a patient on dapagliflozin treatment for type 2 diabetes. *J Diabetes.* 2019;11:348–50.
12. Elshimy G, Correa R, Alsayed M, Jyothinagaram S. Early presentation of a rare complication of sodium-glucose cotransporter-2 inhibitors 10 days after initiation: case report and literature review. *Cureus.* 2019;11(7):e5173. <https://doi.org/10.7759/cureus.5173>.
13. U.S. Food and Drug Administration. FDA warns about rare occurrences of a serious infection of the genital area with SGLT2 inhibitors for diabetes. In: Drug safety and Availability. 2019. <https://www.fda.gov/drugs/drug-safety-and-availability/fda-warns-about-rare-occurrences-serious-infection-genital-area-sgl2-inhibitors-diabetes>. Accessed 22 July 2019.
14. Naranjo CA, Busto U, Sellers EM, Sandor P, Ruiz I, Roberts EA, Janecek E, Domecq C, Greenblatt DJ. A method for estimating the probability of adverse drug reactions. *Clin Pharmacol Ther.* 1981;30:239–45.
15. Khouri C, Cracowski JL, Roustit M. SGLT-2 inhibitors and the risk of lower-limb amputation: is this a class effect? *Diabetes Obes Metab.* 2018;20:1531–4.
16. Bersoff-Matcha SJ, Chamberlain C, Cao C, Kortepeter C, Chong WH. Fournier gangrene associated with sodium-glucose cotransporter-2 inhibitors. *Ann Intern Med.* 2019;170:764–9.
17. Luzi L, Pozza G. Glibenclamide: an old drug with a novel mechanism of action? *Acta Diabetol.* 1997;34:239–44.