



Pediatric Neuroanesthesia — a Review of the Recent Literature

Dorottya Szántó¹ · Judit Gál¹ · Béla Tankó¹ · Péter Siró¹ · Zsuzsa Jakab¹ · Péter Luterán¹ · Béla Fülesdi¹ · Csilla Molnár¹

Accepted: 20 September 2022 / Published online: 6 October 2022
© The Author(s) 2022

Abstract

Purpose of Review Pediatric neuroanesthesia is a growing and still challenging subspecialty. The purpose of this review is to summarize the available knowledge and highlight the most recent findings of the literature on non-traumatic pediatric neuroanesthesia care.

Recent Findings Several human studies have confirmed the negative effects of early life anesthetic exposure. According to non-human studies, volatile anesthetics and opioids contribute to tumor progression. Tranexamic acid effectively reduces peri-operative blood loss; it is used in several different doses without standard guidelines on optimal dosing. The widespread use of neuromonitoring has necessitated the development of anesthetic methods that do not affect neuromuscular transmission.

Summary Pediatric anesthetic neurotoxicity, management of intraoperative bleeding, and the effect of anesthesia on tumor growth are among the most debated and researched topics in pediatric neuroanesthesia. The lack of evidence and clinical guidelines underlines the need for further large prospective studies in this subspecialty.

Keywords Pediatric neuroanesthesia · Craniosynostosis · Brain tumor · Scoliosis surgery · Epilepsy surgery · Procedural sedation

Introduction

In recent years, the number of pediatric neurosurgical interventions has increased worldwide. As a result, a new subspecialty of anesthesia, pediatric neuroanesthesia, was born. In this challenging field, neurophysiological differences between children and adults must be taken into account. This review aims to summarize the basic physiological and pharmacological aspects and anesthetic management of the most common non-traumatic neurosurgical procedures and to highlight the most recent findings of the literature in this field.

Search Strategy

We reviewed the relevant literature, focusing mainly on research from the last 5 years, using PubMed. Our search terms were: “pediatric anesthesia,” “pediatric neuroanesthesia,” “neurotoxicity,” “intraoperative bleeding,” “brain tumor,” “spinal cord tumor,” “craniosynostosis,” “epilepsy surgery,” “hydrocephalus,” “meningomyelocele,” “tethered cord,” “selective dorsal rhizotomy,” and “procedural sedation.”

Physiological Characteristics in Pediatric Neuroanesthesia

For safe pediatric neuroanesthesia practice, the difference between pediatric and adult neurophysiology must be taken into account. Compared to adults, cerebral blood flow (CBF) is lower in newborns and premature infants, while it is higher in children between 6 months and 3 years of age [1]. Cerebral metabolic rate of oxygen (CMRO₂) is closely connected to CBF in children, as it is in adults. Newborns have lower CMRO₂ and CBF causing relative

This article is part of the *Topical Collection on Patient Safety in Anesthesia*

✉ Dorottya Szántó
dorottyaszanto22@gmail.com

¹ Department of Anesthesiology and Intensive Care, Faculty of Medicine, University of Debrecen, Debrecen, Hungary

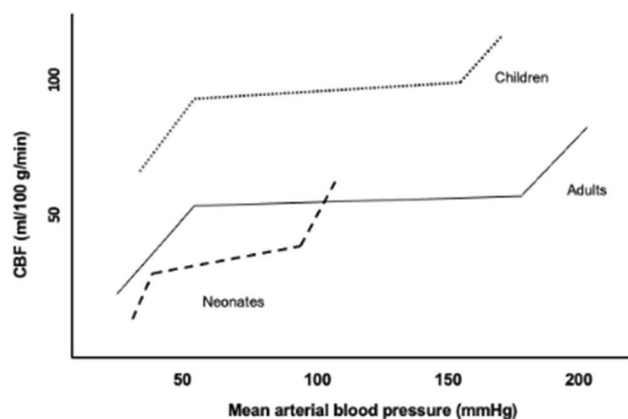


Fig. 1 Differences in cerebral autoregulation in adults, children, and neonates

Table 1 The effects of the most commonly used anesthetic agents on cerebral physiology

Agent	CMR	CBF	CBV	ICP
Isoflurane	↓↓↓	↑	↑↑	↑↑
Desflurane	↓↓↓	↑	↑	↑
Sevoflurane	↓↓↓	↑	↑	↑
Nitrous oxide	↓	↑	→	↑
Propofol	↓↓↓	↓↓↓↓	↓↓	↓↓
Benzodiazepines	↓↓	↓	↓	↓
Ketamine	→	↑↑	↑↑	↑↑*
Etomidate	↓↓↓	↓↓	↓↓	↓↓
Opioids	→	→	→	→
Barbiturates	↓↓↓↓	↓↓↓	↓↓	↓↓↓

↑ increase, ↓ decrease, → no or little change, *CMR* cerebral metabolic rate, *CBF* cerebral blood flow, *CBV* cerebral blood volume, *ICP* intracranial pressure

*Ketamine does not increase ICP when patients are sedated and normocapnia is maintained with ventilation[51, 52]

tolerance of hypoxia. Children over 6 months of age have higher *CMRO₂* than adults [2]. In adults, the cerebrovascular autoregulation maintains stable CBF within a wide range of mean arterial blood pressure and cerebral perfusion pressure (CPP); this range is narrow in neonates and may be affected by ventilation (Fig. 1). Hypoxia and hypercarbia may cause vasodilation leading to increased CBF, while hypocapnia causes vasoconstriction with decreased CBF [3]. Increased CBF, out of the autoregulatory range, can cause intracerebral hemorrhage, while decreased CBF can cause ischemia in the pediatric population [4]. Based on the above, maintenance of normal CBF, normocapnia, and normoxia is essential in pediatric neuroanesthesia. The effects of the most commonly used anesthetic agents on cerebral physiology are summarized in Table 1.

Pediatric Anesthetic Neurotoxicity

Multiple studies on immature animals strengthened the evidence of the neurotoxic effect of general anesthetics. Anesthetics can cause neuronal apoptosis and morphological changes in dendritic and glial cells, resulting in impaired neurocognitive function and abnormal behavior in nonhuman models [5, 6••]. An increasing number of human studies, including the Mayo Anesthesia Safety in Kids (MASK) Study, have also confirmed the negative effects of early life exposure [7••, 8, 9]. Lately, a meta-analysis showed that children with multiple exposures to general anesthesia have a higher risk of neurodevelopmental disorders and the incidence of ADHD was more than twofold as high as in children with any exposure [6••]. There is no evidence that any anesthetic is less likely to cause adverse effects in the human developing brain. Currently, the only possible way to lower the risk of neuronal damage is to reduce unnecessary anesthetic exposure, especially between the third trimester and 2–3 years of age (“vulnerable time window”) [10].

Anesthesia for Hydrocephalus and Neural Tube Defect Surgeries

Pediatric hydrocephalus is a condition characterized by an abnormal accumulation of cerebrospinal fluid (CSF) within the ventricles of the brain, commonly caused by intraventricular hemorrhage in premature infants. These patients are at risk of developing intracranial hypertension and resultant impairments in cerebral hemodynamics and metabolism. Patients often require neurosurgical placement of a CSF diversion system, such as ventriculo-subgaleal shunt, ventricular access devices (VAD), or ventriculo-peritoneal shunt. All surgical procedures are performed under general anesthesia in an operating room. Bedside placement of VADs under local anesthesia in the neonatal intensive care unit is a well-tolerated, low-risk procedure. Using local anesthesia over general anesthesia is preferred because anesthesia-induced hypotension can be prevented and hypoxia associated with intubation and extubation does not occur; the risk associated with patient transport through the hospital to the operating room is avoided [11].

Encephalocele is a rare congenital cranial dysraphism when the neural tube does not fully close. It can be associated with microcephaly due to the herniation of the cranial contents into an extracranial sac. Hydrocephalus is also a common comorbidity. To prevent postoperative CSF leak, a ventriculo-peritoneal shunt is often inserted, before

definitive surgery. Encephalocele is treated surgically by removing any nonfunctioning brain tissue and CSF, moving functional tissue back into the skull, and relieving fluid pressure in the head. During the perioperative period, such patients need specialized anesthetic care for dealing with difficult tracheal intubation, unusual positioning, associated congenital anomalies, hypothermia, electrolyte abnormalities, and cardiorespiratory disturbances. The patient should be positioned carefully to prevent compression of the sac, which can lead to raised ICP or, even, rupture. Large amounts of CSF drainage during surgery may lead to bradycardia, electrolyte imbalance, or cardiac arrest [12].

Meningomyelocele is also a neural tube defect, the most serious form of spina bifida, in which the backbone and spinal canal do not close fully before birth. It is the commonest congenital anomaly of the central nervous system that often contributes to the development of hydrocephalus and causes serious developmental disability at later ages. It requires early surgical repair in the first few postpartum days to prevent infection and further damage to the spinal cord. The majority of patients develop Chiari II malformation, which may lead to compression of the cervical cord and brainstem during manipulation to secure the airway. Proper positioning of the neonates is important, as direct pressure on the exposed neural placode may lead to an increase in intracranial pressure. During surgery intraoperative neuromonitoring is used to identify neurological structures and prevent neurological damage (see the section on scoliosis) [13, 14].

Anesthesia for Craniosynostosis Surgeries

Craniosynostosis is a condition characterized by premature fusion of the cranial suture(s). In 80% of the cases premature fusion affects only one suture, it is also known as isolated craniosynostosis. Those children are otherwise healthy, without any comorbidity. In 20% of the cases, craniosynostosis is associated with abnormalities like Crouzon, Apert, Pfeiffer, or other syndromes, and their consequences. Elevated intracranial pressure and hydrocephalus are more frequent in the case of syndromic craniosynostosis [15]. Timing of elective surgery is controversial but usually performed at 3–6 months of age. In this period of life, the bones are soft and easy to reshape. If the surgery is done later, between 6 and 12 months of age, increased blood volume is an advantage with less transfusion need. In the case of syndromic craniosynostosis, cardiac status has to be evaluated [16]. Surgical techniques can vary from strip craniectomy to total vault remodeling. Reduced temporomandibular joint movement, fused cervical spines, or facial abnormalities may lead to difficult airway management. Obstructive sleep apnea (OSA) may occur in 50% of

multisutural and syndromic cases leading to difficult intubation and extubation. Anesthesia induction with volatile agents has the advantage to minimize the risk of sudden airway loss. Patients are frequently operated on in prone position or modified prone position or supine position. The main risks are intraoperative hypothermia, massive bleeding requiring transfusion, and venous air embolism (VAE). Low core temperature can lead to coagulopathy, requiring massive transfusion. It is challenging to estimate the exact blood loss because most of the wasted blood goes to the surgical drapes and surrounding area. A recent study showed that early fibrinogen replacement according to fibrin-based thromboelastometry control significantly decreases the transfusion need in the settings of craniosynostosis surgery [17]. According to this data, fibrinogen level control before the surgery is advocated. Tranexamic acid (TXA) is frequently used to decrease intraoperative blood loss during pediatric neurosurgery. Very recent studies established the exact dose of TXA in the case of craniosynostosis surgery. These studies showed that the loading dose of 10 mg/kg, followed by 5–10 mg/kg/h, may reduce the transfusion need by two-thirds without any side effects [18••]. The incidence of VAE varies according to the literature and may be up to 82% in the case of craniosynostosis surgery. In the case of pediatric neurosurgery, it may remain without clinical signs, but a precordial Doppler and sudden drop of end tidal carbon dioxide may help to diagnose it. The neurosurgeon has to be informed immediately when VAE is assumed [19]. In infants, assessing pain is challenging, and pain management is an underestimated problem. A scalp nerve block with 0.25% levobupivacaine (1 ml/kg) and epinephrine can reduce the postoperative pain mainly in the first 24 h. The use of nonsteroidal antiinflammatory drugs (NSAIDs) is controversial, as they can facilitate postoperative bleeding. Oversedation with high-dose opioids should be avoided especially in the case of OSA [20].

Anesthesia for Pediatric Brain Tumor Surgeries

Brain tumors are the most common solid tumors in children and the leading cause of childhood cancer-related death [21]. About 60 to 70% of all pediatric brain tumors develop in the infratentorial compartment, and the remaining 30 to 40% of tumors are supratentorial in origin [22]. Symptoms are often nonspecific, such as headache, nausea, vomiting, ataxia, asthenia, seizures, walking, speech, or visual disorders. Acute onset may happen due to the blockage of the cerebrospinal fluid outflow or stroke [23]. Tumors located near the hypothalamic-pituitary area are associated with an increased risk of hormonal dysfunction, including growth hormone, thyrotropic hormone, and adrenocorticotropic

hormone deficiency. Consequently, in these cases, preoperative and postoperative serum hormone level measurement is recommended.

Recently, anesthetics have received attention for their potential effect on tumor growth. Unlike adults, where anesthesia is required mainly for surgical procedures, most children with cancer require sedation or general anesthesia for diagnostic, noninvasive, and minimally invasive procedures as well. This is evidence that pediatric patients with cancer are highly exposed to general anesthetics during their treatment, highlighting the importance of the effect of anesthetics on tumor cells in this population. In vitro studies suggest that anesthetics and analgesics might have an impact on tumor growth, angiogenesis, metastasis formation, and anti-tumor immunity. Volatile anesthetics and opioids can contribute to cancer cell survival, metastasis formation, inflammation, and immunosuppression. Local anesthetics and propofol have been associated with anticancer effects. Although there is insufficient clinical data to recommend the use of one anesthetic over another, future studies may determine the relevance of tumor-specific anesthesia care [24•].

Although surgical resection is the cornerstone of management, it carries significant risks and potential morbidity. According to a recent retrospective study, the most common intraoperative complications are brain stem handling (sudden bradycardia with or without hypotension), massive blood loss, brain swelling, VAE, hypotension, and post-extubation seizure [25]. Intraoperative bleeding is a prominent concern in pediatric brain surgery. Because of the nature of the procedure and the highly vascularized anatomical structures, a significant amount of blood loss may occur, which frequently requires allogeneic blood transfusion (ABT). Vassal et al. reported that age at surgery < 4 years, duration of surgery > 270 min, and preoperative hemoglobin < 12.2 mg/dl were factors independently associated with the need for intraoperative ABT during craniotomy for brain tumor removal in children [26]. The use of TXA is recommended to be considered for all pediatric patients undergoing high blood loss surgery. Higher doses of TXA are more effective in decreasing bleeding, although side effects, such as seizures, are likely dose-related, therefore it is important to avoid unnecessarily high plasma concentrations during administration [5]. Based on the pharmacokinetics of TXA, Goobie et al. recommend a dosing regimen of between 10 and 30 mg/kg loading dose followed by 5 to 10 mg/kg/h maintenance infusion rate for pediatric surgery [27••].

Several studies have demonstrated that moderate-to-severe pain is common in patients after major craniotomy. Inadequate pain control leads to anxiety and hypertension which may increase intracranial pressure or cause bleeding. Opioids, nonopioid analgesics, and local anesthetics (scalp block or local infiltration) are used in pain control [28]. Zhao et al. recommend the addition of dexamethasone

to ropivacaine for preemptive incision-site infiltration to prolong postoperative analgesia [29]. Studies have also demonstrated that the anesthetic used intraoperatively may affect post-craniotomy pain, with inhalational anesthesia associated with higher opioid need [28].

Awake Brain Surgery (ABS) in Children

ABS is a special type of intracranial tumor resection procedure. Awake craniotomy with direct cortical stimulation and mapping is the gold standard for resection of lesions near eloquent brain areas. This procedure maximizes the extent of resection while minimizing the risk of neurological damage. Two main types of anesthetic techniques are present in the literature, while nighter has demonstrated any superiority in children: asleep-awake-asleep and conscious sedation, both of them are supplemented with scalp block. ABS in children is strongly limited by their maturity and the fact that only 30–40% of childhood brain tumors are supratentorial, mainly diagnosed in the first 2 years of life, where awake craniotomy is not viable [30]. Age limit is a debatable aspect of ABS. While it has been previously considered unfeasible in children under 10 years of age, in a recent retrospective observational study, ABS was successfully performed at the age of 7 years. In that study, data of 28 children were processed, and the median age was 14 years. The majority of children were managed with the asleep-awake-asleep technique, the most commonly administered drug combination was propofol with remifentanyl and during the asleep phases, the airway was secured with a laryngeal mask. The rates of failure (3.3%) and unsuccessful mapping (3.4%) were comparable to adults [31]. Due to the limited available data, no recommendation exists about the best anesthetic approach or drug combinations for awake craniotomy in the pediatric population.

Anesthesia for pediatric epilepsy surgeries

Epilepsy is a condition of at least 2 unprovoked seizures. The seizures can originate from a distinct part of the brain (partial seizures with or without seconder generalization) or the whole brain has an increased vulnerability to abnormal synchronization (generalized seizures). With proper pharmacotherapy in most patients, good control of the seizures can be obtained; however, 15–40% of the epilepsy cases are pharmaco-resistant [32]. In these patients, surgical intervention can relieve their symptoms. In the case of partial seizures, the identification and the safe removal of the epileptogenic focus lead to the best result. When there is no single well-defined focus, the spreading of the activity can be limited by surgical intervention (subpial incisions, callosotomy)

or the increase of the endogenous antiepileptic function of the brain can reduce seizure severity and frequency (vagal nerve stimulation, deep brain stimulation). Callosotomy and hemispherectomy are the most invasive procedures in epilepsy surgery reserved for the most malignant intractable epilepsy syndromes.

Antiepileptic drugs should be continued during the perioperative period to ensure therapeutic levels, barring adjustments needed to facilitate localization of seizure foci [33]. Generalized intraoperative seizures must be treated. The management of intraoperative seizures consists of local ice-cold water irrigation, propofol, or benzodiazepine boluses.

The electrophysiological localization of the epileptogenic focus consists of electroencephalography (EEG), magnetoencephalography (MEG), invasive electrocorticography (ECoG), and sometimes direct cortical stimulation. For the ECoG grid, EEG electrodes are put on the dura for the localization of the spike activity. Awake techniques provide the best result, as widely used anesthetic drugs have major, dose-dependent effects on electrophysiological examinations. Sevoflurane and isoflurane at low dose can increase the epileptic activity producing an ictal-like record. Nitrous oxide attenuates epileptic activity as well. At low doses, propofol increases spike activity, while at anesthetic doses, it suppresses epileptogenic activity. Twenty minutes after terminating propofol infusion, the result of electrocorticography is not affected. Benzodiazepines suppress spike activity; therefore, they should be avoided. Opioids at normal doses have no or minimal effect on spike activity, and short-acting opioids at large doses have a significant epileptogenic effect. Dexmedetomidine has minimal effect on ECoG, so it is particularly useful for sedation during non-painful examinations [34]. Direct cortical stimulation is needed when the epileptogenic focus is close to the eloquent areas of the brain, and when the focus is close to the speaking centers, awake craniotomy is needed.

When the patient has pharmaco-resistant epilepsy and lesionectomy is not possible, the implantation of a seizure modifying device (vagal-nerve stimulation, deep brain stimulation) can reduce seizure frequency. For vagal nerve stimulation, an electrode is attached to the left vagal nerve at the cervical part. Possible complications of this procedure are jugular vein or carotid artery injury and bradycardia. Deep brain stimulation of the globus pallidus and subthalamic nucleus can reduce seizure frequency. Insertion of electrodes requires an alert and cooperative patient and this is its major limitation, especially in the pediatric population (see the section on ABS). Callosotomy and hemispherectomy are the most invasive procedures in epilepsy surgery. Callosotomy can prevent the spreading of epileptic activity to the contralateral hemisphere. Hemispherectomy is reserved for the most malignant intractable epilepsies (Sturge-Weber disease, Rasmussen encephalitis, infantile hemiplegia). These

operations commonly cause severe blood loss and complex coagulation disorders. Anesthesia should be prepared for the monitoring and treatment of these complications [35].

During the postoperative period, the prolonged post-narcotic state is quite frequent, the elevated risk for a brain hemorrhage, and the revisit of the antiepileptic therapy needs extra attention.

Anesthesia for Scoliosis Surgery

Scoliosis is a condition of abnormal lateral spinal curvature. The severity of the deformation is evaluated on spinal radiographs using the Cobb angle. Scoliosis has three main types in terms of etiology: congenital, idiopathic, and neuromuscular. Congenital scoliosis is a result of either failure of vertebral segmentation or failure of vertebral formation. Idiopathic scoliosis begins manifesting itself in adolescence between 10 and 16 years of age. Infantile onset idiopathic scoliosis has the most serious prognosis. Neuromuscular scoliosis is caused by neurological or degenerative muscular diseases. The aim of the surgery is to prevent long-term disability and correct deformity.

Scoliosis surgeries take several hours while the patient is in the prone position. When positioning the patient, all pressure points should be padded carefully. The neck should be maintained in the neutral forward position using a special helmet with foam cushion. Temperature monitoring and warming of all infusions and a forced air warming system are recommended.

Intraoperative spinal neuromonitoring is an effective method to predict an increased risk of adverse neurological sequelae and is considered standard care during scoliosis surgery. Contemporary methods for monitoring spinal function are somatosensory and motor evoked potentials that provide information about the integrity of neural pathways. Somatosensory evoked potential (SSEP) reflects activation of the sensory cortex following electrical stimulation of peripheral nerves in the lower extremities and is thought to be less sensitive in detecting new motor deficits. Magnetic evoked potential (MEP) is more sensitive in identifying spinal injuries however highly vulnerable to all inhalational anesthetics. Anesthesia is commonly performed with a propofol-based total intravenous anesthesia or target-controlled infusion and the depth of anesthesia is monitored with processed encephalogram. Muscle relaxants are not used after intubation so as not to compromise myoneural transmission of MEP. Furthermore, factors like hypoxia, hypercarbia, hypothermia, and hypotension can also negatively influence signal transduction [36].

Scoliosis surgeries are commonly associated with massive blood loss and often require ABT. Children with neuromuscular scoliosis suffer greater intraoperative blood

loss than children with idiopathic scoliosis [37]. The use of intraoperative cell salvage has become a standard of blood conservation. Intraoperative conventional coagulation tests or viscoelastic coagulation monitoring may help to identify consumptive coagulopathy rapidly. The administration of TXA decreases the need of ABT. The most frequently used dose is 10–30 mg/kg in bolus followed by 1–5 mg/kg/h; however, it was demonstrated that higher doses of TXA (loading dose: 30–50 mg/kg, maintenance dose: 1–5 mg/kg/h) reduce intraoperative blood loss more effectively [38].

Scoliosis surgery is associated with intense pain in the postoperative period. The pain management is typically opioid-based patient-controlled analgesia. The opioid-sparing effect of NSAIDs and paracetamol are well described. Pre- and postoperative administration of gabapentin has been shown to decrease opioid use. Dexamethasone administered at the time of induction of anesthesia has also been shown to reduce opioid consumption [39]. A bolus of 0.5 mg/kg ketamine administered before incision, followed by an intraoperative infusion of 0.2 mg/kg/h, is also an effective regime for reducing postoperative pain [40].

Anesthesia for Other Pediatric Spinal Surgeries

Tethered cord is located in the lumbosacral region, tethering of the spinal cord to inelastic structures is characteristic of this abnormality. It has a wide range of symptoms including pain of the lower extremities, back pain, incontinence, sensory or motor deficits, and sacral hair tufts. Anesthesiologists have to be prepared for other congenital anomalies, such as vertebral defects, cardiovascular anomalies, and tracheoesophageal fistula. During the operation, the patient is in the prone position. SSEP and MEP are used to monitor neurophysiological function accurately (see the section on scoliosis). Tethered cord releasing surgery has minimal risk of major bleeding. For postoperative pain management, non-opioid analgesics can be used [41].

Selective dorsal rhizotomy is a type of neurosurgical operation which could provide a solution for children suffering from spastic cerebral palsy. Similar to tethered cord syndrome, myoneural transmission has to be undisturbed during the surgery, for precise neurophysiological monitoring [42]. The combined use of perioperative dexmedetomidine and NSAIDs may have a similar effect on postoperative pain as opioids [43].

Spinal cord tumors are relatively rare, accounting for 1 to 10% of all pediatric central nervous system tumors. The most frequent spinal cord tumors are intramedullary, among which astrocytomas represent around 60% of tumors. Common symptoms are pain, limb weakness,

sphincter dysfunction, and sensory symptoms. Treatment of spinal cord tumors is based on tumor type, but surgical resection is the mainstay [44]. To monitor neurological function and improve postoperative outcomes, SSEP and MEP are used in these cases as well [45]. Anesthesiologists also have to be prepared for intraoperative bleeding and pro- or antitumor effects of anesthetic and analgesic agents (see the section on brain tumor surgeries).

Procedural Sedation in Pediatric Neuroanesthesia

In recent years, the number of radiological diagnostic procedures has increased [46]. Children undergoing these procedures frequently require sedation to ensure a calm and immobile state while maintaining stable breathing and circulation. Preanesthesia evaluation should be performed to the same standards as for surgery. Several drugs, such as midazolam, fentanyl, ketamine, dexmedetomidine, etomidate, and propofol, are used alone or in combination. Oral midazolam (0.5 mg/kg) is widely used and has several beneficial effects, such as rapid onset and limited duration of action, but has been associated with significant preprocedural anxiety and emergence delirium. Dexmedetomidine, an alpha-2 agonist, is used both intravenously (2 µg/kg over 10 min, repeated till Ramsay Sedation Scale of 4 was achieved) and intranasally (2.5 µg/kg) [46]. Propofol-based pediatric sedation (2–3 mg/kg of propofol, and a continuous propofol infusion at a rate of 100 to 200 µg/kg/min) is associated with a high risk of adverse events [47]. The advantage of ketofol (mixture of ketamine and propofol, ratio 1:1–1:10) is that sub-dissociative dosing of ketamine has analgesic and sympathomimetic effects, while propofol provides deep sedation and antiemetic effect with more rapid recovery. For pediatric use, a weight-based dose of 0.5 mg/kg of ketamine and 0.5 mg/kg of propofol is administered every 2 to 5 min, as needed [48, 49].

Neuro-interventional radiology includes the treatment of central nervous system (CNS) diseases using endovascular access for delivering therapeutic agents, including both drugs and devices to the CNS. Most common procedures include embolization of cerebral and dural arteriovenous malformations, coiling of cerebral aneurysms, thrombolysis, and balloon dilatation of vessels. General anesthesia with controlled ventilation is usually preferred [50]. Nonoperating room anesthesia may be challenging as these patients also require adequate resuscitation, maintenance of cerebral perfusion pressure, and control of intracranial pressure. After the procedure, patients should be monitored until complete recovery from anesthesia.

Conclusion

Pediatric neuroanesthesia is a growing and still challenging field. The lack of evidence and clinical guidelines highlights the need for further large prospective studies in this subspecialty.

Funding Open access funding provided by University of Debrecen.

Compliance with Ethical Standards

Conflict of Interest The authors declare they have no conflict of interest.

Human and Animal Rights and Informed Consent This article does not contain any studies with human or animal subjects performed by any of the authors.

Open Access This article is licensed under a Creative Commons Attribution 4.0 International License, which permits use, sharing, adaptation, distribution and reproduction in any medium or format, as long as you give appropriate credit to the original author(s) and the source, provide a link to the Creative Commons licence, and indicate if changes were made. The images or other third party material in this article are included in the article's Creative Commons licence, unless indicated otherwise in a credit line to the material. If material is not included in the article's Creative Commons licence and your intended use is not permitted by statutory regulation or exceeds the permitted use, you will need to obtain permission directly from the copyright holder. To view a copy of this licence, visit <http://creativecommons.org/licenses/by/4.0/>.

References

Papers of particular interest, published recently, have been highlighted as:

- Of importance
- Of major importance

1. Rhee CJ, da Costa CS, Austin T, Brady KM, Czosnyka M, Lee JK. Neonatal cerebrovascular autoregulation. *Pediatr Res*. 2018;84(5):602–10. <https://doi.org/10.1038/s41390-018-0141-6>.
2. Kalita N, Goswami A, Goswami P. Making pediatric neuroanesthesia safer. *J Pediatr Neurosci*. 2017;12(4):305–12. https://doi.org/10.4103/jpn.JPN_173_17.
3. Meng L, Gelb AW. Regulation of cerebral autoregulation by carbon dioxide. *Anesthesiology*. 2015;122(1):196–205. <https://doi.org/10.1097/ALN.0000000000000506>.
4. Beausoleil TP, Janaillac M, Barrington KJ, Lapointe A, Dehaes M. Cerebral oxygen saturation and peripheral perfusion in the extremely premature infant with intraventricular and/or pulmonary haemorrhage early in life. *Sci Rep*. 2018;8(1):6511. Published 2018 Apr 25. <https://doi.org/10.1038/s41598-018-24836-8>
5. Lamsal R, Rath GP. Pediatric neuroanesthesia. *Curr Opin Anaesthesiol*. 2018;31(5):539–43. <https://doi.org/10.1097/ACO.0000000000000630>.
6. •• Reighard C, Junaid S, Jackson WM, et al. Anesthetic exposure during childhood and neurodevelopmental outcomes: a systematic review and meta-analysis. *JAMA Netw Open*. 2022;5(6):e2217427. Published 2022 Jun 1. <https://doi.org/10.1001/jamanetworkopen.2022.17427> (Findings of this recent meta-analyses support the hypothesis that associations between anesthetic exposure during childhood and subsequent neurodevelopmental deficits differ based on neurodevelopmental domain.)
7. •• Warner DO, Chelonis JJ, Paule MG, et al. Performance on the Operant Test Battery in young children exposed to procedures requiring general anaesthesia: the MASK study. *Br J Anaesth*. 2019;122(4):470–9. <https://doi.org/10.1016/j.bja.2018.12.020>. (This widely cited article suggests that multiple, but not single, childhood anesthetic exposures are associated with a pattern of changes in specific neuropsychological domains associated with behavioral and learning difficulties.)
8. Zaccariello MJ, Frank RD, Lee M, et al. Patterns of neuropsychological changes after general anaesthesia in young children: secondary analysis of the Mayo Anesthesia Safety in Kids study. *Br J Anaesth*. 2019;122(5):671–81. <https://doi.org/10.1016/j.bja.2019.01.022>.
9. Gleich SJ, Shi Y, Flick R, et al. Hypotension and adverse neurodevelopmental outcomes among children with multiple exposures to general anesthesia: subanalysis of the Mayo Anesthesia Safety in Kids (MASK) Study. *Paediatr Anaesth*. 2021;31(3):282–9. <https://doi.org/10.1111/pan.14106>.
10. Walkden GJ, Pickering AE, Gill H. Assessing Long-term Neurodevelopmental outcome following general anesthesia in early childhood: challenges and opportunities. *Anesth Analg*. 2019;128(4):681–94. <https://doi.org/10.1213/ANE.00000000000004052> ([published correction appears in *Anesth Analg*. 2020 Feb;130(2):e44]).
11. van Lindert EJ, Liem KD, Geerlings M, Delye H. Bedside placement of ventricular access devices under local anaesthesia in neonates with posthaemorrhagic hydrocephalus: preliminary experience. *Childs Nerv Syst*. 2019;35(12):2307–12. <https://doi.org/10.1007/s00381-019-04361-3>.
12. Mahajan C, Rath GP, Bithal PK, Mahapatra AK. Perioperative management of children with giant encephalocele: a clinical report of 29 cases. *J Neurosurg Anesthesiol*. 2017;29(3):322–9. <https://doi.org/10.1097/ANA.0000000000000282>.
13. Gisi G, Boran OF. Anesthesia management during meningo-myelocele repair alongside motor-evoked potentials in a newborn and a small infant. *Childs Nerv Syst*. 2020;36(12):3053–7. <https://doi.org/10.1007/s00381-020-04579-6>.
14. Singh D, Rath GP, Dash HH, Bithal PK. Anesthetic concerns and perioperative complications in repair of myelomeningocele: a retrospective review of 135 cases. *J Neurosurg Anesthesiol*. 2010;22(1):11–5. <https://doi.org/10.1097/ANA.0b013e3181bb44a9>.
15. Thomas K, Hughes C, Johnson D, Das S. Anesthesia for surgery related to craniosynostosis: a review. Part 1 *Paediatr Anaesth*. 2012;22(11):1033–41. <https://doi.org/10.1111/j.1460-9592.2012.03927.x>.
16. Mathews F, Shaffer AD, Georg MW, et al. Airway anomalies in patients with craniosynostosis. *Laryngoscope*. 2019;129(11):2594–602. <https://doi.org/10.1002/lary.27589>.
17. Haas T, Spielmann N, Restin T, et al. Higher fibrinogen concentrations for reduction of transfusion requirements during major paediatric surgery: a prospective randomised controlled trial. *Br J Anaesth*. 2015;115(2):234–43. <https://doi.org/10.1093/bja/aev136>.
18. •• Goobie SM, Staffa SJ, Meara JG, et al. High-dose versus low-dose tranexamic acid for paediatric craniosynostosis surgery: a double-blind randomised controlled non-inferiority trial. *Br J Anaesth*. 2020;125(3):336–45. <https://doi.org/10.1016/j.bja.2020.05.054>. (The important finding of this article is that low-dose TXA, determined by pharmacokinetic modeling, is

- non-inferior to high-dose TXA in decreasing blood loss and transfusion in children.)**
19. Arts S, Delye H, van Lindert EJ, Blok L, Borstlap W, Driessen J. Evaluation of anesthesia in endoscopic strip craniectomy: a review of 121 patients. *Paediatr Anaesth*. 2018;28(7):647–53. <https://doi.org/10.1111/pan.13414>.
 20. Festa R, Tosi F, Pusateri A, et al. The scalp block for postoperative pain control in cranosynostosis surgery: a case control study. *Childs Nerv Syst*. 2020;36(12):3063–70. <https://doi.org/10.1007/s00381-020-04661-z>.
 21. Pollack IF, Agnihotri S, Broniscer A. Childhood brain tumors: current management, biological insights, and future directions. *J Neurosurg Pediatr*. 2019;23(3):261–73. <https://doi.org/10.3171/2018.10.PEDS18377>.
 22. Nejat F, El Khashab M, Rutka JT. Initial management of childhood brain tumors: neurosurgical considerations. *J Child Neurol*. 2008;23(10):1136–48. <https://doi.org/10.1177/0883073808321768>.
 23. Cojocaru E, Mihăilă D, Leon-Constantin MM, et al. Update in pediatric primary brain tumors - from histology to genetically defined tumors. *Rom J Morphol Embryol*. 2019;60(3):761–7.
 24. ●Cata JP, Owusu-Agyemang P, Kapoor R, Lonnqvist PA. Impact of anesthetics, analgesics, and perioperative blood transfusion in pediatric cancer patients: a comprehensive review of the literature. *Anesth Analg*. 2019;129(6):1653–1665. <https://doi.org/10.1213/ANE.0000000000004314> **(This article discusses the impact of anesthetics, analgesics, and perioperative blood transfusions on pediatric cancer progression.)**
 25. Mishra N, Rath GP, Rajagopalan V, Doddamani R, Chaturvedi A. Perioperative management of pediatric brain tumors: a retrospective analysis. *Neurol India*. 2022;70(3):1095–101. <https://doi.org/10.4103/0028-3886.349578>.
 26. Vassal O, Desgranges FP, Tosetti S, et al. Risk factors for intraoperative allogeneic blood transfusion during craniotomy for brain tumor removal in children. *Paediatr Anaesth*. 2016;26(2):199–206. <https://doi.org/10.1111/pan.12810>.
 27. ●●Goobie SM, Faraoni D. Tranexamic acid and perioperative bleeding in children: what do we still need to know? *Curr Opin Anaesthesiol*. 2019;32(3):343–52. <https://doi.org/10.1097/ACO.0000000000000728>. **(This article highlights the current pediatric indications and contraindications and dosage recommendations of TXA.)**
 28. Endencia MCS, Piñera MGC, Sy Su KMC. postoperative craniotomy pain management in pediatric patients: a systematic review. *J Clin Anesth Pain Manag*. 2021;5(1):205–13. <https://doi.org/10.36959/377/355>.
 29. Zhao C, Zhang N, Shrestha N, Liu H, Ge M, Luo F. Dexamethasone as a ropivacaine adjuvant to pre-emptive incision-site infiltration analgesia in pediatric craniotomy patients: a prospective, multicenter, randomized, double-blind, controlled trial. *Paediatr Anaesth*. 2021;31(6):665–75. <https://doi.org/10.1111/pan.14178>.
 30. Huguët L, Lohkamp LN, Beuriat PA, et al. Psychological aspects of awake brain surgery in children-interests and risks. *Childs Nerv Syst*. 2020;36(2):273–9. <https://doi.org/10.1007/s00381-019-04308-8>.
 31. Alcaraz García-Tejedor G, Echániz G, Strantzias S, et al. Feasibility of awake craniotomy in the pediatric population. *Paediatr Anaesth*. 2020;30(4):480–9. <https://doi.org/10.1111/pan.13833>.
 32. Koh JL, Egan B, McGraw T. Pediatric epilepsy surgery: anesthetic considerations. *Anesthesiol Clin*. 2012;30(2):191–206. <https://doi.org/10.1016/j.anclin.2012.05.001>.
 33. Wong BJ, Agarwal R, Chen MI. Anesthesia for the pediatric patient with epilepsy and minimally invasive surgery for epilepsy. *Curr Anesthesiol Rep*. 2021;11:233–42. <https://doi.org/10.1007/s40140-021-00457-2>.
 34. Larkin CM, O'Brien DF, Maheshwari D. Anaesthesia for epilepsy surgery. *BJA Educ*. 2019;19(12):383–9. <https://doi.org/10.1016/j.bjae.2019.08.001>.
 35. Thudium MO, von Lehe M, Wessling C, Schoene-Bake JC, Soehle M. Safety, feasibility and complications during resective pediatric epilepsy surgery: a retrospective analysis. *BMC Anesthesiol*. 2014;14:71. Published 2014 Aug 18. <https://doi.org/10.1186/1471-2253-14-71>
 36. Strike SA, Hassanzadeh H, Jain A, et al. Intraoperative neuromonitoring in pediatric and adult spine deformity surgery. *Clin Spine Surg*. 2017;30(9):E1174–81. <https://doi.org/10.1097/BSD.0000000000000388>.
 37. Jia R, Li N, Xu BY, Zhang W, Gu XP, Ma ZL. Incidence, influencing factors, and prognostic impact of intraoperative massive blood loss in adolescents with neuromuscular scoliosis: a STROBE-compliant retrospective observational analysis. *Medicine (Baltimore)*. 2017;96(11):e6292. <https://doi.org/10.1097/MD.00000000000006292>.
 38. Raman T, Varlotta C, Vasquez-Montes D, Buckland AJ, Errico TJ. The use of tranexamic acid in adult spinal deformity: is there an optimal dosing strategy? *Spine J*. 2019;19(10):1690–7. <https://doi.org/10.1016/j.spinee.2019.06.012>.
 39. Lee CS, Merchant S, Chidambaran V. Postoperative pain management in pediatric spinal fusion surgery for idiopathic scoliosis. *Paediatr Drugs*. 2020;22(6):575–601. <https://doi.org/10.1007/s40272-020-00423-1>.
 40. Ricciardelli RM, Walters NM, Pomerantz M, et al. The efficacy of ketamine for postoperative pain control in adolescent patients undergoing spinal fusion surgery for idiopathic scoliosis. *Spine Deform*. 2020;38(3):433–40. <https://doi.org/10.1007/s43390-020-00073-w>.
 41. Lee JM, Gee E, Liu CA. Anesthesia for innovative pediatric surgical procedures. *Anesthesiol Clin*. 2020;38(3):493–508. <https://doi.org/10.1016/j.anclin.2020.06.004>.
 42. Abou Al-Shaar H, Imtiaz MT, Alhalabi H, Alsubaie SM, Sabbagh AJ. Selective dorsal rhizotomy: a multidisciplinary approach to treating spastic diplegia. *Asian J Neurosurg*. 2017;12(3):454–65. <https://doi.org/10.4103/1793-5482.175625>.
 43. Pao LP, Zhu L, Tariq S, et al. Reducing opioid usage: a pilot study comparing postoperative selective dorsal rhizotomy protocols [published online ahead of print, 2019 Nov 22]. *J Neurosurg Pediatr*. 2019;1–6. <https://doi.org/10.3171/2019.9.PEDS19398>
 44. Wilson PE, Oleszek JL, Clayton GH. Pediatric spinal cord tumors and masses. *J Spinal Cord Med*. 2007;30 Suppl 1(Suppl 1):S15–20. <https://doi.org/10.1080/10790268.2007.11753963>.
 45. Guo L, Li Y, Han R, Gelb AW. The correlation between recordable MEPs and motor function during spinal surgery for resection of thoracic spinal cord tumor. *J Neurosurg Anesthesiol*. 2018;30(1):39–43. <https://doi.org/10.1097/ANA.0000000000000386>.
 46. Ghai B, Jain K, Saxena AK, Bhatia N, Sodhi KS. Comparison of oral midazolam with intranasal dexmedetomidine premedication for children undergoing CT imaging: a randomized, double-blind, and controlled study. *Paediatr Anaesth*. 2017;27(1):37–44. <https://doi.org/10.1111/pan.13010>.
 47. Lee JR, Lee JH, Lee HM, Kim N, Kim MH. Independent risk factors for adverse events associated with propofol-based pediatric sedation performed by anesthesiologists in the radiology suite: a prospective observational study. *Eur J Pediatr*. 2021;180(5):1413–22. <https://doi.org/10.1007/s00431-020-03916-w>.

48. Grunwell JR, Travers C, Stormorken AG, et al. Pediatric procedural sedation using the combination of ketamine and propofol outside of the emergency department: a report from the Pediatric Sedation Research Consortium. *Pediatr Crit Care Med*. 2017;18(8):e356–63. <https://doi.org/10.1097/PCC.0000000000001246>.
49. Iqbal AU, Shuster ME, Baum CR. Ketofol for procedural sedation and analgesia in the pediatric population. *Pediatr Emerg Care*. 2022;38(1):28–33. <https://doi.org/10.1097/PEC.0000000000002599>.
50. Chaudhary N, Eljovich L, Martinez M, et al. Pediatric diagnostic cerebral angiography: practice recommendations from the SNIS Pediatric Committee. *J Neurointerv Surg*. 2021;13(8):762–6. <https://doi.org/10.1136/neurintsurg-2021-017389>.
51. Zeiler FA, Teitelbaum J, West M, Gillman LM. The ketamine effect on intracranial pressure in nontraumatic neurological illness. *J Crit Care*. 2014;29(6):1096–106. <https://doi.org/10.1016/j.jcrc.2014.05.024>.
52. Zeiler FA, Teitelbaum J, West M, Gillman LM. The ketamine effect on ICP in traumatic brain injury. *Neurocrit Care*. 2014;21(1):163–73. <https://doi.org/10.1007/s12028-013-9950-y>.

Publisher's Note Springer Nature remains neutral with regard to jurisdictional claims in published maps and institutional affiliations.