



# A Randomized Study of the Impact of a Corneal Pre-Cut During Cataract Surgery on Wound Architecture and Corneal Astigmatism

Birgit Doeller · Nino Hirsenschall · Maria Fichtenbaum ·  
Phuong-Mai Nguyen · Ralph Varsits · Oliver Findl

Received: December 21, 2020 / Accepted: February 23, 2021 / Published online: March 11, 2021  
© The Author(s) 2021

## ABSTRACT

**Introduction:** The aim of the current study was to assess the effect of a 600- $\mu\text{m}$  corneal pre-cut on wound architecture and its impact on surgically induced astigmatism. The images were acquired intraoperatively and postoperatively with high-resolution spectral-domain optical coherence tomography (SD-OCT).

**Methods:** This study included patients scheduled for cataract surgery. Preoperatively, optical biometry and corneal topography were performed (IOL Master 500 and Atlas 9000, both Carl Zeiss Meditec AG, Germany). The first eye randomly received a 600- $\mu\text{m}$  corneal pre-cut during cataract surgery, or a single-plane stab-incision and the second eye received the other incision technique. Incision architecture was assessed intraoperatively using a continuous intraoperative optical coherence tomography (iOCT) device (ReScan 700, Carl Zeiss Meditec

AG, Germany) at three time points: after the incision, after irrigation/aspiration and after intraocular lens (IOL) implantation. Additionally, OCT (Spectralis, Heidelberg Engineering, Germany) measurements were performed 1 h, 1 week and 1 month postoperatively.

**Results:** Forty eight eyes of 24 patients were analysed. The pre-cut group and the stab-incision group had a significant decrease in wound thickness from the 1-h to the 1-week measurement ( $p = 0.022$  and  $p = 0.001$ ). Corneal astigmatism showed a vector difference from preoperatively to the 1-week measurement of 0.48 D (SD,  $\pm 0.27$ ) in the stab incision group and 0.49 D (SD,  $\pm 0.24$ ) in the stab incision group. No significant differences were found between the groups.

**Conclusion:** To our knowledge, this was the first study which compared the wound alterations in pre-cut and stab-incision groups.

**Trial Registration:** NCT02155270.

---

B. Doeller (✉) · N. Hirsenschall · M. Fichtenbaum ·  
P.-M. Nguyen · R. Varsits · O. Findl (✉)  
VIROS-Vienna Institute for Research in Ocular  
Surgery, a Karl Landsteiner Institute, Hanusch  
Hospital, Vienna, Austria  
e-mail: b.doeller@viros.at

O. Findl  
e-mail: oliver@findl.at

N. Hirsenschall · O. Findl  
Moorfields Eye Hospital NHS Foundation Trust,  
London, UK

**Keywords:** Cataract surgery; Corneal  
astigmatism; Pre-cut; Stab-incision

## Key Summary Points

### Why carry out this study

A corneal pre-cut during cataract surgery makes the wound safer owing to the self-sealing effect and, as a consequence, a reduced risk of leakage through the wound.

The aim of this study was to assess the effect of a 600- $\mu\text{m}$  corneal pre-cut on wound architecture, biomechanical properties of the cornea and surgically induced astigmatism. The images were acquired intraoperatively and postoperatively with high-resolution spectral-domain optical coherence tomography (SD-OCT).

### What was learned from this study

Intraoperative wound gaping occurred more often in the stab-incision group, but this effect was more pronounced intraoperatively and not visible postoperatively.

There was no relevant difference concerning surgically induced astigmatism between the groups.

## DIGITAL FEATURES

This article is published with digital features, including a summary slide, to facilitate understanding of the article. To view digital features for this article, go to <https://doi.org/10.6084/m9.figshare.14077385>.

## INTRODUCTION

The most popular and widely accepted incision method in cataract surgery is a clear corneal incision (CCI) [1, 2]. CCI was shown to have faster recovery times compared to other incision techniques [3]. However, this technique also

has a few disadvantages, which include the possible occurrence of irregular astigmatism or rarely insufficient wound closure [4].

In 1994 Langerman described a hinged incision with a 0.75-mm-deep corneal pre-cut, followed by a corneal tunnel. This concept implies that a hinged CCI makes the wound safer owing to the self-sealing effect and, as a consequence, a reduced risk of leakage through the wound [3, 5].

Corneal wound architecture in cataract surgery has been assessed using optical coherence tomography (OCT) in the past but, to our knowledge, intraoperative assessment of the wound architecture has not been published. OCT scans allow a three-dimensional depiction of wound architecture and a better understanding for the dynamic changes in wound structure during surgery [6–12].

The aim of the current study was to assess the effect of a 600- $\mu\text{m}$  corneal pre-cut on wound architecture and its impact on surgically induced astigmatism. The images were acquired intraoperatively and postoperatively with high-resolution SD-OCT.

## METHODS

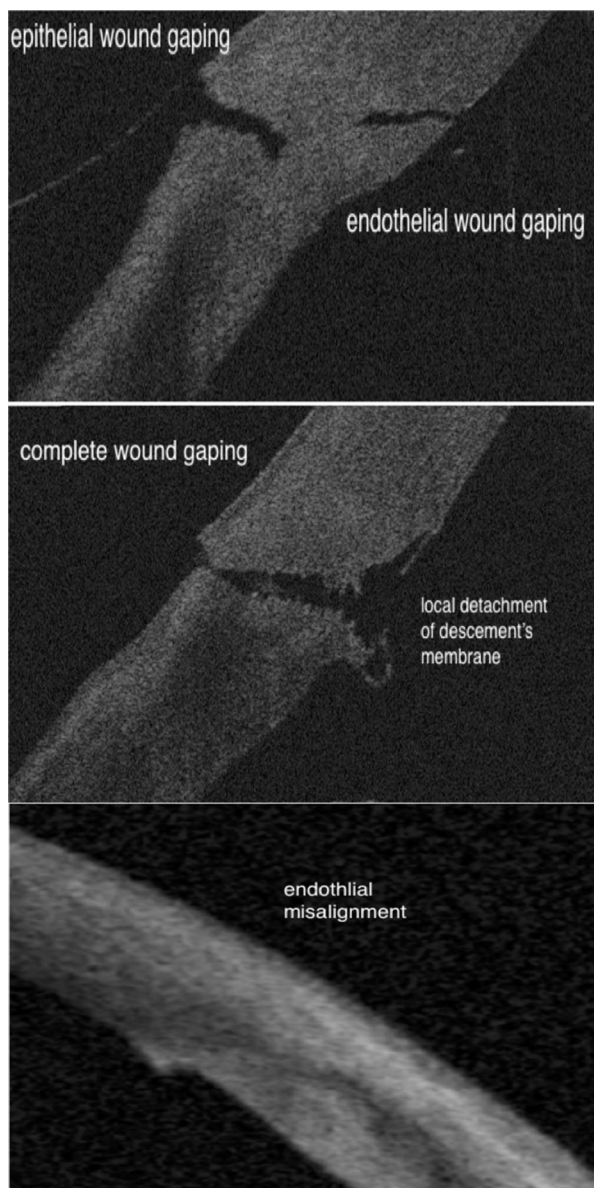
This randomized, patient and observer blinded, study with bilateral comparison included patients scheduled for cataract surgery in both eyes. Exclusion criteria included pregnancy as well as any ophthalmic abnormalities that could compromise the measurements, such as corneal scars, corneal ectasia, previously performed ophthalmic surgery, as well as an age below 21 years.

All the research and measurements followed the tenets of declaration of Helsinki and local ethics committee (Ethics Commission of Vienna) approved the study. Informed consent to participate in the trial was obtained from all patients prior to enrolment (NCT02155270, [www.clinicaltrials.gov](http://www.clinicaltrials.gov)).

Suitable patients were screened on the day of their medical examination 1 week prior to cataract surgery (ophthalmic examination including slit lamp biomicroscopy and retinal examination).

Both eyes of each patient were allocated in a 1:1 ratio to one of two groups using an online randomization tool ([www.randomizer.org](http://www.randomizer.org)). The first eye to be operated on randomly received either a 600- $\mu\text{m}$  corneal pre-cut or a single-plane stab-incision, and the second eye received the other incision technique.

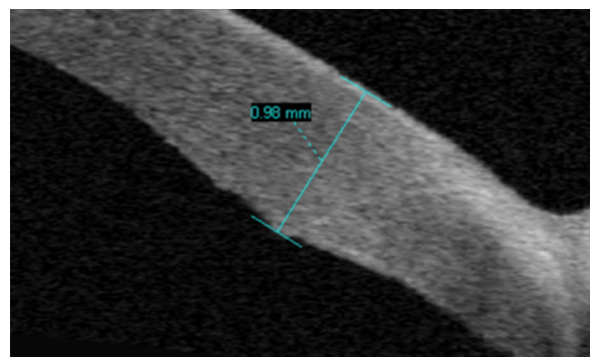
Preoperatively, routine optical biometry (IOLMaster 500) and topography (Atlas 9000, both Carl Zeiss Meditec AG, Germany) measurements were performed. Additionally,



**Fig. 1** OCT images of wound architecture

preoperatively and at 1 week and 1 month postoperatively, autorefractometry (Topcon, Japan) and subjective refraction (ETDRS charts, Precision vision, USA) were assessed and all patients underwent a slit lamp and funduscopy examination. SD-OCT (Spectralis, Heidelberg Engineering) scans of the cornea were performed 1 h, 1 week and 1 month postoperatively. The maximum wound thickness and wound score developed by Calladine and Packard were used for assessment [7]. Outcomes were complete wound gaping, local detachment of Descemet's membrane, epithelial or endothelial wound gaping and endothelial misalignment. Figure 1 shows pictures of the wounds of our patients. One observer (B.D.) assessed the wound score and measured the maximum wound thickness. Therefore, the thickest part of the wound was measured within the OCT image. All measurements were manually measured. Figure 2 shows an example of the measurement of the maximum wound thickness.

All surgeries were performed by the same experienced surgeon (O.F.), who is familiar with both incision techniques. Surgery was performed under topical anaesthesia. In all cases incision location was temporal and size was 2.4 mm with or without a pre-cut using a 600- $\mu\text{m}$  guarded blade (BVI, USA), named 'pre-cut group' or 'stab-incision group'. For both incision types a single bevelled knife was utilized (Xstar® Safety Slit Knife, 2.4 mm Beaver, BVI, USA). Injection of viscoelastic substance (Healon, Johnson & Johnson, USA), capsulorhexis, phacoemulsification, and bimanual



**Fig. 2** Shows an example of the measurement of the maximum wound thickness

irrigation/aspiration (I/A) of cortical material were performed as standard procedure; hydration at the end of the surgery was not done either for the pre-cut or for the stab-incision groups. Incision architecture was assessed intraoperatively using a continuous intraoperative iOCT device (ReScan 700, Carl Zeiss Meditec AG, Germany) after the incision, after I/A and after intraocular lens (IOL) implantation. To guarantee a standardized intraocular pressure the bottle height of the infusion was 30 cm above the patient's eye level and holding a bimanual irrigating handpiece through the left paracentesis, which represents approximately 20 mmHg. After phacoemulsification, corticosteroids (Monodex, Laboratoires Thea, France) as standard regimen were applied. The postoperative standard medication was bromfenac eye-drops (Yellox, Bausch & Lomb, USA) twice a day for 4 weeks.

For statistical analysis Microsoft Excel 14.0 (Microsoft, USA) with a Statplus: Mac Version 5.8.3.8 plug-in (AnalystSoft, USA), and Xlstat 2012 plug-in (Addinsoft, USA) and a Solver plug-in in Excel (Microsoft, USA) was used.

Furthermore, SPSS 21.0 for Mac (IBM, USA) was used for box plots. Missing data observations were excluded from analysis. Descriptive data is always shown as mean, standard deviation (SD) and range.  $P < 0.05$  was considered statistically significant.

## RESULTS

In total, 90 eyes of 45 patients were included. In 21 patients data were missing (9 patients were lost to follow-up as a result of non-compliance, 8 patients had poor image quality intraoperatively on at least one eye, and in 4 cases the intraoperative measurement was not recorded in one eye because of technical issues). The remaining 48 eyes of 24 patients were analysed. Mean age of the remaining patients was 72.4 years (SD 8.9 years) with a range from 43 to 84 years. Of these, 12 were female and 12 male. As a result of randomization, 15 right eyes and nine left eyes received a pre-cut incision. No postoperative complications such as wound leaking or endophthalmitis were observed.

Wound thickness was significantly different between both groups within the first week, but no significant difference was found after 1 month (Table 1).

The wound score including epithelial and endothelial wound gaping, local detachment of Descemet's membrane and endothelial misalignment is shown in Tables 2 and 3. Complete wound gaping after phaco was observed in the stab-incision and pre-cut group in 26% and 9%, respectively ( $p = 0.06$ ). After lens implantation this was the case in 26% versus 13%, respectively ( $p = 0.15$ ). Postoperatively no wound gaping was observed.

Surgically induced astigmatism was low in both groups. The corneal astigmatism difference vector from preoperative to 1 week postoperatively in both groups is shown in Fig. 3. None of these was statistically significant (Table 4). For the IOL-Master 500 measurements there was a mean absolute difference vector of 0.65 D (SD,  $\pm 0.43$ ) in the stab-incision group from preoperative to the 1-week follow-up and 0.83 D (SD,  $\pm 0.56$ ) from the 1-week to the

**Table 1** Difference of wound thickness in millimetres between both groups within 1 h postoperative, the first week and after 1 month

	Wound thickness difference	
	Pre-cut	Stab-incision
1 h–1 week	103 ( $\pm 123.50$ )	188 ( $\pm 70.78$ )
<i>p</i> value (Mann–Whitney <i>U</i> test)	0.022*	
1 week–1 month	66 ( $\pm 106.41$ )	40 ( $\pm 67.50$ )
<i>p</i> value	0.407	
1 h–1 month	179 ( $\pm 92.22$ )	222 ( $\pm 60.32$ )
<i>p</i> value (Mann–Whitney <i>U</i> test)	0.187	

\*stastically significant

**Table 2** Wound score including epithelial and endothelial wound gaping

	Wound score stab-incision vs. pre-cut					
	Epithelial wound gaping (%)			Endothelial wound gaping (%)		
	Stab-incision	Pre-cut	<i>p</i> value (difference between groups)	Stab-incision	Pre-cut	<i>p</i> value (difference between groups)
Intraop						
After incision	57	83	0.01	65	83	0.08
After phaco	74	91	0.06	74	83	0.34
After IOL implantation	74	87	0.15	57	74	0.09
Postop						
1 h	4	100	< 0.01	48	50	0.78
1 week	0	0	–	16	32	0.06
1 month	0	0	–	4)	28	< 0.01

**Table 3** Wound score including local detachment of Descemet’s membrane and endothelial misalignment

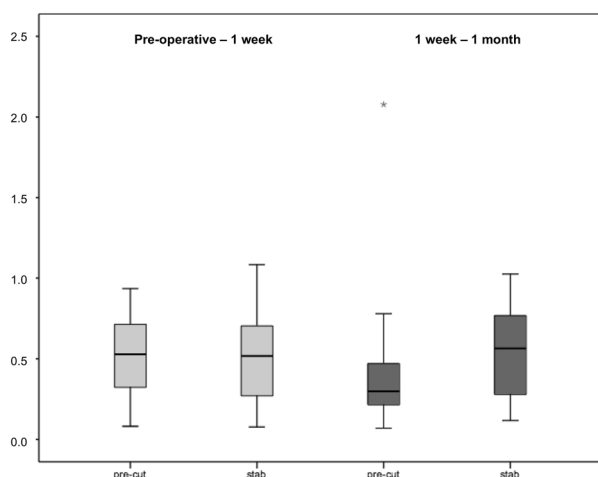
	Local detachment of Descemet’s membrane (%)			Endothelial misalignment (%)		
	Stab-incision	Pre-cut	<i>p</i> value (difference between groups)	Stab-incision	Pre-cut	<i>p</i> value (difference between groups)
Intraop						
After incision	65	26	< 0.01	30	52	0.02
After phaco	70	78	0.36	13	22	0.22
After IOL implantation	70	78	0.36	13	13	1.0
Postop						
1 h	39	45	0.53	57	45	0.30
1 week	10	15	0.46	65	68	0.71
1 month	0	0	–	74	50	0.01

1-month examination. In the pre-cut group the mean absolute change was 0.51 D (SD, ± 0.34) from the preoperative to the 1-week measurement and 0.65 D (SD, ± 0.37) for the 1-week to the 1-month follow-up.

The results of the topography measurements showed in the stab-incision group a difference vector of 0.48 D (SD, ± 0.27) from the preoperative to the 1-week examination and 0.53 D

(SD, ± 0.25) in the 1-week to the 1-month follow-up. In the pre-cut group there was a mean induced astigmatism of 0.49 D (SD, ± 0.24) in the preoperative to the 1-week examination and 0.43 D (SD, ± 0.43) in the 1-week to the 1-month follow-up.





**Fig. 3** Corneal astigmatism difference vector from preoperative to 1 week postoperatively in the pre-cut and the stab-incision groups

## DISCUSSION

In this study the influence of a 600- $\mu$ m corneal pre-cut on incision architecture and astigmatism was evaluated. Concerning wound thickness, the pre-cut group showed a significantly lower wound thickness from the 1-h to the 1-week measurement.

In our study the maximum wound thickness and wound score were analysed with a classification system developed by Calladine and Packard [7], including epithelial and endothelial wound gaping, endothelial misalignment, local detachment of Descemet's membrane and complete wound gaping. Our findings showed that complete wound gaping during surgery occurred more often in the stab-incision group.

To our knowledge, this is the first time that intraoperative wound gaping was measured. However, no difference was found at the postoperative follow-ups. We observed that epithelial and endothelial wound gaping, local detachment of Descemet's membrane and endothelial misalignment were more common in the pre-cut group during surgery (after incision, after phaco and after lens implantation). One hour postoperatively epithelial wound gaping was found in all cases of the pre-cut group. This was expected since the outside part of the incision was incised with the 600-micron knife. However, 1 week and 1 month postoperatively, no epithelial wound gaping or local detachment of Descemet's membrane was found in either group. So obviously, the epithelial closure happens in all cases within the first week after surgery. Endothelial wound gaping was more common in the pre-cut group 1 h, 1 week and 1 month postoperatively. This may be due to more distortion of the wound when passing the phaco and I/A tips as well as the injector through the incision. Endothelial misalignment was significantly higher 1 month postoperatively in the stab-incision group. This may be due to slight central "slippage" of the anterior part of the wound in stab incisions, which would be less pronounced with a pre-cut. Calladine and Tanner stated that endothelial misalignment is more common with stromal hydration, which is important for healing and decreasing the risk of endophthalmitis [13].

Surgically induced corneal astigmatism was similar in the stab-incision and the pre-cut groups. Several studies have assessed surgically

**Table 4** Surgically induced astigmatism in both groups using difference vector analysis (preoperative compared to 1 week and 1 week compared to 1 months)

	IOL Master 500		Atlas 9000	
	Stab-incision (D)	Pre-cut (D)	Stab-incision (D)	Pre-cut (D)
Preop-1 week	0.62 ( $\pm$ 0.43)	0.51 ( $\pm$ 0.34)	0.48 ( $\pm$ 0.27)	0.49 ( $\pm$ 0.24)
<i>p</i> value	0.523		0.546	
1 week-1 month	0.83 ( $\pm$ 0.56)	0.65 ( $\pm$ 0.37)	0.53 ( $\pm$ 0.25)	0.43 ( $\pm$ 0.43)
<i>p</i> value	0.351		0.115	

Measurements were taken with the IOL Master 500 and Atlas 9000 (both Carl Zeiss Meditec AG, Germany)

induced astigmatism after different types of small incisions and incision locations [2, 11, 14–16]. Surgically induced astigmatism in our study was low in both groups, which is comparable to recent findings by Aykut et al. [14]. It is also stated that proper wound site plays an important role on low surgically induced astigmatism [11].

In our study the patient population was very small. A larger sample size needs to be considered for further investigations. Another limitation of the study is that some of the parameters assessed are subjective. Like we did, one observer should take all measurements, but it could be worth considering that two observers take the same measurement and compare their results.

## CONCLUSIONS

Wound gaping occurred more often in the stab-incision group, but this effect was more pronounced intraoperatively and not visible post-operatively. There was no relevant difference concerning surgically induced astigmatism between the groups.

## ACKNOWLEDGEMENTS

**Funding.** No funding or sponsorship was received for this study or publication of this article. We thank the participants of the study.

**Authorship.** All named authors meet the International Committee of Medical Journal Editors (ICMJE) criteria for authorship for this article, take responsibility for the integrity of the work as a whole and have given approval for this version to be published.

**Disclosures.** The authors have no affiliations with or involvement in any organization or entity with any financial interest in the subject matter or materials discussed in this manuscript. The authors have no conflict of interest and no fundings to declare for this study. Nino

Hirschall serves as a board member of this journal.

**Compliance with Ethics Guidelines.** All the research and measurements followed the tenets of declaration of Helsinki and local ethics committee (Ethics Commission of Vienna) approved the study. Informed consent to participate in the trial was obtained from all patients prior to enrolment (NCT02155270, [www.clinicaltrials.gov](http://www.clinicaltrials.gov)).

**Data availability.** The datasets generated during and/or analyzed during the current study are available from the corresponding author on reasonable request.

**Open Access.** This article is licensed under a Creative Commons Attribution-NonCommercial 4.0 International License, which permits any non-commercial use, sharing, adaptation, distribution and reproduction in any medium or format, as long as you give appropriate credit to the original author(s) and the source, provide a link to the Creative Commons licence, and indicate if changes were made. The images or other third party material in this article are included in the article's Creative Commons licence, unless indicated otherwise in a credit line to the material. If material is not included in the article's Creative Commons licence and your intended use is not permitted by statutory regulation or exceeds the permitted use, you will need to obtain permission directly from the copyright holder. To view a copy of this licence, visit <http://creativecommons.org/licenses/by-nc/4.0/>.

## REFERENCES

1. Al Mahmood AM, Al-Swailem SA, Behrens A. Clear corneal incision in cataract surgery. Middle East Afr J Ophthalmol. 2014;21:25–31.
2. Vasavada V, Vasavada AR, Vasavada VA, Srivastava S, Gajjar DU, Mehta S. Incision integrity and post-operative outcomes after microcoaxial phacoemulsification performed using 2 incision-dependent systems. J Cataract Refract Surg. 2013;39:563–71.

3. Vass C, Menapace R, Rainer G, Findl O, Steineck I. Comparative study of corneal topographic changes after 3.0 mm beveled and hinged clear corneal incisions. *J Cataract Refract Surg.* 1998;24:1498–504.
4. Buzard KA, Febbraro JL. Transconjunctival corneoscleral tunnel “blue line” cataract incision. *J Cataract Refract Surg.* 2000;26:242–9.
5. Langerman DW. Architectural design of a self-sealing corneal tunnel, single-hinge incision. *JCRS.* 1994;20:84–8.
6. Fine IH, Hoffman RS, Packer M. Profile of clear corneal cataract incisions demonstrated by ocular coherence tomography. *J Cataract Refract Surg.* 2007;33:94–7.
7. Calladine D, Packard R. Clear corneal incision architecture in the immediate postoperative period evaluated using optical coherence tomography. *J Cataract Refract Surg.* 2007;33:1429–35.
8. Dupont-Monod S, Labbe A, Fayol N, Chassignol A, Bourges JL, Baudouin C. In vivo architectural analysis of clear corneal incisions using anterior segment optical coherence tomography. *J Cataract Refract Surg.* 2009;35:444–50.
9. Behrens A, Stark WJ, Pratzler KA, McDonnell PJ. Dynamics of small-incision clear cornea wounds after phacoemulsification surgery using optical coherence tomography in the early postoperative period. *J Cataract Refract Surg.* 2008;24:46–9.
10. Bang JW, Lee JH, Kim JH, Lee DH. Structural analysis of different incision sizes and stromal hydration in cataract surgery using anterior segment optical coherence tomography. *Korean J Ophthalmol.* 2015;29(1):23–30.
11. Schallhorn JM, Tang M, Li Y, Song JC, Huang D. Optical coherence tomography of clear corneal incisions for cataract surgery. *J Cataract Refract Surg.* 2008;34:1561–5.
12. Lyles GW, Cohen KL, Lam D. OCT-documented incision features and natural history of clear corneal incisions used for bimanual microincision cataract surgery. *Cornea.* 2011;30:681–6.
13. Calladine D, Tanner V. Optical coherence tomography of the effects of stromal hydration on clear corneal incision architecture. *J Cataract Refract Surg.* 2009;35:1367–71.
14. Aykut V, Kirgiz A, Gülay B, Celik U. Comparison of pre-incision and single-stepped clear corneal incision in phacoemulsification surgery. *Eur Rev Med Pharmacol Sci.* 2014;18(12):1698–703.
15. Kohnen S, Neuber R, Kohnen T. Effect of temporal and nasal unsutured limbal incisions on induced astigmatism after phacoemulsification. *J Cataract Refract Surg.* 2002;28:821–5.
16. Rodoplu S, Esgin H, Erda N, Alimgil ML. Astigmatic changes after phacoemulsification surgery using superior-right and temporal clear corneal incision. *Türkiye Klinikleri J Ophthalmol.* 2005;14:173–9.