



REVIEW

Laparoscopic Treatment Strategies for Liver Echinococcosis

Li Wan · Tao Wang · Long Cheng · Qianjun Yu

Received: May 8, 2022 / Accepted: May 31, 2022 / Published online: June 25, 2022
© The Author(s) 2022

ABSTRACT

Liver echinococcosis is clinically mainly composed of hepatic cystic echinococcosis (CE) and hepatic alveolar echinococcosis (AE). At present, laparoscopy has been comprehensively applied in the treatment of two types of liver echinococcosis. For hepatic CE treatment, both laparoscopic total pericystectomy and laparoscopic hepatectomy can achieve radical results, but the former is considered the first choice owing to its being more minimally invasive; laparoscopic subtotal pericystectomy and laparoscopic partial pericystectomy can be accepted as complementary options, considering the presence of complicated cysts and the level of laparoscopic technique in remote hospitals; laparoscopic cystectomy is simple, but it is not currently recommended for treatment of hepatic CE owing to poor efficacy and high risk of postoperative complications. For hepatic AE treatment, laparoscopy not only achieves the same radical effect as open surgery in selected patients, but also is more minimally invasive, so it has a better prospect.

Keywords: Echinococcosis; Cystic echinococcosis; Alveolar echinococcosis; Laparoscopy; Laparoscopic surgery

Key Summary Points

With the advancement of laparoscopic techniques, the surgical indications for laparoscopic treatment of hepatic echinococcosis have been further extended and developed

So far, almost all published articles are discussing the feasibility and superiority of laparoscopic treatment of hepatic echinococcosis, ignoring its specific treatment algorithm, which is extremely important for clinical surgeons

In this review, we summarize recent advances in the laparoscopic treatment of two types of liver echinococcosis and focus on their respective therapeutic algorithms from the perspective of surgeons specializing in hepatobiliary surgery

L. Wan (✉) · T. Wang · L. Cheng · Q. Yu
Department of General Surgery, The General
Hospital of Western Theater command, Chengdu
610083, People's Republic of China
e-mail: doctor_wanli@163.com

INTRODUCTION

Echinococcosis, a serious parasitic disease, is caused by the larval tapeworm of genus *Echinococcus* [1]. This serious and globally distributed disease is still a major public health problem [2]. There are two main types in clinical practice: cystic echinococcosis (CE) and alveolar echinococcosis (AE), caused by *Echinococcus granulosus* sensu lato and *Echinococcus multilocularis*, respectively [3]. The liver is the most vulnerable organ owing to the particular life cycle of *Echinococcus* [4]. Liver echinococcosis is often ignored because it is asymptomatic in early-middle stages, which leads to delayed presentation and high mortality [1]. With the improvement and popularization of examination techniques, more and more patients with asymptomatic liver echinococcosis have obtained prompt diagnosis and effective treatment. The long-term and regular use of oral benzimidazoles is a feasible treatment for hepatic echinococcosis [4]. However, people prefer to choose more radical surgical approaches owing to the potential serious side effects and heavy economic burdens caused by lifelong drug administration [5]. Although conventional open surgery for treatment of liver echinococcosis has been confirmed to be safe and effective, its disadvantages of large surgical trauma, slow postoperative recovery, and potential incision complications have prompted surgeons to seek an alternative method that is more minimally invasive.

Katkhouda et al. successfully completed the world's first total pericystectomy in laparoscopy in 1992, thus opening a new era of laparoscopic treatment of liver echinococcosis [6]. Through 30 years of exploration and development, laparoscopic technology has been relatively mature and has played an increasingly important role in the treatment of two types of liver echinococcosis. In terms of hepatic CE, laparoscopy has been comprehensively carried out in all classical surgical approaches, including total pericystectomy, hepatectomy, subtotal pericystectomy, and partial pericystectomy as well as cystectomy. In terms of hepatic AE, laparoscopic hepatectomy has been applied in the

surgical treatment in selected patients and has been proven to be safe and effective [7, 8]. However, currently, there are large differences in the surgical indications for laparoscopic treatment of liver echinococcosis due to the presence of differences in the technical level and experience of laparoscopy among centers.

In this review, we summarize recent advances in the laparoscopic treatment of two types of liver echinococcosis and focus on their respective therapeutic algorithms from the perspective of surgeons specializing in hepatobiliary surgery. This article is based on previously conducted studies and does not contain any new studies with human participants or animals performed by any of the authors.

LAPAROSCOPIC TREATMENT FOR HEPATIC CYSTIC ECHINOCOCCOSIS

Surgical Indications of Laparoscopic Treatment for Hepatic CE

The indications for laparoscopic treatment of hepatic CE have changed dramatically owing to the increasing availability of laparoscopic surgery. Initially, only small and marginal cysts such as segments III, IVb, V, and VI were considered suitable for laparoscopic treatment [9–13]. Currently, only the following aspects were considered as exclusion criteria for laparoscopic surgery (Fig. 1): (1) hepatic CE5 patients without clinical symptoms and/or without willingness treatment; (2) preoperative liver function is Child–Pugh grade ; (3) the patient's cardiopulmonary function and general condition could not tolerate laparoscopic surgery; (4) patients with deep intraparenchymal cysts, inaccessible cysts, and relapsed CE; (5) multiple cysts with diffuse distribution in liver; (6) with extrahepatic metastasis; (7) dense adhesions surrounding the CE cysts were difficult to separate; (8) CE cysts with thickness of external capsule wall < 3 mm.

In addition to the above conditions, the following aspects should be noted in the specific implementation process: (i) Location of CE

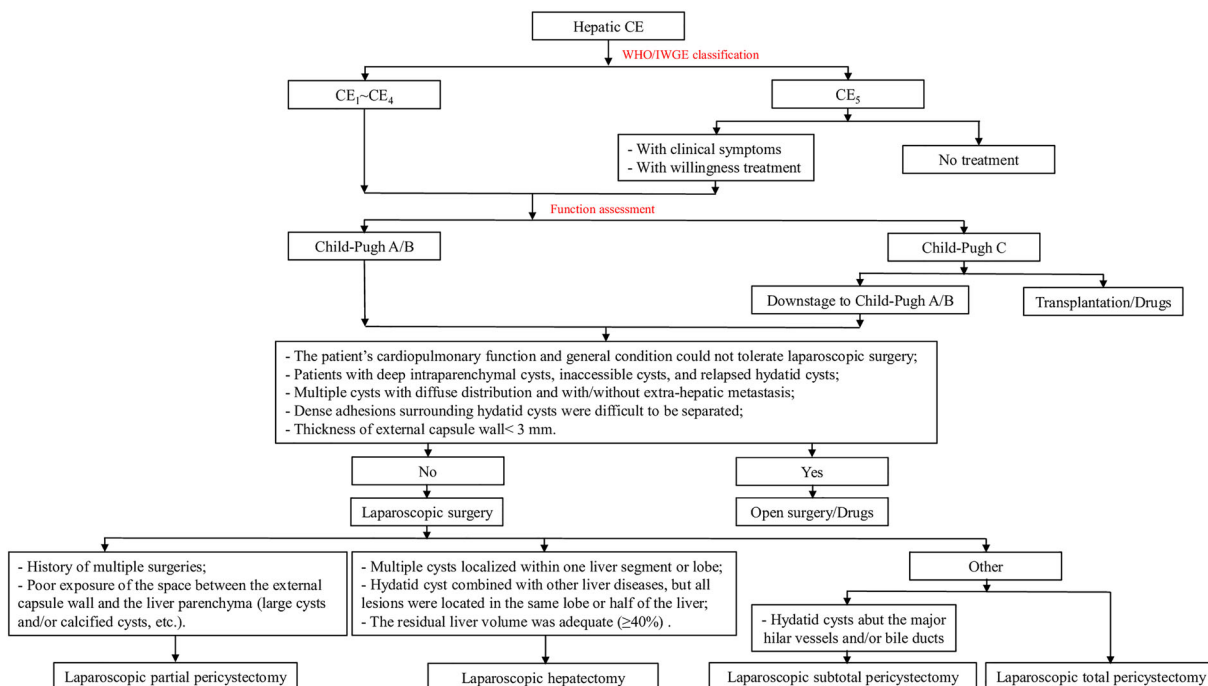


Fig. 1 Algorithm for laparoscopic treatment of hepatic cystic echinococcosis. WHO-IWGE, World Health Organization Informal Working Group on Echinococcosis.

Type (WHO/IWGE [4]): CE1, simple cyst; CE2, multiple daughter cyst; CE3, cyst with detachment of membranes; CE4, consolidation type; CE5, calcified type

cysts. The CE cysts in segments I, VII, and VIII could be well exposed intraoperatively when the patient is placed in the right or left lateral decubitus position. So, these special segment CE cysts should not be considered as a contraindication to laparoscopic surgery [14]. It is reported that the proportion of the posterosuperior segments affected can be as high as 60% in patients with hepatic CE treated with laparoscopic radical surgery in some highly specialized hepatobiliary surgery centers [15]. (ii) Prevention of cyst content spillage. Preventing spillage of cyst fluid is critical in hepatic hydatid surgery because it determines whether the procedure is a success or failure. We believe that preoperative treatment with albendazole and intraoperative encasement of the cyst with hypertonic saline gauze are effective ways to prevent cyst fluid spillage. Mikhail Efanov et al. suggested that, for partial active CE cysts, preoperative use of the percutaneous aspiration–injection–reaspiration (PAIR) technique is also beneficial in preventing spillage of the cyst contents [15]. (iii) Surgeon’s

skills. Laparoscopic conservative surgery can be accepted in remote hospitals, provided that patients with hepatic CE are selected for minimally invasive treatment taking into account the level of surgical skills in laparoscopy.

Finally, we must point out that, although laparoscopic total pericystectomy has many benefits, it should not be blindly pursued, but the most appropriate treatment should be selected according to the specific condition of the patient and the technical level of the surgeon to obtain the lowest morbidity, mortality, and recurrence rate.

Surgical Approaches of Laparoscopic Treatment for Hepatic CE

Liver CE is a chronic parasitic infectious disease caused by tapeworm eggs of *Echinococcus granulosus* sensu lato parasitizing humans [1]. Hepatic CE has been reported worldwide with the exception of a few sporadic island countries [16, 17]. Clinically, hepatic CE is more

common, accounting for more than 90% of the total amount of two types of liver echinococcosis [1]. Most patients with hepatic CE have no any clinical symptoms for a long time or present only with upper abdominal discomfort [18]. Typical hepatic CE cysts are composed of two membranes, including an endocyst consisting of the germinal layer and laminated layer and an ectocyst, which is a fibrous layer caused by the compression of the host tissue around the endocyst [19]. Among them, the endocyst is pathogenic because it is filled with cyst fluid containing a large number of active echinococcal scolices [4]. The residual cavity formed by the external capsule is the main cause of postoperative complications such as residual cavity infection and bile leakage [20, 21]. On the basis of its pathological features, the basic principles of surgical treatment of hepatic CE are prevention of echinococcal spillage, sterilization and evacuation of the parasite, and management of the residual cavity [22].

According to different disposal methods of hydatid external capsule, there are two main types of surgical treatment for hepatic CE, namely radical surgery that extricates the entire pericyst and conservative surgery that removes the parasite and leave all or part of the external capsule in situ [9]. Radical surgery includes total pericystectomy and hepatectomy. Conservative surgery includes subtotal pericystectomy, partial pericystectomy, and cystectomy [23]. Currently, these surgical approaches can all be done in laparoscopy [24, 25]. Studies have demonstrated that laparoscopic approach in the treatment of liver CE is not only safe and effective, but also has the advantages of less pain, good cosmetic results, rapid postoperative recovery, decreased complications and shorter hospital stays compared with similar open surgery [26–28].

Laparoscopic Total Pericystectomy

Total pericystectomy was first reported for the treatment of hepatic CE in 1930 [29]. According to whether the cyst is opened or not, it can be divided into closed total pericystectomy and open total pericystectomy [30, 31]. In the

former method, the cyst is completely resected gradually along the potential space between the liver parenchyma and the ectocyst. In the second technique, the cyst is opened, the cyst contents including echinococcal scolices are removed, and then the pericyst is totally resected. Total pericystectomy (especially close total pericystectomy) is the most ideal surgical approach for the treatment of hepatic CE because it closes the residual cavity and prevents relapse of the disease and secondary inflammatory complications. A large meta-analysis of radical and conservative surgery outcomes in more than 4000 patients from 19 studies also reached the same conclusion [27].

Interestingly, the first reported laparoscopic treatment of hepatic CE by Katkhouda et al. in 1992 was total pericystectomy [6]. Nevertheless, over a long period of time, this approach has not been performed much in clinical practice owing to concerns that intraoperative spillage of cyst contents, hemorrhage, poor exposure, and recurrence rates may be higher with laparoscopy than for open surgery [10]. A large review showed that laparoscopic total pericystectomy was only 5.84% of concurrent laparoscopic treatment for hepatic CE by 2013 [9]. Up to 2016, only about 100 cases of laparoscopic total pericystectomy for treatment of hepatic CE were published in English literature [32]. In recent years, with the improved understanding of anatomical segmentation and laparoscopic technological advances, an increasing number of patients with hepatic CE were treated by laparoscopic total pericystectomy [33]. A recent multicenter study showed that more than half of patients with hepatic hydatid underwent laparoscopic treatment [15]. Among them, the rate of laparoscopic total pericystectomy was 28% [15]. It is noteworthy that this rate was no different from the proportion of total pericystectomy in open surgery during the same period [33]. Studies showed that laparoscopic total pericystectomy has better immediate and long-term results than other laparoscopic approaches because it could completely remove tissues that are source of recurrence and eliminate the residual cavity [15, 34, 35]. Therefore, laparoscopic total pericystectomy is

the first choice for laparoscopic treatment of hepatic CE (Fig. 1).

The detailed operation process is as follows. The patients were usually placed in the supine position with anti-Trendelenburg after the onset of anesthesia. The cysts in special segments such as 6, 7, and 8 were placed in right-side-up or left lateral decubitus position. Subsequently, a small incision of about 10 mm was made around the umbilicus. Next, a Veress needle was placed into the position in order to establish CO₂ pneumoperitoneum, and intra-abdominal pressure was maintained within the range of 12–14 mmHg. Afterwards, an inspection hole was made at the position with 10-mm trocar. Laparoscope was introduced into the abdominal cavity from this inspection hole. On this basis, the lesion size, number, location, and adhesion to the surrounding tissues were comprehensively evaluated. The remaining trocars were sequentially placed according to the evaluation results. Surgical procedures followed the steps described below. Step 1: the cysts were adequately separated from the peripheral tissues and organs. Step 2: medical gauze soaked in 20% hypertonic saline solution was used to protect the normal tissues adjacent to cysts. Step 3: the cysts were completely dissected gradually using harmonic scalpel along the potential space between the liver parenchyma and the ectocyst. Meanwhile, the small blood vessels and/or bile ducts were immediately closed using a monopolar electrocoagulation or ultrasound scalpel, and the large blood vessels and/or bile ducts that entered into the cyst were clipped and/or ligated. Step 4: re-examination was carried out to observe whether active bleeding and/or biliary fistula was present. If necessary, the local operation areas were covered using biological absorbable hemostatic gauzes. Step 5: the echinococcosis cysts were placed into a sampling bag, and then the bag was extracted out from the abdominal wall through the extending subxiphoid incision. Alternatively, cyst puncture suction was performed in the bag, and the cysts were removed after diminution of its size. Step 6: a drainage tube was inserted around the operative region.

Laparoscopic Hepatectomy

Although the first laparoscopic hepatectomy for hepatic CE was described by Descottes et al. as early as 2003, the use of this technique in treatment for hepatic CE was controversial because of the cyst's benign nature, higher risk of intraoperative hemorrhage, and high postoperative complications [29, 36]. In fact, the incidence of intraoperative bleeding and postoperative complications is far less than expected in selected patients [9, 15]. Moreover, these postoperative complications such as liver dysfunction and pleural effusion could be cured after short-term treatment [37]. Therefore, considering the better long-term results of patients with hepatic CE who underwent radical surgery, laparoscopic hepatectomy treatment for liver CE is justified [38]. We strongly recommend laparoscopic hepatectomy for treatment of hepatic CE in the following conditions (Fig. 1): (1) multiple cysts localized within one liver segment or lobe; (2) CE combined with other liver diseases, but all lesions located in the same lobe or half of the liver; (3) adequate residual liver volume ($\geq 40\%$).

Surgical procedures followed the steps described below. Step 1: after successful establishment of pneumoperitoneum, the size and location of the cysts were further evaluated by laparoscopy. Step 2: the diseased liver lobe was adequately separated from the peripheral tissues and organs. Step 3: the precut liver line was marked on the liver tissue 1–2 cm away from the cysts. Step 4: the liver lobe where the cyst was located was resected using an ultrasound scalpel along the precut liver line. In the presence of significant capillary hemorrhage, immediate hemostasis was carried out using a monopolar electrocoagulation or ultrasound scalpel. Meanwhile, large blood vessels and bile ducts were closed using absorbable clips until total diseased liver lobe was completely resected. Step 5: re-examination was carried out to observe whether active bleeding and/or biliary fistula was present. If necessary, the local operation areas were covered using biological absorbable hemostatic gauzes. Step 6: the diseased liver lobe was placed into a sampling bag, and then the bag was extracted out from the

abdominal wall through the extending subxiphoid incision. Step 7: a drainage tube was inserted around the operative region.

Laparoscopic Subtotal Pericystectomy

Laparoscopic subtotal pericystectomy involved the removal of the entire fibrous capsule, with the exception of a small pericystic areas left on the large tubular structures to minimize the risk of severe complications (removal of more than 90% of the fibrous capsule) [1, 39]. The rate of postoperative residual cavity-related complications was much lower with laparoscopic subtotal pericystectomy than other two conservative laparoscopic surgeries. Thus, it was also considered a “quasi-radical surgery” [22]. Therefore, although the incidence of postoperative complications such as recurrence in situ and residual cavity infection of laparoscopic subtotal pericystectomy is higher than laparoscopic total pericystectomy, this approach is still encouraged when the cyst is adjacent to major vessels and/or bile duct to avoid damaging these tubular structures (Fig. 1) [1, 22, 26, 37].

Surgical procedures followed the steps described below. After routine exploration via laparoscopy, the remaining trocars were successively placed depending on the location of the cysts. Step 1: the cyst was adequately separated from the peripheral tissues and organs. Step 2: medical gauzes soaked in 20% hypertonic saline solution were placed around the cyst. Step 3: a puncture needle was quickly penetrated into the cyst cavity under the suction protection of the aspirator. Step 4: after aspiration of the cyst fluid, an appropriate amount of 20% hypertonic saline was injected into the cyst cavity and retained for 5–10 min in order to kill the active echinococcal scolices. Step 5: after aspiration of hypertonic saline, the puncture needle was removed and then part of the external capsule was incised. Step 6: another aspirator was inserted into the cyst cavity along the incised capsule, and then the contents of the cyst, including internal capsule fragments and asci, were completely aspirated. If necessary, steps 3–6 could be repeated. Step 7: the cyst was gradually dissected using harmonic scalpel along the potential space between the

liver parenchyma and the ectocyst until near the mainly great vessels and/or bile ducts (residual external capsule wall $\leq 10\%$). Meanwhile, in the presence of significant capillary hemorrhage, immediate hemostasis was carried out using a monopolar electrocoagulation or ultrasound scalpel, and the large blood vessels and/or bile ducts that entered into the cyst were clipped and/or ligated. Step 8: re-examination was carried out to observe whether active bleeding and/or biliary fistula were present. If necessary, the local operation areas were covered using biological absorbable hemostatic gauzes. Step 9: the residual tissues (including but not limited to resection of the ectocyst capsule wall and part of internal capsule fragments that could not be aspirated) were placed into a sampling bag, and then the bag was extracted out from the abdominal wall through the extending subxiphoid incision. Step 10: a drainage tube was inserted around the operative region. The whole operative process follows the principle of “no contact of cyst fluid” to avoid contamination of the scolex and hydatid planting.

Laparoscopic Partial Pericystectomy

Laparoscopic partial pericystectomy, also known as modified laparoscopic cystectomy, refers to the resection of the entire endocyst and partial pericyst (removal of less than 90% of the fibrous capsule) [15]. This procedure not only eliminates the parasitic foci, but also removes the exuberant part of the pericyst that protrudes from the liver, so its postoperative recurrence rate of hydatid disease is much lower than laparoscopic cystectomy [4, 22]. Laparoscopic partial pericystectomy is relatively simple and with low surgical risk as only the extrahepatic peripheral capsule is removed, without the intrahepatic pericyst, which was once one of the main methods for treatment of hepatic CE [4, 9]. However, compared with laparoscopic total pericystectomy, laparoscopic partial pericystectomy has obviously higher risk of hydatid relapse, biliary fistula, and secondary residual cavity infection due to the rigid residual cavity that remains after surgery [4, 15]. Therefore, currently, laparoscopic partial pericystectomy is

only recommended for the treatment of patients with hepatic CE in the following conditions (Fig. 1): (1) history of multiple surgeries; (2) poor exposure of the space between the external capsule wall and the liver parenchyma.

The surgical procedures performed were as follows: after routine exploration, the remaining trocars were successively placed according to the location of the cysts. In step 1, the cyst was adequately separated from the peripheral tissues and organs. In step 2, medical gauzes soaked in 20% hypertonic saline solution were placed around the cyst, to prevent the spread and leakage of the cystic contents in case of any spillage. In step 3, a puncture needle was quickly penetrated into the cyst cavity under the suction protection of the aspirator. In step 4, after aspiration of the cyst fluid, an appropriate amount of 20% hypertonic saline was injected into the cyst cavity and retained for 5–10 min to kill the active echinococcal scolices. In step 5, after aspiration of hypertonic saline, the puncture needle was removed and then the cyst was opened with the coagulation hook. In step 6, another aspirator was inserted into the cyst cavity via the opened window, and then the contents of the cyst, including internal capsule fragments and asci, were completely aspirated. If necessary, steps 3–6 could be repeated. In step 7, the external capsule wall free from the liver parenchyma was removed (residual external capsule wall > 10%), and then the laparoscope was extended into the residual cavity to explore potential bleeding and bile fistula. In step 8, the residual tissues (including but not limited to resection of the ectocyst capsule wall and part of internal capsule fragments that could not be aspirated) were placed into a sampling bag, and then the bag was extracted out from the abdominal wall through the extending subxiphoid incision. In step 9, a drainage tube was inserted into the residual cavity. The whole operative process follows the principle of “no contact of cyst fluid” to avoid contamination of the scolex and hydatid planting.

Laparoscopic Cystectomy

Laparoscopic cystectomy was once considered the first-line approach for treating patients with hepatic CE owing to its simplicity and nearly no risk of bleeding [4, 9]. It is reported that nearly three-quarters of patients with hepatic CE who underwent laparoscopic surgery were treated by laparoscopic cystectomy by 2013 [9]. This surgical method, although simple, easy, and quick, is prone to refractory complications such as hydatid relapse, biliary fistula, and residual cavity infection. These complications seriously affect the experience of patients' presentation and the quality of life after surgery. Therefore, laparoscopic cystectomy is not currently recommended for the treatment of hepatic CE [40, 41].

LAPAROSCOPIC TREATMENT FOR HEPATIC ALVEOLAR ECHINOCOCCOSIS

Hepatic alveolar echinococcosis (AE), an important type of hepatic echinococcosis, is a fatal parasitic disease caused by the larval stage of *Echinococcus multilocularis* [1, 4, 22]. Hepatic AE, compared with hepatic CE, is rarer but more malignant owing to its tumor-like invasive growth [8]. Studies show that mortality of patients with hepatic AE exceeds 90% after 10–15 years of diagnosis if untreated or inadequately treated [1, 7]. Expert consensus recommends that radical surgical resection following the principle of “tumor-free surgery” is the first choice for the treatment of hepatic AE [4, 20, 22]. Owing to the well-known advantages of laparoscopy, laparoscopic techniques have also been used for hepatic AE treatment in clinical practice [7, 8, 14, 42–44]. Nevertheless, compared with hepatic CE, laparoscopic treatment of hepatic AE was started relatively late and fewer cases were reported, which may be caused by its more complex characteristics.

Table 1 Patient characteristics and demographics of eligible studies

Author (year of publication)	Number of patients (n)	Inclusion frame	Inclusion time	Mean patient age (years)	Liver lesion		Operation	Radical resection rate (%)	Morbidity (%)	Mortality (%)	Recurrence rate (%)	Follow-up (months)
					PNM	Location						
Kawamura et al. (2011)	2	1984–2009	NR	NR	P1N0M0: 1; P2N0M0: 1	LLL: 1; LL: 1	NR	LS: 1; LH: 1	NR	NR	NR	NR
Mikhail Efanov et al. (2017)	NR	2010–2016	NR	NR	NR	NR	NR	NR	NR	NR	NR	NR
Salm et al. (2019)	NR	NR	NR	NR	NR	NR	NR	NR	NR	NR	NR	NR
Zhao et al. (2020)	1	2019.9–2019.12	45	45	P1N0M0	RPL	5.1	RS	0	0	0	3
Wan et al. (2021)	13	2018–2019	32.7	32.7	P1N0M0: 8; P2N0M0: 5	LLL: 3; LML: 1; LL: 1; RPL: 2; RAL: 2; RL: 3; ML: 1	7.8	LS: 7; LH: 6	Acute liver failure: 1; hydrops: 1	0	0	9–30

NR not reported; PNM (WHO/IWGE [4]): P1 peripheral lesion without proximal vascular and/or biliary involvement; P2 central lesions with proximal vascular and/or biliary involvement of one lobe; N0 no regional involvement; M0 no metastasis. RPL right posterior lobe; RL right lateral lobe; LLL left lateral lobe; RAL right anterior lobe; ML middle lobe; LL left lobe; LML left medial lobe; LS laparoscopic segmentectomy; LH laparoscopic hemihepatectomy; RS robotic segmentectomy

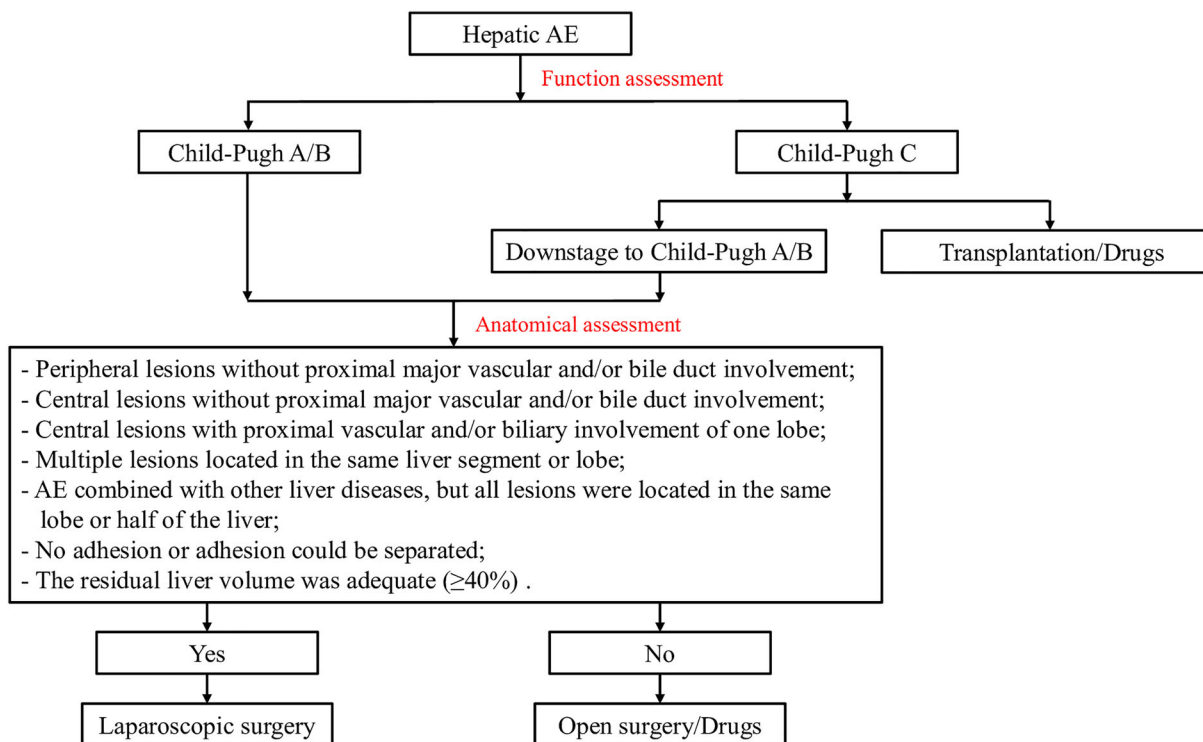


Fig. 2 Algorithms of laparoscopic treatment in patients with hepatic alveolar echinococcosis

Kawamura et al. (2011) were the first to report successful results of laparoscopic treatment of two cases of hepatic AE [42]. Six years later, Mikhail Efanov et al. reported the results of laparoscopic and robotic treatment of hepatic AE in their center [44]. Subsequently, Zhao et al. reported a successful case of robotic treatment of AE in posterosuperior liver segments [14]. A recent publication by Wan et al. indicated that laparoscopy not only achieves the same radical effect as open surgery in selected patients with hepatic AE, but also is superior in terms of minimal wound, better aesthetic results, lower postoperative complication morbidity, and shorter postoperative hospital stay [8]. These results are in line with Salm et al.’s experience with laparoscopic hepatectomy for treatment of hepatic AE showing no difference in efficacy and safety compared with open AE surgery [43]. To date, no more than 50 cases of laparoscopic treatment for hepatic AE were published in the English literature worldwide (Table 1). However, compared with open surgery, its clear

advantages of minimal invasiveness, low complications, and rapid postoperative recovery have important clinical significance and show broad prospects.

On the basis of the current study results and our experience, we believe that the following aspects should be considered for surgical indications for laparoscopic treatment of hepatic AE (Fig. 2): (1) the patient’s cardiopulmonary function and general condition could tolerate laparoscopic surgery; (2) preoperative liver function is Child–Pugh grade A or B; (3) peripheral lesions without proximal major vascular and/or bile duct involvement; (4) central lesions without proximal major vascular and/or bile duct involvement; (5) central lesions with proximal major vascular and/or bile duct involvement of one lobe; (6) multiple lesions located in the same liver segment or lobe; (7) AE combined with other liver diseases, but all lesions located in the same lobe or half of the liver; (8) no adhesion or adhesion could be separated by laparoscopy; (9) adequate residual liver volume ($\geq 40\%$).

It is noted that, although we are as thoughtful as possible, the above algorithms of laparoscopic treatment in patients with hepatic AE may still be flawed and insufficient owing to the lack of results from large, prospective, randomized clinical trials.

CONCLUSIONS

Considering the well-known benefits of minimally invasive surgery, the laparoscopic technique offers a viable alternative to conventional open surgery for the treatment of two types of liver echinococcosis. It is crucial that surgeons be made aware of respective therapeutic algorithms of laparoscopic treatment to achieve surgical success. However, the laparoscopic treatment strategy for liver echinococcosis still needs to be further demonstrated and refined by prospective studies with prolonged follow-up.

ACKNOWLEDGEMENTS

Funding. No funding or sponsorship was received for this study or publication of this article. The Rapid Service Fee was funded by the authors.

Author Contributions. All authors were involved in the design of the study and the collection of relevant evidence. Li Wan drafted and edited the manuscript. The manuscript was critically revised by Li Wan and Tao Wang.

Disclosures. Li Wan, Tao Wang, Long Cheng and Qianjun Yu all have nothing to disclose.

Compliance with Ethics Guidelines. This article is based on previously conducted studies and does not contain any new studies with human participants or animals performed by any of the authors.

Open Access. This article is licensed under a Creative Commons Attribution-

NonCommercial 4.0 International License, which permits any non-commercial use, sharing, adaptation, distribution and reproduction in any medium or format, as long as you give appropriate credit to the original author(s) and the source, provide a link to the Creative Commons licence, and indicate if changes were made. The images or other third party material in this article are included in the article's Creative Commons licence, unless indicated otherwise in a credit line to the material. If material is not included in the article's Creative Commons licence and your intended use is not permitted by statutory regulation or exceeds the permitted use, you will need to obtain permission directly from the copyright holder. To view a copy of this licence, visit <http://creativecommons.org/licenses/by-nc/4.0/>.

REFERENCES

1. Wen H, Vuitton L, Tuxun T, et al. Echinococcosis: advances in the 21st century. *Clin Microbiol Rev*. 2019. <https://doi.org/10.1128/cmr.00075-18>.
2. Wen H, Dong JH, Zhang JH, et al. Ex vivo liver resection and autotransplantation for end-stage alveolar echinococcosis: a case series. *Am J Transplant*. 2016;16(2):615–24. <https://doi.org/10.1111/ajt.13465>.
3. Mcmanus DP, Gray DJ, Zhang W, et al. Diagnosis, treatment, and management of echinococcosis. *BMJ*. 2012;344: e3866. <https://doi.org/10.1136/bmj.e3866>.
4. Brunetti E, Kern P, Vuitton DA. Expert consensus for the diagnosis and treatment of cystic and alveolar echinococcosis in humans. *Acta Trop*. 2010;114(1):1–16. <https://doi.org/10.1016/j.actatropica.2009.11.001>.
5. Aji T, Dong JH, Shao YM, et al. Ex vivo liver resection and autotransplantation as alternative to allotransplantation for end-stage hepatic alveolar echinococcosis. *J Hepatol*. 2018;69(5):1037–46. <https://doi.org/10.1016/j.jhep.2018.07.006>.
6. Katkhouda N, Fabiani P, Benizri E, et al. Laser resection of a liver hydatid cyst under videolaparoscopy. *Br J Surg*. 1992;79(6):560–1. <https://doi.org/10.1002/bjs.1800790628>.

7. Wan L, Ran B, Aji T, et al. Laparoscopic hepatectomy for the treatment of hepatic alveolar echinococcosis. *Parasite*. 2021;28:5. <https://doi.org/10.1051/parasite/2021001>.
8. Wan L, Ran B, Aji T, et al. Laparoscopic or open treatment for hepatic alveolar echinococcosis: a single-institution experience. *Int J Infect Dis*. 2021;107:182–7. <https://doi.org/10.1016/j.ijid.2021.04.017>.
9. Tuxun T, Zhang JH, Zhao JM, et al. World review of laparoscopic treatment of liver cystic echinococcosis—914 patients. *Int J Infect Dis*. 2014;24:43–50. <https://doi.org/10.1016/j.ijid.2014.01.012>.
10. Zaharie F, Bartos D, Mocan L, et al. Open or laparoscopic treatment for hydatid disease of the liver? A 10-year single-institution experience. *Surg Endosc*. 2013;27(6):2110–6. <https://doi.org/10.1007/s00464-012-2719-0>.
11. Tuxun T, Aji T, Tai QW, et al. Conventional versus laparoscopic surgery for hepatic hydatidosis: a 6-year single-center experience. *J Gastrointest Surg*. 2014;18(6):1155–60. <https://doi.org/10.1007/s11605-014-2494-4>.
12. Chen X, Chen X, Shao Y, et al. Clinical outcome and immune follow-up of different surgical approaches for human cyst hydatid disease in liver. *Am J Trop Med Hyg*. 2014;91(4):801–5. <https://doi.org/10.4269/ajtmh.14-0177>.
13. Sokouti M, Sadeghi R, Pashazadeh S, et al. A systematic review and meta-analysis on the treatment of liver hydatid cyst: comparing laparoscopic and open surgeries. *Arab J Gastroenterol*. 2017;18(3):127–35. <https://doi.org/10.1016/j.ajg.2017.09.010>.
14. Zhao ZM, Yin ZZ, Meng Y, et al. Successful robotic radical resection of hepatic echinococcosis located in posterosuperior liver segments. *World J Gastroenterol*. 2020;26(21):2831–8. <https://doi.org/10.3748/wjg.v26.i21.2831>.
15. Efanov M, Azizzoda Z, Elizarova N, et al. Laparoscopic radical and conservative surgery for hydatid liver echinococcosis: PSM based comparative analysis of immediate and long-term outcomes. *Surg Endosc*. 2022;36(2):1224–33. <https://doi.org/10.1007/s00464-021-08391-4>.
16. Craig PS, Larrieu E. Control of cystic echinococcosis/hydatidosis: 1863–2002. *Adv Parasitol*. 2006;61:443–508. [https://doi.org/10.1016/s0065-308x\(05\)61011-1](https://doi.org/10.1016/s0065-308x(05)61011-1).
17. Craig PS, Mcmanus DP, Lightowlers MW, et al. Prevention and control of cystic echinococcosis. *Lancet Infect Dis*. 2007;7(6):385–94. [https://doi.org/10.1016/s1473-3099\(07\)70134-2](https://doi.org/10.1016/s1473-3099(07)70134-2).
18. Akbulut S, Senol A, Ekin A, et al. Primary retroperitoneal hydatid cyst: report of 2 cases and review of 41 published cases. *Int Surg*. 2010;95(3):189–96.
19. Tai QW, Tuxun T, Zhang JH, et al. The role of laparoscopy in the management of liver hydatid cyst: a single-center experience and world review of the literature. *Surg Laparosc Endosc Percutan Tech*. 2013;23(2):171–5. <https://doi.org/10.1097/SLE.0b013e31828a0b78>.
20. Chinese College of Surgeons (CCS), Chinese Committee for Hadytidology(CCH). Expert consensus on the diagnosis and treatment of hepatic cystic and alveolar echinococcosis (2015 edition). *Chin J Dig Surg*. 2015;14(4):253–64.
21. Akbulut S. Parietal complication of the hydatid disease: comprehensive literature review. *Medicine (Baltimore)*. 2018;97(21): e10671. <https://doi.org/10.1097/md.0000000000010671>.
22. Chinese Doctor Association, Chinese College of Surgeons(CCS), Chinese Committee for Hadytidology(CCH). Expert consensus on diagnosis and treatment of hepatic cystic and alveolar echinococcosis. *Chin J Dig Surg*. 2019;18(8):711–21.
23. Sozuer E, Akyuz M, Akbulut S. Open surgery for hepatic hydatid disease. *Int Surg*. 2014;99(6):764–9. <https://doi.org/10.9738/int surg-d-14-00069.1>.
24. Yağmur Y, Akbulut S, Gümüş S, et al. Laparoscopic management of hydatid cyst of the liver. *S Afr J Surg*. 2016;54(3):14–7.
25. Koc C, Akbulut S, Sahin TT, et al. Intraperitoneal rupture of the hydatid cyst disease: single-center experience and literature review. *Ulus Travma Acil Cerrahi Derg*. 2020;26(5):789–97. <https://doi.org/10.14744/tjtes.2020.32223>.
26. Jabbari Nooghabi A, Mehrabi Bahar M, Asadi M, et al. Evaluation and comparison of the early outcomes of open and laparoscopic surgery of liver hydatid cyst. *Surg Laparosc Endosc Percutan Tech*. 2015;25(5):403–7. <https://doi.org/10.1097/sle.000000000000199>.
27. Pang Q, Jin H, Man Z, et al. Radical versus conservative surgical treatment of liver hydatid cysts: a meta-analysis. *Front Med*. 2018;12(3):350–9. <https://doi.org/10.1007/s11684-017-0559-y>.
28. Bayrak M, Altıntaş Y. Current approaches in the surgical treatment of liver hydatid disease: single center experience. *BMC Surg*. 2019;19(1):95. <https://doi.org/10.1186/s12893-019-0553-1>.

29. Filippou D, Tselepis D, Filippou G, et al. Advances in liver echinococcosis: diagnosis and treatment. *Clin Gastroenterol Hepatol*. 2007;5(2):152–9. <https://doi.org/10.1016/j.cgh.2006.08.017>.
30. Prousalidis J, Tzardinoglou E, Kosmidis C, et al. Surgical management of calcified hydatid cysts of the liver. *HPB Surg*. 1999;11(4):253–9. <https://doi.org/10.1155/1999/20148>.
31. Cirenei A, Bertoldi I. Evolution of surgery for liver hydatidosis from 1950 to today: analysis of a personal experience. *World J Surg*. 2001;25(1):87–92. <https://doi.org/10.1007/s002680020368>.
32. Jarufe N, Galindo JL. Radical laparoscopic treatment for hepatic hydatid disease. *J Gastrointest Digest Syst*. 2016. <https://doi.org/10.4172/2161-069X.1000419>.
33. Tuxun T. Laparoscopic versus open surgery for hepatic cystic echinococcosis: a systematic review and meta-analysis. *Int J Clin Exp Med*. 2017;10(12):16788–97.
34. Grubnik V, Iliashenko V, Bugridze Z, et al. Liver cystic echinococcosis laparoscopic treatment effectiveness. *Georgian Med News*. 2018;278:20–5.
35. Li H, Shao Y, Aji T, et al. Laparoscopic approach for total cystectomy in treating hepatic cystic echinococcosis. *Parasite*. 2014;21:65. <https://doi.org/10.1051/parasite/2014065>.
36. Descottes B, Glineur D, Lachachi F, et al. Laparoscopic liver resection of benign liver tumors. *Surg Endosc*. 2003;17(1):23–30. <https://doi.org/10.1007/s00464-002-9047-8>.
37. Tuergan T, Shao YM, Zhang RQ, et al. A study on the clinical outcomes using different laparoscopic methods to treat hepatic cystic hydatidosis. *Chin J Hepatobiliary Surg*. 2019;25(9):664–7.
38. Georgiou GK, Lianos GD, Lazaros A, et al. Surgical management of hydatid liver disease. *Int J Surg*. 2015;20:118–22. <https://doi.org/10.1016/j.ijsu.2015.06.058>.
39. Goldin SB, Mateka JJ, Schnaus MJ, et al. Laparoscopic drainage of a hepatic echinococcal cyst: a case report. *Case Rep Gastrointest Med*. 2011;2011:107087. <https://doi.org/10.1155/2011/107087>.
40. Duta C, Pantea S, Lazar C, et al. minimally invasive treatment of liver hydatidosis. *JSLs*. 2016. <https://doi.org/10.4293/jsls.2016.00002>.
41. Manterola C, Otzen T. Surgical strategies in the treatment of liver hydatid cyst. *Surg Pract*. 2017;21(4):164–72.
42. Kawamura N, Kamiyama T, Sato N, et al. Long-term results of hepatectomy for patients with alveolar echinococcosis: a single-center experience. *J Am Coll Surg*. 2011;212(5):804–12. <https://doi.org/10.1016/j.jamcollsurg.2011.02.007>.
43. Salm LA, Lachenmayer A, Perrodin SF, et al. Surgical treatment strategies for hepatic alveolar echinococcosis. *Food Waterborne Parasitol*. 2019;15: e00050. <https://doi.org/10.1016/j.fawpar.2019.e00050>.
44. Efanov M, Alikhanov R, Tsvirkun V, et al. Comparative analysis of learning curve in complex robot-assisted and laparoscopic liver resection. *HPB (Oxford)*. 2017;19(9):818–24. <https://doi.org/10.1016/j.hpb.2017.05.003>.

Publisher's Note

Springer Nature remains neutral with regard to jurisdictional claims in published maps and institutional affiliations.