



# Sporotrichosis: a Comprehensive Review on Recent Drug-Based Therapeutics and Management

Bunty Sharma<sup>1</sup> · Anil Kumar Sharma<sup>1</sup> · Ujjawal Sharma<sup>1</sup>

Accepted: 16 February 2022 / Published online: 17 March 2022

© The Author(s), under exclusive licence to Springer Science+Business Media, LLC, part of Springer Nature 2022

## Abstract

**Purpose of Review** Over a period of time, sporotrichosis has arisen as one of the leading fungal infections not only in animals but humans also. Several possible reasons that contribute to its emergence include change in epidemiology and distribution, evolutionary changes in taxonomy, and several outbreaks. World Health Organization has identified sporotrichosis as one of the major neglected tropical diseases (NTD) for 2021–2030 under the category of fungal NTDs. Several factors are contributing to increases in morbidity due to sporotrichosis such as delayed diagnosis and unavailability of appropriate antifungal therapy, which lead to redundant and inappropriate treatment with associate costs and adverse effects.

**Recent Findings** The potassium iodide is the first line of treatment for cutaneous forms while amphotericin B is used for the most severe cases of the disease. The limited medication arsenal, side effects, failure of therapy, and the advent of drug-resistant isolates emphasize the need for the development of new therapeutic options. Several studies are focusing on the development of the new drugs which either used alone or in combination with already available treatment. Along with this, several new antigens have been identified as possible targets for its vaccine development.

**Summary** The early diagnosis is required for selecting the best possible treatment strategy. The researchers should focus on developing new diagnostic methods and treatment options as well as vaccine development for the better management of sporotrichosis. In the long run, patient education for preventative features to reduce risk and counselling for prolonged therapy will be beneficial.

**Keywords** Sporotrichosis · Treatment · Strategy · Fungal infections · Sporothrix · Antifungal

## Introduction

Sporotrichosis is regarded as an environmentally acquired disease. This disease is most typically seen in gardeners and can be contracted through a thorn prick; hence, sporotrichosis is also recognized as rose growers' sickness or gardener's disease. A pustule is developed and ulcerates after *Sporothrix schenckii* inoculation. The infection spreads through the lymphatic circulation, causing a series of cutaneous ulcers. In humans, this lymphocutaneous type is the most prevalent manifestation of *Sporothrix schenckii* infection. Occasionally, at the site of inoculation, a dermal version of the disease persists [1]. The most typical location for lesions is the arm,

but they can appear elsewhere. According to a study, 17% of forestry workers, 10% florists and gardeners, and 16% of other soil-related occupations, such as farmers, accounted for *Sporothrix schenckii* infections [2]. Infections with *Sporothrix schenckii* in humans have mostly occurred after touching the plant material; in 1983, for instance, in Oklahoma and New Mexico, 12 cases of dermal sporotrichosis were reported among workers involved in farming activity [3].

In 1988, the most widespread sporotrichosis outbreak in horticulture happened, in that cutaneous sporotrichosis was reported to develop in 84 workers who handled sphagnum moss-packed conifer seedlings [4, 5]. People from 15 states who were involved in forestry, nursery, and gardening were afflicted by the outbreak. It was found that sphagnum moss was the source of sporotrichosis in ten horticulture employees at a Disney World topiary [6]. Besides the horticultural sources of sporotrichosis, the involvement of domestic cats in the *Sporothrix schenckii* transmission is receiving more attention. The studies on the zoonotic transmission of sporotrichosis imply that

✉ Ujjawal Sharma  
ujjawalbiotech@gmail.com

<sup>1</sup> Department of Biotechnology, Maharishi Markandeshwar (Deemed To Be University), Mullana-Ambala, Haryana 133207, India

this mode of infection may become more common in immunocompromised populations of sporotrichosis in AIDS patients [7, 8]. Sporotrichosis has been considered as an emergent health problem [9]. There are six important factors that affect the rise of zoonotic diseases, which comprise the transportation of animals and humans between geographic locations, augmented animals and human contact, alteration in the environment and husbandry practices, a rising immunocompromised population, improved awareness about the origin of many zoonotic diseases, and the identification of previously unknown organisms.

## Etiologic Agent of Sporotrichosis

The causing agent of Sporotrichosis is *Sporothrix schenckii* which is a dimorphic fungus. It belongs to the Moniliales family of the Hyphomycetes class of fungi. There are two important mechanisms of infection of the mycotic agent of sporotrichosis for infection of the mammalian host. First, *Sporothrix schenckii* can convert into ascomycete teleomorph that helps in its survival on decaying or living plant material. Therefore, it is isolated from decaying foliage such as straw, thorns, wood hay, and soil. Second, the ability to change into a yeast phase after entering the skin through the puncture and cause local lesions and probably systemically in the mammalian host [10].

The *Sporothrix schenckii* has the dimorphic ability that it remains as a yeast-like form at a temperature between 35 and 37 °C and converts into a mycelial phase (with branching, septate hyphae) at a temperature range between 25 and 30 °C. This nature helps it to survive in the environment and becomes pathogenic in animals [11, 12]. The isolates of *Sporothrix schenckii* are hyphal mycelia form; nevertheless, it readily adapts to a yeast-like form after subsequent injection into mice or other susceptible mammalian hosts. Conversely, the isolates from animals which is in yeast-like form can easily change into hyphal-conidial form when incubated on suitable media at 25 to 30 °C. However, some *Sporothrix schenckii* strains grow well at temperatures below or equal to 35 °C and are thought to be involved in localized cutaneous lesion development in animals and humans [13]. Subcutaneous and other rarer forms of infection with *Sporothrix schenckii* are widespread worldwide in animals and men. There is a wide range of the hosts for infection with this mycotic agent that includes humans, chimpanzees, cattle, dogs, horses, cats, mice, rats, and hamsters [14, 15].

## Prevalence of Sporotrichosis

The actual prevalence of sporotrichosis is unknown because it is not a reportable disease; nevertheless, the disease has been reported in South America (Brazil,

Columbia, Mexico, Guatemala, Peru), the USA, Asia (China, Japan, and India.), and Australia [10]. In India, most cases have been reported along the sub-Himalayan regions [16]. After a considerable number of instances were documented in France in the early twentieth century, the number of cases has declined, and the disease is now only seen in Europe on rare occasions [17].

In Peru, the prevalence ranges from 48 to 98 cases per 100 000 people [18], with a mean of 156 cases per 100 000 people in youngsters [19]. In Japan, about 155 cases per year were reported from 1946 to 1982 [20]; however, now, it has been reduced to 50 cases in a year. On the other hand, in Brazil, the cases have increased progressively, from 13 cases to 759 from 1987–1997 to 1998–2004 [21]. In another study from Brazil [22], approximately 2200 cases have been reported between 1998 and 2009, the largest cohort of human sporotrichosis on record worldwide.

## Age, Gender, and Occupation Distribution of Sporotrichosis

Although sporotrichosis is thought to be more common in certain age groups and/or genders, the truth is that it can affect anyone, regardless of gender or age. It all depends on exposure. Diverse populations have different occupational and leisure habits, which increase the risk of infection; for example, in Uruguay, males and armadillo hunters have a higher prevalence of sporotrichosis, as the former become infected via scratches obtained while armadillo hunting [23]. In Japan and Northeast India, females have a higher incidence, owing to their greater involvement in agricultural activities [24, 25]. However, in South Africa, as males are more involved in outdoor and mining activities than females, they have a rate of 3:1 [26]. In the Peruvian Andes, compared to adults, children have a threefold higher incidence. Playing in crop fields and on dirty floors in households are two plausible mechanisms of exposure in these children, according to case-controlled studies [19]. Remarkably, even newborns have been known to contract sporotrichosis if they are exposed [27].

## Types of Sporotrichosis

Sporotrichosis is broadly classified into two categories.

### I. Cutaneous sporotrichosis

It includes three clinically discrete forms: first is the most common and typical form, cutaneous-lymphatic sporotrichosis, generally seen on arms,

legs, and the face of the individual. It represents painful, linearly distributed, and pruriginous ulcerated nodules that might become verrucous plaques in chronic stages. Cutaneous-fixed sporotrichosis is the second form that arises at the inoculation site, also known as sporotrichoid chancre, typically containing a vegetative asymptomatic, slow-growing verrucous lesion, and a squamous, violaceous, or erythematous halo [28–30, 31•]. The third form is cutaneous-disseminated sporotrichosis which is also termed hematogenous sporotrichosis. It is a rare form and is generally present in immunocompromised individuals [10, 29, 32]. The clinical symptoms include verrucous plaques and ulcerated nodules [33]. Most of the cases may be related to cat scratches and develop in individuals with immunocompetency [10, 34].

It can affect any area of the body, including mucous membranes present in various parts of the body like the mouth, pharynx, glans penis and develop ulcerations and sinus plaques in one-third of the patients [35–37]. It can affect joints and bones, causing minor to significant lytic lesions, joint effusions, osteomyelitis, edema, and acute pain. The most commonly affected bones are the carpels, metacarpus, tibia, knee, ulna, and ankle [38–41]. There have been reports of osteoarticular instances or sporotrichoid arthritis without involvement in cutaneous tissue resulting in pulmonary or hematogenous spread [10, 42]. Cutaneous-disseminated sporotrichosis can spread to a variety of organs and systems, e.g., the testes, the central nervous system, leading to fungemia [36, 37, 43].

## II. Extracutaneous sporotrichosis

This occurs when the infection spreads to another part of the body beyond the skin. One of the extracutaneous sporotrichosis is pulmonary sporotrichosis which is a rare form. Only about 100 cases have been reported so far [42, 44, 45] and mostly those are of primary disease type and typically reported in high prevalent areas. It is divided into two clinical forms. First, the chronic form is the most common type. It usually remains asymptomatic (98% of cases). This type has restricted cavitory zones that are indistinguishable from tuberculosis; symptomatic patients have a cough and little expectoration. Condensation or infiltrating miliar type 2 is visible on the radiographs. The acute and progressive variety causes extensive adenopathies in the tracheobronchial lymph nodes, which can lead to bronchial blockage; frequent symptoms include cough with profuse expectoration, dyspnea, and exhaustion. Perihilar lymphadenopathy and, less occasionally, mediastinal enlargement can

be seen on a chest X-ray. One of the most lethal consequences of sporotrichosis is central nervous system involvement. It has been recorded in individuals with significant immunosuppression, frequently as a result of leukemia or post-transplantation therapy; nevertheless, the majority of cases are linked to HIV/AIDS and zoonotic outbreaks [36, 46].

*Sporothrix brasiliensis* is the most prevalent cause of these infections; invasion appears to happen in around 17% of the cases, though the actual incidence is not known [46]. Meningoencephalitis and hydrocephalus are signs of central nervous system involvement; clinical symptoms include headache, neck stiffness, fever, vomiting, and mental disorientation; cryptococcosis is the main differential diagnosis [10, 44]. It is also worth noting that immune reconstitution inflammatory syndrome can arise as a result of antiretroviral therapy; it is believed to affect about 7% of people and can exhibit itself in a variety of ways [37, 46, 47]. Sinuses, lungs, skin, liver, eyes, kidney, heart, and genitalia are all affected by disseminated sporotrichosis (endocarditis). Clinical symptoms vary, and the necropsy is frequently used to detect them [48].

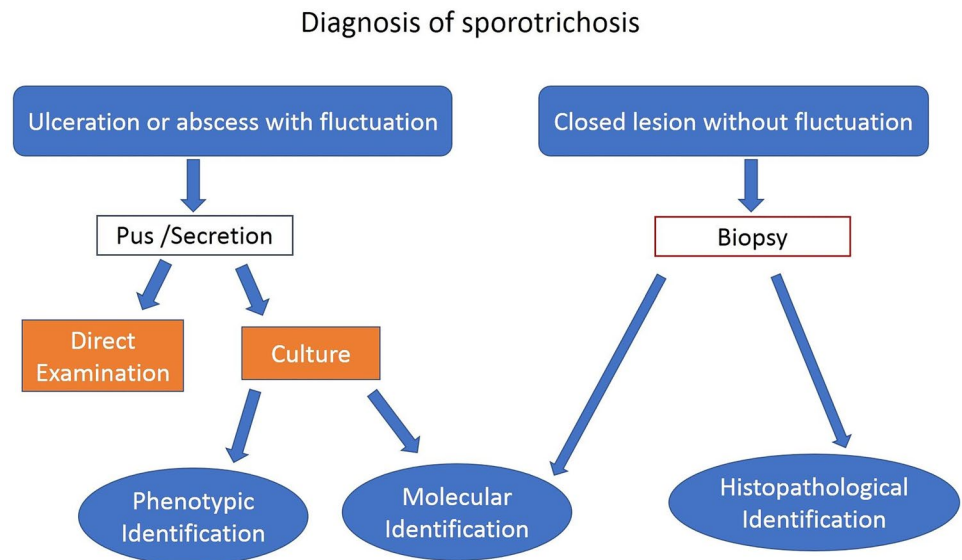
## Diagnosis of Sporotrichosis

The disease must be distinguished from other similar diseases like chromoblastomycosis, cutaneous leishmaniasis, cutaneous tuberculosis, blastomycosis, paracoccidioidomycosis, nocardiosis, and atypical mycobacteriosis [49, 50]. Pyoderma gangrenosum also shows similar ulcerating lesions [51]. The detailed scheme of the diagnosis is presented in Fig. 1.

### (A) Direct examination

Direct examination of specimens is generally carried out by 10% potassium hydroxide to see budding yeast cells. These cells are smaller in size (2 to 6  $\mu\text{m}$  in diameter) and dispersed, thus not easy to detect by direct examination of human specimens [10]. Because of the scarcity of fungal cells, testing of biopsy or pus specimen smear for causal fungus may not be an appropriate procedure for diagnosis. When examined, the lesion with Gomori-methenamine silver (GMS) or periodic acid-Schiff (PAS) stains after fine-needle aspiration cytology could seldom display yeast cells and cigar-shaped entities, epithelioid cell granuloma, and/or asteroid bodies [52, 53]. On the other hand, the sensitivity/specificity of tissue sample examination by direct microscopy is understudied because it is considered a useless diagnostic tool by most of the researchers due to the scarcity of fungal cells.

**Fig. 1** Detailed scheme of the diagnosis of sporotrichosis



### (B) Histopathology

The histopathology for sporotrichosis disease is typically vague because of its resemblance with other granulomatous diseases (sarcoidosis, cutaneous tuberculosis, deep fungal infections, and foreign body granulomas) [54]. The foremost histopathologic characteristics of cutaneous sporotrichosis contain epidermal hyperplasia, hyperkeratosis at the edge, central ulceration of epidermis, and acanthosis. In the upper and mid-dermis, there is generally a condensed cellular infiltrate with plasma cells, lymphocytes, and a variable number of eosinophils, giant cells with or without fibrocapillary proliferation, and epithelioid histiocytes [55]. Three concentric zones are indicative of lymphocutaneous sporotrichosis nodules; amorphous debris and polymorphonuclear leukocytes are found in the central necrotic zone (zone of chronic suppuration); epithelioid cells and large cells make up the middle tuberculoid zone. (largely Langhans' type). The outer zone contains a large number of plasma cells, lymphocytes, and fibroblasts, all of which have notable proliferation and capillary hyperplasia (syphiloid zone) [54, 55]. In histological sections stained with GMS or PAS, the fungal elements can be seen within these zones if they are present. In the gigantic cell's cytoplasm or in asteroid bodies center, they present as globose, cigar-shaped cells, budding yeast-like cells, or oval to spherical or solitary budding yeast forms [53, 56]. The use of direct immunofluorescence and particular immunohistochemistry procedures to demonstrate them is thought to be more sensitive and specific [57]. Asteroid bodies, on the other hand, are not only associated with the pathogenesis of sporotrichosis and can be seen in various infectious and/or granulomatous disorders [58].

### (C) Culture

Although the morphology of the many sporothrix species is similar, the only pathogenic strain is *S. schenckii*. *S. schenckii* can be isolated from skin biopsy or other clinical samples (synovial fluid, pus, sputum, and cerebrospinal fluid) and cultured at 25 °C on brain heart infusion agar, Sabouraud's glucose agar, or Mycosel. The visible growth is achieved in 1 to 2 weeks [53]. Its yeast form is produced by incubating colonies in brain–heart infusion broth or blood glucose-cysteine agar at 37 °C. Generally, *S. schenckii* is recognized through its typical colony morphology, microscopic appearance, and temperature dimorphism (the ability to live as a yeast at 37 °C and as a mold at 25 °C) [48].

### (D) Molecular diagnosis

Because of large differences in specificity and sensitivity, the diagnostic usefulness of all of these tests for sporotrichosis diagnosis is not consistent. Furthermore, due to their inaccessibility for routine diagnostic use, these tests remain of limited usefulness. Nonetheless, they can help to establish a diagnostic suspicion and trigger a more thorough investigation. The antibody titer can be measured by agglutination, immunoblotting, and enzyme-linked immunosorbent assay. Furthermore, for identification of *S. schenckii* in exudates, tissues, and culture, polymerase chain reaction and restriction fragment length polymorphism using calmodulin gene are useful in diagnosis [59, 60]. These are typically suitable diagnosis strategies, particularly when clinical lesions cannot be assessed.



## Therapeutic Options

Natural recovery is very rare and treatment is required for most of the patients [61]. Low cost, safety profile, the convenience of administration, and the site of infection (disseminated or localized) are all factors that influence treatment selection. Despite concerns about drug-related side effects, severe and systemic infection will necessitate more vigorous therapy. All therapies should result in the suppression of active infection and *S. schenckii* eradication from tissues. Treatment for sporotrichosis lasts 3–6 months, although to ensure mycological cure any treatment must be continued for at least 4–6 weeks beyond complete clinical remission. Following adequate therapy for cutaneous sporotrichosis, complete recovery without scarring is anticipated, despite the fact that treatment is time-consuming and costly [62, 63]. Immunocompromised patients typically need suppressive therapy for their whole life. Since its introduction in the nineteenth century, a saturated potassium iodide solution has been the conventional treatment for uncomplicated disease and remains so in poor nations.

### (A) Potassium iodide

Oral saturated solution of potassium iodide (SSKI) continues to be the first-line, low-cost treatment for cutaneous sporotrichosis, particularly when itraconazole is prohibitively expensive, though it is not useful in extracutaneous sporotrichosis. Some researchers believe that this affects granuloma clearance by increasing proteolysis, while others believe it enhances phagocytosis. The actual method of action, however, is uncertain [64]. However, it is not reported to increase *S. schenckii* killing by monocytes or neutrophils. At 10% SSKI, *S. schenckii* can grow, indicating that it has no antifungal or antifungicidal effect. It has been proposed that there is in vivo conversion of SSKI into iodine by myeloperoxidase and then display its cidal effect, as evidenced by inhibition of cell germination and their direct destruction upon exposure to the iodine-potassium-iodine solution [65].

It remains the most widely practiced treatment in both lymphocutaneous sporotrichosis and fixed cutaneous. It has also been shown to be effective even in circumstances when itraconazole has not worked [33, 66]. There are no particular guidelines/recommendations or treatment plans available. SSKI is commonly administered with 5 drops, comprising 1 g/mL potassium iodide, three times a day orally as a starting dose. There is a gradual rise of dose by 5 drops every day, with 30 to 40 drops maximum, till the complete cure is achieved. Within 2 weeks, the response is visible, and recovery takes 4–32 weeks [67, 68]. However, this schedule is

incomprehensible, especially for patients who work outside for a longer period of time, resulting in low compliance.

Some potential side effects include hyperthyroidism or hypothyroidism, iododerma, vasculitis, cardiac irritability, pulmonary edema and angioedema, pustular psoriasis, urticaria, myalgia, lymphadenopathy, and eosinophilia [69]. Patients with a faulty autoregulation system that maintains thyroid hormone production are more likely to develop hypothyroidism as a result of SSKI therapy. In the case of iatrogenic hypothyroidism, stopping SSKI will generally reestablish normal thyroid function within a month. Potassium toxicity can occur in patients on angiotensin-converting enzyme inhibitors, potassium-sparing diuretics, or those with renal impairment, necessitating vigilant monitoring throughout SSKI therapy. SSKI is now classified as a pregnancy category D medication. Patients who acquire “flu-like syndrome” or SSKI hypersensitivity should not resume SSKI therapy since they will have unpleasant effects even at modest dosages [70].

### (B) Itraconazole

It is efficacious and well-tolerated at doses of 100–200 mg every day, which has essentially replaced amphotericin B and SSKI in cutaneous and extracutaneous sporotrichosis due to its 90–100% efficacy rates [71]. Itraconazole is also utilized in pulse treatments since it lasts 3–4 weeks in the stratum corneum after it is stopped. In spite of its expensive price, it became the treatment of choice for cutaneous (fixed and lymphocutaneous) and osteoarticular sporotrichosis with success rates ranging from 90 to 100% [72]. According to present guidelines from the Infectious Diseases Society of America, it is given as an oral dose of 200–400 mg for 3 to 6 months and 1 year for disseminated and osteoarticular forms [61]. Despite reported elapses or therapeutic failures, itraconazole is a viable alternative in SSKI-intolerant patients or readily availability/affordability of itraconazole [73]. Epigastric pain, nausea, peripheral edema, hypertriglyceridemia or hypercholesterolemia, and abnormal liver function tests are some of the more common side effects. Another limitation is that the treatment outcome is unpredictable.

### (C) Fluconazole

This is a broad-spectrum synthetic biazole antifungal drug. It selectively prevents the activity of fungal cytochrome P-450, required for demethylation of sterol C-14- $\alpha$  to ergosterol which is a vital component of the fungal membrane. It provides another valuable therapeutic option either alone or with SSKI orally. Doses range from 150 mg once a week to 200 mg daily for the treatment of both lymphocutaneous and fixed sporotri-

chosis [74, 75]. Though greater doses of 400 to 600 mg per day are often suggested for the treatment of visceral and osteoarticular sporotrichosis, the response is not encouraging [38]. Vomiting, nausea, diarrhea, headache, abdominal pain, and altered liver enzymes are all typical side effects that rarely need therapy withdrawal. Because of its teratogenic risk, it is not recommended during pregnancy. Fluconazole therapy for sporotrichosis is a second-line therapeutic option for individuals who are itraconazole intolerant because it is somewhat effective [76].

(D) Ketoconazole

It has a poor response rate and is not indicated for the treatment of sporotrichosis. Hepatotoxicity is another constraint for its use, aside from its low efficacy, which is even lower than fluconazole [77].

(E) Terbinafine

Terbinafine is another option for treating itraconazole-resistant cutaneous or lymphocutaneous sporotrichosis or when there is intolerance to itraconazole. It functions well when taken orally and has a low cytochrome P450 enzyme binding affinity. Because it is extremely lipophilic, its antifungal activity is preserved in adipose tissue for a few weeks post-treatment. However, there is no agreement on the best terbinafine dosage and duration schedule. In a limited series or case reports, it has been given alone or in combination with SSKI for the treatment of a few individuals in doses 125–1000 mg/day for 4–37 weeks to attain medical cure. It is now classified as a pregnancy category B medication [78].

(F) Amphotericin B

It is a lipophilic polyene macrolide antibiotic derived from *Streptomyces nodosus* which is mostly used as an antifungal drug intravenously or topically. It is a treatment of choice for pulmonary/meningeal sporotrichosis and/or severely resistant and disseminated cutaneous sporotrichosis and is safer during pregnancy. It may also be used in individuals with significant osteoarticular sporotrichosis or who are unresponsive to itraconazole therapy, although it is not recommended for intra-articular usage [72]. After the initial 1-mg intravenous testing dose, the recommended adult dose of 0.25 mg/kg/day is raised to obtain the desired dose of 2–3 g. Pre-medication with antipyretics, sedatives, and corticosteroids can alleviate headache, chills, fever, malaise, and vomiting that may occur following administration of the drug. Hypomagnesemia, hypokalemia, reversible normochromic normocytic anemia, and nephrotoxicity are all common side effects that must be monitored once a week [79, 80]. Amphotericin B's safety profile has been improved thanks to new lipid formulations that offer

higher drug concentrations and reduce nephrotoxicity. Depending on the severity of the disease, it is commonly given at a dose of 3–5 mg/kg of lipid formulation or 0.7 to 1.0 mg/kg/day of amphotericin B deoxycholate. Despite the lack of guidelines due to amphotericin B's inconsistent therapeutic response, itraconazole is usually prescribed in the early stages of treatment until a good response is achieved, after which itraconazole is prescribed for the remainder of the treatment period [61].

(G) Treatment in pregnancy and pediatric patients

Currently, SSKI is classified as a pregnancy category D medicine, and it is not suggested for use in pregnancy or during lactation due to the possibility of developing thyromegaly and/or neonatal hypothyroidism unless the benefits overshadow the hazards. Terbinafine should not be used during pregnancy, and azoles should be avoided at all costs. Skinny sporotrichosis that does not require immediate treatment can be treated with local heating. Liposomal amphotericin B (3–5 mg/kg/day) can be used to treat sporotrichosis that needs to be treated during pregnancy. It is recommended to postpone the treatment in pregnant patients because there is little risk of sporotrichosis intensifying or spreading to the fetus. The incidence of sporotrichosis in children is less than in adult but are not rare. The children can be treated with half of the adult dose of SSKI, up to 15 drops three times daily, or itraconazole 6–10 mg/kg/day (max 400 mg/day) for 3 to 4 months, just as adults [81]. SSKI, terbinafine, and itraconazole have all been shown to be effective in treating sporotrichosis in infants under the age of 10 months. However, the lack of pediatric antifungal formulations continues to be a problem. Another alternative for children with minimal cutaneous illness is local heat therapy [27].

(H) Treatment of sporotrichosis in patients with immunosuppression

The only sign of an infection spreading to the central nervous system/meninges in immunocompromised people is mild changes in mental status. In these individuals, the medicine of choice is recommended doses of liposomal amphotericin B and will require suppressive therapy with itraconazole 200 mg/day orally for the rest of their lives, as eradication of the pathogen may not be possible [8, 82]. In the patients with AIDS, initial course of treatment is amphotericin B followed by itraconazole that may be useful for lifelong maintenance therapy in these patients. Furthermore, itraconazole can be used as primary therapeutic option for non-life-threatening disease in those patients who are intolerant to amphotericin B [83].

(I) Treatment of patients with ocular sporotrichosis

The first option for the ocular sporotrichosis is itraconazole at a dose of 100–300 mg/day depending upon

the condition and weight of the patient with variable duration of treatment from 4 to 6 months. Another drug is SSKI which is cost effective, has good efficacy, has less side effects, and is mainly used in underdeveloped countries. The 2–20 drops of SSKI three times a day for 2–3 months are used. It also has been administered in combination with itraconazole in those that did not respond well to SSKI alone. The most commonly used treatment for intraocular infections is systemic amphotericin B alone or in combination with an oral antifungal. The suggested dose of amphotericin B is 3–5 mg/kg/day with a variable treatment time depending upon the side effects. Terbinafine is another drug of choice as it has fewer drug interactions and side effects at doses of 250–500 mg/day [84••].

The overview of the treatment option available with the respective dosages and use in different types of patients is provided in Table 1.

### Possible Candidates for Vaccine

Although no vaccine is available against sporotrichosis, however, various studies are going on focusing on the vaccine development for sporotrichosis. Identification of a few antigens as a possible candidate for the vaccine may lead to the better and more effective prevention of sporotrichosis. The involvement of proteins found in the sporothrix

cell wall that can trigger an immunological response in the host and hence provide an immunoprotective effect has been investigated. In mice afflicted with highly virulent strains of sporothrix, a monoclonal antibody against cell wall Gp70 glycoprotein was employed as a therapeutic vaccination resulting in a reduction in the fungus burden on the organs studied [85]. Few animal studies identified four antigenic molecules (a 44-kDa peptide hydrolase, a 47-kDa enolase, which was predicted to be an adhesin, a 71-kDa protein, and a 9.4-kDa peptide) from *S. schenckii* cell wall proteins with their possible efficacy and toxicity that represent their potential as a putative candidate for the development of the vaccine. Out of these four antigens, enolase was found to be a possible potential antigenic target against sporotrichosis for vaccinal purposes [86••, 87].

Several other studies have reported additional potential molecules as a target for vaccine development. These include 3-carboxymuconate cyclase (GP60-70), an endoplasmic signal peptidase, and the ZR8 peptide from the GP60-70 protein. Out of these, ZR8 peptide induces the cellular immune response by higher levels of cytokines like IFN- $\gamma$ , IL-17A, and IL-1 $\beta$  as well as an elevated number of CD4 + T cells. Furthermore, it also increases the number of neutrophils in the lesions responsible for fungus clearance. All, these properties make the ZR8 peptide the best potential vaccine candidate [88–90].

**Table 1** Overview of the treatment option available

S. no.	Name of drug	Dosages	Used in pregnant patients	Used in pediatric patients	References
1	<b>Potassium iodide (KI)</b>	<ul style="list-style-type: none"> <li>●5 drops, comprising 1 g/mL KI, three times a day orally as a starting dose</li> <li>●Gradual rise of dose by 5 drops every day, with a 30 to 40 drops maximum</li> </ul>	No	Up to 15 drops three times daily	[67, 68]
2	<b>Itraconazole</b>	<ul style="list-style-type: none"> <li>●Oral dose of 200–400 mg</li> </ul>	No	6–10 mg/kg/day (max 400 mg/day)	[61]
3	<b>Fluconazole</b>	<ul style="list-style-type: none"> <li>●150 mg once a week to 200 mg daily for the treatment of both lymphocutaneous and fixed sporotrichosis</li> <li>●400 to 600 mg per day are often suggested for treatment of visceral and osteoarticular sporotrichosis,</li> </ul>	No	Yes	[38, 74, 75]
4	<b>Terbinafine</b>	125–1000 mg/day	No	Yes	[78]
5	<b>Amphotericin B</b>	<ul style="list-style-type: none"> <li>●Initial 1-mg intravenous testing dose,</li> <li>●0.25 mg/kg/day to 2–3 g</li> <li>●3–5 mg/kg of lipid formulation or 0.7 to 1.0 mg/kg/day of amphotericin B deoxycholate</li> </ul>	3-5 mg/kg/ day	–	[61, 79, 80]

## Conclusion

Sporotrichosis is an emerging fungal infection worldwide. Early diagnosis remains a difficulty for treating clinicians, and future research should focus on developing novel diagnostic methods with a faster turnaround time than culture. Over the years, significant progress has been made in the treatment of sporotrichosis. However, it is still undiscovered, and many new therapeutic compounds are now under the preclinical, clinical, and developmental phase. Various treatment options which are available must be used cautiously and efficiently as cost, availability, and the emergence of drug resistance and toxicity in a particular type of sporotrichosis must be considered. Various researchers are now focusing on the development of anti-sporothrix vaccines for prophylactic and therapeutic use against sporotrichosis.

**Acknowledgements** We sincerely apologize to those whose work could not be cited owing to space limitations. The authors are grateful to the M.M. (Deemed to be University) for providing the requisite platform to write this article. The authors wish to thank Dr. Humanshu Sharma for reviewing their manuscript.

## Compliance with Ethical Standards

**Conflict of Interest** There exists no conflict of interest amongst authors regarding publications of this manuscript.

**Human and Animal Rights and Informed Consent** This article does not contain any studies with human or animal subjects performed by any of the authors.

## References

### Papers of particular interest, published recently, have been highlighted as:

- Of importance
- Of major importance

1. Kauffman CA. Sporotrichosis. *Clin Infect Dis*. 1999;29:231–6.
2. Welsh RD. Sporotrichosis JAVMA. 2003;223:1123–6.
3. Sporotrichosis among hay-mulching workers. *Oklahoma, New Mexico. MMWR Morb Mortal Wkly Rep*. 1984;33:682–3.
4. Multistate outbreak of sporotrichosis in seedling handlers. *MMWR Morb Mortal Wkly Rep*. 1988;37:652–3.
5. Dixon DM, Salkin IF, Duncan RA, Hurd NJ, Haines JH, Kemna ME, et al. Isolation and characterization of *Sporothrix schenckii* from clinical and environmental sources associated with the largest U.S. epidemic of sporotrichosis. *J Clin Microbiol*. 1991;29:1106–13.
6. Ricks D. Disney World topiary workers are infected with sporotrichosis. *Orlando Sentinel* 1994;B1.
7. Donabedian H, O'Donnell E, Olszewski C, MacArthur RD, Budd N. Disseminated cutaneous and meningeal sporotrichosis in an AIDS patient. *Diagn Microbiol Infect Dis*. 1994;18:111–5.
8. al-Tawfiq JA, Wools KK. Disseminated sporotrichosis and *Sporothrix schenckii* fungemia as the initial presentation of human immunodeficiency virus infection. *Clin Infect Dis*. 1998;26:1403–6.
9. López-Romero E, Reyes-Montes MDR, Pérez-Torres A, Ruiz-Baca E, Villagómez-Castro JC, Mora-Montes HM, et al. *Sporothrix schenckii* complex and sporotrichosis, an emerging health problem. *Future Microbiol*. 2011;6:85–102.
10. Barros MB, de Almeida PR, Schubach AO. *Sporothrix schenckii* and Sporotrichosis. *Clin Microbiol Rev*. 2011;24:633–54.
11. Sil A, Andrianopoulos A. Thermally dimorphic human fungal pathogens–polyphyletic pathogens with a convergent pathogenicity trait. *Cold Spring Harb Perspect Med*. 2014;5:a019794.
12. Sizar O, Talati R. Sporotrichosis. 2021 Jun 29. In: StatPearls [Internet]. Treasure Island (FL): StatPearls Publishing, 2022.
13. Rooney PJ, Klein BS. Linking fungal morphogenesis with virulence. *Cell Microbiol*. 2002;4:127–37.
14. Pal M, Dave P. Sporotrichosis: an infectious emerging mycosis of zoonotic potential. *Annals of Biological Sciences*. 2017;5:1–4.
15. Gremião ID, Miranda LH, Reis EG, Rodrigues AM, Pereira SA. Zoonotic epidemic of sporotrichosis: cat to human transmission. *PLoS Pathog*. 2017;13:e1006077. **A review discussing about the transmission of disease from animals (cat) to humans.**
16. Sharma R, Mahajan VK, Chauhan PS, Sharma A, Sharma J. The clinico-epidemiological characteristics and therapeutic experience of 152 patients with cutaneous sporotrichosis: a 10-year retrospective study from India. *Int J Dermatol*. 2021;60:99–106.
17. Chakrabarti A, Bonifaz A, Gutierrez-Galhardo MC, Mochizuki T, Li S. Global epidemiology of sporotrichosis. *Med Mycol*. 2015;53:3–14.
18. Pappas PG, Tellez I, Deep AE, Nolasco D, Holgado W, Bustamante B. Sporotrichosis in Peru: description of an area of hyperendemicity. *Clin Infect Dis*. 2000;30:65–70.
19. Lyon GM, Zurita S, Casquero J, Holgado W, Guevara J, Brandt ME, et al. Sporotrichosis in Peru Investigation Team. Population-based surveillance and a case-control study of risk factors for endemic lymphocutaneous sporotrichosis in Peru. *Clin Infect Dis*. 2003;36:34–9.
20. Mochizuki T, Anzawa K. Deep mycosis in Japan. In: Eun HC, Kim SC, Lee WS, editors. *Aging and skin diseases. Special book of the 22nd World Congress of Dermatology*. Seoul, Korea: Medrang Inc; 2011. p. 393–97.
21. Schubach A, Barros MB, Wanke B. Epidemic sporotrichosis. *Curr Opin Infect Dis*. 2008;21:129–33.
22. Barros MB, Schubach TP, Coll JO, Gremião ID, Wanke B, Schubach A. Sporotrichosis: development and challenges of an epidemic. *Rev Panam Salud Publica*. 2010;27:455–60.
23. Rodrigues AM, Bagagli E, de Camargo ZP, de Moraes Gimenes Bosco S. *Sporothrix schenckii* sensu stricto isolated from soil in an armadillo's burrow. *Mycopathologia*. 2014;177:199–206.
24. Fukushima R. Epidemiology and ecology of sporotrichosis in Japan. *Zentralbl Bakteriell Mikrobiol Hyg A*. 1984;257:228–33.
25. Bhutia PY, Gurung S, Yegneswaran PP, Pradhan J, Pradhan U, Peggy T, et al. A case series and review of sporotrichosis in Sikkim. *J Infect Dev Ctries*. 2011;5:603–8.
26. Vismar HF, Hull PR. Prevalence, epidemiology and geographical distribution of *Sporothrix schenckii* infections in Gauteng. *South Afr Mycopathologia*. 1997;137:137–43.
27. Song Y, Yao L, Zhong SX, Tian YP, Liu YY, Li SS. Infant sporotrichosis in northeast China: a report of 15 cases. *Int J Dermatol*. 2011;50:522–9.
28. Schechtman RC. Sporotrichosis: Part I. *Skinmed*. 2010;8:216–20.



29. Bonifaz A, Vázquez-González D. Sporotrichosis: an update. *G Ital Dermatol Venereol*. 2010;145:659–73.
30. Song Y, Li SS, Zhong SX, Liu YY, Yao L, Huo SS. Report of 457 sporotrichosis cases from Jilin province, Northeast China, a serious endemic region. *J Eur Acad Dermatol Venereol*. 2013;27:313–8.
31. Takenaka M, Yoshizaki A, Utani A, Nishimoto K. A survey of 165 sporotrichosis cases examined in Nagasaki prefecture from 1951 to 2012. *Mycoses*. 2014;57:294–8. **A study on the prevalence of type of sporotrichosis and treatment available.**
32. Severo LC, Festugato M, Bernardi C, Londero AT. Widespread cutaneous lesions due to *Sporothrix schenckii* in a patient under a long-term steroids therapy. *Rev Inst Med Trop Sao Paulo*. 1999;41:59–62.
33. Fujii H, Tanioka M, Yonezawa M, Arakawa A, Matsumura Y, Kore-eda S, et al. A case of atypical sporotrichosis with multifocal cutaneous ulcers. *Clin Exp Dermatol*. 2008;33:135–8.
34. Sanchotene KO, Madrid IM, Klafke GB, Bergamashi M, Della Terra PP, Rodrigues AM, et al. *Sporothrix brasiliensis* outbreaks and the rapid emergence of feline sporotrichosis. *Mycoses*. 2015;58:652–8.
35. Fontes PC, Kitakawa D, Carvalho YR, Brandão AA, Cabral LA, Almeida JD. Sporotrichosis in an HIV-positive man with oral lesions: a case report. *Acta Cytol*. 2007;51:648–50.
36. Freitas DF, de Siqueira Hoagland B, do Valle AC, Fraga BB, de Barros MB, de Oliveira Schubach A, et al. Sporotrichosis in HIV-infected patients: report of 21 cases of endemic sporotrichosis in Rio de Janeiro, Brazil. *Med Mycol*. 2012;50:170–78.
37. Freitas DF, Valle AC, da Silva MB, Campos DP, Lyra MR, de Souza RV, et al. Sporotrichosis: an emerging neglected opportunistic infection in HIV-infected patients in Rio de Janeiro, Brazil. *PLoS Negl Trop Dis*. 2014;8:e3110.
38. Kauffman CA, Pappas PG, McKinsey DS, Greenfield RA, Perfect JR, Cloud GA, et al. Treatment of lymphocutaneous and visceral sporotrichosis with fluconazole. *Clin Infect Dis*. 1996;22:46–50.
39. Gordhan A, Ramdial PK, Morar N, Moodley SD, Aboobaker J. Disseminated cutaneous sporotrichosis: a marker of osteoarticular sporotrichosis masquerading as gout. *Int J Dermatol*. 2001;40:717–79.
40. de Carvalho AF, Trope BM, Fernandes NC, Engel DC, Ramos-E-Silva M. Sporotrichosis with bone involvement: an alert to an occupational disease. *Case Rep Dermatol*. 2014;6:114–8.
41. Lederer HT, Sullivan E, Crum-Cianflone NF. Sporotrichosis as an unusual case of osteomyelitis: a case report and review of the literature. *Med Mycol Case Rep*. 2016;11:31–5.
42. Aung AK, Spelman DW, Thompson PJ. Pulmonary sporotrichosis: an evolving clinical paradigm. *Semin Respir Crit Care Med*. 2015;36:756–66.
43. Castrejón OV, Robles M, Zubieta Arroyo OE. Fatal fungaemia due to *Sporothrix schenckii*. *Mycoses*. 1995;38:373–6.
44. Callens SF, Kitetele F, Lukun P, Lelo P, Van Rie A, Behets F, et al. Pulmonary *Sporothrix schenckii* infection in a HIV positive child. *J Trop Pediatr*. 2006;52:144–6.
45. Orofino-Costa R, Unterstell N, Carlos Gripp A, de Macedo PM, Brota A, Dias E, et al. Pulmonary cavitation and skin lesions mimicking tuberculosis in a HIV negative patient caused by *Sporothrix brasiliensis*. *Med Mycol Case Rep*. 2013;2:65–71.
46. Moreira JA, Freitas DF, Lamas CC. The impact of sporotrichosis in HIV-infected patients: a systematic review. *Infection*. 2015;43:267–76.
47. Freitas DF, Lima MA, de Almeida-Paes R, Lamas CC, do Valle AC, Oliveira MM, et al. Sporotrichosis in the central nervous system caused by *Sporothrix brasiliensis*. *Clin Infect Dis*. 2015;61:663–4.
48. Bonifaz A, Tirado-Sánchez A. Cutaneous disseminated and extracutaneous sporotrichosis: current status of a complex disease. *J Fungi (Basel)*. 2017;3:6.
49. Sharma RC, Sharma NL. Sporotrichoid reactions to mycobacterial infections. *Indian J Dermatol Venereol Leprol*. 1994;60:283–5.
50. De Araujo T, Marques AC, Kerdel F. Sporotrichosis. *Int J Dermatol*. 2001;40:737–42.
51. Byrd DR, El-Azhary RA, Gibson LE, Roberts GD. Sporotrichosis masquerading as pyoderma gangrenosum: case report and review of 19 cases of sporotrichosis. *J Eur Acad Dermatol Venereol*. 2001;15:581–4.
52. Zaharopoulos P. Fine-needle aspiration cytologic diagnosis of lymphocutaneous sporotrichosis: a case report. *Diagn Cytopathol*. 1999;20:74–7.
53. Morris-Jones R. Sporotrichosis. *Clin Exp Dermatol*. 2002;27:427–31.
54. Mahajan VK, Sharma NL, Sharma RC, Gupta ML, Garg G, Kanga AK. Cutaneous sporotrichosis in Himachal Pradesh. *India Mycoses*. 2005;48:25–31.
55. Hirsh BC, Johnson WC. Pathology of granulomatous diseases. Mixed inflammatory granulomas. *Int J Dermatol*. 1984;23:585–97.
56. Rodríguez G, Sarmiento L. The asteroid bodies of sporotrichosis. *Am J Dermatopathol*. 1998;20:246–9.
57. Irizarry-Rovira AR, Kaufman L, Christian JA, Reberg SR, Adams SB, DeNicola DB, et al. Diagnosis of sporotrichosis in a donkey using direct fluorescein-labeled antibody testing. *J Vet Diagn Invest*. 2000;12:180–3.
58. Civilia ES, Bonasse J, Conti-Díaz IA, Vignale RA. Importance of the direct fresh examination in the diagnosis of cutaneous sporotrichosis. *Int J Dermatol*. 2004;43:808–10.
59. Scott EN, Muchmore HG. Immunoblot analysis of antibody responses to *Sporothrix schenckii*. *J Clin Microbiol*. 1989;27:300–4.
60. Rodrigues AM, de Hoog GS, de Camargo ZP. Genotyping species of the *Sporothrix schenckii* complex by PCR-RFLP of calmodulin. *Diagn Microbiol Infect Dis*. 2014;78:383–7.
61. Kauffman CA, Bustamante B, Chapman SW, Pappas PG; Infectious Diseases Society of America. Clinical practice guidelines for the management of sporotrichosis. update by the Infectious Diseases Society of America. *Clin Infect Dis*. 2007;2007(45):1255–65.
62. Purvis RS, Diven DG, Drechsel RD, Calhoun JH, Tyring SK. Sporotrichosis presenting as arthritis and subcutaneous nodules. *J Am Acad Dermatol*. 1993;28:879–84.
63. Sharma NL, Mehta KI, Mahajan VK, Kanga AK, Sharma VC, Tegta GR. Cutaneous sporotrichosis of face: polymorphism and reactivation after intralesional triamcinolone. *Indian J Dermatol Venereol Leprol*. 2007;73:188–90.
64. Coskun B, Saral Y, Akpolat N, Ataseven A, Çiçek D. Sporotrichosis successfully treated with terbinafine and potassium iodide: case report and review of the literature. *Mycopathologia*. 2004;158:53–6.
65. Hiruma M, Kagawa S. Ultrastructure of *Sporothrix schenckii* treated with iodine-potassium iodide solution. *Mycopathologia*. 1987;97:121–7.
66. Sandhu K, Gupta S. Potassium iodide remains the most effective therapy for cutaneous sporotrichosis. *J Dermatolog Treat*. 2003;14:200–2.
67. Sharma VK, Kaur S, Kumar B, Talwar P, Joshi K, Kaur J, et al. Sporotrichosis in north western India (report of 5 cases). *Indian J Dermatol Venereol Leprol*. 1988;54:142–7.
68. Xue SL, Li L. Oral potassium iodide for the treatment of sporotrichosis. *Mycopathologia*. 2009;167:355–6.
69. Sterling JB, Heymann WR. Potassium iodide in dermatology: a 19th century drug for the 21st century—uses, pharmacology, adverse effects, and contraindications. *J Am Acad Dermatol*. 2000;43:691–7.
70. Mahajan VK. Sporotrichosis: an overview and therapeutic options. *Dermatol Res Pract*. 2014;2014:272376.
71. Kauffman CA, Hajjeh R, Chapman SW. Practice guidelines for the management of patients with sporotrichosis. For the Mycoses

- Study Group. Infectious Diseases Society of America. Clin Infect Dis. 2000;30:684–87.
72. Cabezas C, Bustamante B, Holgado W, Begue RE. Treatment of cutaneous sporotrichosis with one daily dose of potassium iodide. *Pediatr Infect Dis J*. 1996;15:352–4.
  73. Sharkey-Mathis PK, Kauffman CA, Graybill JR, Stevens DA, Hostetler JS, Cloud G, et al. Treatment of sporotrichosis with itraconazole. NIAID Mycoses Study Group. *Am J Med*. 1993;95:279–85.
  74. Castro LG, Belda Júnior W, Cucé LC, Sampaio SA, Stevens DA. Successful treatment of sporotrichosis with oral fluconazole: a report of three cases. *Br J Dermatol*. 1993;128:352–6.
  75. Ghodsi SZ, Shams S, Naraghi Z, Daneshpazhooh M, Akhyani M, Arad S, et al. Case report. An unusual case of cutaneous sporotrichosis and its response to weekly fluconazole. *Mycoses*. 2000;43:75–7.
  76. Pursley TJ, Blomquist IK, Abraham J, Andersen HF, Bartley JA. Fluconazole-induced congenital anomalies in three infants. *Clin Infect Dis*. 1996;22:336–40.
  77. Heel RC, Brogden RN, Carmine A, Morley PA, Speight TM, Avery GS. Ketoconazole: a review of its therapeutic efficacy in superficial and systemic fungal infections. *Drugs*. 1982;23:1–36.
  78. Francesconi G, Valle AC, Passos S, Reis R, Galhardo MC. Terbinafine (250 mg/day): an effective and safe treatment of cutaneous sporotrichosis. *J Eur Acad Dermatol Venereol*. 2009;23:1273–6.
  79. Mercurio MG, Elewski BE. Therapy of sporotrichosis. *Semin Dermatol*. 1993;12:285–9.
  80. Vásquez-del-Mercado E, Arenas R, Padilla-Desgarenes C. Sporotrichosis. *Clin Dermatol*. 2012;30:437–43.
  81. Bonifaz A, Saúl A, Paredes-Solis V, Fierro L, Rosales A, Palacios C, et al. Sporotrichosis in childhood: clinical and therapeutic experience in 25 patients. *Pediatr Dermatol*. 2007;24:369–72.
  82. Rocha MM, Dassin T, Lira R, Lima EL, Severo LC, Londero AT. Sporotrichosis in patient with AIDS: report of a case and review. *Rev Iberoam Micol*. 2001;18:133–6.
  83. Kauffman CA, Hajjeh R, Chapman sw, Mycoses Study Group. Practice guidelines for the management of patients with sporotrichosis. *Clin Infect Dis*. 2000;30:684–7.
  84. ●● Ramírez-Soto MC, Tirado-Sánchez A, Bonifaz A. Ocular sporotrichosis. *J Fungi (Basel)*. 2021;7:951. **This review discussed the ocular sporotrichosis diagnosis and treatment.**
  85. De Almeida JRF, Kaihama GH, Jannuzzi GP, De Almeida SR. Therapeutic vaccine using a monoclonal antibody against a 70-kDa glycoprotein in mice infected with highly virulent *Sporothrix schenckii* and *Sporothrix brasiliensis*. *Med Mycol*. 2014;53:42–50.
  86. ●● Rodrigues AM, Fernandes GF, Araujo LM, Della Terra PP, dos Santos PO, Pereira SA, Schubach TM, Burger E, Lopes-Bezerra LM, de Camargo ZP. Proteomics-based characterization of the humoral immune response in sporotrichosis: toward discovery of potential diagnostic and vaccine antigens. *PLoS Negl Trop Dis*. 2015;9:e0004016. **This article discusses about the vaccine target molecules.**
  87. Portuondo DL, Batista-Duarte A, Ferreira LS, de Andrade CR, Quinello C, Téllez-Martínez D, de Aguiar Loesch ML, Carlos IZ. Comparative efficacy and toxicity of two vaccine candidates against *Sporothrix schenckii* using either Montanide™ Pet Gel A or aluminum hydroxide adjuvants in mice. *Vaccine*. 2017;35:4430–4436.
  88. Della Terra PP, Rodrigues AM, Fernandes GF, Nishikaku AS, Burger E, de Camargo ZP. Exploring virulence and immunogenicity in the emerging pathogen *Sporothrix brasiliensis*. *PLoS Negl Trop Dis*. 2017;11:e0005903.
  89. de Almeida JRF, Jannuzzi GP, Kaihama GH, Breda LCD, Ferreira KS, de Almeida SR. An immunoproteomic approach revealing peptides from *Sporothrix brasiliensis* that induce a cellular immune response in subcutaneous sporotrichosis. *Sci Rep*. 2018;8:4192.
  90. Etchecopaz A, Toscanini MA, Gisbert A, Mas J, Scarpa M, Iovannitti CA, Bendezú K, Nusblat AD, Iachini R, Cuestas ML. *Sporothrix brasiliensis*: a review of an emerging South American fungal pathogen, its related disease, presentation and spread in Argentina. *J Fungi (Basel)*. 2021;7:170.
- Publisher's Note** Springer Nature remains neutral with regard to jurisdictional claims in published maps and institutional affiliations.