



Coronaviruses and the central nervous system

Susan Morgello¹

Received: 14 May 2020 / Revised: 4 June 2020 / Accepted: 10 June 2020 / Published online: 31 July 2020
© Journal of NeuroVirology, Inc. 2020

Abstract

Seven coronavirus (CoV) species are known human pathogens: the epidemic viruses SARS-CoV, SARS-CoV-2, and MERS-CoV and those continuously circulating in human populations since initial isolation: HCoV-OC43, HCoV-229E, HCoV-HKU1, and HCoV-NL63. All have associations with human central nervous system (CNS) dysfunction. In infants and young children, the most common CNS phenomena are febrile seizures; in adults, non-focal abnormalities that may be either neurologic or constitutional. Neurotropism and neurovirulence are dependent in part on CNS expression of cell surface receptors mediating viral entry, and host immune response. In adults, CNS receptors for epidemic viruses are largely expressed on brain vasculature, whereas receptors for less pathogenic viruses are present in vasculature, brain parenchyma, and olfactory neuroepithelium, dependent upon viral species. Human coronaviruses can infect circulating mononuclear cells, but meningoencephalitis is rare. Well-documented human neuropathologies are infrequent and, for SARS, MERS, and COVID-19, can entail cerebrovascular accidents originating extrinsically to brain. There is evidence of neuronal infection in the absence of inflammatory infiltrates with SARS-CoV, and CSF studies of rare patients with seizures have demonstrated virus but no pleocytosis. In contrast to human disease, animal models of neuropathogenesis are well developed, and pathologies including demyelination, neuronal necrosis, and meningoencephalitis are seen with both native CoVs as well as human CoVs inoculated into nasal cavities or brain. This review covers basic CoV biology pertinent to CNS disease; the spectrum of clinical abnormalities encountered in infants, children, and adults; and the evidence for CoV infection of human brain, with reference to pertinent animal models of neuropathogenesis.

Keywords Coronavirus · Central nervous system · Neurologic disease

Mammalian coronaviruses have well-documented ability to damage the central nervous system (CNS), and most recently, concerns have been raised that severe acute respiratory syndrome coronavirus 2 (SARS-CoV-2) may be neuroinvasive. Neurologic manifestations in up to 84% of patients hospitalized with COVID-19 have been described in series from China and France (Mao et al. 2020; Helms et al. 2020). Symptoms related to olfactory dysfunction have been interpreted as evidence of CNS involvement (Eliezer et al. 2020). There has been speculation that CNS infection contributes to respiratory failure in COVID-19 disease, similar to the “Ondine’s curse” of bulbar polio, in which virally mediated

damage to brainstem autonomic centers causes alveolar hypoventilation during sleep, when volitional control of breath is absent (Li et al. 2020; Baig et al. 2020). Opposite interpretations of these phenomena have been expressed. It has been noted that patients with COVID-19 pulmonary disease display hypoxia-driven, type 1 respiratory rate increases, and not decreased respiratory rates indicative of centrally mediated type 2 failure (Turtle 2020; Young et al. 2020). Olfactory abnormalities have been considered a reflection of peripheral nasopharyngeal, and not CNS, dysfunction (Mao et al. 2020). Encephalopathy with the severe respiratory, metabolic, and immunologic derangements of critical illness, and not viral neuroinvasion, may account for non-focal neurologic manifestations (Pleasure et al. 2020). These issues of interpretation make it appropriate to address the following question: are concerns about the potential neurotropism and neurovirulence of SARS-CoV-2 warranted? To answer this question, it would seem helpful to examine the evidence for nervous system involvement by coronaviruses in general, both in man, and with the supporting evidence of animal models

✉ Susan Morgello
susan.morgello@mssm.edu

¹ Departments of Neurology, Neuroscience, and Pathology, Icahn School of Medicine at Mount Sinai, Box 1137, New York 10029, NY, USA

that are relevant to neuropathogenesis. Accordingly, this review will cover aspects of basic coronavirus biology relevant to nervous system disorders; the types of neurologic syndromes that have been observed in man; the evidence for virally mediated human neuropathogenesis, whether by direct CNS involvement, or indirect immunologic and vascular mechanisms; and when pertinent, how our understanding of coronavirus neuropathogenesis in animals is relevant to human disease.

Basic biology of coronaviruses

Coronaviruses are a large and expanding family of membrane-enveloped, positive sense, single-strand RNA viruses, with genomes ranging in molecular weight from 25 to 32 kb. They are roughly 120 to 140 nm in diameter, inclusive of spike (S) proteins that protrude from their envelopes to a height of approximately 20 nm, producing the corona-like appearance on electron microscopy (EM) that gives the family its name. An excellent review of the viral and cellular biology of coronaviruses can be found in *Fields Virology* (Perlman and Masters, 2020). Within the subfamily Coronavirinae, there are four genera—alpha, beta, gamma, and delta—defined by intra-genus conservation of seven domains in the viral replicase/transcriptase; within each genus, species are defined by a minimum of 90% amino acid sequence homology in these conserved regions (Perlman and Masters 2020).

Currently, with one exception, mammalian coronaviruses are members of the alpha and beta genera (Table 1). The global distribution of coronavirus species is “driven” by bat populations, which constitute the major viral reservoir. In regions of the world where bats are highly diverse, such as portions of Asia and Africa, host switching is the dominant mechanism of viral evolution (Anthony et al. 2017). Thus, zoonotic transmission to man has higher likelihood in these geographic areas, as host switching is its predicate. There are currently seven known human coronaviruses (Table 1); almost all have zoonotic origins, or are known to circulate in animals (Anthony et al. 2017; Andersen et al. 2020). Animal surveillance has been suggested as a useful technique in combatting epidemic viruses: for example, both SARS-CoV and SARS-CoV-2 can infect and replicate in domestic cats, with transmission from infected to uninfected cats occurring through respiratory droplets (Martina et al. 2003; Shi et al. 2020). As these common pets may be in community as well as in close contact with their owners at home, they may conceivably provide an adjunctive mechanism for virus tracking.

Canonical features of coronaviruses include a large RNA molecule with 5' capping and polyadenylated tail and an invariant order of major genes encoding (from 5' to 3'): the replicase/transcriptase complex–spike (S) protein–envelope (E) protein–membrane (M) protein–nucleocapsid (N) protein.

The S, E, and M proteins are embedded in the viral envelope, with M being most abundant, whereas N is the sole protein of the helical viral nucleocapsid (Fig. 1). As the genome is capped and polyadenylated, it is ready for translation once introduced into cell cytoplasm. Dependent upon viral species, a variety of smaller open reading frames (ORFs) for accessory genes are found within intergenic regions of the structural proteins. In a subset of betacoronaviruses (murine hepatitis virus (MHV), bovine CoV, and human viruses HCoV-OC43 and HCoV-HKU1), a fifth major protein, hemagglutinin-esterase (HE), may be encoded. The HE protein, expressed on the viral membrane envelope, is capable of binding sialic acid residues on cell surface glycoproteins and glycolipids and has acylesterase activity; it is a close relative of the influenza C virus HE and is thought to reflect a shared common ancestor (Perlman and Masters 2020). In mice inoculated with some strains of MHV, an important animal model of neuropathogenesis, HE mediates enhanced neurovirulence, and higher HE expression is associated with neuronal infection and more severe pathology (Lai and Stohlman 1992). Importantly, through adaptation to human infection, the HEs found in HCoVs OC43 and HKU1 are thought to have lost their receptor/lectin binding functions (Bakkers et al. 2017). The HE protein is not found in SARS viruses.

Cell tropism is an essential aspect of establishing CNS disease and, for coronaviruses, the S protein dominates this characteristic (albeit not exclusively, as demonstrated by the HE protein). It is the major cell surface binding molecule, responsible for membrane fusion and viral genome entry into the cell. The S protein is a homotrimer, with each of its polypeptides containing a large, bipartite ectodomain: S1, which is highly variable and mediates receptor binding, and S2, which is more conserved and functions in membrane fusion between virus and host cell (Perlman and Masters 2020). Virus entry into the cell occurs either in an “early” pathway of direct fusion between viral envelope and the cell membrane or a “late” pathway in which receptor binding leads to endocytosis in clathrin-coated pits, which then transition to acidified endosomes (Fig. 2). Proteolytic priming of the S protein is an essential step in the viral life cycle, both at cell entry and upon maturation and egress; large conformational changes on cell entry are needed to expose the S2 fusion peptide. This occurs through two cleavages, at the boundary of S1/S2 and at a second S2' site. Thus, cell entry requires not only S protein binding to its cognate receptor but also exposure to a cellular protease for priming, either in the context of the cell membrane or the endosome. While cathepsins provide this proteolytic processing in the endosome, a variety of proteases may be active at the cell surface. The cell surface serine protease TMPRSS2 can provide priming function for all human coronaviruses, and there is evidence to suggest that wild type viruses prefer the TMPRSS2-mediated cell surface pathway to cathepsin-mediated endosomal pathways of cell entry (Shirato

Table 1 Representative mammalian coronaviruses and their dominant cell receptors or attachment factors

Virus	Abbreviation	Cell receptor or attachment factor
Genus: Alphacoronaviruses		
Human coronavirus 229E	HCoV-229E	APN (CD13)
Human coronavirus NL63	HCoV-NL63	ACE2
Alphacoronavirus 1 species:		
Transmissible gastroenteritis virus	TGEV	APN (CD13)
Feline coronavirus type 1	FCoV-1	
Feline infectious peritonitis virus	FIPV	APN (CD13)
Canine coronavirus	CCoV	APN (CD13)
Porcine epidemic diarrhea virus	PEDV	APN (CD13)
Diverse bat coronaviruses		
Genus: Betacoronaviruses		
Human coronavirus HKU1	HCoV-HKU1	<i>N</i> -Acetyl-9- <i>O</i> -acetylneuraminic acid (9- <i>O</i> -acetylsialic acid)
Betacoronavirus 1 species:		
Human coronavirus OC43	HCoV-OC43	<i>N</i> -Acetyl-9- <i>O</i> -acetylneuraminic acid (9- <i>O</i> -acetylsialic acid)
Bovine coronavirus	BCoV	<i>N</i> -Acetyl-9- <i>O</i> -acetylneuraminic acid (9- <i>O</i> -acetylsialic acid)
Equine coronavirus	EqCoV	9- <i>O</i> -Acetylsialic acid determinant?
Porcine hemagglutinating encephalomyelitis virus	PHEV	9- <i>O</i> -Acetylsialic acid determinant?
Dromedary camel coronavirus HKU23	DcCoV HKU23	
Severe acute respiratory syndrome-related coronavirus species:		
Human SARS coronavirus	SARS-CoV	ACE2, also L-SIGN (CD209L)
Human SARS coronavirus-2	SAR-CoV-2	ACE2
SARS-related <i>Rhinolophus</i> bat coronavirus Rp3	SARSr-Rh-BatCoV Rp3	
Middle East respiratory syndrome-related coronavirus	MERS-CoV	DPP4 (CD26)
Murine coronavirus species:		
Mouse hepatitis virus	MHV	CEACAM1, also L-SIGN (CD209L), also 4- <i>O</i> - or 9- <i>O</i> -acetylsialic acid
Rat coronavirus	RCoV	
Diverse bat coronaviruses		
Genus: Deltacoronaviruses		
Porcine deltacoronavirus	PDCoV	APN (CD13)

ACE2 angiotensin-converting enzyme 2, APN aminopeptidase N, DPP4 dipeptidyl peptidase 4

et al. 2018; Kleine-Weber et al. 2018; Hoffmann et al. 2020). TMPRSS2 is not expressed in human brain, and it is unclear what impact this absence might have on neurotropism (Jacquinet et al. 2001). Of interest, SARS-CoV-2 has acquired a polybasic site at the S1–S2 junction that allows for effective cleavage by furin, an endoprotease abundantly expressed in CNS, located on cell membranes, in endosomes, and also cleaved and secreted (Andersen et al. 2020; Thomas 2002; Braun and Sauter 2019).

The major cell receptors for epidemic human coronaviruses are for SARS-CoV and SARS-CoV-2, angiotensin-converting enzyme 2 (ACE2) and for MERS, dipeptidyl peptidase 4 (DPP4) (Table 1). For continuously circulating human species, HCoV-NL63 uses the ACE2 receptor, and neutralizing antibodies to HCoV-NL63 have been found in virtually all adults (Hofmann et al. 2005). Furthermore, HCoV-NL63

and SARS-CoV recognize the same motifs in ACE2 with their receptor binding domains (Perlman and Masters 2020). While sharing a common receptor, characteristics of viral–host cell interactions vary between species: SARS-CoV binds and downregulates ACE2 with greater efficiency than HCoV-NL63, and SARS-CoV-2 demonstrates even greater binding efficiency for ACE2 than SARS-CoV (Hofmann et al. 2005; Glowacka et al. 2010; Wang et al. 2020). HCoV-229E uses aminopeptidase N (APN, also known as CD13) as its major receptor, and binding motifs for HCoVs OC43 and HKU1 are *N*-acetyl-9-*O*-acetylneuraminic acids (9-*O*-acetylsialic acids) (Hulswit et al. 2019; Perlman and Masters 2020).

The importance of cell receptor expression to neuropathogenesis is demonstrated by transgenic animal models. Mice can be infected with SARS-CoV and support viral replication, but generally fail to develop the severe

Fig. 1 a Canonical organization of the coronavirus genome. Major genes present in all coronaviruses, from 5' to 3', encode the replicase/transcriptase complex, the spike (S) protein, the envelope (E) protein, the membrane (M) protein, and the nucleocapsid protein (N). In some variants, a fifth major protein, the hemagglutinin-esterase (HE), is represented proximal to the spike protein. **b** Organization of the coronavirus virion. S, E, and M proteins are embedded in the membrane envelope, whereas the N protein encases the viral genome

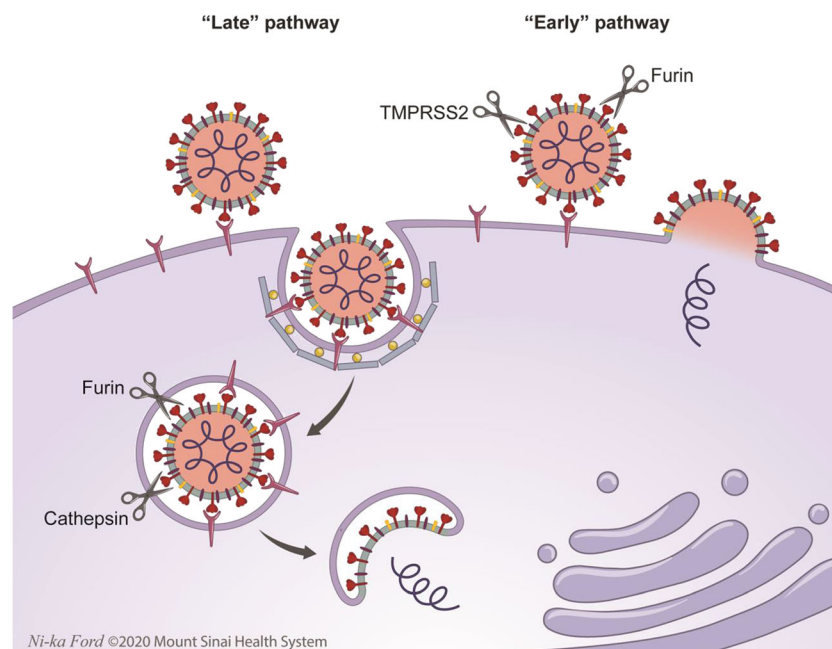
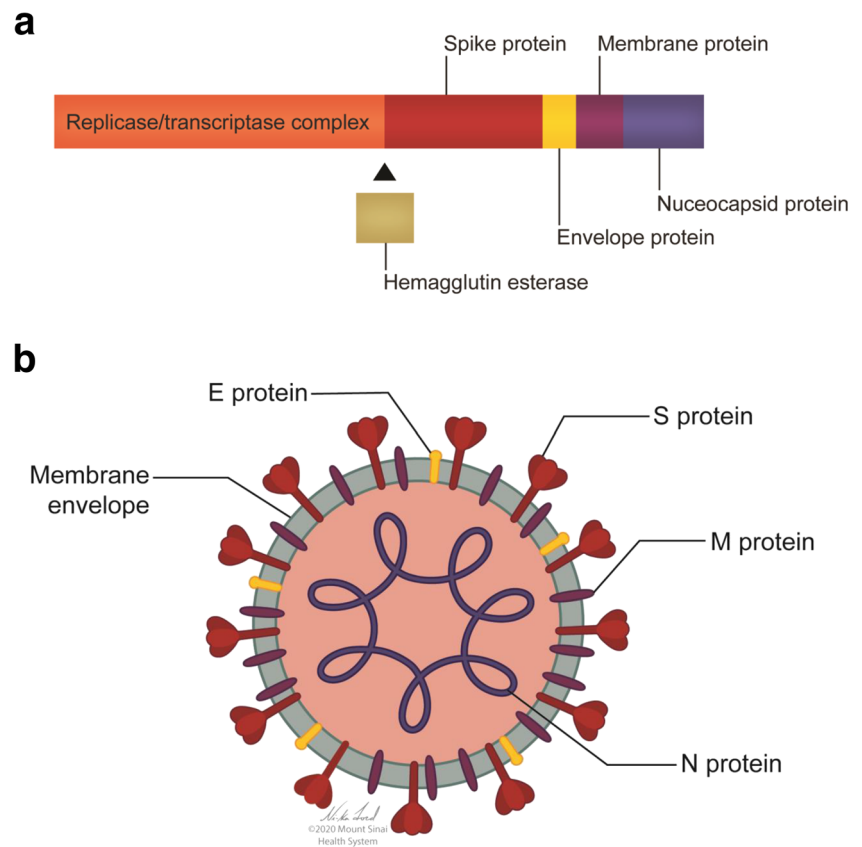


Fig. 2 Cell entry pathways utilized by coronaviruses. Coronaviruses enter cell cytoplasm via two receptor-mediated pathways that require proteolytic processing of the S protein; this priming exposes the S2 domain, which participates in membrane fusion and allows injection of viral genome into the cell. The “early pathway” occurs exclusively at the cell membrane, and the “late pathway” entails viral internalization via clathrin-coated pits that transition to acidified endosomes. In the late pathway, S antigen priming occurs both at the cell membrane (via

proteases such as TMPRSS2 and furin), as well as in the endosome, utilizing endosomal proteases (cathepsins) and potentially furin. Therapies that interfere with acidification of the endosome, such as hydroxychloroquine, interfere with this pathway. In the early pathway, viral binding to the receptor and proteolytic processing of the S protein are accomplished entirely by proteases at the cell surface, which allows direct entry of the viral genome into cytoplasm.

disease seen in humans. When mice are made transgenic for human ACE2 (hACE2), their disease becomes lethal, characterized by severe pulmonary and extra-pulmonary infection, including the brain (McCray et al. 2007). When hACE2 transgenic mice are inoculated intranasally with SARS-CoV, virus spreads through the olfactory bulbs into the brain and then rapidly disseminates via trans-neuronal pathways, with viral protein detected in brain regions with first- and second-order connections to the olfactory system (McCray et al. 2007). Neuronal infection is subsequently followed by neuronal loss (McCray et al. 2007; Netland et al. 2008). This model is remarkable in that expression of the transgene is very low in brain, contrasting with the extensive neuronal infection (McCray et al. 2007). Furthermore, the model does not demonstrate a cellular immune response—that is, inflammatory cell infiltration/meningoencephalitis does not develop (Netland et al. 2008). A similar model featuring brain infection has been created for MERS-CoV, with mice transgenic for human DPP4 (hDPP4) (Li et al. 2016a). In contrast to mouse models of SARS, hDPP4 transgenics have high levels of receptor expression in brain and, when inoculated intranasally with MERS-CoV, show viropathic effects in neurons with most significant early damage in regions unrelated to olfaction; these mice also demonstrate perivascular inflammatory cell infiltrates (Li et al. 2016a). Both SARS-CoV and MERS-CoV transgenic mouse models highlight the importance of receptor expression to neuropathogenesis, raising the important question of whether HCoV receptors are found in human brain.

While present on pulmonary, nasopharyngeal, and gastrointestinal epithelia, the ACE2 protein was not described in human brain parenchyma in the single publication documenting its distribution (Hamming et al. 2004). However, ACE2 was demonstrated in brain vascular (arterial and venous) endothelia and smooth muscle, as well as systemic vasculature (Hamming et al. 2004). In human heart, vascular pericytes demonstrate abundant ACE2 expression (Chen et al. 2020). While reports of brain parenchymal ACE2 are often cited in the literature, none have entailed analysis of human tissue. Neuronal cytoplasmic ACE2 has been described in a rabbit model of heart failure and in a transgenic mouse model of hypertension with human renin and angiotensin transgenes, with no explanation regarding its cytosolic localization (Kar et al. 2010; Doobay et al. 2007). In a study of ontogeny, ACE2 immunoreactivity was detected in mouse ependyma at E18.5, with no mention of neuronal staining (Song et al. 2012). ACE2 activity and mRNA have been detected in mouse and rat brain tissues without cellular localization, and cultured rat astrocytes can express ACE2 mRNA and protein (Sakima et al. 2005; Gallagher et al. 2006; Elased et al. 2008). Thus, it remains an open question whether ACE2 is sufficiently expressed and can act as a SARS receptor in non-vascular human brain parenchyma, both under normal

conditions and in disease states known to regulate ACE2 expression and/or activity, such as diabetes and hypertension (Battle et al. 2010; South et al. 2020).

In contrast, DPP4 (also known as T cell activation antigen CD26) can more confidently be localized to human CNS in an age-dependent manner and is a protein implicated in immunologic signaling, processing/inactivation of neuropeptides, and glucose homeostasis. It is the target for inhibition by gliptin therapies in diabetes, which are also in trial for dementia and stroke (Wicinski et al. 2019). The DPP4 protein has been detected in abundance in human fetal and perinatal brains and in neuroblasts and neurons, capillaries, ependyma, and choroid plexus (Bernstein et al. 1987). With maturation, its expression decreases and, in adult brain, appears largely confined to vascular structures; this is in contrast to a study in normal mice, which detected protein in cortical astrocytes (Bernstein et al. 1987; Mentzel et al. 1996). Only small amounts of DPP4 mRNA are detected in adult human brain relative to other tissues such as the placenta, kidney, lung, and liver (Abbott et al. 1994). Detection in brain parenchyma is also described in human disease: in progressive multiple sclerosis (MS), DPP4 is upregulated in microglia of normal appearing white matter, whereas within MS plaque, expression is in monocytes/macrophages (Elkjaer et al. 2019). One report of increased DPP4 in neurons and plaques of Alzheimer's disease is published, but is restricted to immunohistochemical analysis without other means of confirmation (Bernstein et al. 2018).

Whereas ACE2 and DPP4 are primarily vascular in the healthy adult human brain, strong expression of APN (CD13) is seen both in mature brain parenchyma and vasculature (Larrinaga et al. 2005; Smyth et al. 2018). In cerebral cortex, APN activity can be isolated in diverse subcellular fractions, including nuclei and synaptic membranes; the protein is a component of the system regulating neuropeptide activity (Larrinaga et al. 2005). In brain vasculature, APN is a marker of pericytes and smooth muscle cells (Smyth et al. 2018). APN has also been identified in primary cultures of human olfactory neuroepithelia, which by virtue of their location offer a potential CNS portal for respiratory viruses (Vawter et al. 1996). It is currently hypothesized, but not proven, that transaxonal spread from infected olfactory neuroepithelium is a CNS portal for HCoVs, as has been described in animal models of diverse viral pathogens and in SARS-HCoV-infected hACE2 transgenic mice (Van Riel et al. 2015; McCray et al. 2007). Finally, the human brain contains the highest concentration of sialic acids of any organ, found predominantly as sialoglycolipids (Wang and Brand-Miller 2003; Schnaar et al. 2014). *O*-Acetylated forms constitute several percent of total brain gangliosides, although 9-*O* forms may be specific for neurogenesis and migrating neuroblasts and, thus, not generally available for binding in adults (Schnaar et al. 2014).

While expression of most major coronavirus receptors may not be significant in adult human brain parenchyma, another consideration for viral neurotropism is the fact that viruses commonly exploit alternate receptors to gain cell access, albeit with lesser efficiency. For example, human CD209L (L-SIGN), expressed on endothelial cells of liver and lymph node and also on primary isolated human brain microvascular endothelia, can act as a receptor for SARS-CoV (Jeffers et al. 2004; Mukhtar et al. 2002). It is currently unclear if SARS-CoV-2 is capable of exploiting L-SIGN, and alternate receptor mechanisms are not thoroughly investigated for HCoV; only receptor motifs are available for two human species (OC43 and HKU1) (Table 1). A clinical isolate of one of those species, HCoV-OC43-Paris, can infect murine olfactory bulbs with dissemination throughout brain; the cell receptor mediating this neurovirulence is unknown (St-Jean et al. 2004).

It is also important to recognize that direct infection of neurons, glia, and/or olfactory neuroepithelia is not a necessary predicate for neuropathogenesis (Table 2). In addition to direct parenchymal infection, mechanisms that can contribute to CNS damage are direct infection of endothelial cells; increased thrombophilia with vascular occlusion in the absence of direct infection; para-infectious immune-mediated damage as in acute disseminated necrotizing or demyelinating encephalopathy; and in the course of inflammatory cell migration across the blood–brain and blood–CSF barriers, meningoencephalitis. Many viruses gain access to the CNS via immune cell trafficking across the blood–brain and blood–CSF barriers.

SARS and MERS coronaviruses are both capable of infecting human monocyte-derived macrophages and dendritic cells; however, with SARS, *in vitro* infections are abortive and do not support production of virions, whereas with MERS, productive infections and rising viral titers are seen (Zhou et al. 2015; Cheung et al. 2005; Tseng et al. 2005). *In vitro*, different characteristics of monocyte-derived cell infection are associated with differences in the pattern of immune response and cytokine elaboration (Zhou et al. 2015; Perlman and Dandekar 2005; Law et al. 2005). Whether these differences have nervous system relevance is unclear (Zhou et al. 2015; Cameron et al. 2008). SARS and MERS also directly infect T lymphocytes (Perlman and Dandekar 2005; Zhou et al. 2015). In tissue samples of individuals with SARS-CoV, virions, viral proteins, and nucleic acids have been identified in macrophages, T lymphocytes, granulocytes, and, to lesser degrees, B lymphocytes and NK cells (Gu et al. 2005; Shi et al. 2005; Nicholls et al. 2006). In contrast, a single autopsy report of an individual dying with MERS-CoV failed to demonstrate viral antigen in pulmonary macrophages despite detection in pneumocytes (Ng et al. 2016). Finally, non-epidemic HCoVs are also capable of infecting human monocyte/macrophages *in vitro*, with variable abilities to replicate (Desforges et al. 2007; Cheung et al. 2005). Thus,

regardless of systemic pathogenicity, for human coronaviruses, immune cell trafficking is a potential mechanism for establishing CNS disease.

Neurologic syndromes in man

Neurologic manifestations have been recorded for all currently recognized HCoVs, impacting a wide age range; not surprisingly, the spectrum of disease in infants and children differs from that in adults (Table 3). In interpreting the literature, it is essential to distinguish encephalopathy in the setting of systemic infection from infectious encephalitis, as per the International Encephalitis Consortium guidelines (see Table 4) (Venkatesan et al. 2013). Coronavirus encephalitis is so infrequent in infants, children, and adults, that it is not mentioned as a differential diagnosis in any consensus diagnostic algorithm or treatment protocol for, or in any large-scale survey of, viral encephalitis (Venkatesan et al. 2013; Sharma et al. 2012; Kneen et al. 2012; Granerod et al. 2010; Tunkel et al. 2008). It is unclear why encephalitis is so infrequent in man, when other naturally occurring coronaviruses in animals may frequently display inflammatory CNS pathology; for example, encephalitis is commonly seen with feline infectious peritonitis virus (FIPV), one of the most prevalent and fatal pathogens of cats (Rissi 2018).

In infants and children worldwide, respiratory viruses are the most common infectious pathogens, and lower respiratory tract infections are the leading cause of death (Dominguez et al. 2009; Carman et al. 2019). The contribution of coronaviruses to respiratory infections is inconstant, as the seroepidemiology for HCoVs NL63, HKU1, 229E, and OC43 varies widely, ranging from 1 to 75%, dependent on viral species, patient age, geographic location, care venue, and time of year (Principi et al. 2010). Coronaviruses can be seri-

Table 2 Potential mechanisms of coronavirus neuropathogenesis

Infection of olfactory neuroepithelium with transaxonal spread into deeper brain regions
Infection of brain vasculature: <ul style="list-style-type: none"> Direct spread from endothelia/vascular structures into neurons and glia Vascular occlusion or inflammation/vasculitis with ischemia/hemorrhage
Infection of lymphocytes and monocytes/macrophages: <ul style="list-style-type: none"> Migration across blood–brain and blood–CSF barrier with immune-mediated damage Migration across blood–brain and blood–CSF barrier with spreading viral infection
Para-infectious sequelae: <ul style="list-style-type: none"> Increased thrombophilia with cerebral infarction Dysregulated immunity with cerebral demyelination or necrosis
Febrile seizures

Table 3 Neurologic manifestations of the human coronaviruses, and their potential etiologies

CNS manifestation	Potential pathogenesis
Febrile seizures in children	Fever as trigger, possible cytokine response to infection; no evidence of direct CNS viral effect
General seizures in adults and children	Uncertain trigger, may be generalized CNS response to systemic illness, inclusive of hypoxia, cytokine storm, and microvascular abnormalities; CNS virus (patients with CSF detection are documented) with possible neuronal infection (unproven); CNS inflammation (patients with CSF pleocytosis have been documented)
Meningitis and meningoencephalitis	Inflammatory cell invasion of CNS (documented through CSF analysis and rare post mortem cases), possible mononuclear cell trafficking with or without viral infection of monocytes; or immune response to primary brain infection of uncertain cell type (infection not well documented for many species)
Stroke (both large vessel ischemic infarction and intracranial hemorrhage)	Coronavirus-associated coagulopathy; antiphospholipid antibodies; direct endothelial infection
Anosmia and hypogeusia	Infection of nasopharyngeal mucosa (well documented); possible infection of neuroepithelium (not established); concern for olfactory bulb, tract, and primary cortical infection (not documented in humans)
Non-focal phenomena: changes in sensorium including lethargy and confusion; agitation; dizziness; headache	Possibly a generalized CNS response to hypoxemia, cytokine storms, and microangiopathy of critical disease; or undisclosed inflammatory/infectious pathology in the absence of a diagnostic neurologic workup
Acute disseminated encephalomyelitis and hemorrhagic necrotizing encephalopathy	Para-infectious immune response

ous pathogens when encountered in infancy and childhood; in a series of children under the age of 16 hospitalized in Hunan Province, coronaviruses accounted for 11% of respiratory infections (Li et al. 2016b). A study from the Children’s

Hospital in Colorado estimated 40% of tests for prevalent respiratory pathogens were non-diagnostic (for respiratory syncytial virus, influenza A and B, parainfluenza, and adenovirus), when re-tested, 5% yielded coronaviruses (44% NL63, 40% OC43, 13% 229E, 2% HKU1) (Dominguez et al. 2009).

Table 4 International Encephalitis Consortium criteria for diagnosis of encephalitis (Venkatesan et al. 2013)

Major criterion (must be present):
Altered mental status lasting over 24 h with no other causes identified (decreased level of consciousness, lethargy, or personality disorder)
Minor criteria (2 for possible encephalitis, 3 for probable encephalitis):
Documented fever ≥ 100.4 °F within the 72 h before presentation
Generalized or partial seizures not attributable to a pre-extant seizure disorder
New onset focal neurological findings
CSF WBC count ≥ 5 cells/mm ³
Abnormality of brain parenchyma on neuroimaging suggestive of encephalitis that is new from prior studies or acute in onset
Abnormality on electroencephalography that is consistent with encephalitis and not attributable to another cause

There are two major neurologic complications seen with coronaviruses in infants and children: febrile seizures and acute meningoencephalitis. Febrile seizures are events in association with fever, occurring in the absence of prior seizures, evidence of CNS infection, or systemic metabolic derangements (Carman et al. 2019). In a recent multicenter study of 192 children with febrile seizures, HCoV OC43 and 229E were identified in 6.9% and 3.4% of nasopharyngeal samples, most often in combination with other respiratory viruses (Carman et al. 2019). While infrequent overall, HCoV-OC43 was the most common viral pathogen in infants under the age of 12 months. In children under the age of 6 with febrile seizures in Slovenia, 10% were associated with HCoVs (Pokorn et al. 2017). Of 26 children hospitalized for coronavirus respiratory illness in Hong Kong, of 6 (23%) had febrile seizures, 4 with HCoV-NL63, and 2 with HCoV-OC43 (Chiu et al. 2005). Another study from Hong Kong described febrile seizures in 5 of 10

(50%) hospitalized children with HCoV-HKU1, raising the possibility that this species may have greater than usual impact on the CNS (Principi et al. 2010; Lau et al. 2006). Febrile seizures are uncommon with SARS-CoV; while not mentioned in some reports, a single infant with febrile convulsions is described in a series from Hong Kong (Hon et al. 2003; Bitnun et al. 2003; Chiu et al. 2003). In series of infants and children with SARS-CoV-2 currently available from China and Spain, there is no mention of febrile seizures, nor are any neurologic disorders described (Tagarro et al. 2020; Wei et al. 2020; Lu et al. 2020). Thus, HCoVs appear to contribute in minor part to febrile seizures in infants and children; when identified, they are usually continuously circulating and not epidemic species and are present both in isolation as well as accompanied by other, more common respiratory viruses.

Acute meningoencephalitis or meningitis is another complication of coronaviruses in infants and children, albeit rare. A 3-year-old with meningitis in the setting of HCoV-OC43 serology may be the first case described in the literature; another case report of HCoV-OC43 encephalitis in an 11-month-old boy with immunodeficiency was published 36 years later (Riski and Hovi 1980; Morfopoulou et al. 2016). The only series to date describing features of coronavirus-associated encephalitis is from the Children's Hospital of Chenzhou in Hunan Province (Li et al. 2016b). Of 183 children under the age of 16 years admitted for acute encephalitis, 22 (12%) had coronavirus infection detected by IgM serology (Li et al. 2016b). Eighty-two percent of these children were male, and the mean age was 3 years. The course of disease averaged 14.5 days, and all had a full recovery with no neurological sequelae. Fever was present in 82%, headache in 46%, vomiting in 36%, and seizure in 23%. Cerebrospinal fluid pleocytosis was seen in 46%, normal CSF glucose in 82%, and elevated protein in 36%. When compared to children hospitalized with pulmonary coronavirus, children with encephalitis had lower peripheral blood lymphocyte and eosinophil counts, higher neutrophil counts, and higher serum levels of granulocyte macrophage colony-stimulating factor (GM-CSF). Children with encephalitis also had higher peripheral blood monocyte counts than healthy controls. When paired biospecimens were analyzed, levels of GM-CSF, IL-6, IL-8, and MCP-1 were higher in the CSF than in the serum of the encephalitic children (Li et al. 2016b).

Non-specific neurologic manifestations such as lethargy, dizziness, and headache are also described in children with SARS-related respiratory illness, but there is insufficient evidence to ascribe signs and symptoms to a viral CNS effect, as opposed to constitutional symptoms of severe respiratory compromise (Hon et al. 2003; Bitnun et al. 2003; Chiu et al. 2003). Recently, infants under the age of 3 months with COVID-19, presenting with non-focal neurologic phenomena (axial hypotonia, drowsiness) with isolated fever and without respiratory illness, have been described (Nathan et al. 2020).

Cerebrospinal fluid in all was normal and negative for SARS-CoV-2; all recovered with only acetaminophen therapy. It has been noted that constitutional symptoms with SARS are more frequent in teenagers than in children under 12 and resemble the symptoms seen in adults (Ng et al. 2004).

Non-specific neurologic manifestations have also been reported in the more severe COVID-19-associated pediatric multisystem inflammatory syndrome (Riphagen et al. 2020; Chiotos et al. 2020). This emerging syndrome resembles Kawasaki disease, with persistent fevers, rash, conjunctivitis, peripheral edema, gastrointestinal symptoms, and cardiac and coronary abnormalities. In one report, symptoms and signs seen in 4 of 6 children with this severe illness included headache, altered mental status, irritability, and nuchal rigidity (Chiotos et al. 2020). One child displayed cerebral edema on head CT, and lumbar puncture revealed a pleocytosis consistent with aseptic leptomeningitis. While viral testing of CSF for SARS-CoV-2 was not described, this may represent the first case of meningoencephalitis in a child with COVID-19 disease.

While continuously circulating coronaviruses account for most CNS manifestations in infants and children, the majority of brain abnormalities in adults have been described with the epidemic coronaviruses. In adults, neurologic manifestations most frequently described are non-focal, non-specific, and unaccompanied by direct evidence of CNS viral invasion and hence the debate as to whether they are intrinsically neurologic or constitutional. Furthermore, even when neurologic signs confirm diffuse intracerebral pathology, it is unclear whether this reflects damage mediated by virus, or by the severe hypoxia and cytokine storms encountered in COVID-19, SARS, and MERS disease. Finally, peripheral nervous system (PNS) and musculoskeletal abnormalities are described in adults with SARS-CoV-2, SARS-CoV, and MERS-CoV infections; while not the focus of this review, these include Guillain-Barré syndrome (GBS), critical illness polyneuropathy, critical illness myopathy, isolated multiple cranial neuropathy, and Miller Fisher syndrome (Gutierrez-Ortiz et al. 2020; Zhao et al. 2020; Toscano et al. 2020; Kim et al. 2017; Tsai et al. 2004). Both demyelinating and axonal forms of GBS have been described with COVID-19 and can in part be distinguished from critical illness neuropathy and myopathy by earlier onset in the course of general disease (Toscano et al. 2020).

High rates of neurologic phenomena have been reported in adults hospitalized with SARS-CoV-2 (Mao et al. 2020; Helms et al. 2020). In 214 COVID-19-related hospitalizations from Wuhan, manifestations were categorized as central, peripheral (included in this category were impairments in taste, smell, and vision), or musculoskeletal (Mao et al. 2020). Central nervous system abnormalities were present in 25%, PNS in 9%, and musculoskeletal in 11%. The most common CNS manifestations were dizziness (17%), headache (13%),

and impaired consciousness (7.5%). Of 58 hospitalized patients reported from France, 84% had neurologic manifestations; common abnormalities were also non-focal and included agitation (69%), confusion (65% of a subset of 40), and, on examination, diffuse corticospinal tract signs (enhanced deep tendon reflexes, ankle clonus, bilateral extensor plantar reflexes) in 67%. A small subset of French patients underwent brain MRI and CSF analysis; all 7 CSF studies returned negative reverse transcriptase-polymerase chain reaction (RT-PCR) for SARS-CoV-2, despite leptomeningeal enhancement in 8 of 13 neuroimaging studies (Helms et al. 2020). Series of patients with SARS and MERS are similar with regard to commoner phenomena being potentially constitutional. Of 138 patients with SARS reported from Hong Kong, headache and dizziness were seen in 56% and 43% respectively; of 144 patients in Toronto, 35% reported headache and 4% dizziness (Lee et al. 2003; Booth et al. 2003). In 70 patients hospitalized with MERS in Saudi Arabia, headache (13%), confusion (26%), and seizures (9%) were reported; in 23 MERS patients from Korea, 9% had headache and 22% confusion (Saad et al. 2014; Kim et al. 2017).

A less common, but well-documented complication of all the epidemic coronaviruses is stroke, either in the form of large artery cerebral infarction or intracranial hemorrhage (Umapathi et al. 2004; Arabi et al. 2015; Algahtani et al. 2016; Mao et al. 2020; Oxley et al. 2020). In larger series, the overall prevalence of stroke is 5% or less; 2.4% in SARS patients from Singapore, 5.2% in COVID-19 patients from France, and 2.8% in COVID-19 patients from Wuhan (Mao et al. 2020; Helms et al. 2020; Umapathi et al. 2004). Reported patients range in age from 33 to 70, and many lack other risk factors for stroke. Recently, cerebral infarction was described in a 14-year-old boy with COVID-19-associated multisystem inflammatory syndrome (Riphagen et al. 2020). Patients with SARS-CoV-2-related strokes can present at any stage of viral infection, from otherwise asymptomatic to critical pulmonary disease. In China, it was observed that acute stroke is more common with severe illness, seen in 5.7% of those with critical illness and only 0.8% of those with less advanced disease (Mao et al. 2020). However, in New York City, where European SARS-CoV-2 strains predominate, cerebral infarction was documented in young individuals with mild COVID symptomatology (Oxley et al. 2020). Stroke may be related to coronavirus-associated coagulopathies. Elevated D-dimers, fibrin degradation products and thrombocytopenia are present in over 50% of those with severe COVID-19 and SARS disease, and in similarly high percentages of those with MERS; venous thrombosis and thromboembolism have also been described (Giannis et al. 2020). However, not critically evaluated is how disseminated intravascular coagulopathy (DIC), or a microangiopathic coagulopathy closely resembling DIC, contributes to ischemic stroke in the absence of hemorrhage or underlying arterial lesions, as the strokes described are large

vessel, high flow, arterial phenomena. Recently, antiphospholipid antibodies were detected in three patients with severe COVID-19 and stroke, raising the possibility that cerebral ischemia arises with vascular immunopathologies other than DIC and microangiopathy (Zhang et al. 2020). Alternatively, there may be a direct role for viral infection of endothelia, as recent autopsy reports demonstrate viral particles in systemic and brain endothelium, with apoptosis and focal endotheliitis (Varga et al. 2020; Mondolfi et al. 2020).

An altered sense of smell or taste has been reported in up to 87% of adults testing positive for SARS-CoV-2; the prevalence may be higher in European studies than in those from Asia (Spinato et al. 2020; Eliezer et al. 2020; Lechien et al. 2020; Mao et al. 2020). In Europe, olfactory and gustatory dysfunction is the presenting symptom in approximately 12% of patients with mild to moderate COVID-19 and has been suggested as a useful screening tool for SARS-CoV-2 (Spinato et al. 2020; Lechien et al. 2020; Wee et al. 2020). However, olfactory dysfunction is not unique to epidemic coronaviruses; this is a well-known post-viral phenomenon for other respiratory viruses, and in one study, HCoV-229E was identified as an underlying pathogen (Suzuki et al. 2007). When contrasted with historical influenza patients, one study found a greater frequency of smell and taste disorders with COVID-19 (Beltran-Corbellini et al. 2020). The pathogenesis of this phenomenon for any respiratory virus is unclear, but it is of interest that nasal epithelial cells have robust expression of ACE2. Similarly, the CNS relevance of this phenomenon is unresolved. Neuroimaging of patients with post-viral olfactory loss has demonstrated decreased olfactory cortex and olfactory bulb volumes, implicating CNS damage; it is unclear whether similar phenomena will be observed with the epidemic coronaviruses (Yao et al. 2018).

Other coronavirus-associated neurologic phenomena in adults, reported infrequently, are seizures and meningoencephalitis with SARS-CoV and CoV-2 (Hung et al. 2003; Lau et al. 2004; Moriguchi et al. 2020). Recently, an adult patient with SARS-CoV-2 and acute hemorrhagic necrotizing encephalopathy was described (Poyiadji et al. 2020). Finally, for both children and adults, there are reports of demyelinating phenomena. Acute disseminated encephalomyelitis (ADEM) in a previously healthy 15-year-old boy with HCoV-OC43 detected in CSF and nasopharyngeal secretions has been published (Yeh et al. 2004). While multiple T2-hyperintense, occasionally enhancing lesions were seen on magnetic resonance imaging (MRI) of the brain and spinal cord, the child's neurologic symptoms resolved without any therapeutic interventions over the course of several weeks (Yeh et al. 2004). Acute flaccid paralysis in a 3-year-old dually infected with HCoVs OC43 and 229E has been reported; it resolved after several weeks, but a definitive CNS or PNS origin could not be ascertained (Turgay et al. 2015). In adults, HCoVs 229E and OC43 have been associated with multiple sclerosis (MS),

but these observations are not uniform across all studies (Burks et al. 1980; Stewart et al. 1992; Arbour et al. 2000). A reliable model of coronavirus-induced demyelination is seen with MHV (Bergmann et al. 2006; Perlman and Wheeler 2016). When inoculated with attenuated strains of John Howard Mueller virus (JHMV), mice initially develop a productive and transient encephalitis; as the immune response decreases viral titers, demyelinating lesions arise, and mice have increasing clinical symptomatology. Mice remain persistently infected with ongoing chronic demyelination, thus providing a model of human MS. When primates are inoculated with JHMV, both encephalomyelitis and demyelination are observed (Murray et al. 1992a).

Human neuropathogenesis: coronavirus localization in the CNS

Perhaps due to persuasive findings in MHV models of demyelination, there have been more studies of coronavirus in the brains of patients with MS than for any other HCoV-associated neurologic syndrome (Burks et al. 1980; Stewart et al. 1992; Murray et al. 1992b; Cristallo et al. 1997; Arbour et al. 2000; Dessau et al. 2001). The first isolation of coronavirus from MS was reported in 1980, when 2 of 13 human brain homogenates inoculated into weanling mice produced either CNS disease (isolate SD) or cytopathic effects in cell culture (isolate SK) (Burks et al. 1980). Neutralizing antibodies to isolate SK were detected in CSF and sera of both patients, however, neutralizing antibodies were also detected in 85% of normal controls, albeit in lower titer than in individuals with MS (Burks et al. 1980). Isolate SD produced demyelination with intracerebral inoculation into primates, with detection of virus in the white matter, meninges, and choroid plexus, although the monkeys remained clinically asymptomatic (Murray et al. 1992a). In 1992, coronavirus was identified in plaque and non-plaque regions of 12 of 22 brains with MS; 5 brains were reactive for HCoV-OC43 and none for HCoV-229E (Murray et al. 1992b). In another study, HCoV-229E but not HCoV-OC43 was detected in MS brain tissues (Stewart et al. 1992). Neither study detected coronavirus in normal control brains. In the largest series, encompassing 39 brains with MS, 26 with other neurological diseases, and 25 controls, both species were detected with an overall prevalence of 44% for HCoV-229E and 23% for HCoV-OC43; however, viruses were identified in all patient groups, albeit with greater frequency in MS (Arbour et al. 2000). Both viruses have also been detected in CSF samples in patients with MS and other CNS disorders (Cristallo et al. 1997). In contrast to these studies, HCoVs 229E and OC43 could not be reliably detected in a single study of 25 MS and 36 control human brains, using nested RT-PCR (Dessau et al. 2001). Thus, while variably present in the human CNS, HCoVs OC43 and 229E cannot

be considered specific to demyelinating pathology, raising questions about what aspects of infection might be relevant to human neuropathogenesis.

Direct evidence of HCoV-OC43 neurovirulence was found in the brain biopsy of an infant with severe combined immunodeficiency who developed fatal encephalitis (Morfopoulou et al. 2016). HCoV-OC43 was detected by RNA sequencing and real-time RT-PCR, and immunohistochemistry for the viral N protein showed dark staining of neuronal perikarya and lighter staining of surrounding neuropil, with frequent neuronal karyorrhexis, while microglial proliferation and infiltrating T cells were seen in the biopsy, depicted regions with viral antigen staining appeared devoid of lymphoid inflammation or neuronophagia. Productive neuronal infection with apoptosis and persistent neurologic deficit has been described with HCoV-OC43 infection of mice, and axonal transport with neuron-to-neuron propagation has been identified as a mode of virus spreading in cell culture (Jacomy et al. 2006; Dube et al. 2018). Thus, while coronavirus encephalitis may be rare, it is possible that a cellular inflammatory response is not prominent with neuronal necrosis, hampering clinical recognition; murine models highlight the role of selective neuronal damage in neurovirulence.

Limited studies of the CSF and brain have also been performed for the epidemic coronaviruses. SARS-CoV has been detected in the CSF of patients who develop seizures in the context of pulmonary disease; in both cases reported, there was a normal CSF protein and no CSF pleocytosis (Lau et al. 2004; Hung et al. 2003). Viral loads were quantified in one patient, with the CSF yielding 6884 copies/ml and the

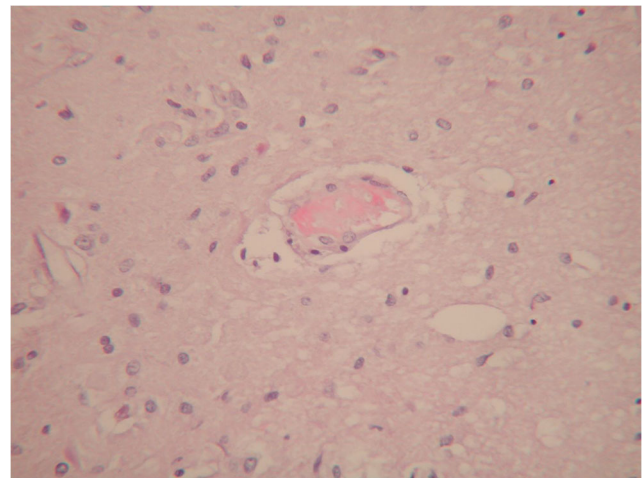


Fig. 3 COVID-19-associated microangiopathy in the brain. This high-power photomicrograph displays a small blood vessel in cerebral white matter of a patient dying with COVID-19 disease. A small fibrin thrombus is seen, and monocyte margination consistent with “endotheliitis” as has been described in systemic vasculature. This patient had infarcts and hemorrhages; these findings were the most common abnormalities in the largest neuropathology series described to date (Bryce et al. 2020). (Hematoxylin and eosin stain, original magnification 200×)

serum 6750 copies/ml, strongly supportive of CNS infection (Hung et al. 2003). In contrast, mononuclear pleocytosis was present in a patient with altered sensorium and seizures with SARS-CoV-2 detected in CSF; in this patient, virus was not detected in a nasopharyngeal swab, and post-seizure neuroimaging demonstrated hyperintensities in the medial temporal lobe, hippocampus, and lateral ventricle (Moriguchi et al. 2020). While MERS patients with seizures have been described, CSF studies are not available (Saad et al. 2014). In MERS and COVID-19 patients who are without seizures, the few reported CSF studies have been negative, raising the possibility that seizure activity might be an indicator of CNS viral penetration and neuronal damage (Kim et al. 2017; Helms et al. 2020). However, data from CSF studies is too limited to draw conclusions.

There is also limited data on the neuropathology of the epidemic viruses (Gu and Korteweg 2007). In 4 patients, SARS-CoV protein and nucleic acids were detected in neurons of an unspecified region of the cerebral cortex but not in the cerebellum; the authors estimated that fewer than 24% of cells demonstrated evidence of infection and did not further characterize brain histopathology (Ding et al. 2004). In a series of 8 brains, all demonstrated viral nucleic acid in numerous neurons of an again unspecified region of cerebral cortex, as well as in hypothalamus (Gu et al. 2005). In this series, edema and selective neuronal necrosis were described in 6 of the 8 patients, and there was no mention of inflammatory infiltration. A 13th autopsied individual with SARS demonstrated edema and selective neuronal necrosis; staining for N protein in neurons as well as unspecified “glia” was reported, again in the absence of mononuclear or lymphoid inflammation (Xu et al. 2005). Finally, an electron microscopic study of the brain of a single patient dying with COVID-19 has been published, demonstrating viral-like particles in endothelial vesicles and perivascular cell processes (Mondolfi et al. 2020). While vascular localization of SARS-CoV-2 is consistent with the brain distribution of ACE2, it is hard to draw conclusions from a single case report. With regard to SARS-CoV, autopsy localization of virus in neuronal cytoplasm coupled with viral detection in the CSF from patients with seizures may suggest that in a subset of individuals, neuronal infection is a significant pathology—as it is in animal models. Recently, a manuscript has been deposited in medRxiv describing the microscopic findings in 20 brains from patients dying with COVID-19 disease (Bryce et al. 2020). Widespread thrombi in microvessels with acute infarction was the most prominent finding, present in 30%; it is unclear if this pathology reflects the DIC-like syndrome often seen in terminal COVID-19 disease, or selective viral targeting of brain microvasculature (Fig. 3). Other findings included large parenchymal infarcts, hemorrhages, global anoxia, and, in general, sparse inflammation. Two brains with single foci of T cell infiltration were also described, but the significance of

this was unclear, and the authors stressed the lack of evidence for meningoencephalitis. In contrast, a single case report describing infarcts, acute hemorrhages with axonal disruption, macrophage infiltrates, and ADEM, with regions of perivascular myelin loss accompanied by macrophages, has also been published in a patient dying with COVID-19 (Reichard et al. 2020). Neither of these reports of COVID-19 neuropathology entailed assays for CNS virus. Thus, as these viruses continue to evolve and emerge, their potential neurovirulence needs greater investigation, both in animal models and in their human hosts.

Funding information The author is supported in part by the National Institutes of Health (grants U24MH100931, RO1MH112391, RO1NS108801, RF1AG060961, R61DA048207). She has no other funding sources to disclose.

References

- Abbott CA, Baker E, Sutherland GR, McCaughan GW (1994) Genomic organization, exact localization, and tissue expression of the human CD26 (dipeptidyl peptidase IV) gene. *Immunogenetics* 40:331–338
- Algahtani H, Subahi A, Shirah B (2016) Neurological complications of Middle East respiratory syndrome coronavirus: a report of two cases and review of the literature. *Case Rep Neurol Med* 2016:3502683–3502686. <https://doi.org/10.1155/2016/3502683>
- Andersen KG, Rambaut A, Lipkin WI, Holmes EC, Garry RF (2020) The proximal origin of SARS-CoV-2. *Nature Med* 26:450–452. <https://doi.org/10.1038/s41591-020-0820-9>
- Anthony SJ, Johnson CK, Greig DJ, Kramer S, Che X, Wells H et al (2017) Global patterns in coronavirus diversity. *Viral Evolution* 3(1):vex012. <https://doi.org/10.1093/ve/vex012>
- Arabi YM, Harthi A, Hussein J, Bouchama A, Johani S, Hajeer AH, Saeed BT, Wahbi A, Saedy A, AlDabbagh T, Okaili R, Sadat M, Balkhy H (2015) Severe neurologic syndrome associated with Middle East respiratory syndrome corona virus (MERS-CoV). *Infection* 43:495–501
- Arbour N, Day R, Newcombe J, Talbot PJ (2000) Neuroinvasion by human respiratory coronaviruses. *J Virol* 74(19):8913–8921
- Baig AM, Khaleeq A, Ali U, Syeda H (2020) Evidence of the COVID-19 virus targeting the CNS: tissue distribution, host-virus interaction, and proposed neurotropic mechanisms. *ACS Chem Neurosci* 11:995–998. <https://doi.org/10.1021/acchemneuro.0c00122>
- Bakkers MJG, Lang Y, Feitsma LJ, Hulswit RJG, de Poot SAH, van Vliet ALW, Margine I, de Groot-Mijnes JDF, van Kuppeveld FJM, Langereis MA, Huizinga EG, de Groot RJ (2017) Betacoronavirus adaptation to humans involved progressive loss of hemagglutinin-esterase lectin activity. *Cell Host and Microbe* 21:356–366
- Battle D, Soler MJ, Ye M (2010) ACE2 and diabetes: ACE of ACEs? *Diabetes* 59:2994–2996
- Beltran-Corbellini A, Natera-Villalba E, Parra-Diaz P, Masjuan J (2020) Acute onset smell and taste disorders in the context of Covid-19: a pilot multicenter PCR-based case-control study. *Eur J Neurol*. <https://doi.org/10.1111/ene.14273>
- Bergmann CC, Lane TE, Stohlman SA (2006) Coronavirus infection of the central nervous system: host-virus stand-off. *Nat Rev Microbiol* 4:121–132
- Bernstein HG, Schon E, Ansorge S, Rose I, Dorn A (1987) Immunolocalization of dipeptidyl aminopeptidase (DAPIV) in the developing human brain. *Int J Devel Neurosci* 5(3):237–242

- Bernstein HG, Dobrowolny H, Keilhoff G, Steiner J (2018) Dipeptidyl peptidase IV, which probably plays important roles in Alzheimer disease (AD) pathology, is upregulated in AD brain neurons and associates with amyloid plaques. *Neurochem Int* 114:55–57
- Bitnun A, Allen U, Heurter H, King SM, Opavsky MA, Ford-Jones EL, Matlow A, Kitai I, Tellier R, Richardson S, Manson D, Babyn P, Read S, Other Members of the Hospital for Sick Children SARS Investigation Team (2003) Children hospitalized with severe acute respiratory syndrome-related illness in Toronto. *Pediatrics* 112:e261–e268
- Booth SM, Matukas LM, Tomlinson GA, Rachlis AR, Rose DB, Dwosh HY et al (2003) Clinical features and short-term outcomes of 144 patients with SARS in the greater Toronto area. *JAMA* 289(21):2801–2809
- Braun E, Sauter D (2019) Furin-mediated protein processing in infectious diseases and cancer. *Clinical & Translational Immunol* 8:e1073. <https://doi.org/10.1002/cti2.1073>
- Bryce C, Grimes Z, Pujadas E, Ahuja S, Beasley MB, Albrecht R, et al. (2020) Pathophysiology of SARS-CoV-2: targeting of endothelial cells renders a complex disease with thrombotic microangiopathy and aberrant immune response. The Mount Sinai COVID-19 autopsy experience. medRxiv preprint <https://doi.org/10.1101/2020.05.18.20099960>, Accessed May 22, 2020
- Burks JS, DeVald BL, Jankovsky LD, Gerdes JC (1980) Two coronaviruses isolated from central nervous system tissue of two multiple sclerosis patients. *Science* 209:933–934
- Cameron MJ, Bermejo-Martin JF, Danesh A, Muller MP, Kelvin DJ (2008) Human immunopathogenesis of severe acute respiratory syndrome (SARS). *Virus Res* 133:13–19
- Carman KB, Calik M, Karal Y, Isikay S, Kocak O, Ozcelik A, Yazar AS, Nuhoglu C, Sag C, Kilic O, Dinleyici M, Lacinel Gurlevik S, Yimenicioglu S, Ekici A, Perk P, Tosun A, Isik I, Yazar C, Arslantas D, Dinleyici EC (2019) Viral etiological causes of febrile seizures for respiratory pathogens (EFES study). *Human Vaccines Immunother* 15(2):496–502
- Chen L, Li X, Chen M, Feng Y, Xiong C (2020) The ACE2 expression in human heart indicates new potential mechanism of heart injury among patients infected with SARS-CoV-2. *Cardiovasc Res* 116:1097–1100. <https://doi.org/10.1093/cvr/cvaa078>
- Cheung CY, Poon LLM, Ng IHY, Luk W, Sia SF, Wu MHS, Chan KH, Yuen KY, Gordon S, Guan Y, Peiris JSM (2005) Cytokine responses in severe acute respiratory coronavirus-infected macrophages in vitro: possible relevance to pathogenesis. *J Virol* 79(12):7819–7826
- Chiotos K, Bassiri H, Behrens EM, Blatz AM, Chang J, Diorio C et al (2020) Multisystem inflammatory syndrome in children during the COVID-19 pandemic: a case series. *J Pediatric Infect Dis Soc* paa069. <https://doi.org/10.1093/jpids/piaa069>
- Chiu WK, Cheung PCH, Ng KL, Ip PLS, Sugunan VK, Luk DCK, Ma LCK, Chan BHB, Lo KL, Lai WM (2003) Severe acute respiratory syndrome in children: experience in a regional hospital in Hong Kong. *Pediatr Crit Care Med* 4:279–283
- Chiu SS, Chan KH, Chu KW, Kwan SW, Guan Y, Poon LLM, Peiris JSM (2005) Human coronavirus NL63 infection and other coronavirus infections in children hospitalized with acute respiratory disease in Hong Kong, China. *Clin Infect Dis* 40:1721–1729
- Crystallo A, Gambaro F, Biamonti G, Ferrante P, Battaglia M, Cereda PM (1997) Human coronavirus polyadenylated RNA sequences in cerebrospinal fluid from multiple sclerosis patients. *New Microbiol* 20(2):105–114
- Desforges M, Miletti TC, Gagnon M, Talbot PJ (2007) Activation of human monocytes after infection by human coronavirus 229E. *Virus Res* 130:228–240
- Dessau RB, Lisby G, Frederiksen JL (2001) Coronaviruses in brain tissue from patients with multiple sclerosis. *Acta Neuropathol* 101:601–604
- Ding Y, He L, Zhang Q, Huang Z, Che X, Hou J, Wang H, Shen H, Qiu L, Li Z, Geng J, Cai J, Han H, Li X, Kang W, Weng D, Liang P, Jiang S (2004) Organ distribution of severe acute respiratory syndrome (SARS) associated coronavirus (SARS-CoV) in SARS patients: implications for pathogenesis and virus transmission pathways. *J Pathol* 203:622–630
- Dominguez SR, Robinson CC, Holmes KV (2009) Detection of four human coronaviruses in respiratory infections in children: a one-year study in Colorado. *J Med Virol* 81(9):1597–1604
- Doobay MF, Talman LS, Obr TD, Tian X, Davisson RL, Lazartigues E (2007) Differential expression of neuronal ACE2 in transgenic mice with overexpression of the brain renin-angiotensin system. *Am J Physiol Regul Integr Comp Physiol* 292:R373–R381
- Dube M, Coupance AL, Wong AHM, Rini JM, Deforges M, Talbot PJ (2018) Axonal transport enables neuron-to-neuron propagation of human coronavirus OC43. *J Virol* 92(17):e00404–e00418
- Elased KM, Cunha TS, Marcondes FK, Morris M (2008) Brain angiotensin-converting enzymes: role of angiotensin-converting enzyme 2 in processing angiotensin II in mice. *Exp Physiol* 93(5):665–675
- Eliezer M, Hautefort C, Hamel AL, Verillaud B, Herman P, Houdart E, Eloit C (2020) Sudden and complete olfactory loss function as a possible symptom of COVID-19. *JAMA Otolaryngol*. <https://doi.org/10.1001/jamaoto.2020.0832>
- Elkjaer ML, Frisch T, Reynolds R, Kacprowski T, Burton M, Kruse TA, Thomassen M, Baumbach J, Illes Z (2019) Signature of different lesion types in the brain white matter of patients with progressive multiple sclerosis. *Acta Neuropathologica Commun* 7:205. <https://doi.org/10.1186/s40478-019-0855-7>
- Gallagher PE, Chappell MC, Ferrario CM, Tallant EA (2006) Distinct roles for ANG II and ANG-(1-7) in the regulation of angiotensin-converting enzyme 2 in rat astrocytes. *Am J Physiol Cell Physiol* 290:C420–C426
- Giannis D, Ziogas IA, Gianni P (2020) Coagulation disorders in coronavirus infected patients: COVID-19, SARS-CoV-1, MERS-CoV and lessons from the past. *J Clin Virol*:104362. <https://doi.org/10.1016/j.jcv.2020.104362>
- Glowacka I, Bertram S, Herzog P, Pfeifferle S, Steffen I, Muench MO, Simmons G, Hofmann H, Kuri T, Weber F, Eichler J, Drosten C, Pöhlmann S (2010) Differential downregulation of ACE2 by the spike proteins of severe acute respiratory syndrome coronavirus and human coronavirus NL63. *J Virol* 84(2):1198–1205
- Granerod J, Ambrose HE, Davies NW, Clewley JP, Walsh AL, Morgan D, Cunningham R, Zuckerman M, Mutton KJ, Solomon T, Ward KN, Lunn MP, Irani SR, Vincent A, Brown DW, Crowcroft NS, UK Health Protection Agency (HPA) Aetiology of Encephalitis Study Group (2010) Causes of encephalitis and differences in their clinical presentations in England: a multicenter, population-based, prospective study. *Lancet Infect Dis* 10:835–844
- Gu J, Korteweg C (2007) Pathology and pathogenesis of severe acute respiratory syndrome. *Am J Pathol* 170(4):1136–1147
- Gu J, Gong E, Zhang B, Zheng J, Gao Z, Zhong Y, Zou W, Zhan J, Wang S, Xie Z, Zhuang H, Wu B, Zhong H, Shao H, Fang W, Gao D, Pei F, Li X, He Z, Xu D, Shi X, Anderson VM, Leong ASY (2005) Multiple organ infection and the pathogenesis of SARS. *J Exp Med* 202(3):415–424
- Gutierrez-Ortiz C, Mendez A, Rodrigo-Rey S, Pedro-Murillo ES, Bermejo-Guerrero L, Gordo-Manas R et al (2020) Miller Fisher syndrome and polyneuritis cranialis in COVID-19. *Neurology*. <https://doi.org/10.1212/WNL.00000000000009619>
- Hamming I, Timens W, Bulthuis MLC, Lely AT, Navis GJ, van Goor H (2004) Tissue distribution of ACE2 protein, the functional receptor for SARS coronavirus. A first step in understanding SARS pathogenesis. *J Pathol* 203:631–637
- Helms J, Kremer S, Merdji H, Clere-Jehl R, Schenck M, Kummerlen C, Collange O, Boulay C, Fafi-Kremer S, Ohana M, Anheim M,

- Meziani F (2020) Neurologic features in severe SARS-CoV-2 infection. *N Engl J Med* 382:2268–2270. <https://doi.org/10.1056/NEJMc2008597>
- Hoffmann M, Kleine-Weber H, Schroeder S, Kruger N, Herrier T, Erichsen S et al (2020) SARS-CoV-2 cell entry depends on ACE2 and TMPRSS2 and is blocked by a clinically proven protease inhibitor. *Cell* 181:1–10. <https://doi.org/10.1016/j.cell.2020.02.052>
- Hofmann H, Pyrc K, van der Hoek L, Geier M, Berkhout B, Pohlmann S (2005) Human coronavirus NL63 employs the severe acute respiratory syndrome coronavirus receptor for cellular entry. *Proc Natl Acad Sci* 102(22):7988–7993
- Hon KLE, Leung CW, Cheng WTF, Chan PKS, Chu WCW, Kwan YW, Li AM, Fong NC, Ng PC, Chiu MC, Li CK, Tam JS, Fok TF (2003) Clinical presentations and outcome of severe acute respiratory syndrome in children. *Lancet* 361:1701–1703
- Hulswit RJG, Lang Y, Bakkers MJG, Li W, Li Z, Schouten A, Ophorst B, van Kuppeveld FJM, Boons GJ, Bosch BJ, Huizinga EG, de Groot RJ (2019) Human coronaviruses OC43 and HKU1 bind to 9-O-acetylated sialic acids via a conserved receptor-binding site in spike protein domain A. *Proc Natl Acad Sci* 116(7):2681–2690
- Hung ECW, Chim SSC, Chan PKS, Tong YK, Ng EKO, Chiu RWK, Leung CB, Sung JY, Tam JS, Lo YMD (2003) Detection of SARS coronavirus RNA in the cerebrospinal fluid of a patient with severe acute respiratory syndrome. *Clin Chem* 49(12):2108–2109
- Jacomy H, Fragoso G, Almazan G, Mushynski WE, Talbot PJ (2006) Human coronavirus OC43 infection induces chronic encephalitis leading to disabilities in Balb/C mice. *Virology* 349:335–346
- Jacquinet E, Rao NV, Rao GV, Zhengming W, Albertine KH, Hoidal JR (2001) Cloning and characterization of the cDNA and gene for human epitheliasin. *Eur J Biochem* 268:2687–2699
- Jeffers SA, Tusell SM, Gillim-Ross L, Hemmila EM, Achenbach JE, Babcock GJ, Thomas WD, Thackray LB, Young MD, Mason RJ, Ambrosino DM, Wentworth DE, DeMartini JC, Holmes KV (2004) CD209L (L-SIGN) is a receptor for severe acute respiratory syndrome coronavirus. *Proc Natl Acad Sci* 101(44):15748–15753
- Kar S, Gao L, Zucker IH (2010) Exercise training normalizes ACE and ACE2 in the brain of rabbits with pacing-induced heart failure. *J Appl Physiol* 108:923–932
- Kim JE, Heo JH, Kim HO, Song SH, Park SS, Park TH, Ahn JY, Kim MK, Choi JP (2017) Neurological complications during treatment of Middle East respiratory syndrome. *J Clin Neurol* 13(3):227–233
- Kleine-Weber H, Elzayat MT, Hoffmann M, Pohlmann S (2018) Functional analysis of potential cleavage sites in the MERS-coronavirus spike protein. *Nature Sci Reports* 8:16597. <https://doi.org/10.1038/s41598-018-34859-w>
- Kneen R, Michael BD, Menson E, Mehta B, Easton A, Hemingway C, Klapper PE et al (2012) Management of suspected viral encephalitis in children—Association of British Neurologists and British Paediatric Allergy, Immunology and Infection Group national guidelines. *J Inf Secur* 64:449–477
- Lai MMC, Stohlman SA (1992) Molecular basis of neuropathogenicity of mouse hepatitis virus. In: *Molecular neurovirology*, Roos, ed., Humana Press, pp 319–348
- Larrinaga G, Callado LF, Agirregoitia N, Varona A, Gil J (2005) Subcellular distribution of membrane-bound aminopeptidases in the human and rat brain. *Neurosci Lett* 383:136–140
- Lau KK, Yu WC, Chu CM, Lau ST, Sheng B, Yuen KY (2004) Possible central nervous system infection by SARS coronavirus. *Emerg Infect Dis* 10(2):342–344
- Lau SKP, Woo PCY, Yip CCY, Tse H, Tsoi HW, Cheng VCC, Lee P, Tang BSF, Cheung CHY, Lee RA, So LY, Lau YL, Chan KH, Yuen KY (2006) Coronavirus HKU1 and other coronavirus infections in Hong Kong. *J Clin Microbiol* 44(6):2063–2071
- Law HKW, Cheung CY, Ng HY, Sia SF, Chan YO, Luk W, Nicholls JM, Peiris JSM, Lau YL (2005) Chemokine up-regulation in SARS-coronavirus-infected, monocyte-derived human dendritic cells. *Blood* 106:2366–2374
- Lechien JR, Chiesa-Estomba CM, DeSiati DR, Horoi M, LeBon SD, Rodriguez A et al (2020) Olfactory and gustatory dysfunctions as a clinical presentation of mild-to-moderate forms of the coronavirus disease (COVID-19): a multicenter European study. *Eur Arch Oto Rhino Laryngol*. <https://doi.org/10.1007/s00405-020-05965-1>
- Lee N, Hui D, Wu A, Chan P, Cameron P, Joynt GM, Ahuja A, Yung MY, Leung CB, To KF, Lui SF, Szeto CC, Chung S, Sung JY (2003) Major outbreak of severe acute respiratory syndrome in Hong Kong. *New Engl J Med* 348(20):1986–1994
- Li K, Wohlford-Lenane C, Perlman S, Zhao J, Jewell AK, Reznikov LR, Gibson-Corley KN, Meyerholz DK, McCray PB Jr (2016a) Middle East respiratory syndrome coronavirus causes multiple organ damage and lethal disease in mice transgenic for human dipeptidyl peptidase 4. *J Infect Dis* 213:712–722
- Li Y, Fan R, Wen B, Zhang J, Cao X, Wang C et al (2016b) Coronavirus infections in the central nervous system and respiratory tract show distinct features in hospitalized children. *Intervirology* 59:163–169
- Li YC, Bai WZ, Hashikawa T (2020) The neuroinvasive potential of SARS-CoV2 may be at least partially responsible for the respiratory failure of COVID-19 patients. *J Med Virol*:1–4. <https://doi.org/10.1002/jmv.25728>
- Lu X, Zhang L, Du H, Zhang J, Li YY, Qu J et al (2020) SARS-CoV-2 infection in children. *New Engl J Med* 382(17):1663–1665. <https://doi.org/10.1056/NEJMc2005073>
- Mao L, Jin H, Wang M, Hu Y, Chen S, He Q, Chang J, Hong C, Zhou Y, Wang D, Miao X, Li Y, Hu B (2020) Neurologic manifestations of hospitalized patients with coronavirus disease 2019 in Wuhan, China. *JAMA Neurol* 77:683. <https://doi.org/10.1001/jamaneurol.2020.1127>
- Martina BEE, Haagmans BL, Kuiken T, Fouchier RAM, Rimmelzwaan GF, van Amerongen G, Peiris JSM, Lim W, Osterhaus ADME (2003) SARS virus infection of cats and ferrets. *Nature* 425:915
- McCray PB, Pewe L, Wohlford-Lenane C, Hickey M, Manzel H, Shi L et al (2007) Lethal infection of K18-hACE2 mice infected with severe acute respiratory syndrome coronavirus. *J Virol* 81(2):813–821
- Mentzel S, Dijkman HBPM, van Son JPHF, Koene RAP, Assmann KJM (1996) Organ distribution of aminopeptidase A and dipeptidyl peptidase IV in normal mice. *J Histochem Cytochem* 44(5):445–461
- Mondolfi AP, Bryce C, Grimes Z, Gordon RE, Reidy J, Lednický J et al (2020) Central nervous system involvement by severe acute respiratory syndrome coronavirus-2 (SARS-CoV-2). *J Med Virol* 92:699–702. <https://doi.org/10.1002/jmv.25915>
- Morfopoulou S, Brown JR, Davies EG, Anderson G, Virasami A, Qasim W, Chong WK, Hubank M, Plagnol V, Desforges M, Jacques TS, Talbot PJ, Breuer J (2016) Human coronavirus OC43 associated with fatal encephalitis. *N Engl J Med* 375(5):497–498
- Moriguchi T, Harii N, Goto J, Harada D, Sugawara H, Takamino J, Ueno M, Sakata H, Kondo K, Myose N, Nakao A, Takeda M, Haro H, Inoue O, Suzuki-Inoue K, Kubokawa K, Ogihara S, Sasaki T, Kinouchi H, Kojin H, Ito M, Onishi H, Shimizu T, Sasaki Y, Enomoto N, Ishihara H, Furuya S, Yamamoto T, Shimada S (2020) A first case of meningitis/encephalitis associated with SARS-coronavirus-2. *Int J Infect Dis* 94:55–58. <https://doi.org/10.1016/j.ijid.2020.03.062>
- Mukhtar M, Harley S, Chen P, BouHamdan M, Patel C, Acheampong E, Pomerantz RJ (2002) Primary isolated human brain microvascular endothelial cells express diverse HIV/SIV-associated chemokine coreceptors and DC-SIGN and L-SIGN. *Virology* 297:78–88
- Murray RS, Cai GY, Hoel K, Zhang JY, Soike KF, Cabirac GF (1992a) Coronavirus infects and causes demyelination in primate central nervous system. *Virology* 188:274–284

- Murray RS, Brown B, Brian D, Cabirac GF (1992b) Detection of coronavirus RNA and antigen in multiple sclerosis brain. *Ann Neurol* 31: 525–533
- Nathan N, Prevost B, Corvol H (2020) Atypical presentation of COVID-19 in young infants. *Lancet* 395:1481. [https://doi.org/10.1016/S0140-6736\(20\)30980-6](https://doi.org/10.1016/S0140-6736(20)30980-6)
- Netland J, Meyerholz DK, Moore S, Cassell M, Perlman S (2008) Severe acute respiratory syndrome coronavirus infection causes neuronal death in the absence of encephalitis in mice transgenic for human ACE 2. *J Virol* 82(15):7264–7275
- Ng PC, Leung CW, Chiu WK, Wong SF, Hon EKL (2004) SARS in newborns and children. *Biol Neonate* 85:293–298
- Ng DL, Hosani FA, Keating MK, Gerber SI, Jones TL, Metcalfe M et al (2016) Clinicopathologic, immunohistochemical, and ultrastructural findings in a fatal case of Middle East respiratory syndrome coronavirus infection in the United Arab Emirates, April 2014. *Am J Pathol* 186(3):652–658
- Nicholls JM, Butany J, Poon LLM, Chan KH, Beh SL, Poutanen S, Peiris JSM, Wong M (2006) The course and cellular localization of SARS-CoV nucleoprotein and RNA in lungs from fatal cases of SARS. *PLoS Med* 3(2):e27. <https://doi.org/10.1371/journal.pmed.0030027>
- Oxley TJ, Mocco J, Majidi S, Kellner CP, Shoirah H, Singh IP, de Leacy RA, Shigematsu T, Ladner TR, Yaeger KA, Skliut M, Weinberger J, Dangayach NS, Bederson JB, Tuhim S, Fifi JT (2020) Large-vessel stroke as a presenting feature of COVID-19 in the young. *N Engl J Med* 382:e60. <https://doi.org/10.1056/NEJMc2009787>
- Perlman S, Wheeler DL (2016) Neurotropic coronavirus infections. In: *Neurotropic viral infections*, Volume 1, 2nd edition. Carol Shoshkes Reiss, ed. Springer Publishing Company, pp 115–148
- Perlman S, Dandekar AA (2005) Immunopathogenesis of coronavirus infections: implications for SARS. *Nat Rev Immunol* 5:917–927
- Perlman S, Masters PS (2020) Coronaviridae: the viruses and their replication. In: *Fields virology—emerging viruses – Volume 1*, 7th edition, Howley and Knipe, eds. Lippincott, Williams & Wilkins, pp 410–448
- Pleasure SJ, Green AJ, Josephson A (2020) The spectrum of neurologic disease in the severe acute respiratory syndrome coronavirus 2 pandemic infection: neurologists move to the frontline. *JAMA Neurology*:E1–E2
- Pokorn M, Jevsnik M, Petrovec M, Steyer A, Mrvic T, Grosek S et al (2017) Respiratory and enteric virus detection in children: a prospective study comparing children with febrile seizures and healthy controls. *J Child Neurol* 32(1):84–93
- Poyiadji N, Shahin G, Noujaim D, Stone M, Patel S, Griffith B (2020) COVID-19-associated acute hemorrhagic necrotizing encephalopathy: CT and MRI features. *Radiology*. <https://doi.org/10.1148/radiol.2020201187>
- Principi N, Bosis S, Esposito S (2010) Effects of coronavirus infections in children. *Emerg Infect Dis* 16(2):183–188
- Reichard RR, Kashani KB, Boire NA, Constantopoulos E, Guo Y, Lucchinetti CF (2020) Neuropathology of COVID-19: a spectrum of vascular and acute disseminated encephalomyelitis (ADEM)-like pathology. *Acta Neuropathol*. <https://doi.org/10.1007/s00401-020-02166-2>
- Riphagen S, Gomez X, Gonzalez-Martinez C, Wilkinson N, Theocharis P (2020) Hyperinflammatory shock in children during COVID-19 pandemic. *Lancet* 395(10237):1607–1608
- Riski H, Hovi T (1980) Coronavirus infections of man associated with diseases other than the common cold. *J Med Virol* 6:259–265
- Rissi DR (2018) A retrospective study of the neuropathology and diagnosis of naturally occurring feline infectious peritonitis. *J Vet Diagn Investig* 30(3):392–399
- Saad M, Omrani AS, Baig K, Bahloul A, Elzein F, Matin MA, Selim MAA, Mutairi MA, Nakhli DA, Aidaroos AYA, Sherbeeni NA, al-Khashan HI, Memish ZA, Albarrak AM (2014) Clinical aspects and outcomes of 70 patients with Middle East respiratory syndrome coronavirus infection: a single-center experience in Saudi Arabia. *Int J Infect Dis* 29:301–306
- Sakima A, Averill DB, Gallagher PE, Kasper SO, Tommasi EN, Ferrario CM, Diz DI (2005) Impaired heart rate baroreflex in older rats: role of endogenous angiotensin-(1-7) at the nucleus tractus solitarius. *Hypertension* 46:333–340
- Schnaar RL, Gerardy-Schahn R, Hildebrandt H (2014) Sialic acids in the brain: gangliosides and polysialic acid in nervous system development, stability, disease, and regeneration. *Physiol Rev* 94(2):461–518
- Sharma S, Mishra D, Aneja S, Kumar R, Jain A, Vashishtha VM, for the Expert Group on Encephalitis, Indian Academy of Pediatrics (2012) Consensus guidelines on evaluation and management of suspected viral encephalitis in children in India. *Indian Pediatr* 49:897–910
- Shi X, Gong E, Gao D, Zhang B, Zheng Z, Gao Z et al (2005) Severe acute respiratory syndrome associated coronavirus is detected in intestinal tissues of fatal cases. *Am J Gastroenterol* 100(1):169–176
- Shi J, Wen Z, Zhong G, Yang H, Wang C, Huang B, Liu R, He X, Shuai L, Sun Z, Zhao Y, Liu P, Liang L, Cui P, Wang J, Zhang X, Guan Y, Tan W, Wu G, Chen H, Bu Z (2020) Susceptibility of ferrets, cats, dogs, and other domesticated animals to SARS-coronavirus 2. *Science* 368:1016–1020
- Shirato K, Kawase M, Matsuyama S (2018) Wild-type human coronaviruses prefer cell-surface TMPRSS2 to endosomal cathepsins for cell entry. *Virology* 517:9–15
- Smyth LCD, Rustenhoven J, Scotter EL, Schweder P, Faul RLM, Park TIH, Dragunow M (2018) Markers for human brain pericytes and smooth muscle cells. *J Chem Neuroanat* 92:48–60
- Song R, Preston G, Yosypiv IV (2012) Ontogeny of angiotensin-converting enzyme 2. *Pediatric Res* 71(1):13–19
- South AM, Tomlinson L, Edmonston D, Hiremath S, Sparks MA (2020) Controversies of renin-angiotensin system inhibition during the COVID-19 pandemic. *Nat Rev Nephrol* 16:305–307. <https://doi.org/10.1038/s41581-020-0279-4>
- Spinato G, Fabbris C, Polesel J, Cazzafior D, Borsetto D, Hopkins C, Boscolo-Rizzo P (2020) Alterations in smell or taste in mildly symptomatic outpatients with SARS-CoV-2 infection. *JAMA* 323(20): 2089–2090
- Stewart JN, Mounir S, Talbot PJ (1992) Human coronavirus gene expression in the brains of multiple sclerosis patients. *Virology* 191:502–505
- St-Jean JR, Jacomy H, Desforges M, Vabret A, Freymuth F, Talbot PJ (2004) Human respiratory coronavirus OC43: genetic stability and neuroinvasion. *J Virol* 78(16):8824–8834
- Suzuki M, Saito K, Min WP, Vladau C, Toida K, Itoh H, Murakami S (2007) Identification of viruses in patients with postviral olfactory dysfunction. *Laryngoscope* 117(2):272–277
- Tagarro A, Epalza C, Santos M, Sanz-Santaeufemia FJ, Otheo E, Moraleda C, Calvo C (2020) Screening and severity of coronavirus disease 2019 (COVID-19) in children in Madrid, Spain. *JAMA Pediatrics*. <https://doi.org/10.1001/jamapediatrics.2020.1346>
- Thomas G (2002) Furin at the cutting edge: from protein traffic to embryogenesis and disease. *Nat Rev Mol Cell Biol* 3(10):753–766
- Toscano G, Palmerini F, Ravaglia S, Ruiz L, Invernizzi P, Cuzzoni MG, Franciotta D, Baldanti F, Daturi R, Postorino P, Cavallini A, Micieli G (2020) Guillain-Barre syndrome associated with SARS-CoV-2. *New Engl J Med*. <https://doi.org/10.1056/NEJMc2009191>
- Tsai LK, Hsieh ST, Chao CC, Chen YC, Lin YH, Chang SC, Chang YC (2004) Neuromuscular disorders in severe acute respiratory syndrome. *Arch Neurol* 61:1669–1673
- Tseng CTK, Perrone LA, Zhu H, Makino S, Peters CJ (2005) Severe acute respiratory syndrome and the innate immune responses: modulation of effector cell function without productive infection. *J Immunol* 174:7977–7985
- Tunkel AR, Glaser CA, Bloch KC, Sejvar JJ, Marra CM, Roos KL, Hartman BJ, Kaplan SL, Scheld WM, Whitley RJ, Infectious

- Diseases Society of America (2008) The management of encephalitis: clinical practice guidelines by the Infectious Diseases Society of America. *Clin Infect Dis* 47:303–327
- Turgay C, Emine T, Ozlem K, Muhammet SP, Haydar AT (2015) A rare case of acute flaccid paralysis: human coronaviruses. *J Pediatr Neurosci* 10:280–281
- Turtle L (2020) Respiratory failure alone does not suggest central nervous system invasion by SARS-CoV-2. *J Med Virol* 92:705–706. <https://doi.org/10.1002/jmv.25828>
- Umapathi T, Kor AC, Venketasubramanian N, Lim CCT, Pang BC, Yeo TT, Lee CC, Lim PL, Ponnudurai K, Chuah KL, Tan PH, Tai DYH, Ang SPB (2004) Large artery ischemic stroke in acute respiratory syndrome (SARS). *J Neuro* 251:1227–1231
- Van Riel D, Verdijk R, Kuiken T (2015) The olfactory nerve: a shortcut for influenza and other viral diseases into the central nervous system. *J Pathol* 235:277–287
- Varga Z, Flammer AJ, Steiger P, Haberecker M, Andermatt R, Zinkernagel AS, Mehra MR, Schuepbach RA, Ruschitzka F, Moch H (2020) Endothelial cell infection and endotheliitis in COVID-19. *Lancet* 395:1417–1418. [https://doi.org/10.1016/S0140-6736\(20\)30937-5](https://doi.org/10.1016/S0140-6736(20)30937-5)
- Vawter MP, Basaric-Keys J, Li Y, Lester DS, Lebovics RS, Lesch KP, Kulaga H, Freed WJ, Sunderland T, Wolozin B (1996) Human olfactory neuroepithelial cells: tyrosine phosphorylation and process extension are increased by the combination of IL-1b, IL-6, NGF, and bFGF. *Exp Neurol* 142:179–194
- Venkatesan A, Tunkel AR, Bloch KC, Luring AS, Sejvar J, Bitnun A, Stahl JP, Mailles A, Drebot M, Rupprecht CE, Yoder J, Cope JR, Wilson MR, Whitley RJ, Sullivan J, Granerod J, Jones C, Eastwood K, Ward KN, Durrheim DN, Solbrig MV, Guo-Dong L, Glaser CA, on behalf of the International Encephalitis Consortium, Sheriff H, Brown D, Farnon E, Messenger S, Paterson B, Soldatos A, Roy S, Visvesvara G, Beach M, Nasci R, Pertowski C, Schmid S, Rascoe L, Montgomery J, Tong S, Breiman R, Franka R, Keuhnert M, Angulo F, Cherry J (2013) Case definitions, diagnostic algorithms, and priorities in encephalitis: consensus statement of the International Encephalitis Consortium. *Clinical Infect Dis* 57(8):1114–1128
- Wang B, Brand-Miller J (2003) The role and potential of sialic acid in human nutrition. *Eur J Clin Nutrition* 57:1351–1369
- Wang Q, Zhang Y, Wu L, Niu S, Song C, Zhang Z, Lu G, Qiao C, Hu Y, Yuen KY, Wang Q, Zhou H, Yan J, Qi J (2020) Structural and functional basis of SARS-CoV-2 entry by using human ACE2. *Cell* 181:1–11. <https://doi.org/10.1016/j.cell.2020.03.045>
- Wee LE, Chan YFZ, Teo NWY, Cherng BPZ, Thien SY, Wong H et al (2020) The role of self-reported olfactory and gustatory dysfunction as a screening criterion for suspected COVID-19. *Eur Arch Oto Rhino Laryn*. <https://doi.org/10.1007/s00405-020-05999-5>
- Wei M, Yuan J, Liu Y, Fu T, Yu X, Zhang Z-J (2020) Novel coronavirus infection in hospitalized infants under 1 year of age in China. *JAMA*. <https://doi.org/10.1001/jama.2020.2131>
- Wicinski M, Gorski K, Walczak M, Wodkiewicz E, Slupski M, Pawlak-Osinska K et al (2019) Neuroprotective properties of linagliptin: focus on biochemical mechanisms in cerebral ischemia, vascular dysfunction and certain neurodegenerative diseases. *Int J Mol Sci* 20:4052. <https://doi.org/10.3390/ijms20164052>
- Xu J, Zhong S, Liu J, Li L, Li Y, Wu X, Li Z, Deng P, Zhang J, Zhong N, Ding Y, Jiang Y (2005) Detection of severe acute respiratory syndrome coronavirus in the brain: potential role of the chemokine Mig in pathogenesis. *Clin Infect Dis* 41:1089–1096
- Yao L, Yi X, Pinto JM, Yuan X, Guo Y, Liu Y, Wei Y (2018) Olfactory cortex and olfactory bulb volume alterations in patients with post-infectious olfactory loss. *Brain Imaging Behav* 12:1355–1362
- Yeh EA, Collins A, Cohen ME, Duffner PK, Faden H (2004) Detection of coronavirus in the central nervous system of a child with acute disseminated encephalomyelitis. *Pediatrics* 113:e73–e76
- Young BE, Ong SWX, Kalimuddin S, Low JG, Tan SY, Loh J et al (2020) Epidemiologic features and clinical course of patients infected with SARS-CoV-2 in Singapore. *JAMA*. <https://doi.org/10.1001/jama.2020.3204>
- Zhang Y, Xiao M, Zhang S, Xia P, Cao W, Jiang W, Chen H, Ding X, Zhao H, Zhang H, Wang C, Zhao J, Sun X, Tian R, Wu W, Wu D, Ma J, Chen Y, Zhang D, Xie J, Yan X, Zhou X, Liu Z, Wang J, du B, Qin Y, Gao P, Qin X, Xu Y, Zhang W, Li T, Zhang F, Zhao Y, Li Y, Zhang S (2020) Coagulopathy and antiphospholipid antibodies in patients with COVID-19. *N Engl J Med* 382(17):e38. <https://doi.org/10.1056/NEJMc2007575>
- Zhao H, Shen D, Zhou H, Liu J, Chen S (2020) Guillain-Barre syndrome associated with SARS-CoV-2 infection: causality or coincidence? *Lancet* 19(5):383–384
- Zhou J, Chu H, Chan JFW, Yuen KY (2015) Middle East respiratory syndrome coronavirus infection: virus-host cell interactions and implications on pathogenesis. *Virol J* 12:218. <https://doi.org/10.1186/s12985-015-0446-6>

Publisher's note Springer Nature remains neutral with regard to jurisdictional claims in published maps and institutional affiliations.