

IMAGE

Dupuytren Subungual Exostosis

An 8-year-old, otherwise healthy boy presented with a 4-month history of a growing mass under the nail of his right fifth toe, painful on palpation, which caused onycholysis. The patient denied recent trauma or occurrence of similar lesions in the past. Family history was unremarkable. X-Ray showed a dorsomedial exostosis, of approximately 4×3 mm, on the right fifth toe.

Dupuytren's subungual exostosis (SE) is a rare heterotopic ossification that commonly involves the first toe or, more rarely, other toes or fingers. It usually presents with a solitary, fixed, painful, sometimes ulcerated or infected dorsomedial mass on the distal phalanx of toes or fingers, associated with elevation and dystrophy of the nail plate. The majority of patients are younger than 18 years. Triggers may be trauma or infections. The diagnosis is confirmed by radiography or histology.

Differential diagnosis includes viral warts, pyogenic granuloma and osteochondroma. Papillomavirus periungual warts are firm, keratotic papules which are located around the nail. They can be painful and cause onycholysis and hyperkeratosis. Pyogenic granuloma, an acquired benign vascular tumor, appears as a rapidly growing erythematous, soft, friable nodule with erosive surface and tendency to bleed under pressure, commonly located on fingers and toes but also in the head and neck region and oral mucosa. Osteochondroma is clinically similar to Dupuytren's SE but radiographically and histologically different – unlike the latter, in the majority of the cases, osteochondroma has continuity with the underlying bone and is covered by hyaline cartilage.

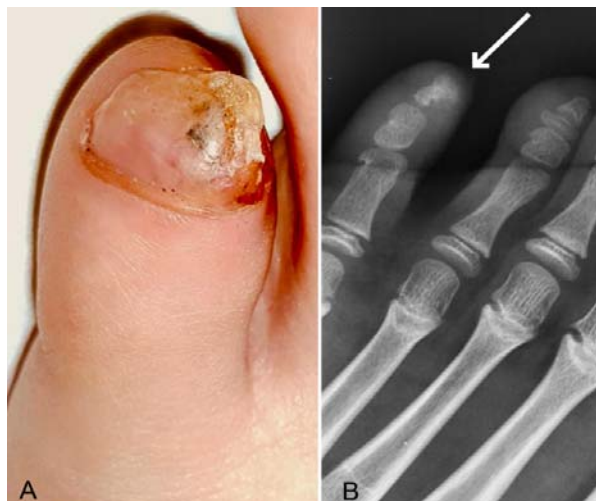


Fig. 1 Dupuytren's subungual exostosis; (a) mass under the nail of fifth toe causing onycholysis, and (b) radiograph showing dorsomedial exostosis (arrow).

Surgical treatment should aim to preserve the nail plate; nevertheless, an incomplete excision may lead to recurrence.

MARIO VACCARO,^{1*} LUCA DI BARTOLOMEO,² AND SERAFINELLA P CANNANO¹

¹Department of Clinical and Experimental Medicine – Dermatology and ²School and Operative Unit of Dermatology and Venereology - University of Messina, Italy.
*mario.vaccaro@unime.it

BOOK REVIEW



Principles of Medical Education (5th Edition, 2021)

ED. TEJINDER SINGH, PIYUSH GUPTA, DALJIT SINGH

Jaypee Brothers Medical Publishers (P) Ltd, Pages: 248

Medical education has to be dynamic, to keep pace with not only the changing health care needs but also the newer teaching-learning methods. India has recently witnessed a major shift in its undergraduate curriculum with focus on competencies, skills, and integration (both horizontal and vertical). The publication of the new edition of this book by authors who have played a key role in shaping the medical education curriculum in the country, is therefore, timely.

This handbook covers almost all the key themes which every medical teacher must be aware of. The initial chapters of the book cover the principles underlying teaching and learning and shift in

medical teaching, in particular the curriculum and integrated teaching the subsequent sections deal with various teaching methods. A greater part of the handbook is devoted to student assessment in medical education – essay, short answers and objective questions, assessment of practical and clinical skills, and at the workplace. The sections on assessing non-cognitive skills, mentoring, teacher evaluation and faculty development are particularly important.

The book is easy to read with its large well-spaced fonts, boxes with key information and easy to understand illustrations. It is a handbook that every medical teacher should have to help them in planning each day of their teaching. It should also hopefully enthrall them to innovate and make teaching-learning an enjoyable experience for both the preceptor and the student.

SIDDARTH RAMJI

*Department of Neonatology
Maulana Azad Medical College,
New Delhi
siddarthramji@gmail.com*