



Recurrent Dermatofibrosarcoma Protuberans of the Head and Neck: a Case Series

Suresh Mani¹ · Rajeev Kumar² · Aanchal Kakkar³ · Adarsh Barwad³ · Kondamudi Dheeraj² · Prem Sagar² · Rakesh Kumar²

Received: 27 May 2022 / Accepted: 23 August 2022 / Published online: 1 September 2022
© The Author(s), under exclusive licence to Indian Association of Surgical Oncology 2022

Abstract

Dermatofibrosarcoma protuberans (DFSP) is a rare cutaneous sarcoma that develops from dermal fibroblasts and spreads within the dermis and subcutaneous fat. It is locally aggressive, with a high local recurrence rate after excision but has extremely low metastatic potential. In the case of recurrent tumors, surgical excision with adequate margins is the gold standard treatment and may require adjuvant radiotherapy or chemotherapy in some cases. We conducted a retrospective analysis of individuals with dermatofibrosarcoma protuberance of the head and neck region that had treatment at our facility between 2016 and 2021. We gathered the data on the surgical techniques, reconstructive techniques used, histopathological features, adjuvant therapy, and outcomes. We treated three patients with head and neck dermatofibrosarcoma protuberance: one scalp lesion and two on the cheek. All three patients had recurrent tumors, two of whom were treated elsewhere for the primary lesion. One patient underwent surgery for a benign spindle cell tumor of the right cheek, but a final histopathological examination revealed dermatofibrosarcoma protuberance, and the tumor recurred within 3 months. The duration of recurrence is between 3 and 24 months. The size of the tumor ranges from 7.2 to 10.5 cm. The wide local excision margins range from 2 to 4 cm. Reconstruction ranges from split skin graft to regional flap. Inadequate margins raise the possibility of local recurrence in dermatofibrosarcoma protuberance.

Keywords Dermatofibrosarcoma protuberans · Sarcoma · Skin neoplasm · Scalp · Cutaneous malignancy

Introduction

Approximately half of all dermatofibrosarcoma protuberans (DFSP) cases are found on the trunk, followed by the extremities, accounting for 20–35% of cases. The head and neck region, on the other hand, is rarely involved (in 10–15% of cases) [1]. The early clinical symptoms of DFSP are non-specific, making diagnosis difficult and increasing the likelihood of misdiagnosis. The gold standard for diagnosing DFSP is the histopathological examination, with surgical resection remaining the primary treatment option [2]. Despite the achievement of “negative” margins, the high recurrence rate is thought to be due to the inability of standard histologic processing to evaluate large portions of the actual margins [3]. According to some studies, the occult finger-like projections of DFSP are responsible for tumor recurrence [3, 4].

In the literature, tumors with close or positive surgical margins, recurrent tumors, metastatic tumors, and large unresectable tumors are treated with radiation therapy and systemic therapy as adjuvant treatment modalities [5]

✉ Rajeev Kumar
rajeev9843@yahoo.co.in

Suresh Mani
msuresh.doc@gmail.com

Aanchal Kakkar
aanchalkakkar@gmail.com

Adarsh Barwad
adawad@gmail.com

Kondamudi Dheeraj
dheerajkondamudi@gmail.com

Prem Sagar
sgadrdprem@gmail.com

Rakesh Kumar
winirk@hotmail.com

¹ Department of Head and Neck Surgery, CMC, Vellore, India

² Department of ENT & Head and Neck Surgery, AIIMS, New Delhi, India

³ Department of Pathology, AIIMS, New Delhi, India

Materials and Method

All consecutive patients with recurrent DFSP of the head and neck region who received surgical treatment at our department from April 2016 to March 2021 were enrolled. The informed consent was acquired from each participant. We describe three cases of large, recurrent DFSPs occurring in the scalp and face and the therapeutic challenges in reconstructing the defect and providing adjuvant treatment (Tables 1 and 2).

Case 1

A 47-year-old man presented with a 10-year history of slowly progressive swelling on the right side of his scalp. He provided a history of previous surgery in 2008. One year after surgery, the swelling reappeared and grew to its current size of 8 × 7 cm. The swelling was pinkish, crusted, and broad in the right parieto-occipital region near the midline. The swelling was firm and tender on palpation. It was bleeding on crust removal. A contrast-enhanced computed tomography (CECT) scan revealed a 10.5 × 9-cm heterogeneously enhancing lesion in the right parietal region of the scalp without underlying bony erosion. Incisional biopsy revealed a cellular tumor composed of spindle cells in storiform architecture, immunopositive for CD34, consistent with dermatofibrosarcoma protuberans. Metastatic workup was negative. The tumor was entirely excised with a 4-cm tumor-free margin, and the defect was repaired with a split-thickness skin graft. Except at the previous scar site, where the pericranium was involved and excised, dissection took place in the loose areolar plane. The underlying bone was

tumor-free. The histology report revealed a negative peripheral tumor margin; however, with a close deep margin, the periosteum was uninvolved. The patient was advised adjuvant radiotherapy based on tumor size, recurrent nature, and close deep margin. However, he opted for observation and regular follow-up. He has been disease-free for 4 years and is on regular follow-up (Fig. 1).

Case 2

This 47-year-old female patient presented to us with complaints of a right cheek swelling that had bothered her for 3 years. FNAC from the swelling showed a benign spindle cell lesion. The patient underwent excision of the swelling by sub-labial approach, diagnosed as DFSP. The patient noticed a recurrence of the swelling 3 months after primary surgery, which progressed rapidly over a short period. On examination, there was a 10 × 8 × 4-cm swelling with stretched skin and dilated veins on the surface, extending from the lower eyelid to the lower border of the mandible. The local temperature was raised; the swelling was soft to firm and tender. CECT face revealed a heterogeneously enhancing lesion in the premaxilla, surrounded by a well-preserved plane and anterior skin involvement. A biopsy showed features of DFSP. The metastatic workup did not reveal any evidence of regional or distant spread.

The patient underwent wide local excision with a 2-cm margin around the tumor. The bilobed flap reconstructed the resultant defect. The final histology report revealed a dermal spindle cell tumor with cells arranged in a storiform pattern. Focally, tumor cells were arranged in a herringbone pattern and demonstrated nuclear atypia and frequent mitoses, accompanied by loss of CD34 immunoreactivity; necrosis

Table 1 Clinical profile of patients till the first surgery

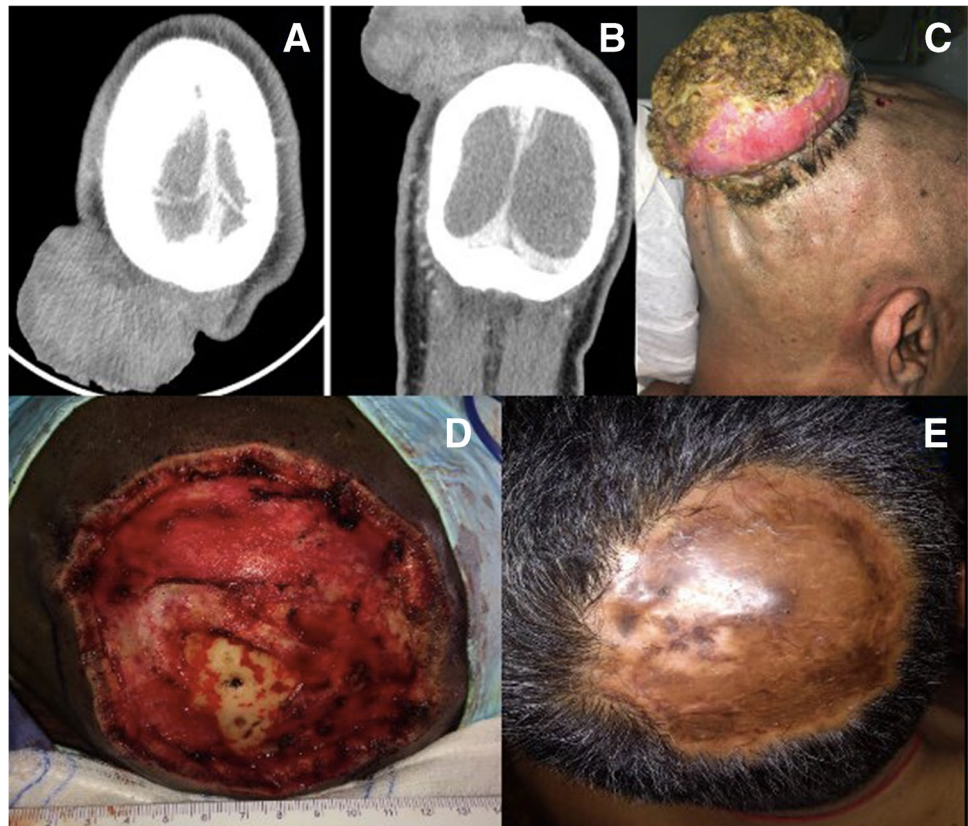
Patients	Age/sex	Duration of symptoms	FNAC before the first surgery	Primary surgery	Time to recurrence
1	47/M	12 months	Sebaceous cyst	Excision	12 months
2	47/F	31 months	Benign spindle cell lesion	Sublabial approach and excision of the mass	Three months
3	35/M	24 months	Not done	Excision	24 months

Table 2 Revision surgery, reconstructive methods, and follow up

Patients	Type of surgery	Margin took around the lesion	Reconstruction	Size of the tumor	Margin assessment	Adjuvant therapy	Follow up
1	Wide local excision	4 cm	Split thickness skin graft	10.5 × 9 × 5 cm	Close deep margin	No	NED at 48 months
2	Wide local excision	2 cm	Bilobed cervical rotation	10.2 × 7 × 5 cm	Close deep margin	RT	NED at 36 months
3	Wide local excision	2 cm	Supraclavicular flap	7.2 × 6 × 5.5 cm	Close deep margin	No	NED at 15 months

NED no evidence of disease

Fig. 1 CT axial view (A), and coronal view (B) showing the lesion on the parietal region. Preoperative view (C), defect after tumor excision (D), and follow-up after 4 years (E)



was present. Based on these features, the diagnosis of fibrosarcomatous DFSP was made. The peripheral tumor margins were negative; the deep margin was close to the tumor. The patient received postoperative adjuvant therapy based on the unfavorable histology, recurrent nature of the tumor, and close deep margin. She is disease-free after 36 months of follow-up (Fig. 2).

Case 3

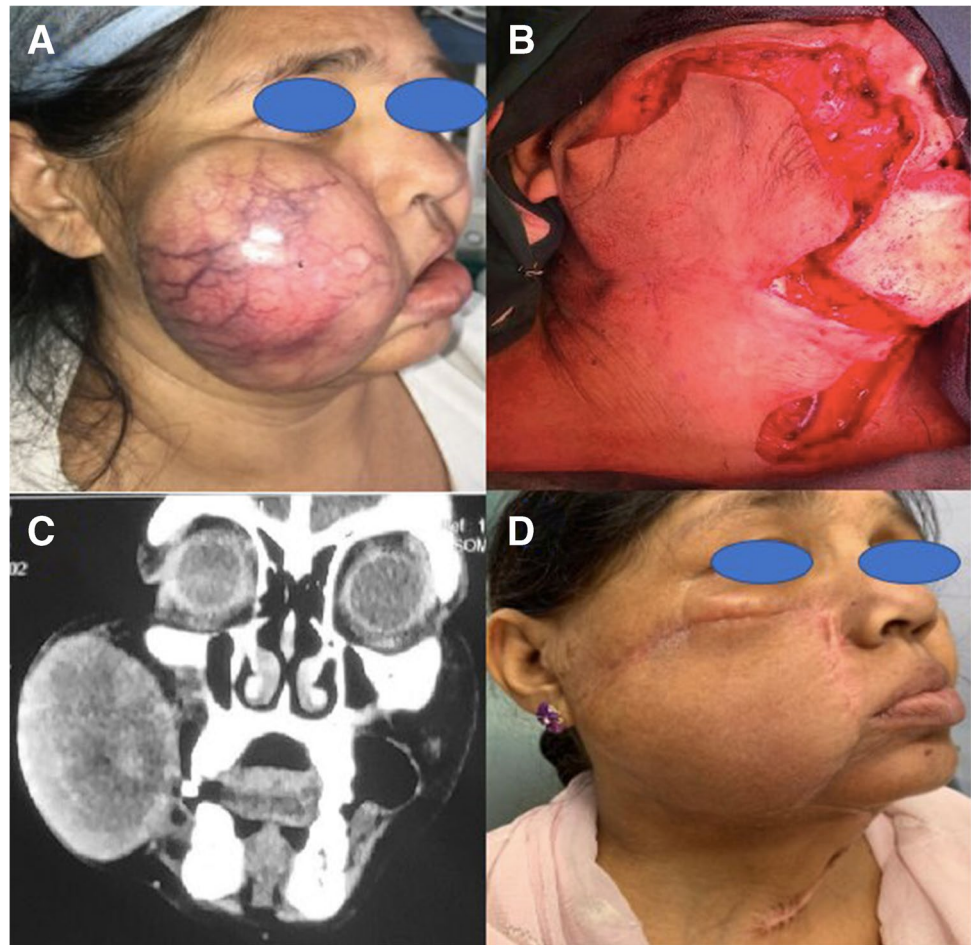
A 35-year-old male patient presented with a right-sided cheek swelling, slowly increasing in size for the previous 2 years. He had undergone surgery elsewhere for a similar swelling on his right cheek 4 years prior, revealing a low-grade fibromyxoid sarcoma. The swelling was pinkish, globular, and attached with a broad base in the right maxillary region, with a small projection of a previous scar at the lower part. The cheek swelling was non-tender and firm in consistency. CECT face revealed a $9 \times 8 \times 5$ -cm broad-based, heterogeneously enhancing lesion without underlying bony erosion in the right premaxillary region. Incisional biopsy showed features of a DFSP. Metastatic workup showed that the tumor had not spread to the rest of his body. The tumor was excised entirely with 2-cm margins, and the defect was reconstructed with a supraclavicular island flap (SCAIF). The distal end of the flap was random and had necrosis in

the postoperative period. It gradually healed with secondary intention (Clavien Dindo Class 3A). The final histopathology was consistent with DFSP with a close deep margin (Fig. 3). All other margins were free of tumor. He was discussed in the tumor board and advised adjuvant radiotherapy because of recurrent disease and close deep margin. However, because of the COVID-19 pandemic, he could not receive it. After a 15-month follow-up period, he is disease-free (Fig. 4).

Discussion

Although head and neck DFSP accounts for less than 5% of all cases, the literature review suggests that DFSP of the head and neck region has a high chance of local recurrence, up to 56% (Table 3). So, DFSP therapy frequently necessitates a multidisciplinary strategy. Depending on the area, the management may involve head and neck surgeons, dermatologic surgeons, surgical oncologists, plastic surgeons, neurosurgeons, radiation oncologists, and occasionally medical oncologists. There are no significant risk factors for DFSP, which primarily affects healthy skin but can sporadically appear on chronically scarred areas. The usual course of DFSP cases involves the emergence of a tiny, solid, and subtly stained skin nodule that enlarges over time and joins

Fig. 2 Preoperative view (A), defect after tumor excision (B), and follow-up after 2 years (D). CT coronal view (C) showing the lesion on the right cheek



with additional nodules to form an ill-defined circumscribed skin plaque [15].

If left untreated, the tumor exhibits slow and locally infiltrative invasiveness of the surrounding tissues, including fat, fascia, muscles, periosteum, and neurovascular bundles. DFSP's subclinical spread is incredibly variable [16]. Several local recurrences often precede the uncommon occurrence of metastasis, typically localized in a nearby lymph node or farther in the lung [4]. The high recurrence rates could be attributed to limited resection due to tumor location or complex reconstruction. Long-standing tumors are known to invade the fascia, muscle, and bone [16]. Fortunately, bone infiltration did not occur in any of our cases. The lack of bone infiltration could be due to the slow growth of the tumor and its exophytic nature. Also, the bony periosteum offers excellent resistance to invasion and acts as a barrier to tumor spread.

Magnetic resonance imaging is frequently used to determine the amount of local tumor dissemination once a diagnosis of DFSP is suspected or confirmed by biopsy. Additionally, high-frequency ultrasonography has been helpful in determining the extent of tumor infiltration and aiding in targeted biopsies. Computed tomography (CT) imaging can

be used to evaluate the initial tumor burden as well as the metastatic dissemination. Positron emission tomography-CT can help in assessing potential distant metastases and monitoring therapy response [17].

Two patients had inconclusive FNAC, leading to limited resection. Because DFSP shares morphological characteristics with other benign as well as low-grade malignant spindle-cell neoplasms such as fibrosarcoma, myxofibrosarcoma, low-grade fibromyxoid sarcoma, low-grade malignant peripheral nerve sheath tumor (MPNST), benign peripheral nerve sheath tumor, nodular fasciitis, and deep fibrous histiocytoma, FNAC has a limited role in preoperative diagnosis. When there is a clinical suspicion of cancer, incisional biopsy should be the preferred diagnostic procedure [18]. The myxoid, pigmented, giant cell, giant cell fibroblastoma, granular cell, sclerotic, and fibrosarcomatous (FS) components are among the histological types of DFSP. These variations demonstrate the morphologic variability linked to spindle cell differentiation during tumor growth. Except for the FS variety with a higher risk of local recurrence and potential for metastasis, they do not exhibit notable clinical symptoms and prognosis [19].

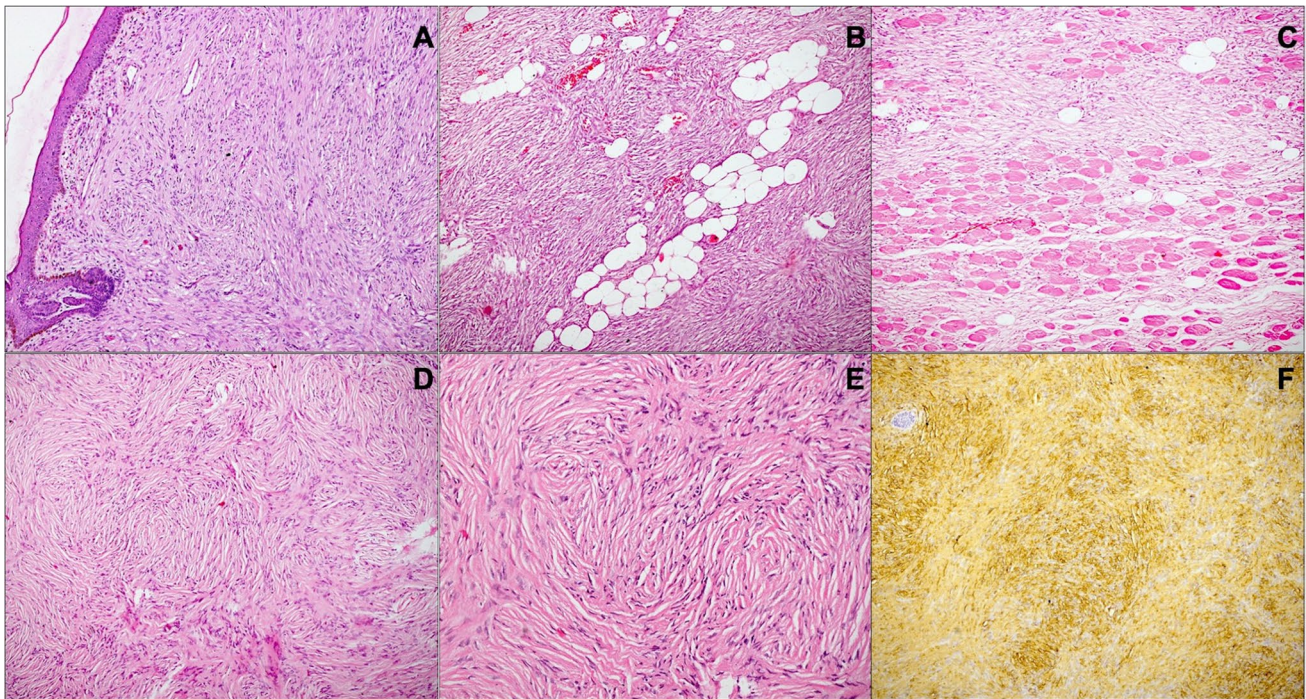


Fig. 3 Photomicrographs from DFSP show a dermal spindle cell tumor (A; HE, 10 \times) infiltrating subcutaneous fat (B; HE, 10 \times) and skeletal muscle (C; HE, 10 \times); tumor cells are arranged in a storiform

pattern (D; HE, 10 \times), have ill-defined cytoplasmic borders and bland nuclei (E; HE, 20 \times) and are immunopositive for CD34 (F; IHC, 10 \times)

There is no standard staging system for DFSP. Based on European consensus-based interdisciplinary guidelines, the primary tumor is considered stage I; lymph node metastasis is in stage II and distant metastasis is stage III [20]. Hao et al. proposed a modified staging system based on European guidelines [21] (Table 4). For site-specific, all the soft tissue tumors are staged according to the AJCC 8th edition (2017) staging system for soft tissue sarcoma of the head and neck region.

The objectives of effectively managing DFSP of the head and neck area are to ensure complete surgical excision and restore anatomic integrity with a functional and cosmetically acceptable outcome. We believe that incomplete tumor excision resulted in recurrence in all our cases. As a result, we treated them with wide local excision with 2–4-cm margins around the lesion. Mohs micrographic surgery (MMS) has recently gained popularity in treating DFSP due to its lower recurrence rate than wide excision. Some authors believe conserving tissue may compromise surgical margins, resulting in tumor recurrence [22, 23]. MMS has the advantage of tissue preservation over wide local excision. However, it has the disadvantages of a longer surgical time and the need for frozen sections, and it is a complex procedure to perform for large lesions. Derek DuBay et al. concluded that wide local excision with adequate margins is comparable to MMS in preventing tumor recurrence [3]. Patients undergoing wide excision with margins more than or equal to 3 cm were found

to have lower recurrence rates when compared with those with margins of 1.5–2 cm [24].

Reconstructing the face will be a difficult task at first because we must maintain a face appearance and color complexion that matches the facial skin. We faced a significant challenge due to giant recurrent lesions and the requirement for complete excision with appropriate reconstruction. Most cases reported in the literature required complex closure techniques such as mucocutaneous flaps, free flaps, and pedicle flaps with or without a skin graft [22–24]. Because of limited mobility and availability of the skin, scalp defects are challenging to close. We decided to excise the lesion with 4-cm margins all around so that we would not have to perform a frozen section. The defect was covered with a split-thickness skin graft (STSG) because of its significant size, almost 16 cm in the longest dimension. STSG reconstruction can be used to monitor for recurrence. Even though free tissue transfer would be the preferred reconstruction method, we used a local and regional flap for the face that could produce results comparable to free tissue flaps. We believe that regional flaps can reconstruct larger defects because free flaps are prohibitively expensive, increase operating time, and require an expert surgeon. Badeau et al. used tissue expansion to manage two cases of massive dermatofibrosarcoma protuberans of the head and neck and achieved a better cosmetic appearance. In the end, they suggested that the patient should decide whether to undergo

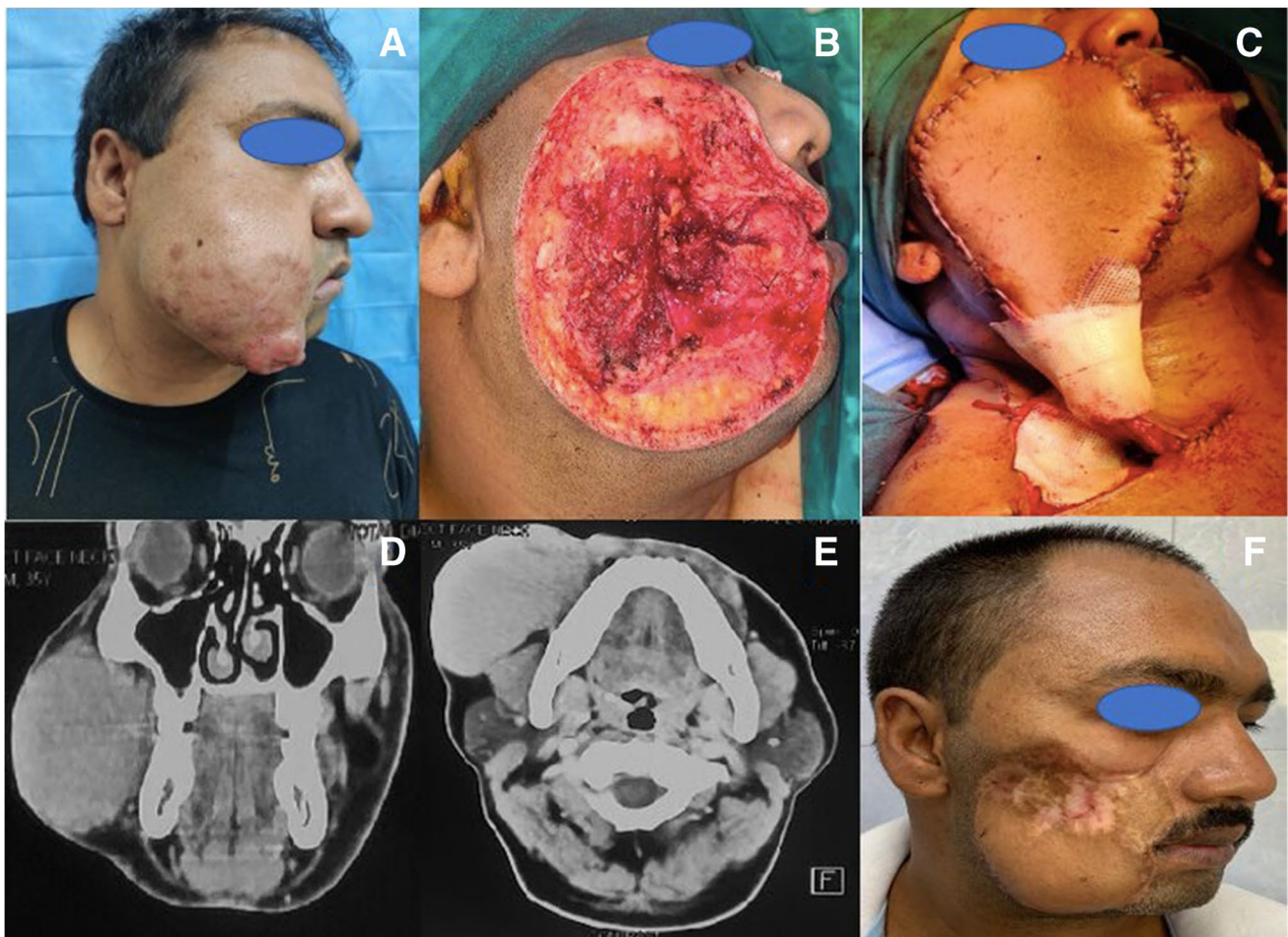


Fig. 4 Preoperative view (A), defect after tumor excision (B), reconstruction with SCAIF (C), and follow-up after 15 months (E). CT axial view (D) and coronal view (E) show the right cheek lesion

tissue expansion before or after tumor removal, conservatively considering the likelihood of local tumor growth or metastasis and positive margins against the requirement for staged reconstruction [25].

Because of the recurrent nature of the disease and the close deep margins on histology, we recommended adjuvant radiation therapy (RT). The previous surgery in a patient with scalp DFSP was a simple excision that did not adhere to oncological principles. We had complete surgical clearance, and the only indication for adjuvant therapy was the recurrent status. We discussed the risks and benefits of adjuvant RT with the patient, but he chose to have a follow-up without any adjuvant treatment. In limited studies, radiation therapy has been suggested as an adjuvant for DFSP variants, tumors with large width, those with increased expression of Ki-67 and positive surgical margins, after planned marginal excision in critical anatomic sites, or as an exclusive treatment in advanced cases with no feasible surgical approach [26, 27]. Two patients did not receive adjuvant radiation for various reasons and are symptom-free, suggesting that adequate

surgical excision can cure the disease. Therefore, preoperative confirmation of the diagnosis is a must in DFSP to avoid treatment failure.

Imatinib mesylate is a tyrosine kinase inhibitor that targets platelet-derived growth factor receptors (PDGFRs). Identifying the aberrant activation of the PDGF pathway led to the hypothesis that the inhibition of PDGFR may have clinical efficacy in treating DFSP. The recent National Comprehensive Cancer Network (NCCN) guidelines recommend using imatinib for metastasis and recurrences when “disease is unresectable, or unacceptable functional or cosmetic outcomes with the resection” [28, 29]. Histopathologic response to imatinib-treated DFSP samples frequently shows cellular-depleted areas replaced by hyalinized fibrotic stroma. These findings favor imatinib as neoadjuvant therapy to reduce the size of the tumor, especially in the head and neck region. Response to imatinib is seen primarily in cases harboring COL1A1-PDGFB gene fusion; hence, molecular testing by either FISH or RT-PCR is recommended before starting the therapy. These molecular cytogenetic studies may not be available everywhere.

Table 3 A literature review of DFSP of the head and neck region

Author	Year	No. of patients	Surgery	Reconstruction method	Recurrence	Conclusion
Leon Barnes [6]	1984	17	Wide local excision (WLE)	Primary/Grafting	53%	Prognosis is related to the adequacy of excision, number of local recurrence, and histological appearances
Rufus J. Mark [7]	1993	16	WLE	Primary/grafting	56%	Wide surgical resection achieving good margins offers an excellent probability of cure
Timothy L. Parker [8]	1995	7	MMS	Five patients had primary, one with cheek advancement, one with the secondary intension	No recurrence at 3 years median follow-up	Mohs surgery excises DFSP with maximum tissue conservation and a high cure rate
Chuan K Koh [9]	1995	8	WLE	Primary excision and graft	12.5%	Local recurrence is frequent. Wide surgical excision is the treatment of choice
Scott M. Gayner [10]	1997	32	WLE		34% (11 patients)	Should use surgical margins of 2 cm
Alexander Stojadinovic [11]	2000	33 (21 primaries, 12 recurrences)	WLE		9% (3 patients)	Local recurrence-free survival depends on a negative histological margin. The frozen section analysis may not be accurate
William David Tom [12]	2003	Nine patients (2 recurrences, seven primaries)	MMS		0 (median follow-up 43 months)	Wide local excision with 2- to 3-cm margins results in an unacceptably high recurrence rate; larger excisional margins are necessary to remove all disease
Thiele OC [13]	2009	Seven patients (recurrent)	WLE	Five required grafts, two closed local advancement	Two recurred, and salvage surgery for both	Radical surgical removal is the treatment of choice
Able González [14]	2020	41 patients	MMS	MMS excision and grafts	One patient (2.4%)	MMS should be the standard treatment for DFSP

Table 4 Hao et al. modified staging system of DFSP

Stage	Criteria
I	Non-protuberant lesions, including atrophic or sclerotic plaque, macula, or small nodules
II	Protuberant primary tumor
IIA	Superficial tumor: without invasion of the underlying fascia
IIB	Deep tumor: infiltrating the fascia or occurring beneath the superficial fascia
III	Lymph node metastasis
IV	Distant metastasis to other organs

Nonetheless, imatinib may still be considered in cases without the specific translocation because there have been reports of response to treatment [30, 31]. Since we have achieved complete disease clearance, the role of imatinib therapy is insignificant in our cases. Because it is a slow-growing tumor, we must wait longer to see if there is a recurrence or distant spread before declaring them disease-free.

Conclusion

Inadequate margins raise the possibility of local recurrence. A “wider margin minimum of 2 cm” can prevent a further recurrence, especially in large-sized tumors; however, this should be performed after considering the available reconstructive options and functional and esthetic aspects.

Author Contribution Listed according to the list mentioned above.

Authors: 1 2 3 4 5 6 7
 Concept: Rajeev Kumar
 Design: Rajeev Kumar
 Definition of intellectual content: Rajeev Kumar, Suresh Mani, Aanchal Kakkar
 Literature Search: Suresh Mani, Dherraj Kondamudi
 Clinical Studies: NA
 Data Acquisition: Rajeev Kumar, Suresh Mani, Dheeraj Kondamudi, Aanchal Kakkar, Adarsh Barwad
 Data Analysis: Rajeev Kumar, Suresh Mani
 Statistical Analysis: NA
 Manuscript Preparation: Suresh Mani, Rajeev Kumar, Aanchal Kakkar, Dheeraj Kondamudi
 Manuscript Editing: Rajeev Kumar, Prem Sagar, Rakesh Kumar
 Manuscript Review: Rajeev Kumar, Prem Sagar, Rakesh Kumar, Aanchal Kakkar, Adarsh Kakkar
 Guarantor: NA

Declarations

Competing Interests The authors declare no competing interests.

References

- Chang CK, Jacobs IA, Salti GI (2004) Outcomes of surgery for dermatofibrosarcoma protuberans. *Eur J Surg Oncol* 30(3):341–345. <https://doi.org/10.1016/j.ejso.2003.12.005>
- Lyu A, Wang Q (2018) Dermatofibrosarcoma protuberans: a clinical analysis. *Oncol Lett* 16(2):1855–1862. <https://doi.org/10.3892/ol.2018.8802>
- DuBay D, Cimmino V, Lowe L, Johnson TM, Sondak VK (2004) Low recurrence rate after surgery for dermatofibrosarcoma protuberans: a multidisciplinary approach from a single institution. *Cancer* 100(5):1008–1016. <https://doi.org/10.1002/ncr.20051>
- Paradisi A, Abeni D, Rusciani A et al (2008) Dermatofibrosarcoma protuberans: wide local excision vs. Mohs micrographic surgery. *Cancer Treat Rev* 34(8):728–736. <https://doi.org/10.1016/j.ctrv.2008.06.002>
- Agyeman MB, Vanderpuye VD, Yarney J (2019) Abscopal effect of radiotherapy in imatinib-resistant dermatofibrosarcoma protuberans. *Cureus*. 11(1):e3857. <https://doi.org/10.7759/cureus.3857>
- Barnes L, Coleman JA, Johnson JT (1984) Dermatofibrosarcoma protuberans of the head and neck. *Arch Otolaryngol* 110(6):398–404. <https://doi.org/10.1001/archotol.1984.00800320052012>
- Mark RJ, Bailet JW, Tran LM, Poen J, Fu YS, Calcaterra TC (1993) Dermatofibrosarcoma protuberans of the head and neck A report of 16 cases. *Arch Otolaryngol Head Neck Surg* 119(8):891–6. <https://doi.org/10.1001/archotol.1993.01880200097014>
- Parker TL, Zitelli JA (1995) Surgical margins for excision of dermatofibrosarcoma protuberans. *J Am Acad Dermatol* 32(2 Pt 1):233–236. [https://doi.org/10.1016/0190-9622\(95\)90132-9](https://doi.org/10.1016/0190-9622(95)90132-9)
- Koh CK, Ko CB, Bury HP, Wyatt EH (1995) Dermatofibrosarcoma protuberans. *Int J Dermatol* 34(4):256–260. <https://doi.org/10.1111/j.1365-4362.1995.tb01591.x>
- Gayner SM, Lewis JE, McCaffrey TV (1997) Effect of resection margins on dermatofibrosarcoma protuberans of the head and neck. *Arch Otolaryngol Head Neck Surg* 123(4):430–433. <https://doi.org/10.1001/archotol.1997.01900040066011>
- Stojadinovic A, Karpoff HM, Antonescu CR et al (2000) Dermatofibrosarcoma protuberans of the head and neck. *Ann Surg Oncol* 7:696–704. <https://doi.org/10.1007/s10434-000-0696-3>
- Barker JL Jr, Paulino AC, Feeney S, McCulloch T, Hoffman H (2003) Locoregional treatment for adult soft tissue sarcomas of the head and neck: an institutional review. *Cancer J*. 9(1):49–57. <https://doi.org/10.1097/00130404-200301000-00009>
- Thiele OC, Seeberger R, Bacon C, Mühling J, Freier K, Hofele C (2009) Recurrent craniofacial dermatofibrosarcoma protuberans: long-term prognosis after close surgical removal. *J Craniofac Surg* 20(3):844–846. <https://doi.org/10.1097/SCS.0b013e3181a2d642>
- González A, Etchichury D, Rivero JM, Adamo L (2021) Treatment of dermatofibrosarcoma of the head and neck with Mohs surgery with paraffin sections. *J Plast Reconstr Aesthet Surg* 74(5):1061–1070. <https://doi.org/10.1016/j.bjps.2020.10.062>
- Criscione VD, Weinstock MA (2007) Descriptive epidemiology of dermatofibrosarcoma protuberance in the United States, 1973 to 2002. *J Am Acad Dermatol* 56:968–973
- Mishra GS, Bhatia A (2007) Dermatofibrosarcoma protuberans: rare cause of head and neck swelling. *Indian J Otolaryngol*

- Head Neck Surg 59(3):296–297. <https://doi.org/10.1007/s12070-007-0086-2>
17. RodriguezBandera AI, MorenoBonilla G, FeitoRodriguez M et al (2019) Jellyfish- like sonographic pattern can help recognition of dermatofibrosarcoma protuberans Report of 3 new cases and review of the literature. *Australas J Dermatol* 60:e148–e150
 18. Klijanienko J, Caillaud JM, Lagacé R (2004) Fine-needle aspiration of primary and recurrent dermatofibrosarcoma protuberans. *Diagn Cytopathol* 30(4):261–265. <https://doi.org/10.1002/dc.20024>
 19. Yong PF, Grosse-Kreul D, Maher J, Salisbury JR, Ibrahim MA (2007) Dermatofibrosarcoma protuberans in a patient with X-linked agammaglobulinaemia. *J Clin Pathol* 60:1162–1164. <https://doi.org/10.1136/jcp.2006.044040>
 20. Saiag P, Grob JJ, Lebbe C, Malvey J, del Marmol V, Pehamberger H, Peris K, Stratigos A, Middelton M, Basholt L, Testori A, Garbe C (2015) Diagnosis, and treatment of dermatofibrosarcoma protuberans. European consensus-based interdisciplinary guideline. *Eur J Cancer* 51(17):2604–8. <https://doi.org/10.1016/j.ejca.2015.06.108>
 21. Hao X, Billings SD, Wu F, Stultz TW, Procop GW, Mirkin G, Vidimos AT (2020) Dermatofibrosarcoma protuberans: update on the diagnosis and treatment. *J Clin Med* 9(6):1752. <https://doi.org/10.3390/jcm9061752>. PMID:32516921;PMCID:PMC7355835
 22. Li Y, Wang C, Xiang B, Chen S, Li L, Ji Y (2017) Clinical features, pathological findings and treatment of recurrent dermatofibrosarcoma protuberans. *J Cancer*. 8(7):1319–1323. <https://doi.org/10.7150/jca.17988>
 23. Snow SN, Gordon EM, Larson PO, Bagheri MM, Bentz ML, Sable DB (2004) Dermatofibrosarcoma protuberans: a report on 29 patients treated by Mohs micrographic surgery with long-term follow-up and review of the literature. *Cancer* 101(1):28–38. <https://doi.org/10.1002/cncr.20316>
 24. Hamid R, Hafeez A, Darzi AM, Zaroo I, Owais H, Akhter A (2013) Dermatofibrosarcoma protuberans: role of wide local excision. *South Asian J Cancer* 2(4):232–238. <https://doi.org/10.4103/2278-330X.119926>
 25. Badeau AM, Granick M, Deleyiannis FW (2013) Considerations for tissue expansion in the management of massive dermatofibrosarcoma protuberans of the head and neck. *Eplasty*. 27(13):e63
 26. Du K, Li J, Tang L et al (2019) role of postoperative radiotherapy in dermatofibrosarcoma protuberans: a propensity score-matched analysis. *Radiat Oncol*. 14(1):20. <https://doi.org/10.1186/s13014-019-1226-z>
 27. Dagan R, Morris CG, Zlotecki RA, Scarborough MT, Mendenhall WM (2005) Radiotherapy in the treatment of dermatofibrosarcoma protuberans. *Am J Clin Oncol* 28(6):537–539. <https://doi.org/10.1097/01.coc.0000171278.69291.64>
 28. National Comprehensive Cancer Network (NCCN) site: NCCN. ORG Sarcoma.pdf. Version 1.2020–October 2, 2019 Cited 2020 Feb 2. Available from: https://www.nccn.org/professionals/physician_gls/pdf/sarcoma.pdf
 29. Navarrete-Dechent C, Mori S, Barker CA, Dickson MA, Nehal KS (2019) Imatinib treatment for locally advanced or metastatic dermatofibrosarcoma protuberans: a systematic review. *JAMA Dermatol* 155(3):361–369. <https://doi.org/10.1001/jamadermatol.2018.4940>
 30. Han A, Chen EH, Niedt G, Sherman W, Ratner D (2009) Neoadjuvant imatinib therapy for dermatofibrosarcoma protuberans. *Arch Dermatol* 145(7):792–796. <https://doi.org/10.1001/archdermatol.2009.140>
 31. Kérob D, Porcher R, Vérola O et al (2010) Imatinib mesylate as a preoperative therapy in dermatofibrosarcoma: results of a multicenter phase II study on 25 patients. *Clin Cancer Res* 16(12):3288–3295. <https://doi.org/10.1158/1078-0432.CCR-09-3401>

Publisher's Note Springer Nature remains neutral with regard to jurisdictional claims in published maps and institutional affiliations.

Springer Nature or its licensor holds exclusive rights to this article under a publishing agreement with the author(s) or other rightsholder(s); author self-archiving of the accepted manuscript version of this article is solely governed by the terms of such publishing agreement and applicable law.