



Outcome of Open Surgery in Disease Progression of Post-COVID Rhinomaxillary Mucormycosis Treated by Functional Endoscopic Sinus Surgery and Proposed Evaluation Scale for Maxillary Sinus Disease and Osteomyelitis

Varsha Sunil Manekar¹ · Abhay N. Datarkar¹ ·
Shramapurna Karemore¹ · Ashlesha Ghormode¹ ·
Archana Deshpande¹ · Damyanti Walke¹

Received: 5 November 2021 / Accepted: 18 September 2022 / Published online: 6 October 2022
© The Association of Oral and Maxillofacial Surgeons of India 2022

Abstract

Introduction Rhinomaxillary Mucormycosis (RMM) is a condition peculiarly seen as post-COVID-19 opportunistic infections with Maxillary Sinus Disease and Osteomyelitis (MSDO). The open method of debridement and closed method are two types of surgical modalities available. There is no scoring method for this infection in maxilla. This paper aims to study the clinical and CT-based outcome of open versus closed surgery of MSDO in post-COVID-19 RMM and propose a new scoring method to evaluate the disease severity, progression as well as recovery.

Material and Methods Symptomatic cases of RMM ($n = 17$) with a history of closed surgical treatment were enrolled for this prospective clinical study. These cases were then treated by medicinal and open surgical method. The

clinical and CT scan outcomes were compared by proposed new scoring method.

The CT-based score for Maxillary Sinus Disease (MSD) and Maxillary Osteomyelitis (MO) from pre-FESS (CT1), Post-FESS (Preoperative, CT2), and Post-operative (CT3) were compared for both right and left sides. One-way ANOVA test and post HOC tests were used for statistical evaluation.

Conclusion The open method of maxillary sinus surgery has given significant improvement in the treatment of RMM already treated by a closed endoscopic approach.

Keywords Endoscopic surgery · FESS · Caldwell–Luc · Rhinomaxillary mucormycosis · Osteomyelitis · Bone necrosis · Sinus disease

Abbreviations

FESS	Functional Endoscopic Sinus Surgery
MSD	Maxillary Sinus Disease and MO-Maxillary Osteomyelitis
RMM	Rhinomaxillary Mucormycosis
MSDO	Maxillary Sinus Disease and Osteomyelitis
CT	Computer Tomography
CT1	CT scan before Functional Endoscopic Sinus Surgery
CT2	CT scan after Functional Endoscopic Sinus Surgery, and before open surgery
CT3	CT scan after open surgery

Supplementary Information The online version contains supplementary material available at <https://doi.org/10.1007/s12663-022-01803-5>.

✉ Varsha Sunil Manekar
varsha_manekar@yahoo.co.in

Abhay N. Datarkar
abhaydatarkar@yahoo.com

Shramapurna Karemore
shrama075@gmail.com

Ashlesha Ghormode
ashlesha.ghormode@gmail.com

Archana Deshpande
deshpande.archana111@gmail.com

Damyanti Walke
wadamyanti17@gmail.com

¹ Oral & Maxillofacial Surgery, Government Dental College & Hospital, Nagpur, Maharashtra 444003, India

Introduction and Rationale

COVID-19 pandemic due to Novel coronavirus has affected the health system badly. Now one and half years in this pandemic post-COVID effect has created a major health care system challenge. Mucormycosis previously called

Zygomycosis of paranasal sinuses is one such big challenge. Zygomycosis was first described by Platauf in 1885 in his paper titled “Mycosis Mucorina”. It was not a commonly occurring fungal infection in India. The causative fungi of Mucormycosis belong to the Family Mucoraceae [1]. The risk factors are immunocompromised individuals with uncontrolled diabetes mellitus, acquired immunodeficiency syndrome, iatrogenic immunosuppression and haematological malignancies, and those who have undergone organ transplantation [1].

Rhinomaxillary Mucormycosis (RMM) was a condition peculiarly seen as post-COVID-19 opportunistic infections with Maxillary Sinus Disease and Osteomyelitis (MSDO). The fungal spores reach the nasal cavity by inhalation, get inoculated and germinate into hyphae [1]. The spread occurs from the nose to the sinus and to the maxillary bone, hard palate with the necrosis of hard and soft tissues caused by angioinvasion [2]. Other paranasal sinuses, the orbit, and intracranial spread can occur in severe cases. RMM is treated by combined therapy medicine and surgery. Amphotericin B is a universally accepted drug.

The surgical treatment has a major role in removing the necrosed hard and soft tissue harbouring the fungi. The open method of debridement (through Caldwell–Luc approach) and closed method by Functional Endoscopy Sinus Surgery (FESS) are two types of surgical modalities available. The limitation of the endoscopic approach with disease remaining in sinus especially in floor of sinus and apex region towards the body of zygoma resulting in disease progression has been discussed in the literature for chronic sinusitis [3–5].

There are very few scales available for disease-invading paranasal sinuses to evaluate the disease severity, progression as well as recovery. Not a single scale system has mentioned the involvement of maxillary bone osteomyelitis. The aim of this paper is to study outcome of open surgery in MSDO progressed after Functional Endoscopic Sinus Surgery in post-COVID-19 RMM and propose a new evaluation scale.

Material and Method

From the prospective cohort of 120 cases of post-COVID-19 RMM, a total of seventeen symptomatic cases with a history of FESS performed by otolaryngologist at other centres were enrolled for this prospective clinical study. The sampling method was ‘Convenience sampling’ from the OPD of our department. The approval from an institutional ethics committee was received before the start of the study and the consent from all participant patients was taken.

The inclusion criteria were (1) Symptomatic Cases of post-COVID-19 RMM (unilateral or bilateral), with history of FESS for debridement.; (2) These cases may or may not have other paranasal sinus disease, (3) Stage one disease involving only nose and sinuses and not involving orbit or intracranial extension. The exclusion criteria were any other post-covid complications; disease other than paranasal sinus mucormycosis, diagnostic FESS. The included cases had history of hospitalisation for COVID-19 and use of steroid drug.

The diagnosis RMM was established from signs and symptoms and KOH mount showing the presence of multiple aseptate hyphae suggestive of mucor species from the intraoral mucosal discharging sinuses. The common treatment protocol was medicinal therapy and an open surgical approach for debridement of the maxillary sinus (Caldwell–Luc approach) with nasal antrostomy, unilateral or bilateral maxillectomy, sequestrectomy, and turbinectomy as per the case supportive therapy.

For open surgical procedure, intraoral maxillary crevicular incision or Weber Fergusson incision was used. Debridement, sequestrectomy, partial or complete maxillectomy, turbinectomy, and complete removal of the sinus lining through the bony window were performed depending on the level of MSDO. Figure 1 is the CT1 coronal section showing obliteration of the right sphenoid, ethmoid and maxillary sinuses. Figure 2 is the CT2 coronal section of the same case showing the mucosal thickening in the right maxillary sinus and osteolytic changes in the right maxilla. The patient underwent right maxillectomy, turbinectomy, and open maxillary sinus debridement. Figure 3 (CT3 coronal section) shows the fifteen days post-operative coronal section showing loss of right maxilla and disease-free right maxillary sinus (P 12 case). The medicinal therapy in a hospital set-up included dual antifungal drug therapy Inj Amphotericin B (IV, 0.3–0.7 mg/kg/day) and oral Posaconazole (300 mg) and all patients were evaluated fifteen days after the open surgery clinically and with CT scan (CT3). They were closely observed for recovery from infection. We propose a CT-based evaluation scale to

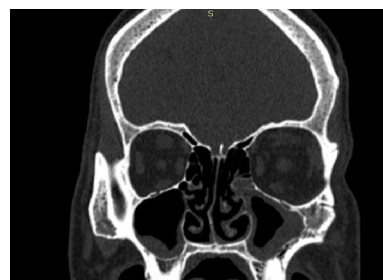

Fig. 1 Coronal section of CT1 of P12 (Patient code) showing paranasal sinus obliteration

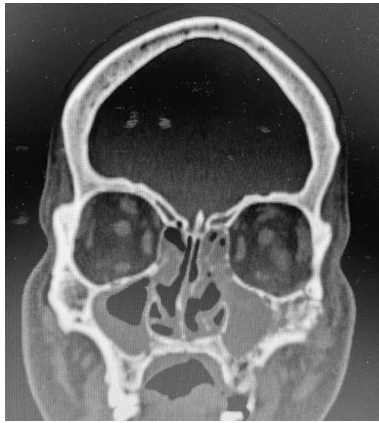

Fig. 2 Coronal section of CT2 of P12 showing the maxillary sinus thickening indicating the presence of disease

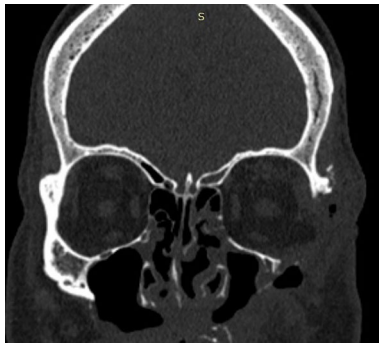


Fig. 3 Coronal section CT3 of P12 showing absence of maxilla and disease-free maxillary sinus

evaluate the disease severity, progression as well as recovery for MSDO (Table 1). The scores as per Table 1 were compared at three levels: CT1- Before Functional Endoscopic Sinus Surgery; CT2- After Functional Endoscopic Sinus Surgery, and before open surgery. CT3- After open surgery.

Table 1 CT scan-based proposed scoring system for Maxillary Sinus Disease and osteomyelitis (MSDO) for each right and left side separately

MSD grading			MO grading		
Sr No	CT findings	NO-0; YES-1	Sr No	CT findings	NO-0; YES-1
1	MT anterolateral wall	0/1	9	BE anterolateral	0/1
2	MT posterolateral wall	0/1	10	BE posterolateral	0/1
3	MT medial wall	0/1	11	BE roof	0/1
4	MT roof	0/1	12	BE nasal septum/turbinate	0/1
5	MT floor	0/1	13	BE hard palate	0/1
6	MT apex	0/1	14	BE alveolar process	0/1
7	Obliteration of sinus	0/1	15	BE pterygoid plates	0/1
8	Osteo-meatal obliteration	0/1	16	BE zygomatic bone	0/1

Total score for severity of MSD or MO disease: 0–2 = MILD, 3–5 = Moderate, 6–8 = Severe

MSD Maxillary Sinus Disease; MO Maxillary Osteomyelitis MT Mucosal Thickening; BE Bony Erosion

Observations and Results

All patients had history of COVID 19. The mean age of patients was 49.1 years, eleven male and six female patients. The clinical presentation was extraoral swelling, intraoral abscesses, discharging sinuses, numbness, blockade of the nose, pain, teeth mobility, ulcer, or perforation of the palate. The mean duration of reporting to our OPD after FESS was 10.3 Days. Comorbidities included long history of Diabetes (five), recently diagnosed Diabetes (seven), Chronic Obstructive Pulmonary Disease, (COPD) (three), Hypertension (seven). The clinical presentation was as per Table 2.

Clinically patients were closely observed for recovery from infection for swelling, pus discharge, the occurrence of a new abscess. All the patients recovered slowly and were disease-free at the time of discharge. Table 2 shows the clinical outcome by comparison of signs and symptoms of number of cases of Rhinomaxillary Mucormycosis (RMM) ($n = 17$) before and after open surgery. This could not be analysed statistically. There was zero per cent mortality. The mean duration of post-recovery was 8 weeks. All patients had uneventful healing. Minor complications were seen such as repeated gapping of the wound, extension of disease to the opposite side. The mean follow-up duration was ten months. The fifteen cases (88%) fully recovered and rehabilitated. One patient died (Other reason); one cases lost to follow-up and in two cases recurrence and extension of infection occurred which was treated at other centre.

The CT scan observations as per proposed evaluation scale (Table 1), for three time intervals, were analysed statistically. CT1, CT2 and CT3 were analysed for mild, moderate, and severe disease. Table 3 shows disease severity of both sides for MSDO. The score for MSD and MO of right and left maxilla from CT1, CT2 and CT3 was compared. One-way ANOVA test and post HOC tests were used for statistical evaluation. The p -value for mean of scores of three groups (CT1, CT2, and CT3) by one-way ANOVA test was statistically significant (Table 4) for all

Table 2 Comparison of signs and symptoms of number of cases of Rhinomaxillary Mucormycosis (RMM) (n = 17) before and after open surgery

Sr no	Clinical presentation	Preoperative	Post-operative
1	Extraoral swelling	18	12
2	Pain	16	14
3	Teeth mobility	14	0
4	Intraoral fistulas	14	0
5	Intraoral abscesses	14	0
6	Palatal perforation	10	0
7	Numbness	7	7

Preoperative—before open surgery; Post-operative—three months after open surgery

Table 3 Comparison of disease severity of MSDO according to Proposed scoring method (Table 1) of both sides (n = 34) of maxillary sinuses and maxilla in CT1 and CT2

Severity of disease	MSD		MO	
	CT1	CT2	CT1	CT2
	Mild	0	0	34
Moderate	34	29	0	10
Severe	0	5	0	5

MSD Maxillary Sinus Disease; MO Maxillary Osteomyelitis; LT left side; RT right side; CT1 CT scan before Functional Endoscopic Sinus Surgery; CT2 CT scan after Functional Endoscopic Sinus Surgery, and before open surgery; CT3 CT scan after open surgery

four scoring sets namely MSD and MO of the right and left sides. This indicates that the all three sets of CT scan scores have variation. To compare the individual mean scores, post HOC test was used. Comparison of CT1 and CT2 mean scores of MO of both sides are less than 0.001, thus statistically significant. This indicates disease progression in maxillary bone. The comparison of CT2 and CT3 was less than 0.001 for MSD and MO of both sides, thus statistically significant for all four sets. This shows

there was significant improvement after the open surgical intervention for both MSD and MO.

Comparison between CT1 and CT3 scores of MSD was less than 0.001 which is statistically significant, indicates disease improvement. Comparison of CT1 and CT3 scores of MO of both sides is statistically NOT significant. This indicates the disease progressed after treatment by the FESS, closed method of surgery. MO was not present in pre-FESS CT.

Discussion

In this prospective clinical study, the cases (n = 17) were studied for the MSDO in Post-COVID mucormycosis clinically and from CT scans. There was a clinical improvement of clinical symptoms, all cases recovered clinically from symptoms of mucor infection in the maxillary sinus and bone. The CT-based comparison of pre-FESS, post-FESS shows the disease progression in maxillary bone and sinus. Similarly, CT comparison of post-FESS (CT2) and post-operative shows improvement in disease of maxillary sinus and bone in the given sample. This has proved statistically that the open method of debridement and removal of involved maxillary bone has given significant improvement clinically and on CT scans.

Histopathology, after open surgery showed fungal hyphae—broad, ribbon-like, irregular, and aseptate with branching at a right angle with haematoxylin and Eosin stain. This confirmed the progression of disease in the maxilla after closed endoscopic surgery. Epithelium, necrotic material, sequestrum, necrosed bone, inflammatory cells were seen in the section.

FESS replaced open surgical technique as the gold standard for the treatment of Chronic Maxillary Sinus diseases on account of its minimally invasive nature and physiological approach [6]. FESS is a conservative type surgery. The limitation of FESS in the management of MSD has been discussed in few articles. Despite many advances in endoscopic equipment and techniques. Richtsmeier WJ (2001) [7] have

Table 4 Comparison of mean of CT scan scores (n = 17) for maxillary sinus disease (MSD) and Maxillary osteomyelitis (MO) at three time intervals of the each patient by one-way ANOVA test and by Post hoc test

Sr no	Name of disease	Mean and SD score of CT scan			Comparison of CT1,CT2, CT3 by ANOVA test	Comparison by post HOC test		
		CT1	CT2	CT3		CT1 & CT2	CT1 & CT3	CT2 & CT3
1	MSD (RT)	4.3 ± 0.7	4.8 ± 0.8	0.7 ± 0.5	<0.001	>0.001	<0.001	<0.001
2	MSD (LT)	4.1 ± 0.6	4.9 ± 0.7	0.5 ± 0.6	<0.001	>0.001	<0.001	<0.001
3	MO (RT)	0	2.3 ± 1.7	0.6 ± 0.6	<0.001	<0.001	>0.001	<0.001
4	MO (LT)	0	3.3 ± 2.2	0.5 ± 0.5	<0.001	<0.001	>0.001	<0.001

MSD Maxillary Sinus Disease; MO Maxillary Osteomyelitis; LT left side; RT right side; CT1 CT scan before Functional Endoscopic Sinus Surgery; CT2 CT scan after Functional Endoscopic Sinus Surgery, and before open surgery. CT3 CT scan after open surgery

mentioned many indications for the Caldwell–Luc procedure, like removal of foreign bodies impacted in regions not visible or accessible with endoscopic instruments, removal of benign tumours, management of MO or osteoradionecrosis, exposure for orbital decompression, access to the pterygomaxillary space, repair of an oroantral fistula, and endoscopic surgical failures.

Forsgren K [8] in his study on rabbits mentioned that the Caldwell–Luc operation is still the mainstay of surgical treatment of maxillary sinus disease. Similar results were observed in the present study.

Chong et al. [9] in their article on FESS emphasized on ostiomeatal unit (OMU). FESS is based on the theory that the OMU is the key in the pathogenesis of chronic sinusitis. FESS aims to re-establish normal ventilation and sinus drainage. Advantages of FESS can be utilized if open and close methods can be done together. Whereas for drainage purpose nasal antrostomy is carried out in the inferior concha in open sinus surgery.

Singh et al. [10] mentioned that surgical debridement is very important for complete control of mucormycosis because antifungal agents cannot reach the involved site due to the blood vessel thrombosis. The diagnostic nasal endoscopy finding of white discoloration indicates tissue ischaemia which is secondary to angiocentric invasion. Spellberg B et al. [11] mentioned the common sites for mucormycosis, includes middle turbinate (67%), septum (24%), palate (19%), and inferior turbinate (10%). The change in the normal appearance of the nasal and the black necrotic eschar tissue with underlying purulent exudates with an unpleasant odour is the most consistent finding [12]. The pterygopalatine fossa acts as a reservoir for fungal disease. This area can only be approached by FESS [10].

In our cohort of seventeen patients with Rhinomaxillary Mucormycosis, FESS was not effective in control of disease, rather the disease increased and spread occurred after FESS. Whereas, this is the first study in post-COVID-19 maxillary mucormycosis establishing the importance of the open surgical method of Caldwell–Luc approach in maxillary sinus disease. Some studies have mentioned the limitations of FESS and the need for open surgery of Caldwell–Luc approach. FESS is essential for other paranasal sinus diseases. Hence, we recommend the use of open surgery if MSD due to mucormycosis is present in isolation. In cases of mucormycosis of other paranasal sinuses, the combined surgery of open method for maxillary sinus and FESS for other sinuses gives better clinical outcome and cure of mucor infection.

Contrast Paranasal CT scan is the main investigation which is for documentation of the presence of disease and demonstration of the exact spread and extent of the disease, especially for surgical management. Also, for demonstration of anatomical variations which consequently prevents

surgical complications and aids in monitoring of disease and treatment [10].

Albu S et al. [13] mentioned that the extent of disease before surgery, as determined by CT scan, has a high correlation with FESS failure. The high level of severity of the disease of rhinomaxillary mucormycosis may be the reason for the progression of the disease after FESS surgery. This finding was correlating with our finding in this study.

Kende et al. [14] assessed the feasibility and limitations of functional endoscopic sinus surgery in combination with an intraoral open approach for the treatment of Chronic Maxillary Sinusitis of Dental Origin (CMSDO). They concluded that FESS with Caldwell–Luc approach should be considered as a part of the treatment of CMSDO for stable long-term results and minimal complications. We recommend use of open surgical approach for control of disease progression leading to osteomyelitis of maxilla.

In a case series (Six cases) of oro-nasal- paranasal sinuses mucormycosis reported that three cases responded to FESS with complete recovery. One case was treated with open debridement. IN FESS cases post-operatively nasal and antral douching with Amphotericin B was started with Oral Posaconazole. [Saidha et al.] [15]

In a retrospective study of thirty cases of Rhino-Orbito-Cerebral Mucormycosis, as a part of surgical intervention, Endoscopic Sinus Surgery (ESS) was done in twenty-seven patients; infrastructure maxillectomy [16] was done in two patients and subtotal maxillectomy for one patient. All patients responded to the timely diagnosis and debridement with the initiation of systemic amphotericin B. [17]

Yeo et al. reported a case of Rhinocerebral mucormycosis after functional endoscopic sinus surgery for chronic rhinosinusitis with nasal polyps by endoscopic sinus surgery within four weeks. While in hospital, endoscopic debridement of the necrotic tissue and middle turbinectomy were performed. They discussed the unique point of this case that mucormycosis occurred after FESS. It is common to use antibiotics after FESS and oral or topical steroids may be used to reduce oedema intermittently. The main reason for the mucormycotic infection after FESS may have been the use of steroids or antibiotics after surgery which is a routine practice. [18]

Yadav et al. in the review article mentioned various surgical modalities for Rhino-orbital-cerebral mucormycosis. The endoscopic methods include Inferior turbinectomy, FESS (Functional endoscopic sinus surgery), Endoscopic decker's approach, Mega-antrostomy, medial maxillectomy, Canine fossa puncture (CFP) technique. Open surgeries included Caldwell–Luc Operation, Nasomaxillary frame translocation in medial maxillectomy, Lateral rhinotomy, Weber Fergusson approach, Midfacial degloving approach. We used the open surgical approach [19]. Whereas, the endoscopic approach is an important and most commonly used surgical

modality for all paranasal sinuses, our experience of the reported cases of recurrence of fungal infection indicates a word of caution. Thorough presurgical planning and use of combined open and close method approach may give a better result in aggressive fungal infections like mucormycosis.

MRI is the best imaging but its availability limits its use. We searched in literature for the CT-based evaluation scale for MSD. Lund-Mackay staging system is the most commonly used evaluation scale for paranasal sinuses. It has a limitation of scoring Maxillary sinus involvement as one unit. The disease in the maxillary sinus here is not scored in detail [20].

There is no CT-based grading system for maxillary osteomyelitis. Hence, we propose new evaluation scale for maxillary sinus disease and osteomyelitis. This proposed scale was used for the evaluation of the outcome of this study. The scoring here is a guide in deciding severity of disease, disease progression, planning the treatment of MSDO and outcome of surgery in post-operative phase after open surgical approach for management of MSDO.

Conclusion

The open surgical debridement can give better results in case of Rhinomaxillary mucormycosis. The new scoring system is very useful in assessment for maxillary sinus disease and osteomyelitis. There is a need to study this outcome in a better study design.

The authors do not have any conflict of interest.

All patient participants consented and ethical approval from the institutional ethics committee was received.

References

- Ananthaneni AR, Undavalli SB, Velagapudi RP, Guduru VS (2013) Mucormycosis: an atrocious mate of patients with diabetes. *BMJ Case Rep*. <https://doi.org/10.1136/bcr-2013-009600>
- Shi BY, Lan L, Guo H et al (2004) Concomitant diabetic ketoacidosis and rhinocerebral mucormycosis: report of a case. *Chin Med J (Engl)* 117:1113–1115
- DeShazo RD (1998) Fungal sinusitis. *Am J Med Sci* 316:39–44
- Närkiö-mäkelä M, Qvarnberg Y (1997) Endoscopic sinus surgery or Caldwell-Luc operation in the treatment of chronic and recurrent maxillary sinusitis. *Acta Otolaryngol* 117(sup529):177–180. <https://doi.org/10.3109/00016489709124115>
- Hajjioannou J, Exarchos S, Lachanas V, Bizakis J (2016) In the era of endoscopic sinus surgery, is there still a place for the Caldwell-Luc procedure? *B Ent* 12(2):99–102 (PMID: 29553613)
- Stammler PW (1990) Functional endoscopic sinus surgery: concept, indications and results of the Messerklinger technique. *Eur Arch Otorhinolaryngol* 247(2):63–76
- Richtsmeier WJ (2001) Top 10 reasons for endoscopic maxillary sinus surgery failure. *Laryngoscope* 111(11 Pt 1):1952–1956
- Forsgren K, Stiernä P, Kumlien J, Carlsoo B (1993) Regeneration of maxillary sinus mucosa following surgical removal: experimental study in rabbits. *Ann Otol Rhinol Laryngol* 102(6):459–466
- Chong VFH, Fan YF, Lau D, Sethi DS (1998) Functional endoscopic sinus surgery (FESS): what radiologists need to know. *Clin Radiol* 53:650–658
- Singh VP et al (2019) Sinonasal mucormycosis: A to Z. *Indian J Otolaryngol Head Neck Surg* 71(Suppl 3):S1962–S1971
- Spellberg B, Edwards J, Ibrahim A (2005) Novel perspectives on mucormycosis: pathophysiology, presentation, and management. *Clin Microbiol Rev* 18(3):556–569
- Lunge SB, Sajjan V, Pandit AM, Patil VB (2015) Rhinocerebrocutaneous mucormycosis caused by *Mucor* species: a rare causation. *Indian Dermatol Online J* 6(3):189–192
- Albu S, Baciut M (2010) Failures in endoscopic surgery of the maxillary sinus. *Otolaryngol Head Neck Surg Official J Am Acad Otolaryngol Head Neck Surg* 142(2):196–201. <https://doi.org/10.1016/j.otohns.2009.10.038>
- Kende P, Mathai PC, Landge J, Aggarwal N, Ghodke M, Chellappa N, Meshram V (2019) Combined endoscopic and intraoral approach for chronic maxillary sinusitis of dental origin—a prospective clinical study. *Oral Maxillofac Surg*, 23(4):429–437. <https://doi.org/10.1007/s10006-019-00792-z>. Epub 2019 Jul 22. PMID: 31332583
- Saidha PK, Kapoor S, Das P, Gupta A, Kakkar V, Kumar A, Arya V (2021) Mucormycosis of paranasal sinuses of odontogenic origin post COVID-19 infection: a case series. *Indian J Otolaryngology Head Neck Surg* 17:1–5
- Lee DH, Lim HR, Lee JK, Lim SC (2021) Infrastructure maxillectomy for maxillary sinus and hard palate neoplasms. *Mol Clin Oncol*, 15(3):180. <https://doi.org/10.3892/mco.2021.2342>. Epub 2021 Jul 1. PMID: 34276999; PMCID: PMC8278379
- SiluvaiArulappan LA (2021) Incidence of Mucormycosis in a tertiary care hospital during Covid first wave—a retrospective study. *Indian J Otolaryngology Head Neck Surg* 4:1–6
- Yeo CD, Kim JS, Kwon SH, Lee EJ, Lee MH, Kim SG, You YS, Kim JS, Lee JH, Ryu JS (2018) Rhinocerebral mucormycosis after functional endoscopic sinus surgery: a case report. *Medicine* 97(51):e13290
- Yadav RR, Singh V, Siva S, Kumar R, Chaudhary AK, Saini R, Yadav S, Silky S, Gupta DK, Goyal A, Panday A (2022) Surgical approaches in Rhino-orbito-cerebral Mucormycosis. *NMO Journal* (……) [Internet]. 2022Feb.25 [cited 2022Mar.6] 16(1):31–9
- Lund VJ, Mackay IS (1993) Staging in rhinosinusitis. *Rhinology* 31:183–184

Publisher's Note Springer Nature remains neutral with regard to jurisdictional claims in published maps and institutional affiliations.

Springer Nature or its licensor holds exclusive rights to this article under a publishing agreement with the author(s) or other rightsholder(s); author self-archiving of the accepted manuscript version of this article is solely governed by the terms of such publishing agreement and applicable law.