



## The catheter-over-needle assembly facilitates delivery of a second local anesthetic bolus to prolong supraclavicular brachial plexus block without time-consuming catheterization steps: a randomized controlled study

### L'assemblage cathéter sur aiguille facilite l'administration d'un deuxième bolus d'anesthésique local pour prolonger la durée du bloc supraclaviculaire du plexus brachial sans longues étapes de cathétérisation: une étude randomisée contrôlée

Vivian H. Y. Ip, MBChB · Ban C. H. Tsui, MD

Received: 5 December 2012 / Accepted: 16 April 2013 / Published online: 1 May 2013  
© Canadian Anesthesiologists' Society 2013

#### Abstract

**Background** Single-shot delivery of a supraclavicular brachial plexus block is effective for providing outpatient surgical anesthesia; however, patients generally must use oral analgesics to control pain shortly after discharge from the hospital. Catheterized delivery of supraclavicular blocks can be challenging to perform. We aimed to show that administering a second postoperative bolus of local anesthetic through a catheter placed by a catheter-over-needle assembly not only avoids time-consuming steps but also provides an extended analgesic effect compared with the traditional single-shot approach.

**Methods** Patients were randomized into two groups: one group received a single-shot supraclavicular block with 25–30 mL of local anesthetic (1.5% lidocaine and 0.125% bupivacaine mixture), while the other group received a supraclavicular block via a catheter-over-needle assembly with the same volume and concentration of local anesthetic

as for the single-shot block, which was followed by a second bolus of analgesic solution (0.2 % ropivacaine 20 mL) administered postoperatively through the catheter before its removal. The duration between the initial bolus and onset of pain was measured as well as the duration of pain relief from the last bolus.

**Results** Thirty patients were enrolled and randomized into the single-shot supraclavicular block group ( $n = 15$ ) and the catheter-over-needle group ( $n = 15$ ). One patient withdrew from the study, and five patients were lost to follow-up. We observed no significant difference between the two groups in time to perform the blocks. The mean (standard deviation [SD]) times were 3.1 (1.9) min and 4.4 (2.7) min for the top-up group and single-shot group, respectively (single-shot took 1.3 min longer than the catheter-over-needle group; 95% confidence interval [CI]:  $-0.65$  to  $3.25$ ;  $P = 0.17$ ). The mean (SD) duration of analgesia, measured from the beginning of the local anesthetic bolus to the onset of pain requiring rescue analgesia was 617.5 (288) min in the catheter-over-needle group and 377.2 (161.3) min in the single-shot control group (difference = 240.3 min; 95% CI: 46.8 to 433.8;  $P = 0.03$ ).

**Conclusions** Using the catheter-over-needle assembly for supraclavicular brachial plexus block facilitated effective delivery of a supplementary bolus of local anesthetic without extending the time to perform the block or increasing the number of steps. It also prolonged analgesia significantly compared with the single-shot approach. This trial was registered at: [ClinicalTrials.gov](http://ClinicalTrials.gov), ID: NCT01522066.

**Author contributions** Vivian Ip and Ban Tsui made substantial contributions to study conception and design, acquisition of data, analysis and interpretation of data, drafting the article, and revising the article critically for important intellectual content.

V. H. Y. Ip, MBChB · B. C. H. Tsui, MD (✉)  
Department of Anesthesiology and Pain Medicine, University of Alberta, 8-120 Clinical Sciences Building, Edmonton, AB T6G 2G3, Canada  
e-mail: btsui@ualberta.ca

## Résumé

**Contexte** L'administration par injection unique d'un bloc supraclaviculaire du plexus brachial est efficace pour l'anesthésie chirurgicale ambulatoire; toutefois, les patients doivent en général utiliser des analgésiques oraux pour contrôler la douleur peu après le congé de l'hôpital. L'administration par cathéter des blocs supraclaviculaires peut être difficile à réaliser. Notre objectif était de montrer que l'administration d'un deuxième bolus d'anesthésique local en postopératoire via un cathéter placé grâce à un dispositif de cathéter sur aiguille permet non seulement d'éviter des étapes qui prennent du temps, mais fournit également un effet analgésique accru comparativement à l'approche conventionnelle d'injection unique.

**Méthode** Les patients ont été randomisés en deux groupes: le premier groupe a reçu un bloc supraclaviculaire en injection unique avec 25-30 mL d'anesthésique local (mélange de lidocaïne 1,5 % et de bupivacaïne 0,125 %), alors que le second groupe a reçu un bloc supraclaviculaire administré via un cathéter sur aiguille avec le même volume et la même concentration d'anesthésique local que pour le bloc en injection unique, suivi par un deuxième bolus de solution analgésique (20 mL de ropivacaïne 0,2 %) administré en postopératoire via le cathéter avant son retrait. Le temps entre l'administration du bolus initial et l'apparition de la douleur a été mesuré, tout comme la durée de soulagement de la douleur depuis l'administration du dernier bolus.

**Résultats** Trente patients ont participé à l'étude et ont été randomisés dans les groupes bloc supraclaviculaire en injection unique ( $n = 15$ ) et cathéter sur aiguille ( $n = 15$ ). Un patient s'est retiré de l'étude, et le suivi n'a pu être fait auprès de cinq patients. Nous n'avons observé aucune différence significative entre les deux groupes quant au temps nécessaire à réaliser le bloc. Les temps moyens (écart type [ET]) étaient de 3,1 (1,9) min et 4,4 (2,7) min pour le groupe avec bolus supplémentaire et le groupe en injection unique, respectivement (l'injection unique a pris 1,3 min de plus que le groupe cathéter sur aiguille; intervalle de confiance [IC] 95 %:  $-0,65$  à  $3,25$ ;  $P = 0,17$ ). La durée moyenne (ET) de l'analgésie, mesurée du début du bolus d'anesthésique local jusqu'à l'apparition de douleur nécessitant une analgésie de secours, était de 617,5 (288) min dans le groupe cathéter sur aiguille et de 377,2 (161,3) min dans le groupe témoin avec injection unique (différence = 240,3 min; IC 95 %:  $46,8$  à  $433,8$ ;  $P = 0,03$ ).

**Conclusion** L'utilisation du dispositif cathéter sur aiguille pour la réalisation d'un bloc supraclaviculaire du plexus brachial a facilité l'administration efficace d'un bolus supplémentaire d'anesthésique local sans prolonger le temps nécessaire à réaliser le bloc ni augmenter le nombre d'étapes. Cette méthode a également significativement prolongé

*l'analgésie par rapport à une approche avec une injection unique. Cette étude a été enregistrée au: ClinicalTrials.gov, ID: NCT01522066.*

Supraclavicular brachial plexus block is the standard of care at our institution to provide rapid effective surgical anesthesia for upper extremity surgery. In the past, the block was associated with a risk of pneumothorax;<sup>1</sup> however, the recent introduction of ultrasound guidance allows the block to be performed relatively safely and reliably.<sup>2,3</sup> Current evidence for supraclavicular blocks has been based largely on studies of single-shot techniques with limited literature focusing on the continuous approach.<sup>4,5</sup> One negative aspect that hinders the single-shot technique is the limited duration of action of the local anesthetic. Although several studies have described prolonging the block with adjuvants, such as dexmedetomidine, clonidine, and epinephrine,<sup>6,7</sup> limited data exist on the safety profile of placing these adjuvants adjacent to the neural tissues. Consequently, patients who have been discharged after undergoing a single-shot supraclavicular block during a procedure may experience postoperative pain shortly after arriving home from the hospital, or even in transit.

We hypothesized that the supraclavicular block could be prolonged by delivering a second dose of local anesthetic close to the time that the patient is discharged from the hospital. Potentially, this could be facilitated by placement of a catheter-over-needle assembly, which eliminates the need for multiple cumbersome catheterization steps and has a simple insertion method comparable with that of the single-shot technique.<sup>8,9</sup> The aim of this randomized study was to evaluate the effectiveness of delivering a second bolus of local anesthetic via a catheter-over-needle perineural catheter to prolong a supraclavicular block. A secondary aim was to assess the feasibility and ease of using a catheter-over-needle assembly to facilitate delivery of the postoperative bolus without prolonging the time required to perform the block.

## Methods

Institutional ethics approval was acquired January 2012, and following written informed consent, adult American Society of Anesthesiologists' (ASA) class I-II patients presenting for hand trauma surgery of the distal arm, forearm, or hand were enrolled in the study. Exclusion criteria included patient refusal or inability to consent, allergy to local anesthetics, or infection at the catheter insertion site.

Patients were assigned to the control or study group by manually randomized sealed opaque envelopes each containing a slip of paper with the study group's name written on it. A member of the study team not involved in the trial generated 30 slips of paper (15 for each group). The slips were sealed in opaque envelopes, shuffled, and sequentially numbered; the departmental research coordinator held the envelopes. Since the patients were scheduled for ambulatory procedures, they were enrolled on the day surgery ward on the morning of surgery, usually two to three hours prior to the procedure. When the patient presented to the operating room, the attending anesthesiologist contacted the research coordinator who then opened the next envelope in the sequence to determine the treatment allocation. Patients randomized to the control group received a standard single-shot supraclavicular block, while patients in the study group were fitted with a perineural catheter through which surgical anesthesia was provided prior to surgery, and a second bolus of local anesthetic was provided after the patient returned to the postanesthesia care unit (PARR).

All patients were positioned supine with intravenous access *in situ*, and light sedation (midazolam 0.5-2 mg) was administered as required prior to the block. All patients were fitted with standard monitoring (pulse oximetry, noninvasive blood pressure measurement, and electrocardiograph) and oxygen (2-4 L given via nasal cannula). All blocks were performed by staff regional anesthesiologists or by regional anesthesia fellows/residents with supervision by a staff regional anesthesiologist.

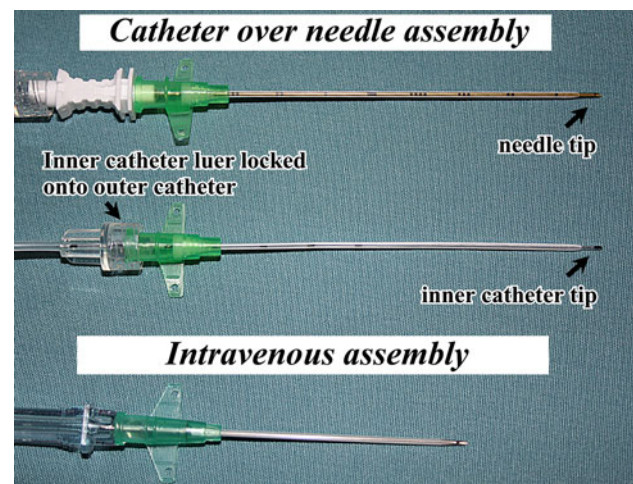
#### Single-shot supraclavicular block

After the area was cleaned with 2% chlorhexidine gluconate and 70% isopropyl alcohol (Solu-I.V. MAXI Swabstick™; Solumed, Laval, QC, Canada), ultrasound was performed using a 13-6 MHz high frequency linear probe (HFL 38, M-Turbo; SonoSite, Bothell, WA, USA) to identify the subclavian artery in a transverse cross-sectional (short-axis) view above the first rib with the pleura deep on the medial side. Nerve stimulation set at 0.2 mA with a pulse width of 0.1 msec (2 Hz) was used to monitor needle placement and warn of possible intraneural injection. After a local anesthetic wheal was raised, a 50-mm 22G Sonoplex needle (Pajunk, Geisingen, Germany) was inserted in-plane just lateral to the subclavian artery and above the first rib. Once the needle-tip position was confirmed by visualizing the spread of 3 mL of dextrose 5% in water (D5W) and no motor response was observed from low current stimulation (0.2 mA), 25-30 mL of local anesthetic (1.5% lidocaine and 0.125% bupivacaine mixture) was injected via the needle.

#### Supraclavicular perineural catheter using catheter-over-needle design

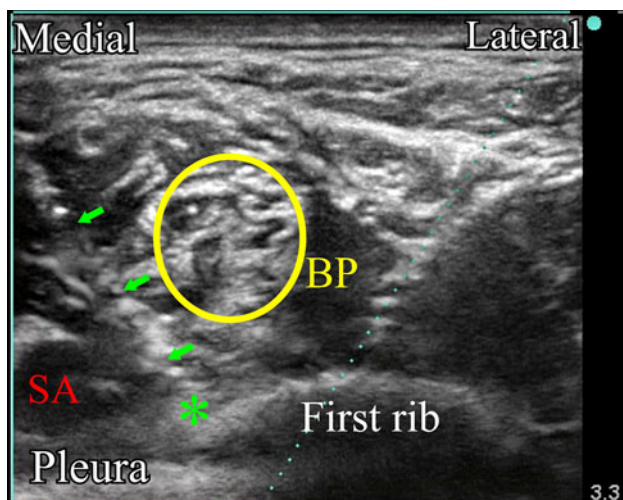
After the area was cleaned with 2% chlorhexidine gluconate and 70% isopropyl alcohol, ultrasound was performed with a 13-6 MHz high frequency linear probe (HFL 38) to identify the landmarks as described above. A 21G × 95-mm catheter-over-needle unit (MultiSet UPK NanoLine 21156-40E, Pajunk, Germany; 21G refers to needle size) (Fig. 1) described previously<sup>8</sup> was directed in a medial-to-lateral approach towards the corner immediately lateral to the subclavian artery and above the first rib. 2-5 mL of D5W and 25-30 mL of local anesthetic (1.5% lidocaine and 0.125% bupivacaine mixture) were injected following negative aspiration of blood or fluid (Fig. 2). The needle was removed and a flexible 20G × 75-mm inner catheter was inserted through the 18G outer catheter and then locked in place with the Luer lock (Fig. 1). 1-2 mL D5W was injected via the catheter such that the spread could be visualized under ultrasound to confirm the position of the inner catheter tip (Fig. 3). Epi-Guard™ (1 × REF: 8170 LiNA Medical ApS, Copenhagen MedLab, Denmark), a catheter anchoring device, and Tegaderm™, a transparent dressing, were used to secure the catheter.

The catheter remained inserted in the patient throughout the operation. In the PARR, a second 20 mL bolus of 0.2% ropivacaine was given through the perineural catheter

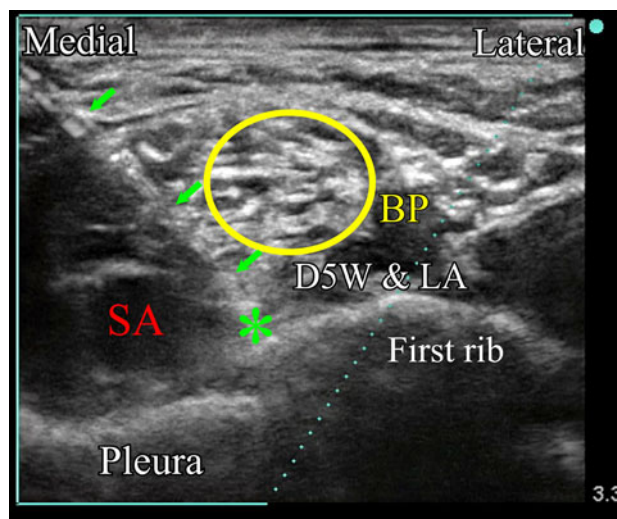


**Fig. 1** Photograph of the catheter-over-needle assembly. (Top) The catheter-over-needle assembly (MultiSet UPK NanoLine 21156-40E, Pajunk, Germany) has the outer catheter preloaded over the needle; (Middle) upon removal of the needle, the inner catheter can be fed through and Luer-locked onto the outer catheter; (Bottom) a standard 18G intravenous assembly (Becton, Dickinson and Co., Mississauga, ON, Canada). As shown, both the catheter-over-needle assembly and the intravenous cannulae are very similar in design; the needle tip protrudes from the distal end of the catheter in both designs. In the catheter-over-needle assembly, the tip of the inner catheter and the needle tip protrude the same distance from the distal end of the outer catheter





**Fig. 2** Ultrasound image of the supraclavicular block showing the catheter-over-needle directed in-plane in a medial-to-lateral approach. Local anesthetic was injected via the catheter-over-needle assembly with the spread lateral to the subclavian artery (SA). The shaft of the catheter-needle assembly is indicated by arrows; the needle tip is indicated by an asterisk. The brachial plexus (BP) is indicated by a circle



**Fig. 3** Ultrasound image showing the spread of 5% dextrose in water (D5W) to confirm catheter positioning following supraclavicular block. Local anesthetic (LA) from the previous injection is also present. The double-catheter assembly is indicated by arrows; the tip of the inner catheter is indicated by an asterisk. The brachial plexus (BP) is indicated by a circle

before its removal. The catheter was removed either before the patient left the PARR or when the patient was taken back to the admitting ward by a member of the research team.

#### Data collection

Patient age, height, and weight were collected prior to surgery; block duration and duration of surgery were also recorded. Prior to discharge from the hospital, patients were reminded to note the time at which they experienced pain and required rescue analgesia. For follow-up, a member of the research team contacted patients by telephone 24 hr after surgery. Patients were also questioned about gross sensory and motor function of the forearm and hand, severity of pain at onset, and approximate time of complete resolution of the block. If the first attempt to follow up was unsuccessful, a second follow-up phone call was made on the second day following surgery.

The primary outcome of the study was the duration of the block measured from the time of the first bolus dose to the time when the subjects felt pain and required rescue analgesia (ibuprofen or acetaminophen with codeine).

#### Blinding

In order to blind patients in both groups, all patients were led to believe they were receiving a second bolus via catheter. In the study group, the process of introducing the catheter (e.g., taping the catheter to the skin, injection of

the postoperative bolus) would be more obvious and lead these patients to believe they were given a second bolus. To blind patients in the single-shot group, a catheter (without the needle) from an intravenous assembly (Becton, Dickinson and Co., Mississauga, ON, Canada) was taped to the skin of the supraclavicular area using a sterile gauze dressing secured by Tegaderm<sup>TM</sup> (3 M Health Care, St Paul, MN, USA) following administration of the initial surgical bolus. To blind these patients to delivery of the second bolus, the anesthesiologist performed a sham injection with an empty syringe in the supraclavicular area after the patient returned to PARR.

#### Sample size calculation

Based on other reported data<sup>7</sup> and our clinical experience, we estimated the duration (SD) of analgesia to be 300 (60) min after a single-shot supraclavicular block. We expected the second bolus of local anesthetic given through the catheter in the PARR to have a similar duration of action and assumed it would prolong the duration of analgesia by at least 90 min compared with the control group. We determined that eleven patients per group were required for the study based on a two-sample Student's *t* test to detect a difference between groups of at least 90 min with 90% power and a type 1 error rate of 0.05 (two-sided). To allow for potential patient withdrawal and the possibility that we may not be able to follow up with patients, we decided to recruit 15 patients (i.e., four extra patients) per group.

## Statistical analysis

The patient samples were described with mean (SD) and frequency (%). Duration of anesthesia and duration of block procedure time were compared between groups using Welch's two-sample *t* test.

## Results

Recruitment and data collection were carried out from May to November 2012 at the University of Alberta Hospital. Thirty-two patients scheduled for hand surgery were approached for participation in the trial. Thirty ASA class I-II patients were enrolled and randomized in the single-shot supraclavicular block group ( $n = 15$ ) and the supraclavicular catheter-over-needle group ( $n = 15$ ). Surgery for two patients was cancelled, and these patients were withdrawn from the study. Four patients in the catheter-over-needle group and one patient in the single-shot group were lost to follow-up due to the inability to contact the patient in the two days after surgery. One patient who was initially recruited in the single-shot group chose to withdraw from the study. Data analysis included 13 patients from the single-shot group and 11 patients from the catheter-over-needle group. The groups were comparable regarding demographics, block times, and duration of surgery (Table). All supraclavicular blocks and perineural catheters were successfully placed as per protocol, and no complications were reported in either group.

The mean (SD) duration of analgesia measured from the beginning of the local anesthetic bolus to the onset of pain requiring rescue analgesia was 617.5 (288) min in the catheter-over-needle group and 377.2 (161.3) min in the single-shot control group (difference = 240.3 min; 95% confidence interval (CI): 46.8 to 433.8;  $P = 0.03$ ) (Fig. 4). For the catheter-over-needle group, the average time (SD) from the preoperative bolus to the postoperative bolus was 116.4 (47.8) min, while the mean (SD) duration of analgesia following the postoperative bolus was 503.8 (290.5) min.

**Table** Demographic characteristics and surgery duration of study participants

	Single-shot group ( $n = 13$ )	Catheter-over-needle group ( $n = 11$ )
Sex (M/F)	10/3	8/3
Age (yr) <sup>†</sup>	28.6 (12.0)	28.2 (12.7)
Weight (kg) <sup>†</sup>	90.3 (16.5)	80.0 (21.4)
Height (cm) <sup>†</sup>	174.6 (10.3)	179.8 (10.4)
Block time (min) <sup>†</sup>	4.4 (2.7)	3.1 (1.9)
Duration of surgery (min) <sup>†</sup>	40.5 (24.2)	39.5 (23.1)

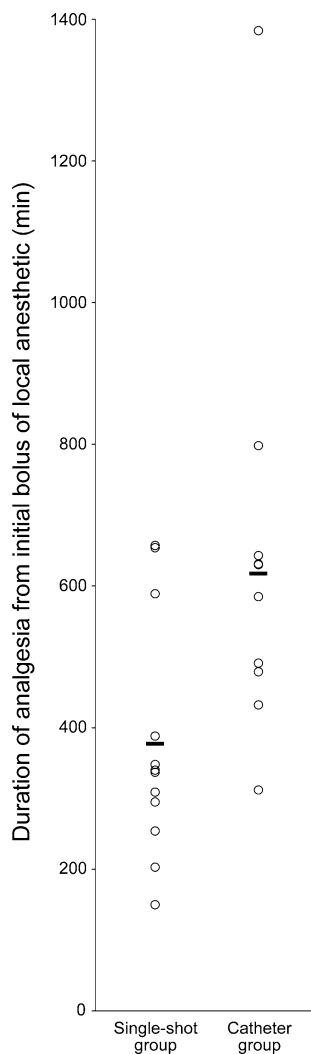
<sup>†</sup> Data are expressed as mean (standard deviation)

No significant difference was observed between the mean (SD) block times of the single-shot group vs the catheter-over-needle group [4.4 (2.7) min and 3.1 (1.9) min, respectively; difference was 1.3 min; 95% CI: -0.65 to 3.25;  $P = 0.17$ ].

## Discussion

In this randomized study, we have shown prolonged duration of analgesia following injection of a postoperative "top-up" bolus of local anesthetic via a supraclavicular catheter-over-needle assembly. Our results show that the catheter-over-needle assembly allows catheterization without prolonging the time to perform the block. Furthermore, the catheter remained stable and did not migrate from its perineural location, allowing the postoperative bolus of local anesthetic to be delivered effectively. The postoperative bolus of local anesthetic extended the analgesic effect from an average of three hours to more than four hours from the initial block injection when compared with the control group of patients who received only a single shot of local anesthetic prior to surgery. One major advantage of the postoperative bolus is enabling a consistent and accurate prediction of the duration of analgesia, which is measured from the time of the top-up dose rather than the initial dose of the preoperative block. Importantly, we found that patients receiving a postoperative top-up bolus prior to discharge experienced almost eight hours of pain relief following this bolus. In addition to providing extended pain relief, including a "pain-free" period while travelling home, this method also allows clinicians to provide patients with better information regarding the expected duration of analgesia and how and when to manage pain with oral analgesia. This is particularly useful in institutions where facilities are not well equipped to provide patients with infusion pumps upon discharge and also in situations where it is difficult to follow up with patients after discharge.

The clinical application of the catheter-over-needle design is not new; over the last century, the innovative concept of "over-the-needle" catheters has revolutionized drug administration via the intravenous route.<sup>10</sup> Rather than performing repetitive needle punctures, the simple and straightforward act of leaving a plastic tube behind after the initial needle insertion is now the preferred method for delivery of intravenous therapy. Similarly, the catheter-over-needle design can potentially offer the benefits of ease of use, increased confidence in the location of the catheter tip, and reduction in leakage and dislodgement in providing prolonged anesthesia. As shown in Fig. 1, the similarities between the catheter-over-needle and intravenous designs are obvious.



**Fig. 4** Duration of analgesia following the initial bolus of local anesthetic for the single-shot supraclavicular block (left column) and supraclavicular catheter-over-needle block (right column). Individual patients are represented by open circles; bars indicate mean duration (617.5 min catheter-over-needle vs 377.2 min single-shot)

The supraclavicular block has evolved tremendously since Kulenkampff reported the first percutaneous approach.<sup>11</sup> With the advent of ultrasound, this block has been extremely effective in providing surgical anesthesia for upper limb surgery with a reduced risk of neurological compromise and pneumothorax.<sup>12</sup> Although continuous delivery of local anesthetic to the brachial plexus via the supraclavicular catheter has advantages in certain cases, it has yet to be proven to be a reliable and effective technique. One study evaluating the effectiveness of supraclavicular catheters found that three out of ten catheters had to be removed due to dislodgement, ineffectiveness, and patient request.<sup>4</sup> Results of another randomized study suggested that the supraclavicular catheter approach was not as effective when compared with infraclavicular catheters<sup>5</sup> despite the anatomic advantages of a more compact brachial

plexus arrangement in the supraclavicular region<sup>13-16</sup> that would potentially allow for more even and complete spread of local anesthetic to the plexus.<sup>5</sup>

One of the speculated reasons for the unpopularity of supraclavicular catheters is the close proximity of the catheter to the clavicle, which may encourage easy dislodgement with slight arm movements, for example, during transfer of a patient from the stretcher to the operating table and vice versa or when moving the patient's arm for sterile preparation of the surgical field. Placement of traditional catheter-through-needle designs involves cumbersome steps, such as threading the catheter blindly through the positioned needle which, despite ultrasound guidance, often makes the position of the catheter tip difficult to ascertain because needle withdrawal is inevitably accompanied by simultaneous compensating advancement of the catheter. In contrast, the catheter-over-needle assembly has a simple insertion technique that is comparable with the single-shot approach, whereby the needle is inserted in the appropriate position, except that the catheter is pre-loaded over the needle. In fact, the size of the needle (21G) in the catheter-over-needle assembly is similar to gauges commonly used in single-shot blocks (i.e., 22G). Once in place, the needle is removed from within the outer catheter, the inner catheter is fed through the outer catheter with no resistance, and the two catheters are Luer-locked together (Fig. 1). With the outer catheter still in its original position and tightly held by the skin, the inner catheter essentially replaces the needle, enabling the inner catheter tip to be in the same position as the needle tip before its removal. Results of our study showed that the time taken to perform the catheter-over-needle block did not differ significantly from the traditional single-shot technique (Table).

Another drawback of the catheter-through-needle method is the tendency of the catheter to dislodge once placed. The technique requires creating a puncture site larger than the diameter of the catheter, which encourages leakage of local anesthetic around the catheter insertion site because the catheter is not held tightly against the skin. This leakage can further disturb the adhesives that hold the catheter in place, allowing catheter dislodgement or premature withdrawal. On the other hand, the catheter-over-needle design features a catheter with a larger diameter than that of the needle, creating a "tight fit" between the catheter and the skin that helps prevent leakage or dislodgement without the need for tunnelling or applying glue.<sup>9</sup> In this study, catheter stability was further increased by adopting a medial-to-lateral approach. As shown previously,<sup>17</sup> this technique may provide a more anatomic approach to catheter threading along the brachial plexus, as the catheters usually pass easily without complications.

The qualities of the catheter-over-needle assembly mentioned above benefit the individual performing the

block by eliminating the need to thread a catheter through the needle and providing a stable yet flexible conduit for injection of local anesthetic. The catheter-over-needle approach to the supraclavicular block is also expected to improve patient satisfaction with the block procedure. Essentially, the catheter-over-needle design allows the anesthesiologist to deliver the initial surgical solution and to retain a means of delivering one or more boluses of analgesia solution prior to patient discharge. This contrasts with the traditional single-shot method where any further boluses of analgesia solution would require another injection with a needle, increasing patient discomfort and possibly the risk of tissue or neurologic damage.

There are limitations to our study. This is a small study conducted at a single centre by individuals with significant expertise with the intervention. Six patients (20%) were not included in the analysis – four in the catheter group and two in the single shot group. It is not possible to determine the effect of these losses; the estimates of the between-group differences would be unbiased<sup>18</sup> only if the data were missing completely at random.<sup>19</sup>

Another limitation of our study is the use of 0.2% ropivacaine as the supplementary bolus via the catheter, as this differed from the local anesthetic solution used to provide surgical anesthesia for both groups prior to surgery. The rationale for using a weaker solution as a second bolus via the catheter was primarily for analgesic purposes. The initial surgical solution provides a dense motor block and a completely insensate arm, which could be uncomfortable for some patients,<sup>4</sup> especially after surgery with no sedation. This difference may affect the comparison between the duration of the analgesic block from the second catheter bolus and the dose used in the single-shot approach. Surprisingly, we observed a longer duration of analgesia following the postoperative top-up bolus compared with the single-shot bolus, suggesting that the analgesic and surgical solutions have similar potency in terms of their analgesic properties.

In summary, our study shows that use of the catheter-over-needle assembly is effective not only in facilitating the delivery of a second local anesthetic bolus postoperatively but also in requiring no more time to perform than a standard single-shot block. Further studies are required to evaluate these qualities and to compare the catheter-over-needle design with traditional catheter designs in terms of their effectiveness over the long term.

**Acknowledgements** The authors gratefully acknowledge Zakiya Dhanani, Jordan Leung, and Mark Rockley for assistance with data collection and Dr. Gareth Corry for assistance with manuscript preparation. The authors also thank the regional anesthesiologists at the University of Alberta Hospital ([www.Edmara.ca](http://www.Edmara.ca)) for their valuable contributions.

**Conflict of interest/other associations** The Pajunk MultiSet 211156-40E is modified and re-designed by Ban Tsui. Dr. Tsui also has a patent-licensing agreement with Pajunk. This work was supported by a Clinical Scholar Award from the Alberta Heritage Foundation for Medical Research (AHFMR) and a CAS/Abbott Laboratories Career Scientist Award from the Canadian Anesthesiologists' Society to Dr. Ban Tsui.

## References

1. *Bridenbaugh LD*. The upper extremity: somatic blockade. In: Cousins MJ, Bridenbaugh PO, editors. *Neural Blockade in Clinical Anesthesia and Management of Pain*. 2nd ed. Philadelphia: Lippincott; 1988. p. 387-416.
2. *Kapral S, Krafft P, Eibenberger K, Fitzgerald R, Gosch M, Weinstabl C*. Ultrasound-guided supraclavicular approach for regional anesthesia of the brachial plexus. *Anesth Analg* 1994; 78: 507-13.
3. *Williams SR, Chouinard P, Arcand G, et al*. Ultrasound guidance speeds execution and improves the quality of supraclavicular block. *Anesth Analg* 2003; 97: 1518-23.
4. *Heil JW, Ilfeld BM, Loland VJ, Mariano ER*. Preliminary experience with a novel ultrasound-guided supraclavicular perineural catheter insertion technique for perioperative analgesia of the upper extremity. *J Ultrasound Med* 2010; 29: 1481-5.
5. *Mariano ER, Sandhu NS, Loland VJ, et al*. A randomized comparison of infraclavicular and supraclavicular continuous peripheral nerve blocks for postoperative analgesia. *Reg Anesth Pain Med* 2011; 36: 26-31.
6. *Chawda PM, Sharma G*. A clinical study comparing epinephrine 200 µg or clonidine 90 µg as adjuvants to local anaesthetic agent in brachial plexus block via supraclavicular approach. *J Anaesthesiol Clin Pharmacol* 2010; 26: 523-7.
7. *Swami SS, Keniya VM, Ladi SD, Rao R*. Comparison of dexmedetomidine and clonidine (alpha2 agonist drugs) as an adjuvant to local anaesthesia in supraclavicular brachial plexus block: a randomised double-blind prospective study. *Indian J Anaesth* 2012; 56: 243-9.
8. *Ip V, Boultane M, Tsui B*. Potential contamination of the surgical site caused by leakage from an interscalene catheter with the patient in a seated position: a case report. *Can J Anesth* 2012; 59: 1125-9.
9. *Tsui BC, Tsui J*. Less leakage and dislodgement with a catheter-over-needle versus a catheter-through-needle approach for peripheral nerve block: an ex vivo study. *Can J Anesth* 2012; 59: 655-61.
10. *Rivera AM, Strauss KW, van Zundert A, Mortier E*. The history of peripheral intravenous catheters: how little plastic tubes revolutionized medicine. *Acta Anaesthesiol Belg* 2005; 56: 271-82.
11. *Kulenkampff D*. Brachial plexus anaesthesia: its indications, technique, and dangers. *Ann Surg* 1928; 87: 883-91.
12. *Liu SS, Gordon MA, Shaw PM, Wilfred S, Shetty T, Yadeau JT*. A prospective clinical registry of ultrasound-guided regional anesthesia for ambulatory shoulder surgery. *Anesth Analg* 2010; 111: 617-23.
13. *Brown DL, Cahill DR, Bridenbaugh LD*. Supraclavicular nerve block: anatomic analysis of a method to prevent pneumothorax. *Anesth Analg* 1993; 76: 530-4.
14. *Cornish PB*. Supraclavicular regional anaesthesia revisited—the bent needle technique. *Anaesth Intensive Care* 2000; 28: 676-9.
15. *Klaastad O, VadeBoncouer TR, Tilling T, Smedby O*. An evaluation of the supraclavicular plumb-bob technique for brachial

- plexus block by magnetic resonance imaging. *Anesth Analg* 2003; 96: 862-7.
16. Neal JM, Gerancher JC, Hebl JR, et al. Upper extremity regional anesthesia: essentials of our current understanding, 2008. *Reg Anesth Pain Med* 2009; 34: 134-70.
  17. Jeng CL, Rosenblatt MA. Considerations when performing ultrasound-guided supraclavicular perineural catheter placement. *J Ultrasound Med* 2011; 30: 423-4.
  18. Kristman V, Manno M, Cote P. Loss to follow-up in cohort studies: how much is too much? *Eur J Epidemiol* 2004; 19: 751-60.
  19. Little RJ, Rubin DB. *Statistical Analysis of Missing Data*. New York: Wiley; 1987.