

Through the looking-glass what you found there

Giampiero Soccorso, George K Ninan

Leicester, United Kingdom

A term-newborn baby developed respiratory distress after his first feed. An orogastric tube failed to reach the stomach. Chest and abdominal radiography showed a coiled tube in the proximal oesophageal pouch, and a gas-containing abdomen. These findings were consistent with oesophageal atresia (OA) and distal tracheo-oesophageal fistula (TOF) (Fig.).

Dextrocardia, right-sided gastric bubble and left-sided liver were also noted. The findings suggested combined OA, TOF and situs inversus totalis (SIT).^[1,2]

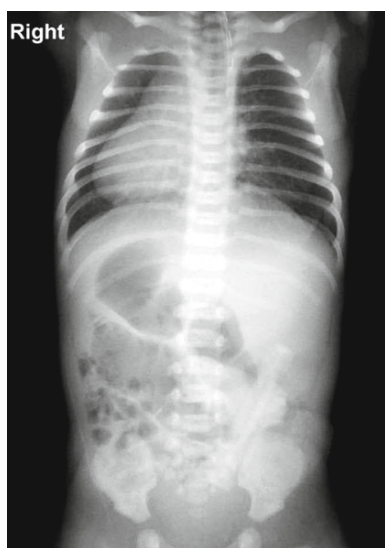


Fig. Plain film showing dextrocardia and the tip of the feeding tube positioned in the dilated upper esophageal pouch. Air in the stomach and throughout the bowel: the gastric bubble was situated on the right side, and the liver on the left.

Author Affiliations: Pediatric Surgical Unit, Sheffield Children Hospital, United Kingdom (Soccorso G); Department of Pediatric Surgery, Leicester Royal Infirmary, University Hospitals of Leicester, United Kingdom (Ninan GK)

Corresponding Author: G. K. Ninan F.R.C.S (Paeds), Consultant Pediatric Urologist, Department of Pediatric Surgery, Leicester Royal Infirmary, University Hospitals of Leicester, Leicester, LE1 5WW, United Kingdom (Email: george.ninan@uhl-tr.nhs.uk)

doi: 10.1007/s12519-012-0336-6

©Children's Hospital, Zhejiang University School of Medicine, China and Springer-Verlag Berlin Heidelberg 2012. All rights reserved.

Echocardiography confirmed dextrocardia, right-sided aortic arch and a small atrial septal defect with normal pulmonary venous connections. Left thoracotomy was performed by extra-pleural approach via the 5th intercostal space to repair the OA and ligate the TOF. At the 12-month postoperative follow-up, the baby was doing well.

SIT is a rare anomaly with complete right-to-left transposition of the thoraco-abdominal organs. The incidence of SIT is 0.01%. Associated intra-abdominal anomalies are polysplenia, malrotation and duodenal obstruction.^[3] Situs inversus may also occur in patients with primary ciliary dyskinesia (PCD). Kartagener syndrome is the combination of situs inversus, chronic sinusitis, and bronchiectasis.^[4]

Although rare, the preoperative recognition of SIT and right-sided aortic arch is essential in infants with OA to enable the surgeon to plan the side of thoracotomy, be aware of other gastrointestinal anomalies, and thereby avoid complications that may jeopardize the OA repair.^[5] Finally, to assess the long-term prognosis, surgeons should be aware that situs inversus occurs randomly in half the patients with PCD. Late complications of OA such as gastro-oesophageal reflux, respiratory tract infection and tracheomalacia can be potential factors aggravating PCD and Kartagener syndrome.

References

- 1 Luo C, Lin J, Lein R, Chu SM. A new variant of esophageal atresia with distal tracheo-antral fistula associated with congenital intra-thoracic stomach and situs inversus. *J Ped Surg* 2003;38:E25-27.
- 2 Bukarica S, Marinković S, Borisev V, Antić J. Esophageal atresia and situs inversus—an unusual association of abnormalities—a case report. *Med Pregl* 2006;59:73-78.
- 3 Cacciaguerra S, Gioviale M, Di Benedetto A. The importance of detailed diagnostic assessment in a case of partial situs inversus. *Pediatr Surg Int* 1998;13:531-532.
- 4 Holzmann D, Ott PM, Felix H. Diagnostic approach to primary ciliary dyskinesia: a review. *Eur J Pediatr* 2000;159:95-98.
- 5 Shenoy VG, Jawale SA, Oak SN, Kulkarni BK. Esophageal atresia with distal tracheoesophageal fistula associated with situs inversus. *Pediatr Surg Int* 2001;17:538-539.

Received May 30, 2011

Accepted after revision July 1, 2011