Current Cardiovascular Imaging Reports (2024) 17:1–19
https://doi.org/10.1007/s12410-023-09588-y

REVIEW

The Additional Value of T1 Mapping in Cardiac Disease: State of the Art

Raffaele Ascione[1] · Marco De Giorgi[2] · Serena Dell'Aversana[3] · Giuseppe Di Costanzo[3] · Carmela Nappi[2] · Massimo Imbriaco[2] · Andrea Ponsiglione[2]

Accepted: 10 November 2023 / Published online: 22 December 2023

Abstract

Purpose of the Review This paper delves into the emerging realm of T1 mapping, exploring recent innovations and their relevance across several cardiac diseases.

Recent Findings T1 mapping with cardiovascular magnetic resonance (CMR) imaging has emerged as a valuable tool for cardiac disease evaluation, offering diagnostic, therapeutic, and prognostic insights. Tissue characterization using parametric mapping methods holds the promise of identifying and quantifying both focal and diffuse changes in myocardial structure, which cannot be adequately assessed through late gadolinium enhancement (LGE).

Summary CMR imaging, particularly LGE, has enhanced cardiac tissue characterization. However, the detection of diffuse interstitial fibrosis remains challenging, necessitating the exploration of alternative techniques. T1 mapping could probably represent a game changer in the evaluation of diffuse and focal fibrosis in multiple cardiovascular conditions.

Keywords CMR · T1 mapping · ECV · Cardiac disease

Introduction

Cardiovascular magnetic resonance (CMR), with its resolution, enhanced tissue contrast, and superior safety profile, has become a unvaluable and comprehensive imaging modality for studying the cardiovascular (CV) system [1]. Advances in CMR with late gadolinium enhancement (LGE) provide an adequate characterization of focal myocardial fibrosis and myocardial scar, allowing a proper differentiation between ischemic and non-ischemic cardiomyopathy [2]. Unfortunately, detecting diffuse interstitial fibrosis on LGE imaging remains complicated because of the lack of a normal myocardium reference standard [3]. Furthermore, in this setting, LGE imaging is not able to adequately evaluate collagen volume when correlated to endomyocardial biopsies [4]. To overcome these limitations, parametric mapping methods have been proposed. The aim of this paper is to review and illustrate recent advances in T1 mapping for different cardiac diseases and their additional value in the context of established CMR methods.

Principles of T1 Mapping

T1 calculates the longitudinal relaxation time, which depends on the rate at which the spin magnetization recovers to its equilibrium state after being excited by a radiofrequency pulse. T1 mapping refers to a pixel-wise illustration of absolute relaxation times on a map [5]. Several technical and biological factors play a crucial role in influencing native T1 values. Among these factors, field strength stands out as the most significant determinant. At 3 Tesla (3 T), native T1 values tend to be higher compared to those at 1.5 T. Additionally, the choice of pulse sequence, the specific phase of the cardiac cycle during imaging, and the region of measurement within the body also exert notable effects on this parameter [6, 7]. The most important biological factors that increase native T1 values are oedema and the expansion of interstitial space, while low native T1 values are determined by lipid

✉ Massimo Imbriaco
massimo.imbriaco@unina.it

1 Department of Diagnostic Imaging, Pineta Grande Hospital, 81030 Castel Volturno, Italy

2 Department of Advanced Biomedical Sciences, University of Naples Federico II, Via Pansini 5, 80131 Naples, Italy

3 Department of Radiology, Santa Maria Delle Grazie Hospital, ASL Napoli 2 Nord, 80078 Pozzuoli, Italy

and iron overload [8–11]. On this basis, native T1 is thus regarded as a promising method for detecting myocardial abnormalities without the necessity of administering a gadolinium contrast agent.

Contrast-enhanced T1 Mapping and Extracellular Volume (ECV) Fraction

Myocardium is made of three different spaces: myocytes, together with fibroblasts, endothelial cells and others, represent the intracellular space; blood constitutes the intravascular compartment, and the interstitial space is the remaining compartment once cells and intravascular spaces are removed. Extracellular space expansion may be determined by several pathologies such as oedema, inflammation and fibrosis; contrast-enhanced T1 mapping may accurately evaluate this alteration in combination with native T1 mapping (Fig. 1). Standard gadolinium-based contrast agents are distributed throughout the extracellular space, and the shortening of T1 myocardial relaxation times depends on the local concentration of gadolinium [4]. Extracellular volume (ECV) is a marker of myocardial tissue remodeling with a value of $25.3 \pm 3\%$ reported in healthy subjects [9]. Its evaluation requires: a) measurements of myocardial and blood T1 before and after gadolinium administration, b) patient's haematocrit; ECV is then calculated according to the following formula:

$$\begin{aligned} \text{ECV} = {} & \{(\Delta \text{R1 of myocardium}/\Delta \text{R1 of left ventricular [LV] blood pool})\} \\ & \times (1 - \text{hematocrit level}), \text{ where R1} = 1/\text{T1 and } \Delta\text{R1} \\ & = \text{post} - \text{contrast R1} - \text{pre} - \text{contrast R} \end{aligned}$$

T1-Mapping Techniques

T1-mapping protocols are based on inversion recovery (IR) or saturation recovery (SR) sequences. To obtain a pixel map of T1, multiple images are acquired during different moment on the recovery curve and a pixel-wise curve fitting is used to evaluate the relaxation time. To reduce movement artefacts, patients are always scanned at the same cardiac and breath phase. At the beginning, protocols comprised multiple breath-holds, but present techniques mostly use single-breath-hold scans with single-shot bi-dimensional imaging.

An example of T1 mapping and ECV from a healthy volunteer is shown in Fig. 2.

Inversion Recovery-Based Techniques

MOLLI, which is the abbreviation for modified Look-Locker, is the most used sequence for T1 mapping; after the inversion pulse, during the subsequent 3 to 5 heartbeats, single-shot images separated by the RR period are acquired along the T1 recovery curve [12]. The first introduced

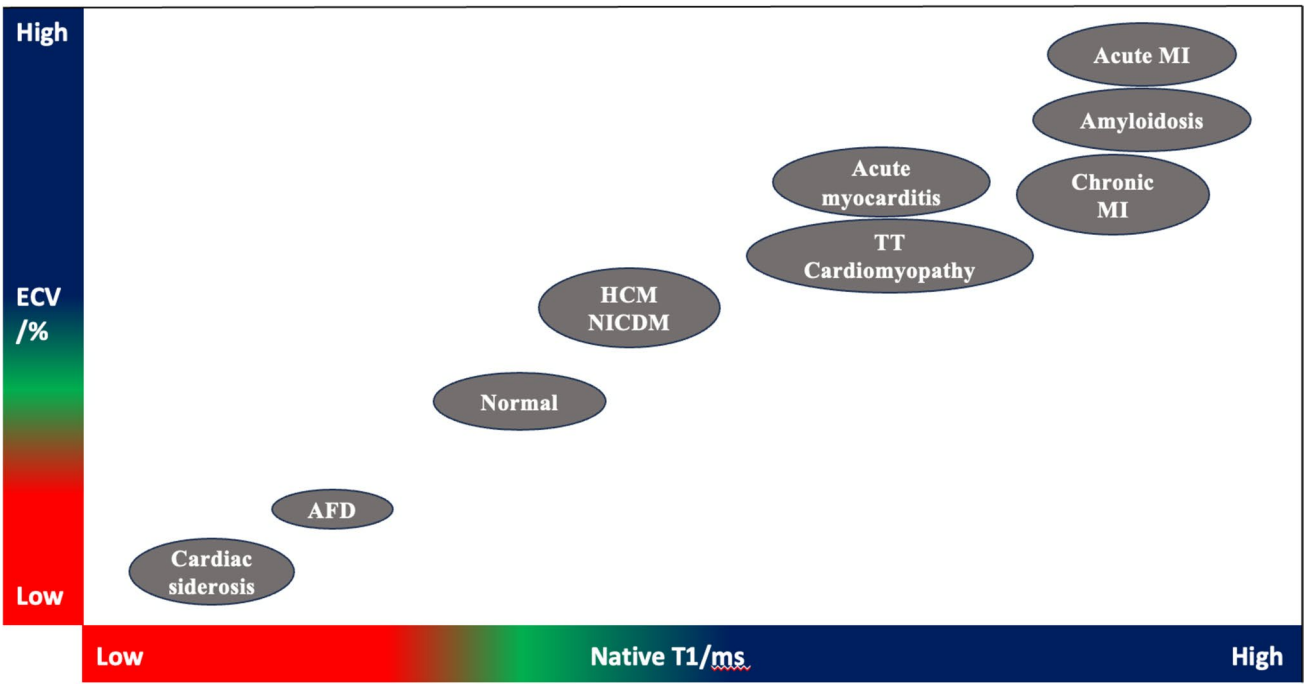

Fig. 1 Native T1 mapping and ECV values across various cardiac disease. *AFD* Anderson Fabry disease; *HCM* Hypertrophic Cardiomyopathy; *NICDM* non-ischemic dilated cardiomyopathy; *TT* Takotsubo; *MI* myocardial infarction

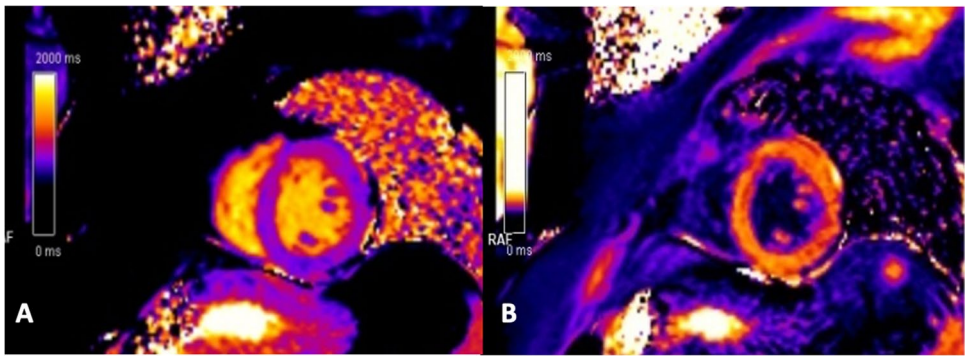

Fig. 2 Midventricular short-axis CMR images of a 40-year-old healthy male volunteer, showing normal global T1 mapping values (**A**) within the range of 986 ± 50 ms, along with normal ECV values (**B**) measuring 23%. *ECV* extracellular volume

MOLLI protocol consists in a 3(3)3(3)5 scheme; these numerical sequences summarize the number of inversion pulses, the samples and the recovery period; numbers in brackets represent the images obtained after the inversion pulse, while the ones in brackets indicate the RR intervals for T1 recovery [12, 13]. The MOLLI technique has been revealed as a highly reproducible diagnostic tool with high signal-to-noise ratio images. However, its critical limitation is represented by the very long breath-hold duration (at least 17 heartbeats), which may be difficult to obtain for cardiopathic patients. Furthermore, if there is not enough time for complete magnetisation recovery, the T1 values will be heart rate dependent. For these reasons, the original MOLLI sequence has been modified several times[14–16]. "Shortened" modified Look-Locker technique (shMOLLI) represents one of the most popular variations of MOLLI sequence, which consists in a 5(1)1(1)1 protocol where the last magnetization inversions may not be complete depending on T1, and T1 is therefore determined by a "conditional" fitting routine [15]. "Conditional" refers to the fact that the data from the last 2 Look-Locker cycles are only used if the T1 is short enough to allow for near-complete relaxation recovery after the second and/or first Look-Locker cycle. The main advantages of ShMOLLI sequence are the very little heart rate dependence and the short breath hold. Due to the presence of residual heart motion, even during breath-holding, the application of nonrigid registration techniques proves to be instrumental in enhancing the robustness and clinical efficacy of the method. [16]. However, the two described techniques could still slightly underestimate T1 because the image readouts during the inversion recovery can be influence by other factors such as T2 [17].

Saturation Recovery-Based Techniques

A second option to IR sequences is represented by SR techniques that may possibly determine T1 value with more accuracy [18]. Since a saturation radiofrequency pulse can null the longitudinal magnetization, independently of its state before the saturation pulse, it is not necessary to wait for T1 recovery between the pulses, and this cancels the problem of heart rate dependence for the calculated T1s [18]. The most critical disadvantage of SR method is that a saturation preparation results in one-half of the dynamic range of an inversion preparation; using a preliminary unperturbed image and acquiring data at consecutive heartbeats by saturation recovery over RR period at diverse saturation times, this method could lower the precision of T1 values evaluation. Nowadays, the most used SR technique is known as SASHA; it acquires data at consecutive heartbeats by saturation recovery over RR period at diverse saturation times, using a preliminary unperturbed image [19].

T1 Mapping in Ischemic Heart Disease

An overview of the main studies with T1 mapping/ECV in ischemic heart disease is presented in Table 1.

Acute Myocardial Infarction

In patients presenting with ST-segment elevation myocardial infarction (STEMI), one-year mortality remains high despite revascularization by primary percutaneous coronary intervention (PCI) [24]. The immediate identification of this group of high-risk patients is fundamental to guarantee their selection for tailored therapy program, and therefore reduce their major adverse cardiac events (MACE) risk, improving prognosis. CMR represents the best imaging modality for characterizing the tissue heterogeneity of an infarcted myocardium, being able to distinguish among all the different shades of myocardial injury such as necrosis, edema, microvascular obstruction and hemorrhage. [25]. In acute MI, native T1 reach a very high values, while ECV values are among the highest (0.585 ± 0.076) of all cardiac diseases [20]. This probably represents the consequence of the loss of integrity of the myocytes membrane which determines an expansion of the distribution volume of gadolinium-based contrast agents. It is important to underline that the presence of intramyocardial hemorrhage and microvascular

Table 1 An overview of the main studies with T1 mapping/ECV in acute and chronic ischemic heart disease

First author	Publication year	Aim of the study	Study design	Sample size	Main outcome
Sado et al. [20]	2012	To assess the significance of myocardial ECV, as a clinical biomarker in health and in cardiac diseases	Prospective, single center	192 # 20 ^ 81*	Myocardial ECV shows gender differences in normal individuals and disease-specific variability. Mean ECV was higher in MI and AL amyloidosis
Ma et al. [21•]	2021	To evaluate the feasibility of texture analysis on non-CE T1 maps of CMR imaging for the diagnosis of myocardial injury in MI	Retrospective, single center	68	Combination of radiomics of non-CE T1 mapping and T1 values showed high diagnostic accuracy in MVO detection
Wang et al. [22]	2020	To assess the feasibility of CMR without gadolinium-based contrast agents using native T1-maps at 3 T to characterize chronic MI	Prospective, multicenter	215	Native-T1 mapping can be used to image chronic MI with high degree of accuracy, and as such, it is a viable alternative for scar imaging in patients with chronic MI who are contraindicated for LGE
Kaolawanich et al. [23]	2022	To explore the impact of fatty metaplasia on the accuracy of native T1 mapping in discerning myocardial replacement fibrosis among individuals suffering from chronic MI	Prospective, single center	312 § 50 *	Native T1 mapping is poor at detecting replacement fibrosis but may indirectly detect chronic MI if there is associated fatty metaplasia

ECV extracellular volume; *MI* myocardial infarction; *CE* contrast enhancement; *CMR* cardiac magnetic resonance; *MVO* microvascular obstruction, *LV* left ventricular; *LGE* late gadolinium enhancement

[#]patients with various cardiac diseases

^ patients with MI

[*] healthy controls

[§] patients with chronic MI

obstruction (MVO) could determine pseudo-normalization of T1 values. T1 can even be reduced because of the accumulation of methemoglobin [26, 27]. As known, LGE represents the gold standard to evaluate scar burden in stable CAD [28]. However, in acute clinical scenario, its clinical applicability and accuracy have been repeatedly challenged [29, 30]. In patients with STEMI, it has been shown that CMR acquisition of native T1 mapping can differentiate reversible and irreversible myocardial damage; a cut-off value of native T1 ≥ of 1400 ms was a good indicator of 6-month wall thickening compared to LGE [31]. Another study confirmed these results, demonstrating that hyperacute T1 values of the area at risk recorded within three hours after PCI could predict a greater extent of the microvascular obstructions and of infarcted myocardium volume at both 24 h and six months follow-up [32]. More recently, Ma et al. have shown that the combined use of radiomic features and T1 values is capable to distinguish different grades of transmurality of an infarcted myocardium wall with a superior diagnostic accuracy than T1 values alone (absence T1 value: 1264.3 ± 69.1 ms; presence T1 value: 1376.0 ± 127.6 ms) [21•]. Moreover, this combination could also predict the irreversibility of a segmental scar with superior accuracy than T1 alone (reversible T1 value: 1268.4 ± 81.3 ms; irreversible T1 value:1387.3 ± 133.6 ms) as well as the recovery of regional left ventricular function at segmental longitudinal strain (SLS) (non-favorable SLS T1 value: 1319.7 ± 134.5 ms; favorable SLS T1 value: 1291.6 ± 94.1 ms).

Chronic Myocardial Infarction

LGE represents the gold standard for accurately characterizing a chronic myocardial infarction where an acute infarct's necrotic and edematous myocardial tissue has been replaced by a collagenous scar. For this reason, when compared to the acute phase, chronic MI is generally characterized by lower and less extended T1 values. On this basis, native T1 has been proposed as a good alternative to LGE for identifying and characterizing chronic MI avoiding the administration of a contrast agent. Wang et al. evaluated the performance of native-T1 mapping and LGE at 3 T in chronic MI patients [22]. In particular, they determined the T1 values within the MI territory to be approximately 1621 ± 110 ms, in contrast to the remote territory, which exhibited T1 values averaging around 1225 ± 75 ms. Their results showed a sensitivity of 88%, a specificity of 92%, and an AUC of 0.93 for identifying MI location based on native-T1 mapping in comparison to LGE. Native-T1 maps were comparable to LGE in measuring infarct size and MI transmurality. For these reasons, in chronic MI patients who cannot benefit from contrast agents administration, T1 mapping could represent a great option for scar imaging, even if the presence of lipomatous metaplasia in the infarcted area could significantly reduce T1 values [27]. Kaolawanich et al. recently demonstrated that native T1 mapping can identify chronic MI better in patients with fatty metaplasia than those without (85.6% vs 13.3% sensitivity) [23]. However, in this subgroup, the size of regions with elevated T1 significantly miscalculated infarct size, while in patients without fatty metaplasia, the lower T1 values seemed to be due to sub-chronic infarcts; these results suggest that native T1 mapping could be useless in detecting replacement fibrosis but could indirectly distinguish chronic MI if there is associated fatty metaplasia.

T1 Mapping in Non-Ischemic Cardiomyopathy

An overview of the main studies with T1 mapping/ECV in non-ischemic cardiomyopathies is presented in Tables 2, 3, 4 and 5.

Non-Ischemic Dilated Cardiomyopathy (NIDCM)

NIDCM is considered the end-stage of numerous non-ischemic cardiac diseases. Even with the recent improvement of treatment protocols, the mortality rate is still high (nearly 20%) [46]. At CMR, the evidence of mid-wall LGE predicts an augmented risk of MACEs in these patients [47, 48]; however, LGE sequences alone are not able to provide an accurate quantitative measurement of diffuse myocardium fibrosis that generally affects patients with DCM. Instead, T1 mapping could represent a good, reproducible tool to quantitative measure diffuse fibrosis in this setting[49, 50]. In a prospective longitudinal observational multicenter study including 637 patients with NIDCM, Puntman et al. have demonstrated that non-invasive evaluation of diffuse myocardial fibrosis through T1 mapping is significantly predictive of all causes of mortality (1.5 T T1 values: 1069 ms (1036–1103), $p < 0.001$ – ECV %: 30 (24–36), $p = 0.03$; 3 T T1 values: 1183 ms (1126–1211) $p < 0.001$ – ECV %: 31 (26–35), $p = 0.02$) and of a composite heart failure (HF) endpoint (HF death and HF hospitalization) in NIDCM [33]; the predictive associations are independent of conventional markers of function, structure, and regional myocardial disease by LGE. These results are partially discordant with another study where ECV was superior to T1 mapping to predict outcomes in NIDCM [51•]. After following their patient for four years, they observed MACE in 15% of the study group. In this subgroup, mean ECV demonstrated strong association with MACE ($p < 0.001$), superior to native T1 and LGE. These discrepancies between the two studies could be likely due to differences in the CMR techniques and in the studies' cohort and design. Moreover, calculated ECV is a CMR tool used to describe myocardial

Table 2 An overview of the main studies with T1 mapping/ECV in non-ischemic dilated and Takotsubo cardiomyopathies

First author	Publication year	Aim of the study	Study design	Sample size	Main outcome
Puntman et al. [33]	2016	To assess the prognostic relevance of T1 mapping parameters in NIDCM and compare them with conventional markers of adverse outcome	Prospective, longitudinal, observational, multi-center	637	Measures of diffuse myocardial disease by T1 mapping are significantly predictive of all-cause of mortality in NIDCM, independently of conventional markers of function, structure, and regional myocardial disease by LGE
Cadour et al. [34]	2023	To determine if T1 mapping and ECV have a prognostic value in NIDCM patients	Prospective, multicenter	225	Native T1 was an independent predictor in arrhythmia-related events occurrence. The addition of ECV and native T1 in the decision-making algorithm may improve arrhythmia risk stratification
Aikawa et al. [35]	2019	To investigate the clinical impact of T1 mapping for detecting myocardial impairment in Takotsubo cardiomyopathy over time	Prospective, single center	23	Native T1 mapping offers high diagnostic performance for detection of myocardial oedema and prediction of LV wall motion restoration

NIDCM non-ischemic dilated cardiomyopathy; *LGE* late gadolinium enhancement; *ECV* extracellular volume

Table 3 An overview of the main studies with T1 mapping/ECV in genetic cardiomyopathies

First author	Publication year	Aim of the study	Study design	Sample size	Main outcome
Liang et al. [36]	2022	To assess the effectiveness of various CMR parameters in differentiating between HCM and HHD	Prospective, longitudinal, observational, multi-center	38 * 35 § 29°	Both native T1 values and ECV can support clinically relevant discrimination between HCM and HHD
Bourfiss et al. [37]	2019	To compare T1 mapping between patients with ARVC and control subjects	Prospective, single center	30 # 13°	Genotype-positive ARVC patients had significantly higher native T1 values than controls, suggesting a predominant role of LV replacement fibrosis rather than fat infiltration in ARVC pathogenesis
Araujo-Filho et al. [38]	2018	To characterize myocardial T1 mapping and ECV fraction by CMR and investigate how these biomarkers relate to LVNC	Prospective, single center	36 18°	Tissue characterization by T1 mapping suggests an extracellular expansion by diffuse fibrosis in myocardium without LGE, associated with myocardial dysfunction and ventricular arrhythmias, but not with the amount of non-compacted myocardium

CMR cardiac magnetic resonance; *HCM* hypertrophic cardiomyopathy; *HDD* hypertensive heart disease; *ARVC* arrhythmogenic right ventricular cardiomyopathy; *ECV* extracellular volume; *LV* left ventricular; *LVNC* left ventricular non-compaction cardiomyopathy; *LGE* late gadolinium enhancement

*patients with HCM

§patients with HHD

°healthy controls

#patients with ARVC

Table 4 An overview of the main studies with T1 mapping/ECV in inflammatory cardiomyopathies

First author	Publication year	Aim of the study	Study design	Sample size	Main outcome
Palmisano et al. [39]	2020	To evaluate the value of early enhanced T1 shortening for the diagnosis of acute myocarditis	Prospective, single center	45 * 19°	Percentage of T1 shortening at early enhanced T1 mapping showed high accuracy for the diagnosis of acute myocarditis
Puntmann et al. [40]	2020	To evaluate the presence of myocardial injury in unselected patients recently recovered from COVID-19 illness	Prospective, observational, single center	100 # 50°	Myocardial native T1 and T2 measures provided the best discriminatory value against healthy controls and risk factor–matched controls for exclusion of any myocardial disease or confirmation of COVID-19–related involvement, respectively
Galea et al. [41]	2021	To assess the clinical value of CMR in characterizing myocardial damage in active COVID-19 patients	Retrospective observational, single center	27 #	CMR allowed characterization of myocardial by means of a multiparametric scanning protocol including conventional imaging and T1–T2 mapping and ECV
Puntmann et al. [42]	2017	To determine whether quantitative tissue characterization with T1 and T2 mapping supports recognition of myocardial involvement in patients with systemic sarcoidosis	Prospective, single center	53 § 36°	Quantitative myocardial tissue characterization with T1 and T2 mapping may enable noninvasive recognition of cardiac involvement and activity of myocardial inflammation in patients with systemic sarcoidosis

ECV extracellular volume; *CMR* cardiac magnetic resonance

*patients with acute myocarditis

°healthy controls

#patients with COVID-19 illness

§patients with systemic sarcoidosis

Table 5 An overview of the main studies with T1 mapping/ECV in infiltrative cardiomyopathies

First author	Publication year	Aim of the study	Study design	Sample size	Main outcome
Fontana et al. [43]	2014	To explore the ability of native myocardial T1 mapping to detect cardiac involvement in ATTR amyloidosis, track the cardiac amyloid burden and detect early disease	Retrospective, single center	172 # 52° 46 §	Native myocardial T1 mapping detects cardiac ATTR amyloid with similar diagnostic performance and disease tracking to AL amyloid. In individuals with established cardiac ATTR amyloidosis, the degree of T1 elevation was comparatively lower than that observed in AL amyloidosis
Sado et al. [44]	2013	To evaluate non contrast T1 mapping ability to detect early cardiac involvement and distinguish LVH due to AFD from other causes	Prospective, single center	227	Noncontrast T1 mapping shows potential as a unique and powerful measurement in the imaging assessment of LVH and AFD
Alam et al. [45]	2015	To compare the established 1.5 T BB T2* technique against native T1 values at 1.5 T and 3 T in iron overload patients with cardiac siderosis	Prospective, single center	53 * 20°	T1 mapping at both 1.5 T and 3 T can effectively detect individuals with substantial iron loading, as defined by the current gold standard T2* measurement at 1.5 T

ATTR transthyretin amyloidosis; *AL* immunoglobulin light-chain amyloidosis; *AFD* Anderson-Fabry disease; *LVH* left ventricular hypertrophy

#amyloid patients

°healthy volunteers

§patients with hypertrophic cardiomyopathy

*patients with cardiac siderosis

extracellular space, and even if in some papers it has been adopted as a surrogate for histological collagen volume fraction in cardiovascular diseases, it does not certainly correlate well with histological fibrosis in DCM. This concept has been clearly elucidated in a single-centre study including a small sample size of NICDM patients where CMR results have been compared to right-sided biopsies of the mid-interventricular septum [52•]. Furthermore, in a recent multicenter study in which a group of 225 patients with NIDCM was followed for two years, Cadour et al. stated that NIDCM patients with HF-related or arrhythmia-related events had higher native T1 and ECV values (Native T1 Z-score: 3.8 ± 2.3, $p = 0.001$; ECV%: 31.1 ± 4.3, $p = 0.001$) compared with NIDCM patients without MACEs (Native T1 Z-score: 2.7 ± 2.2, $p = 0.001$; ECV%: 28.7 ± 3.8, $p = 0.001$) [34]; non-invasive measures of diffuse interstitial fibrosis by native T1 Z-score ($p = 0.008$) and ECV ($p = 0.001$) were significantly predictive of MACEs; the unique significant independent indicator predictive for both HF- and arrhythmia-related events (HR 2.15 [1.14–4.07], $p = 0.018$) was elevated ECV (cutoff > 32.1%); increased native T1 Z-score (cut-off > 4.2) was also an independent predictor of arrhythmia-related events in NIDCM patients (HR 2.86 [1.06–7.68], $p = 0.037$).

Takotsubo Cardiomyopathy

Takotsubo cardiomyopathy (TTC) is considered as an acute cardiovascular syndrome which generally presents as a temporary left ventricular dysfunction with a typical cardiac kinesis pattern without the presence of CAD [53]. In subacute clinical setting, CMR plays an important role in detecting TTC since LGE sequences typically show no enhancement and this can be helpful in differentiate the disease from MI or acute myocarditis [24]. One of the most important features of TTC is represented by diffuse myocardial oedema, which generally involve the whole LV even if it can be more intense in the hypokinetic segments. CMR can easily detect oedema via T2W imaging using the short-tau inversion recovery (STIR), however the introduction of T1 mapping sequences could guarantee a faster (single breath-hold) and quantitative evaluation of oedema without the need of a reference ROI as for T2 STIR sequences. Ferreira et al. stated that high native T1 values in TTC affected the myocardium as well as even in normal wall motion and a negative correlation between baseline LV ejection fraction (EF) and native T1 [54]. They found elevated T1 values in patient segments with preserved and not preserved wall motion when compared to the control group (1029 ± 59 ms, 1113 ± 94 ms and 944 ± 17 ms, respectively; $p < 0.001$) and established that a T1 value cut-off > 990 ms was optimal to differentiate segments affected by oedema from normal segments at 1.5 T, with a 92% sensitivity and specificity. More recently, Aikawa et al. explored the clinical relevance

of T1 mapping for the mid-term evaluation of myocardial impairment in TTC [35]. During the acute phase, when compared to the control group, TTC patients demonstrated elevated native T1 (1438 ± 162 vs. 1251 ± 90 ms, P < 0.001), ECV (35 ± 5% vs. 29 ± 4%, P < 0.001), and T2 (90 ± 34 vs. 68 ± 12 ms, P < 0.001) for the entire heart. Importantly, they observed that native T1 mapping outperformed conventional T2 mapping for detecting myocardial oedema (AUC: 0.96 vs 0.86; P = 0.005) and that a T1 cut-off value > 1339 ms at three months follow-up scan was significantly correlated to prolonged LV wall motion recovery.

Genetic Cardiomyopathies

Hypertrophic Cardiomyopathy

Hypertrophic Cardiomyopathy (HCM) is a condition in which heart walls are thicker than normal and this anomaly cannot be explained by abnormal preload or afterload [55, 56]; in 30–60% of cases, the disease is the consequence of a sarcomere gene mutation inherited with autosomal dominance and it is generally identified in younger patients with family history of HCM [57]. Sudden cardiac death (SCD) is the most feared complication of the disease and to establish the risk of SCD is one of the most important objectives of the clinical management in these patients [58•]. As known, CMR-LGE can non-invasively detect and quantify myocardial fibrosis which possibly represent the basis for dangerous ventricular arrhythmias (VA) [59, 60]. The American HCM guidelines recommend LGE ≥ 15% of LV mass as a marker of SCD risk [55] and recently European guidelines for the prevention of SCD confirm this indication [61]. However, since a variable quote of LGE is present in 60–90% of HCM patients, its value as a risk stratifier is quite weak [62]. An accurate quantification of the LGE burden could reduce the impact of this limitation, but the differences in LGE scanning sequences and LGE quantification methods make the clinical implementation of LGE quantification challenging. Native T1 mapping and ECV could represent an interesting alternative to LGE as they have shown a good correlation with SCD risk for this disease; ECV also demonstrated a good association with SCD independent of LVEF [63, 64].

Qin et al. explored the capability of native T1 mapping and ECV to predict MACE in this category of patients [63]. In their HCM-MACE subgroup, global T1 mapping (1341.2 ± 39.6 ms) values were significantly higher than the HCM group that did not experience MACE (1277.9 ± 45.2 ms) and it was independently associated with MACE (HR: 1.446; 95%; CI: 1.195–1.749; $P < 0.001$). Moreover, in a subgroup of patients with low SCD risk established by conventional guidelines (T1 map not included), statistical analysis showed that global native T1 mapping was independently associated with MACE (HR: 1.532; 95% CI: 1.221–1.922; $P < 0.001$), highlighting that it could improve and support the current guidelines in the prediction of MACE.

More recently, it has been suggested that both native T1 values and ECV can outperform LGE to discriminate between HCM and hypertensive heart disease [36]. In particular, Liang et al. observed that in their cohort of patients, native T1 values were significantly higher in patients with HCM (1293.6 ± 53.8 ms) than in patients with HHD (1264.3 ± 67.7 ms) and in healthy controls (1236.1 ± 42.6 ms) (P < 0.001) [36]. Similarly, significantly higher ECV percentages were observed in HCM patients (34.9 ± 9.8%) when compared with HHD patients (27.1 ± 6.7%) and healthy controls (26.8 ± 5.8%) (P = 0.001). The Authors also identified a cut-off value of 28.8% for ECV, which was able to distinguish between HCM and HHD with 85% sensitivity, 62.07% specificity, and an AUC of 0.772. They demonstrated that these two methods can play an important role in clinical discrimination between HCM and HHD. However, the important overlap of native T1 values between normal and pathological myocardium represents a critical problem; for this reason, temporal or regional variations of T1 values in a single specific patient can represent an essential clinical information while comparisons among different patients could not be of value. Radiomics is a rapidly evolving field that uses data-characterization algorithms to extract data from medical images [65, 66]. It has recently been shown that radiomics phenotyping of native T1 mapping using machine learning could distinguish healthy versus hypertrophic myocardium and can also differentiate LVH aetiology, including HCM or cardiac amyloid [67–69].

Arrhythmogenic Right Ventricular Cardiomyopathy

Arrhythmogenic Right Ventricular Cardiomyopathy (ARVC) is a genetic cardiac condition in which the continuous fibro-fatty replacement of the normal cardiomyocytes becomes the substrate of VAs and SCD [70, 71]. ARVC diagnosis has always been based on the presence of genetic mutations, ECG abnormalities or VAs, but recently at least one morpho-functional right ventricle (RV) or LV is necessary for the diagnosis[72]. On this ground, CMR with cine sequences and tissue characterization with LGE imaging has become the leading imaging technique to detect the disease phenotype [72]. ARVC is increasingly recognized as a biventricular disease, and LV involvement is increasingly observed in up to 80% of relatives of sudden death victims diagnosed with ARVC on post-mortem examination [73, 74]. T1 mapping diagnostic potentials has been recently explored also for this cardiomyopathy. Bourfiss et al. evaluated native T1 mapping values and its dispersion in genotype positive ARVC patients and their families, also in comparison with control groups [37]. Their results demonstrated significantly

(p = 0.04) higher native T1 values (1067 ± 41 ms) for genetically confirmed ARVC patients where controls showed significantly lower values (1038 ± 27 ms); these results also suggest a critical role of LV replacement fibrosis in the pathogenesis of the disease, maybe superior than fat infiltration. On the contrary, when compared with controls, a larger T1 values dispersion has been found in genotype-positive ARVC patients and their family members, that is probably a consequence of regional microstructure changes. Some Authors believe that native T1 variations can precede LV focal abnormalities in ARVC, favoring an early detection of these subjects and consequently improving prognosis. In a recent study, Georgiopoulos et al. discovered that native myocardial T1 values were higher than normal in 37% of their ARVC patients (1.5 T: 977 ± 39 ms, n.v. 950 ± 21 ms; 3 T:1189 ± 102 ms, n.v. 1052 ± 23 ms), including a proportion of patients who would have been otherwise classified as normal using conventional methods [75]. Higher T1 values were also observed in 33% of first-degree relatives who did not exhibit a cardiomyopathy phenotype after extensive investigations. Their observation could suggest a critical role for T1 mapping to early detect patients with ARCV.

Left Ventricular Noncompaction

Left ventricular non-compaction (LVNC) is a cardiomyopathy whose pathogenesis probably resides in a failure of myocardial compaction process during fetal development; this mainly results in an excessive trabeculation of myocardial walls, typically divided in a thick trabeculated non-compacted layer and a thin compacted myocardial one [76, 77]. LVNC is probably due to specific genes mutations, with a great genetic variability and since now no genetic test demonstrated acceptable performance [78]. In some cases, other systemic or cardiovascular conditions may develop in association with abnormal trabeculations [79]. Overall, LVNC clinical manifestations can vary from no symptoms to SCD [80]. Thanks to its spatial and contrast resolution, CMR is generally requested to confirm echocardiographic findings, providing better visualization of cardiac morphology, precise ventricular volumes and above all it can detect fibrosis through LGE sequences [81]. Recently, Araujo-Filho et al. have used T1 mapping in tissue characterization of LVNC providing new insights into the pathophysiology of this disease and suggesting a myocardial extracellular expansion by diffuse fibrosis [38]. LVNC patients presented a very low increment of native T1 (1024 ± 43 ms vs. 995 ± 22 ms, P = 0.01) with an elevated ECV (28.0 ± 4.5% vs. 23.5 ± 2.2%, P < 0.001) compared to controls. ECV was also independently associated with LVEF and Vas, over and above LGE, but not with the amount of non-compacted myocardium. Even if these findings suggest that native T1 mapping can be used earlier than LGE for detecting myocardial fibrosis in LVNC patients, the literature is still poor, and more research is needed for its application in a clinical setting.

Inflammatory Cardiomyopathies

Acute myocarditis

Acute myocarditis (AM) is an inflammatory myocardial disease that may be the underlying basis for approximately 10% of dilated cardiomyopathies; furthermore, it is the leading cause of SCD in young people. Although the molecular and cellular pathophysiology may differ between different etiologies, cellular infiltration, oedema, necrosis and (in later stages) fibrotic scars are standard features [82]. The reference standard for diagnosing AM is endomyocardial biopsy. However, CMR, with the aid of the Lake Louise criteria, proposed in 2009 [83] and updated in 2018 [84], is widely used to guide clinical decision-making [85] and has become a non-invasive alternative to confirm the presence of disease. The introduction of T1 mapping increased diagnostic accuracy, discrimination of stages and activity of disease [86]. The Lake-Louise Criteria represented a first step towards a non-invasive diagnosis, while T1 and T2 mapping represent a step forward through a robust, short and quantifiable imaging application [87].

In a first exploratory study Ferreira V et al. compared native T1 values obtained through shMOLLI sequences with the T2wMRI sequences in patients with myocardial oedema [88]. They proved the excellent capability of native T1 sequences in detecting acute myocardial oedema (cut-off > 990 ms) (AUC: 0.94) when related to the use of skeletal muscle referencing (dark blood T2, AUC: 0.89; bright blood T2, AUC 0.84), or remote myocardium referencing (dark blood T2, AUC 0.58; bright blood T2, AUC 0.72). In 2013, the same group demonstrated that in their cohort of patients with clinical myocarditis, native T1 quantification (using the ShMOLLI sequence) had sensitivity, specificity and accuracy of 90%, 91% and 91%, respectively, while LGE sequences showed a specificity of 97% and a sensitivity of 74% [89].

In a recent meta-analysis on studies of patients with myocarditis, the Authors discovered that MRI-T1 values published in the selected papers had a specificity of 87% and an overall sensitivity of 82% in detecting the disease, resulting as the most sensitive MRI parameter [90]. However, regarding CMR predictors of prognosis in myocarditis, the Authors reported that the only independent predictors of MACE were LGE and baseline LVEF.

In another meta-analysis, Kotanidis et al. analysed a different set of studies and reported a diagnostic accuracy for T1 quantification that was superior to all other MRI parameters (AUC:0.95) [91]. Of note, they report an AUC for the original LLC criteria of 0.81.

In a recent prospective single-centre study, Kersten et al. evaluated the importance of CMR in the diagnosis of myocarditis, with particular consideration to absolute T1 values [92]. They discovered a good diagnostic performance of T1 mapping (cutoff > 1019 ms) in recognizing acute myocarditis patients from healthy subjects (AUC: 0.835, sensitivity 73.7%, specificity 72.4%); however, in a sub-cohort of patients where myocarditis was excluded, the established cutoff value had a false-positive rate of 56.6%. The group concluded that T1 mapping could play an important role in the diagnosis of myocarditis; however, the disease should always be diagnosed based on clinical and imaging factors.

Early post-gadolinium chelate–enhanced T1 mapping values have not yet been integrated into the most recent update of Lake Louise criteria because of their limited robustness compared with the other criteria [93], but recently it has been shown that it is a specific marker of acute myocardial inflammation, allowing a pixel-wise quantification of myocardial hyperemia and may potentially improve cardiac MRI accuracy in the diagnosis of acute myocarditis, once integrated with Lake Louise criteria [39]. Among a wide range of cardiovascular manifestations, AM is a possible complication of the severe acute respiratory syndrome coronavirus-2 (SARS-CoV-2) infection responsible for the current COVID-19 pandemic [94, 95]. Myocardial native T1 and T2 measures provided the best discriminatory value against healthy controls and risk factor–matched controls for exclusion of any myocardial disease or confirmation of COVID–19–related involvement, respectively [40]. However, more recently, it has been shown that T2-mapping values increase is the prevalent imaging biomarker of myocardial involvement in active COVID-19 [41].

Cardiac Sarcoidosis

Sarcoidosis is a systemic, inflammatory condition characterized by non-caseating granulomatous infiltration of many different organs. When cardiac involvement is present, patients can experience many different manifestations which can vary from an asymptomatic condition to heart failure and SCD. First line exams such as ECG, electrophysiology testing, echocardiography, and even myocardial perfusion imaging are often not capable to identify this condition because of its patchy nature that is its tendency to affect only some part of the myocardium without impairing LV function. During the last decades, CMR has played a pivotal role in identifying CS, and recently the Heart Rhythm Society has indicated non-ischemic myocardial LGE pattern as an important diagnostic criterion for CS [96]. Unfortunately, in CS regional scar formation is a late-stage consequence of myocardial injury and recently, it has been shown that quantitative CMR may help to detect diffuse fibrosis and inflammation using T1 and T2 mapping [42].

In a recent study, Puntmann et al. evaluated the capability of native T1 and T2 to distinguish patients with cardiac sarcoidosis from healthy controls [42]. In their results, T1 and T2 mapping showed a better diagnostic accuracy (AUC: 0.96 and 0.89, respectively) in detecting CS patients (T1:1139 ± 65 ms; T2: 54 ± 8 ms) from control subjects (T1:1052 ± 34 ms; T2:45 ± 7 ms) when compared with the standard diagnostic criteria (AUC < 0.67). Native T1 was the independent discriminator between health and disease (specificity, 90%; sensitivity, 96%; accuracy, 94%). Furthermore, they also observed a significant reduction of native T1 and T2 in a follow-up subgroup of patients who underwent treatment (z score: -3.72 and -2.88; P < 0.01). T1 and T2 mapping may enable noninvasive detection of cardiac involvement and activity of inflammation in patients with systemic sarcoidosis.

More recently, Cheung et al. explored the diagnostic performance of Hybrid cardiac ^{18}F-fluorodeoxyglucose (FDG) PET/MRI with T1/T2 mapping in the detection of suspected CS [97]. FDG uptake (69%), FDG uptake co-localizing with LGE (76%) and elevated T2 (79%) reached a specificity of 69%,7 = % and 79% respectively; while sensitivity was highest for LGE, elevated T1 and ECV (100%). Moreover, native T1, FDG uptake, and elevated T2 and resulted being significant predictors of MACE. In Authors opinion, FDG-PET/MRI with T1/T2 mapping could provide important complementary information and predict MACE in patients with suspected CS.

Infiltrative Cardiomyopathies

Cardiac Amyloidosis

Cardiac amyloidosis (CA) is a rare infiltrative disorder in which abnormally folded proteins are deposited within the myocardium, and it can be regarded as the exemplar of an interstitial disease [98]. LGE is one of the first histologically proven methods for non-invasively detecting CA, and it occurs when gadolinium contrast distributes into the extracellular space without entering intact myocardial cells [99]. Patients with CA present circumferential subendocardial LGE in 80% of cases, particularly evident at the base and mid-ventricle segments, while the rest shows various LGE patterns. The characteristic diffuse LGE enhancement makes nulling of normal myocardium particularly difficult, often leading to confusion in interpretation [100, 101]. T1 mapping, circumventing the limitations of myocardial nulling, provides a quantitative assessment of diffuse extracellular expansion and is a viable option in renal failure, common with amyloid. When conducted sequentially, this approach can serve as a valuable method for tracking treatment responses and shifts in myocardial burden over time [102]. Fontana et al. demonstrated that both types of CA show markedly

elevated native T1 values (ATTR T1 values: 1097 ± 43 ms), higher than normal subjects (967 ± 34 ms) and HCM patients (1026 ± 64 ms) ($p < 0.0001$) [43]. However, in established cardiac ATTR amyloidosis, T1 elevation was not as high as in AL amyloidosis (AL 1130 ± 68 ms; $p = 0.01$). Through these observations, the group demonstrated how, using native T1, cardiac amyloidosis could be reliably diagnosed and differentiated from other aetiologies of LVH, such as HCM, a clinically relevant differential diagnosis. The widespread infiltration of the interstitial space by the folded proteins in cardiac amyloidosis is the cause of the extremely high ECV values (0.466), more than in other cardiomyopathies [103]. A recent meta-analysis by Pan et al., compared diagnostic and prognostic performance of Native T1, ECV and LGE for CA [104]. Their results suggest that ECV may have better performances than LGE, while T1 mapping was comparable to other modalities in terms of sensitivity and specificity for diagnosing CA without requiring contrast material.

Anderson-Fabry Disease

A complete or partial α-galactosidase A enzyme deficiency is the cause of Anderson-Fabry disease, (AFD) a multisystem lysosomal storage condition transmitted via X-linked inheritance; the enzyme deficiency determines progressive intracellular accumulation of glycosphingolipids in multiple organs [105]. Long-term accumulation of glycosphingolipids in the myocardium causes LVH and myocardial fibrosis, which led to different symptoms and complications, such as arrhythmias, valvular dysfunction, and CAD [106]. CMR represents the best imaging modality for a comprehensive evaluation of cardiac involvement in this condition [107, 108]. LGE sequences can identify and quantify myocardial fibrosis which is considered an essential prognostic factor to provide risk stratification in AFD patients [109]. However, LGE cannot be considered a very early biomarker to be used for the identification of myocardial involvement in AFD and to start treatment with the recombinant enzyme.

Sado et al. have shown a low mean septal T1 in AFD [44]. They explored the potential of noncontrast T1 mapping to detect early cardiac involvement and distinguish AFD LVH from other causes. Beyond AFD patients they recruited patients affected by left ventricular hypertrophy of different aetiologies (hypertension, aortic stenosis, HCM) and healthy controls. Compared with controls (968 ± 32 ms), septal T1 was lower in AFD (882 ± 47 ms) and higher in other diseases (1018 ± 74 ms; $P < 0.0001$). Furthermore, in patients with LVH, T1 absolutely distinguishes AFD from other common causes with no apparent overlap. Noncontrast T1 mapping septal assessment could represent a simple, safe, quick, and useful tool in the diagnostic workup of LVH and the detection of early cardiac involvement in AFD, with potential for therapy monitoring [44]. These results have been confirmed by a recent metanalysis by Ponsiglione et al. aimed to determine the weighted mean native T1 values of AFD patients [110]. Overall, the weighted mean native T1 value was 984 ± 47 ms in AFD patients and 1016 ± 26 ms in healthy subjects ($P < 0.0001$). These findings confirmed a reduction of native T1 values in AFD patients compared to healthy volunteers, even if there is a need to standardize threshold values according to imaging equipment and protocols.

T1 values in the infero-lateral wall are frequently higher than in 'remote' myocardium (i.e. myocardium not including the infero-lateral wall), probably because the inferolateral wall myocardium in AFD undergoes a 4-phase transition from normal value (pre-detectable storage) to a low-value (storage) to pseudonormal value (storage + fibrosis) to a high value (fibrosis) [44]. It has been recently shown that the use of hybrid PET-MR imaging in AFD patients allows to detect different stages of disease progression [111–113].

Cardiac Siderosis

Cardiac siderosis or myocardial iron overload is a rare cardiac condition, but it can occur in states such as thalassemia or hemochromatosis; without treatment, it is associated with a significant risk of death and heart failure [114]. To date, T2* has been the most used technique to assess cardiac iron load non-invasively; T2* would be normal above 40 ms-but in practice, a threshold of 20 ms is used to avoid false positives [115]. Some researchers have explored T1 mapping in cardiac siderosis in-vivo, demonstrating superior inter-study reproducibility and T1 reclassification of a significant proportion of patients as having mild iron overload [45, 116]. Alam et al. compared the established 1.5 T BB T2* technique against native T1 values at 1.5 T and 3 T in cardiac siderosis patients and in healthy controls [45]. Iron overload patients (1.5 T T2* values < 20 ms) demonstrated native T1 values < 939 ms at 1.5 T, and < 1056 ms at 3 T, while controls presented a median native T1of 1014 ms (939–1059 ms) at 1.5 T and of 1165 ms (1056–1224 ms) at 3 T. Associations between T2* and T1 were found to be moderate, and T1 reproducibility appeared higher than T2*. The group concluded that T1 mapping has the potential to identify patients with significant iron overload. However, there is a significant scatter between results, probably because of measurement errors, interactions between T1 and T2*, or T1 could have a different sensitivity to iron chemistry. The scanner inter-center variation in absolute T1 values and the lack of calibration against human myocardial iron concentration are some of the limitations that slow its clinical application. Recently, similar results were obtained by another research group that compared T1 mapping using ShMOLLI with a T2* technique [116]. Native T1 was lower in iron overload patients than healthy controls (836 ± 138 ms vs. 968 ± 32 ms, $P < 0.0001$). Even in this

case, interstudy reproducibility of native T1 was significantly superior to T2*, with the results suggesting T1 has potential implications for clinical trial design and therapeutic monitoring. More recently, it has been suggested that in the T2* 20-30 ms range, there might be iron load that is still undetected by this method; in this scenario, T1 measurement at 3 T could be capable of identifying even small amounts of iron accumulating in the heart [45, 117].

T1 Mapping in Valvular Disease

An overview of the main studies with T1 mapping/ECV in valvular disease is presented in Table 6.

Aortic Stenosis

Aortic stenosis (AS) stands out as one of the prevalent valvular disorders, associated with elevated mortality rates [120]. Prolonged pressure overload on the left ventricle (LV) ultimately results in the deterioration of cardiomyocytes and the emergence of reactive fibrosis. The extent of myocardial fibrosis closely aligns with the progression of the disease and serves as a reliable predictor of adverse clinical outcomes in AS [121]. While LGE is a recognized marker of replacement fibrosis, it falls short in identifying the diffuse interstitial fibrosis associated with left ventricular decompensation in AS. Additionally, accurately quantifying LGE in cases of diffuse fibrosis poses challenges. To address these limitations, CMR T1 mapping techniques have been devised in AS setting [118, 122].

Lee et al. in their prospective study assessed whether native T1 values could predict clinical events in 127 patients with AS compared to 33 matched controls who underwent CMR imaging [118]. The Authors showed AS patients had higher native T1 values compared to controls (1232 vs. 1185 ms; $p = 0.008$). Elevated native T1 values were associated with an increased risk of clinical events, even when LGE was considered.

In a more recent multicenter, prospective investigation, Everett and colleagues aimed to explore the relationship between ECV fraction (ECV%) and markers of left ventricular decompensation in patients with severe AS, as well as its impact on post-intervention clinical outcomes [122]. The results indicated that ECV% was associated with various markers of LV decompensation, including LV mass, left atrial volume, New York Heart Association functional class III/IV, LGE, and reduced LVEF. Importantly, ECV% independently correlated with cardiovascular mortality and all-cause mortality during a median follow-up of 3.8 years, even after adjusting for factors such as age, sex, EF, and LGE.

Mitral Prolapse

Mitral valve prolapse (MVP) is a relatively common condition typically associated with a favorable overall prognosis,

Table 6 An overview of the main studies with T1 mapping/ECV in valvular diseases

First author	Publication year	Aim of the study	Study design	Sample size	Main outcome
Lee et al [118]	2018	To investigate whether the native T1 values of myocardial tissue, as assessed by CMR, could predict clinical events in patients with significant AS	Prospective, single center	127 # 33^	Elevated native T1 values represent an independent predictor of adverse outcomes in patients with AS
Pavon et al. [119]	2021	To explore the relationship between the severity of MAD and myocardial interstitial fibrosis in patients with MVP, and the association between interstitial fibrosis and VA	Retrospective, single center	30° 14 * 10 §	Elevated basal segments ECV is evident in MVP-MAD patients, even when LGE is not present, and this elevation is associated with the length of MAD and an elevated risk of out-of-hospital cardiac arrest

CMR cardiac magnetic resonance; *AS* aortic stenosis; *MAD* mitral annular disjunction; *MVP* mitral valve prolapse; *VA* ventricular arrhythmia; *LGE* late gadolinium enhancement

#patients with AS

^healthy controls

°patients with MVP and MAD

*patients without MVP, with mitral regurgitation

§patients without MVP and mitral regurgitation

showing an approximate prevalence of 2% in Western populations [123]. However, recent discoveries have indicated a potential link between MVP and VA, along with an elevated risk of SCD [124]. Consequently, terms like "arrhythmic" or "malignant" MVP have been introduced to characterize this new aspect of the condition [124]. Fibrosis affecting the papillary muscles and the inferolateral LV wall, possibly induced by the stretching caused by the prolapsing leaflets, is believed to serve as the structural foundation for ventricular arrhythmias [125]. Guglielmo et al. in their single center prospective study aimed to assess the use of T1 mapping and CMR feature tracking (CMR-FT) techniques in detecting subclinical myocardial structural changes in 73 MVP patients compared to 42 matched control subjects [126]. MVP patients exhibited lower global circumferential strain and longer global native T1 (nT1) values compared to controls (1124.9 ± 97.7 ms vs. 1007.4 ± 26.1 ms, $P < 0.001$). Furthermore, MVP patients displayed reduced radial and circumferential strain in the basal and mid-inferolateral walls. The same regions also exhibited longer nT1 values.

In a more recent investigation, Pavon and colleagues explored the relationship between the severity of mitral annular disjunction (MAD) and myocardial interstitial fibrosis in patients with MVP, as well as the association between interstitial fibrosis and the occurrence of ventricular arrhythmic events [119]. The retrospective study included 30 MVP patients with MAD, 14 patients with mitral regurgitation (MR) but no MAD, and 10 patients with normal CMR. LGE was observed in 47% of MVP-MAD patients, and ECV of the basal segments (ECVsyn) was higher in MVP-MAD patients (30 ± 3% vs 24 ± 3% MR-NoMAD and vs 24 ± 2% NoMR-NoMAD, all $P < 0.001$) even those without LGE. Furthermore, patients with high ECVsyn were at increased risk of out-of-hospital cardiac arrest.

Conclusions

Tissue characterization through T1 mapping with CMR imaging has emerged as a crucial tool with broad implications for diagnostic, therapeutic, and prognostic decisions in various cardiac diseases. Native T1 mapping allows continuous monitoring of myocardial tissue changes over time, making it valuable for patients with cardiomyopathies. Importantly, it offers a suitable alternative for patients with poor renal function or those on dialysis who cannot receive gadolinium-based contrast agents. Studies have consistently highlighted the clinical utility of T1 mapping, particularly in cardiac diseases associated with diffuse fibrosis. Additionally, T1 mapping, often combined with ECV measurement, serves as an adjunct in cases where LGE imaging results may be ambiguous. However, challenges persist in interpreting T1 and ECV values, given their overlap between different cardiomyopathies and normal values. Interpretation must be context-specific, considering clinical factors, pre-test probabilities, and complementary CMR techniques like LGE. To further unlock the potential of T1 mapping and ECV measurement, ongoing research aims to standardize acquisition protocols across different vendors and institutions. These efforts seek to establish normative values and pathological thresholds, making T1 mapping more consistent and widely applicable in CMR centers.

Author Contributions Conceptualization, A.P., R.A. and M.I., methodology, A.P., C.N. and M.I.; writing—original draft preparation, R.A. M.D.G. and G.D.C., writing—review and editing, R.A., A.P., S.D.A. and M.I.; Figure and Tables preparation, M.D.G, S.D.A and G.D.C; supervision, C.N., M.I. and A.P. All authors have read and agreed to the published version of the manuscript.

Funding Open access funding provided by Università degli Studi di Napoli Federico II within the CRUI-CARE Agreement. No funding was received.

Declarations

Competing Interests The authors declare no competing interests.

Ethical Approval Not applicable.

Human and Animal Rights and Informed Consent This article does not contain any studies with human or animal subjects performed by any of the authors.

References

Papers of particular interest, published recently, have been highlighted as:
• Of importance

1. Hundley WG. The use of cardiovascular magnetic resonance to identify adverse cardiac prognosis: an important step in reducing image-related health care expenditures. J Am Coll Cardiol. 2010;56(15):1244–6. https://doi.org/10.1016/J.JACC.2010.07.011.

2. Hunold P, et al. Myocardial late enhancement in contrast-enhanced cardiac MRI: distinction between infarction scar and non-infarction-related disease. AJR Am J Roentgenol. 2005;184(5):1420–6. https://doi.org/10.2214/AJR.184.5.01841420.
3. Mewton N, Liu CY, Croisille P, Bluemke D, Lima JAC. Assessment of myocardial fibrosis with cardiovascular magnetic resonance. J Am Coll Cardiol. 2011;57(8):891–903. https://doi.org/10.1016/J.JACC.2010.11.013.
4. Parsai C, Ohanlon R, Prasad SK, Mohiaddin RH. Diagnostic and prognostic value of cardiovascular magnetic resonance in non-ischaemic cardiomyopathies. J Cardiovasc Magn Reson. 2012;14(1). https://doi.org/10.1186/1532-429X-14-54.
5. Haaf P, Garg P, Messroghli DR, Broadbent DA, Greenwood JP, Plein S. Cardiac T1 Mapping and Extracellular Volume (ECV) in clinical practice: a comprehensive review. J Cardiovasc Magn Reson. 2016;18(1). https://doi.org/10.1186/S12968-016-0308-4.
6. Kawel N, et al. T1 mapping of the myocardium: Intra-individual assessment of post-contrast T1 time evolution and extracellular volume fraction at 3T for Gd-DTPA and Gd-BOPTA. J Cardiovasc Magn Reson. 2012;14(1). https://doi.org/10.1186/1532-429X-14-26.
7. Kawel N, et al. T1 mapping of the myocardium: intra-individual assessment of the effect of field strength, cardiac cycle and variation by myocardial region. J Cardiovasc Magn Reson. 2012;14(1). https://doi.org/10.1186/1532-429X-14-27.
8. Bull S, et al. Human non-contrast T1 values and correlation with histology in diffuse fibrosis. Heart. 2013;99(13):932–7. https://doi.org/10.1136/HEARTJNL-2012-303052.
9. Sado DM, et al. Identification and assessment of Anderson-Fabry disease by cardiovascular magnetic resonance noncontrast myocardial T1 mapping. Circ Cardiovasc Imaging. 2013;6(3):392–8. https://doi.org/10.1161/CIRCIMAGING.112.000070.
10. Alam MH, et al. T1 at 1.5T and 3T compared with conventional T2* at 1.5T for cardiac siderosis. J Cardiovasc Magn Reson. 2015;17(1). https://doi.org/10.1186/S12968-015-0207-0.
11. Ferreira VM, et al. Non-contrast T1-mapping detects acute myocardial edema with high diagnostic accuracy: a comparison to T2-weighted cardiovascular magnetic resonance. J Cardiovasc Magn Reson. 2012;14(1). https://doi.org/10.1186/1532-429X-14-42.
12. Messroghli DR, Radjenovic A, Kozerke S, Higgins DM, Sivananthan MU, Ridgway JP. Modified Look-Locker inversion recovery (MOLLI) for high-resolution T1 mapping of the heart. Magn Reson Med. 2004;52(1):141–6. https://doi.org/10.1002/MRM.20110.
13. Lee JJ, et al. Myocardial T1 and extracellular volume fraction mapping at 3 tesla. J Cardiovasc Magn Reson. 2011;13(1). https://doi.org/10.1186/1532-429X-13-75.
14. Lipinski MJ, McVey CM, Berger JS, Kramer CM, Salerno M. Prognostic value of stress cardiac magnetic resonance imaging in patients with known or suspected coronary artery disease: a systematic review and meta-analysis. J Am Coll Cardiol. 2013;62(9):826–38. https://doi.org/10.1016/J.JACC.2013.03.080.
15. Piechnik SK, et al. Shortened Modified Look-Locker Inversion recovery (ShMOLLI) for clinical myocardial T1-mapping at 1.5 and 3 T within a 9 heartbeat breathhold. J Cardiovasc Magn Reson. 2010;12(1). https://doi.org/10.1186/1532-429X-12-69.
16. Kellman P, et al. Extracellular volume fraction mapping in the myocardium, part 2: Initial clinical experience. J Cardiovasc Magn Reson. 2012;14(1). https://doi.org/10.1186/1532-429X-14-64.
17. Schmitt P, et al. Inversion recovery TrueFISP: quantification of T(1), T(2), and spin density. Magn Reson Med. 2004;51(4):661–7. https://doi.org/10.1002/MRM.20058.
18. Higgins DM, Ridgway JP, Radjenovic A, Sivananthan UM, Smith MA. T1 measurement using a short acquisition period for quantitative cardiac applications. Med Phys. 2005;32(6):1738–46. https://doi.org/10.1118/1.1921668.
19. Chow K, Flewitt JA, Green JD, Pagano JJ, Friedrich MG, Thompson RB. Saturation recovery single-shot acquisition (SASHA) for myocardial T1 mapping. Magn Reson Med. 2014;71(6):2082–95. https://doi.org/10.1002/MRM.24878.
20. Sado DM, et al. Cardiovascular magnetic resonance measurement of myocardial extracellular volume in health and disease. Heart. 2012;98(19):1436–41. https://doi.org/10.1136/HEARTJNL-2012-302346.
21.• Ma Q, Ma Y, Yu T, Sun Z, Hou Y. Radiomics of Non-Contrast-Enhanced T1 Mapping: Diagnostic and Predictive Performance for Myocardial Injury in Acute ST-Segment-Elevation Myocardial Infarction. Korean J Radiol. 2021;22(4):535–46. https://doi.org/10.3348/KJR.2019.0969. **In this research study the Authors assessed the viability of employing texture analysis on non-contrast-enhanced T1 maps with CMR imaging to diagnose myocardial injury for the diagnosis of myocardial injury in acute myocardial infarction. Integrating radiomics analysis of non-contrast-enhanced T1 mapping with T1 values showed the potential to significantly enhance diagnostic accuracy for microvascular obstruction.**
22. Wang G, et al. Multicenter Study on the Diagnostic Performance of Native-T1 Cardiac Magnetic Resonance of Chronic Myocardial Infarctions at 3T. Circ Cardiovasc Imaging. 2020;13(6):E009894. https://doi.org/10.1161/CIRCIMAGING.119.009894.
23. Kaolawanich Y, et al. Native T1 Mapping for the Diagnosis of Myocardial Fibrosis in Patients With Chronic Myocardial Infarction. Cardiovasc Imaging. 2022;15(12):2069–79. https://doi.org/10.1016/J.JCMG.2022.09.011.
24. Ibanez B, et al. 2017 ESC Guidelines for the management of acute myocardial infarction in patients presenting with ST-segment elevation: The Task Force for the management of acute myocardial infarction in patients presenting with ST-segment elevation of the European Society of Cardiology (ESC). Eur Heart J. 2018;39(2):119–77. https://doi.org/10.1093/EURHEARTJ/EHX393.
25. Dall'Armellina E, Karamitsos TD, Neubauer S, Choudhury RP. CMR for characterization of the myocardium in acute coronary syndromes. Nat Rev Cardiol. 2010;7(11):624–36. https://doi.org/10.1038/NRCARDIO.2010.140.
26. Dall'Armellina E, et al. Cardiovascular magnetic resonance by non contrast T1-mapping allows assessment of severity of injury in acute myocardial infarction. J Cardiovasc Magn Reson. 2012;14(1). https://doi.org/10.1186/1532-429X-14-15.
27. O h-Ici D, et al. T1 mapping in ischaemic heart disease. Eur Heart J Cardiovasc Imaging. 2014;15(6):597–602. https://doi.org/10.1093/EHJCI/JEU024.
28. Kim RJ, et al. The use of contrast-enhanced magnetic resonance imaging to identify reversible myocardial dysfunction. N Engl J Med. 2000;343(20):1445–53. https://doi.org/10.1056/NEJM200011163432003.
29. Dall'Armellina E, et al. Dynamic changes of edema and late gadolinium enhancement after acute myocardial infarction and their relationship to functional recovery and salvage index. Circ Cardiovasc Imaging. 2011;4(3):228–36. https://doi.org/10.1161/CIRCIMAGING.111.963421.
30. Engblom H, Hedstrom̈ E, Heiberg E, Wagner GS, Pahlm O, Arheden H. Rapid Initial Reduction of Hyperenhanced Myocardium After Reperfused First Myocardial Infarction Suggests Recovery of the Peri-Infarction Zone. Circ Cardiovasc Imaging. 2009;2(1):47–55. https://doi.org/10.1161/CIRCIMAGING.108.802199.

31. Liu D, et al. CMR Native T1 Mapping Allows Differentiation of Reversible Versus Irreversible Myocardial Damage in ST-Segment-Elevation Myocardial Infarction: An OxAMI Study (Oxford Acute Myocardial Infarction). Circ Cardiovasc Imaging. 2017;10(8). https://doi.org/10.1161/CIRCIMAGING.116.005986.
32. Alkhalil M, et al. Hyper-acute cardiovascular magnetic resonance T1 mapping predicts infarct characteristics in patients with ST elevation myocardial infarction. J Cardiovasc Magn Reson. 2020;22(1). https://doi.org/10.1186/S12968-019-0593-9.
33. Puntmann VO, et al. T1-Mapping and Outcome in Nonischemic Cardiomyopathy: All-Cause Mortality and Heart Failure. JACC Cardiovasc Imaging. 2016;9(1):40–50. https://doi.org/10.1016/J.JCMG.2015.12.001.
34. Cadour F, et al. Prognostic value of cardiovascular magnetic resonance T1 mapping and extracellular volume fraction in nonischemic dilated cardiomyopathy. J Cardiovasc Magn Reson. 2023;25(1). https://doi.org/10.1186/S12968-023-00919-Y.
35. Aikawa Y, et al. Clinical impact of native T1 mapping for detecting myocardial impairment in takotsubo cardiomyopathy. Eur Heart J Cardiovasc Imaging. 2019;20(10):1147–55. https://doi.org/10.1093/EHJCI/JEZ034.
36. Liang L, et al. T1 Mapping and Extracellular Volume in Cardiomyopathy Showing Left Ventricular Hypertrophy: Differentiation Between Hypertrophic Cardiomyopathy and Hypertensive Heart Disease. Int J Gen Med. 2022;15:4163. https://doi.org/10.2147/IJGM.S350673.
37. Bourfiss M, et al. Diagnostic Value of Native T1 Mapping in Arrhythmogenic Right Ventricular Cardiomyopathy. JACC Cardiovasc Imaging. 2019;12(8P1):1580–2. https://doi.org/10.1016/J.JCMG.2019.01.023.
38. Araujo-Filho JAB, et al. Myocardial T1 mapping and extracellular volume quantification in patients with left ventricular noncompaction cardiomyopathy. Eur Heart J Cardiovasc Imaging. 2018;19(8):888–95. https://doi.org/10.1093/ehjci/jey022.
39. Palmisano A, et al. Early T1 Myocardial MRI Mapping: Value in Detecting Myocardial Hyperemia in Acute Myocarditis. Radiology. 2020;295(2):316–25. https://doi.org/10.1148/radiol.2020191623.
40. Puntmann VO, et al. Outcomes of Cardiovascular Magnetic Resonance Imaging in Patients Recently Recovered From Coronavirus Disease 2019 (COVID-19). JAMA Cardiol. 2020;5(11):1265. https://doi.org/10.1001/jamacardio.2020.3557.
41. Galea N, et al. T2-mapping increase is the prevalent imaging biomarker of myocardial involvement in active COVID-19: a Cardiovascular Magnetic Resonance study. J Cardiovasc Magn Reson. 2021;23(1):68. https://doi.org/10.1186/s12968-021-00764-x.
42. Puntmann VO, Isted A, Hinojar R, Foote L, Carr-White G, Nagel E. T1 and T2 Mapping in Recognition of Early Cardiac Involvement in Systemic Sarcoidosis. Radiology. 2017;285(1):63–72. https://doi.org/10.1148/radiol.2017162732.
43. Fontana M, et al. Native T1 Mapping in Transthyretin Amyloidosis. JACC Cardiovasc Imaging. 2014;7(2):157–65. https://doi.org/10.1016/j.jcmg.2013.10.008.
44. Sado DM, et al. Identification and Assessment of Anderson-Fabry Disease by Cardiovascular Magnetic Resonance Noncontrast Myocardial T1 Mapping. Circ Cardiovasc Imaging. 2013;6(3):392–8. https://doi.org/10.1161/CIRCIMAGING.112.000070.
45. Alam MH, et al. T1 at 1.5T and 3T compared with conventional T2* at 1.5T for cardiac siderosis. J Cardiovasc Magn Reson. 2015;17(1):102. https://doi.org/10.1186/s12968-015-0207-0.
46. Jj M, et al. Angiotensin-neprilysin inhibition versus enalapril in heart failure. N Engl J Med. 2014;371(11):132–3. https://doi.org/10.1056/NEJMOA1409077.
47. Gulati A, Ismail TF, Prasad SK. Fibrosis and mortality in patients with dilated cardiomyopathy–reply. JAMA. 2013;309(24):2548–9. https://doi.org/10.1001/JAMA.2013.6467.
48. Wu KC, et al. Late gadolinium enhancement by cardiovascular magnetic resonance heralds an adverse prognosis in nonischemic cardiomyopathy. J Am Coll Cardiol. 2008;51(25):2414–21. https://doi.org/10.1016/J.JACC.2008.03.018.
49. De Leeuw N, Ruiter DJ, Balk AHMM, De Jonge N, Melchers WJG, Galama JMD. Histopathologic findings in explanted heart tissue from patients with end-stage idiopathic dilated cardiomyopathy. Transpl Int. 2001;14(5):299–306. https://doi.org/10.1007/S001470100339.
50. Spiewak M, et al. Comparison of different quantification methods of late gadolinium enhancement in patients with hypertrophic cardiomyopathy. Eur J Radiol. 2010;74(3). https://doi.org/10.1016/J.EJRAD.2009.05.035.
51.• Vita T, et al. Comparing CMR Mapping Methods and Myocardial Patterns Toward Heart Failure Outcomes in Nonischemic Dilated Cardiomyopathy. JACC Cardiovasc Imaging. 2019;12(8 Pt 2):1659–69. https://doi.org/10.1016/J.JCMG.2018.08.021. **In this comprehensive study involving 240 individuals with non-ischemic dilated cardiomyopathy undergoing CMR, the Authors revealed that quantifying myocardial abnormality through ECV mapping provides an additional layer of prognostic value for predicting heart failure outcomes, beyond the information offered by LGE or native T1 mapping alone.**
52.• Nakamori S, et al. Native T1 Mapping and Extracellular Volume Mapping for the Assessment of Diffuse Myocardial Fibrosis in Dilated Cardiomyopathy. JACC Cardiovasc Imaging. 2018;11(1):48–59. https://doi.org/10.1016/J.JCMG.2017.04.006. **This study examined the histological correlation between native measurement of myocardial T1 and ECV for the evaluation of diffuse pathological changes in myocardial tissue in dilated cardiomyopathy. The Authors found that native T1 has similar abilities to ECV in the detection and quantification of histological collagen volume fraction, allowing reliable evaluation without the administration of gadolinium contrast agent.**
53. Bossone E, et al. Takotsubo cardiomyopathy: overview. Heart Fail Clin. 2013;9(2):249–66. https://doi.org/10.1016/J.HFC.2012.12.015.
54. Ferreira VM, et al. Non-contrast T1-mapping detects acute myocardial edema with high diagnostic accuracy: a comparison to T2-weighted cardiovascular magnetic resonance. J Cardiovasc Magn Reson. 2012;14(1). https://doi.org/10.1186/1532-429X-14-42.
55. Ommen SR, et al. 2020 AHA/ACC Guideline for the Diagnosis and Treatment of Patients With Hypertrophic Cardiomyopathy: Executive Summary. Circulation. 2020;142(25):E533–57. https://doi.org/10.1161/CIR.0000000000000938.
56. Losi M, et al. Left Ventricular Mass in Hypertrophic Cardiomyopathy Assessed by 2D-Echocardiography: Validation with Magnetic Resonance Imaging. J Cardiovasc Transl Res. 2020;13(2):238–44. https://doi.org/10.1007/s12265-019-09911-3.
57. Heliö T, et al. ESC EORP Cardiomyopathy Registry: real-life practice of genetic counselling and testing in adult cardiomyopathy patients. ESC Heart Fail. 2020;7(5):3013–21. https://doi.org/10.1002/EHF2.12925.
58.• Avanesov M, et al. Prediction of the estimated 5-year risk of sudden cardiac death and syncope or non-sustained ventricular tachycardia in patients with hypertrophic cardiomyopathy using late gadolinium enhancement and extracellular volume CMR. Eur Radiol. 2017;27(12):5136–45. https://doi.org/10.1007/S00330-017-4869-X/METRICS. **In this research study, a group of 73 individuals with hypertrophic cardiomyopathy**

(HCM) was compared with a control group comprising 16 healthy participants, all of whom underwent a 1.5-T CMR. The Authors showed that by integrating the "sudden cardiac death risk score" with global ECV, there exists a promising opportunity to enhance the process of selecting HCM patients who would derive the most benefit from implantable cardioverter defibrillators.

59. Mentias A, et al. Late Gadolinium Enhancement in Patients With Hypertrophic Cardiomyopathy and Preserved Systolic Function. J Am Coll Cardiol. 2018;72(8):857–70. https://doi.org/10.1016/J.JACC.2018.05.060.
60. Chan RH, et al. Prognostic value of quantitative contrast-enhanced cardiovascular magnetic resonance for the evaluation of sudden death risk in patients with hypertrophic cardiomyopathy. Circulation. 2014;130(6):484–95. https://doi.org/10.1161/CIRCULATIONAHA.113.007094.
61. Zeppenfeld K, et al. 2022 ESC Guidelines for the management of patients with ventricular arrhythmias and the prevention of sudden cardiac death. Eur Heart J. 2022;43(40):3997–4126. https://doi.org/10.1093/EURHEARTJ/EHAC262.
62. Todiere G, et al. Progression of myocardial fibrosis assessed with cardiac magnetic resonance in hypertrophic cardiomyopathy. J Am Coll Cardiol. 2012;60(10):922–9. https://doi.org/10.1016/J.JACC.2012.03.076.
63. Qin L, et al. Incremental Values of T1 Mapping in the Prediction of Sudden Cardiac Death Risk in Hypertrophic Cardiomyopathy: A Comparison With Two Guidelines. Front Cardiovasc Med. 2021;8:661673. https://doi.org/10.3389/FCVM.2021.661673.
64. Li Y, et al. Prognostic value of myocardial extracellular volume fraction evaluation based on cardiac magnetic resonance T1 mapping with T1 long and short in hypertrophic cardiomyopathy. Eur Radiol. 2021;31(7):4557–67. https://doi.org/10.1007/S00330-020-07650-7.
65. Kumar V, et al. Radiomics: the process and the challenges. Magn Reson Imaging. 2012;30(9):1234–48. https://doi.org/10.1016/j.mri.2012.06.010.
66. Ponsiglione A, et al. Cardiac CT and MRI radiomics: systematic review of the literature and radiomics quality score assessment. Eur Radiol. 2022;32(4):2629–38. https://doi.org/10.1007/s00330-021-08375-x.
67. Pu C, et al. Identification of fibrosis in hypertrophic cardiomyopathy: a radiomic study on cardiac magnetic resonance cine imaging. Eur Radiol. 2023;33(4). https://doi.org/10.1007/S00330-022-09217-0.
68. Neisius U, et al. Texture Signatures of Native Myocardial T1 as Novel Imaging Markers for Identification of Hypertrophic Cardiomyopathy Patients Without Scar. J Magn Reson Imaging. 2020;52(3):906. https://doi.org/10.1002/JMRI.27048.
69. Antonopoulos AS, et al. Machine learning of native T1 mapping radiomics for classification of hypertrophic cardiomyopathy phenotypes. Sci Rep. 2021;11(1):1–11. https://doi.org/10.1038/s41598-021-02971-z.
70. Corrado D, Link MS, Calkins H. Arrhythmogenic Right Ventricular Cardiomyopathy. N Engl J Med. 2017;376(1):61–72. https://doi.org/10.1056/NEJMRA1509267.
71. Ponsiglione A, et al. A unique association of arrhythmogenic right ventricular dysplasia and acute myocarditis, as assessed by cardiac MRI: a case report. BMC Cardiovasc Disord. 2016;16(1):230. https://doi.org/10.1186/s12872-016-0412-2.
72. Corrado D, et al. Arrhythmogenic right ventricular cardiomyopathy: evaluation of the current diagnostic criteria and differential diagnosis. Eur Heart J. 2020;41(14):1414–1427b. https://doi.org/10.1093/EURHEARTJ/EHZ669.
73. Aquaro GD, et al. Prognostic Value of Magnetic Resonance Phenotype in Patients With Arrhythmogenic Right Ventricular Cardiomyopathy. J Am Coll Cardiol. 2020;75(22):2753–65. https://doi.org/10.1016/J.JACC.2020.04.023.
74. Miles C, et al. Sudden Death and Left Ventricular Involvement in Arrhythmogenic Cardiomyopathy. Circulation. 2019;139(15):1786–97. https://doi.org/10.1161/CIRCULATIONAHA.118.037230.
75. Georgiopoulos G, et al. Cardiac magnetic resonance in patients with ARVC and family members: the potential role of native T1 mapping. Int J Cardiovasc Imaging. 2021;37(6):2037–47. https://doi.org/10.1007/S10554-021-02166-7.
76. Maron BJ, et al. Contemporary Definitions and Classification of the Cardiomyopathies. Circulation. 2006;113(14):1807–16. https://doi.org/10.1161/CIRCULATIONAHA.106.174287.
77. Arbustini E, Weidemann F, Hall JL. Left Ventricular Noncompaction. J Am Coll Cardiol. 2014;64(17):1840–50. https://doi.org/10.1016/j.jacc.2014.08.030.
78. Gati S, Rajani R, Carr-White GS, Chambers JB. Adult Left Ventricular Noncompaction. JACC Cardiovasc Imaging. 2014;7(12):1266–75. https://doi.org/10.1016/j.jcmg.2014.09.005.
79. Gati S, et al. Reversible De Novo Left Ventricular Trabeculations in Pregnant Women. Circulation. 2014;130(6):475–83. https://doi.org/10.1161/CIRCULATIONAHA.114.008554.
80. Andreini D, et al. Long-Term Prognostic Value of Cardiac Magnetic Resonance in Left Ventricle Noncompaction. J Am Coll Cardiol. 2016;68(20):2166–81. https://doi.org/10.1016/j.jacc.2016.08.053.
81. Kawel N, et al. Trabeculated (Noncompacted) and Compact Myocardium in Adults. Circ Cardiovasc Imaging. 2012;5(3):357–66. https://doi.org/10.1161/CIRCIMAGING.111.971713.
82. Caforio ALP, et al. Current state of knowledge on aetiology, diagnosis, management, and therapy of myocarditis: a position statement of the European Society of Cardiology Working Group on Myocardial and Pericardial Diseases. Eur Heart J. 2013;34(33):2636–48. https://doi.org/10.1093/eurheartj/eht210.
83. Friedrich MG, et al. Cardiovascular Magnetic Resonance in Myocarditis: A JACC White Paper. J Am Coll Cardiol. 2009;53(17):1475–87. https://doi.org/10.1016/j.jacc.2009.02.007.
84. Ferreira VM, et al. Cardiovascular Magnetic Resonance in Nonischemic Myocardial Inflammation. J Am Coll Cardiol. 2018;72(24):3158–76. https://doi.org/10.1016/j.jacc.2018.09.072.
85. Imbriaco M, et al. Assessment of acute myocarditis by cardiac magnetic resonance imaging: Comparison of qualitative and quantitative analysis methods. J Nucl Cardiol. 2019;26(3):857–65. https://doi.org/10.1007/s12350-017-1109-3.
86. Hinojar R, Nagel E, Puntmann VO. T1 mapping in myocarditis – headway to a new era for cardiovascular magnetic resonance. Expert Rev Cardiovasc Ther. 2015;13(8):871–4. https://doi.org/10.1586/14779072.2015.1051035.
87. Puntmann VO, Zeiher AM, Nagel E. T1 and T2 mapping in myocarditis: seeing beyond the horizon of Lake Louise criteria and histopathology. Expert Rev Cardiovasc Ther. 2018;16(5):319–30. https://doi.org/10.1080/14779072.2018.1455499.
88. Ferreira VM, et al. Non-contrast T1-mapping detects acute myocardial edema with high diagnostic accuracy: a comparison to T2-weighted cardiovascular magnetic resonance. J Cardiovasc Magn Reson. 2012;14(1):42. https://doi.org/10.1186/1532-429X-14-42.
89. Ferreira VM, et al. T1 Mapping for the Diagnosis of Acute Myocarditis Using CMR. JACC Cardiovasc Imaging. 2013;6(10):1048–58. https://doi.org/10.1016/j.jcmg.2013.03.008.
90. Blissett S, Chocron Y, Kovacina B, Afilalo J. Diagnostic and prognostic value of cardiac magnetic resonance in acute myocarditis: a systematic review and meta-analysis. Int J Cardiovasc

Imaging. 2019;35(12):2221–9. https://doi.org/10.1007/s10554-019-01674-x.
91. Kotanidis CP, Bazmpani M-A, Haidich A-B, Karvounis C, Antoniades C, Karamitsos TD. Diagnostic Accuracy of Cardiovascular Magnetic Resonance in Acute Myocarditis. JACC Cardiovasc Imaging. 2018;11(11):1583–90. https://doi.org/10.1016/j.jcmg.2017.12.008.
92. Kersten J, Heck T, Tuchek L, Rottbauer W, Buckert D. The Role of Native T1 Mapping in the Diagnosis of Myocarditis in a Real-World Setting. J Clin Med. 2020;9(12):3810. https://doi.org/10.3390/jcm9123810.
93. Esposito A, et al. Lights and shadows of cardiac magnetic resonance imaging in acute myocarditis. Insights Imaging. 2016;7(1):99–110. https://doi.org/10.1007/s13244-015-0444-7.
94. Hendren NS, Drazner MH, Bozkurt B, Cooper LT. Description and Proposed Management of the Acute COVID-19 Cardiovascular Syndrome. Circulation. 2020;141(23):1903–14. https://doi.org/10.1161/CIRCULATIONAHA.120.047349.
95. Ponsiglione A, et al. Cardiac magnetic resonance imaging during the COVID-19 pandemic: A southern Italian single-center experience. Eur J Radiol Open. 2021;8:100319. https://doi.org/10.1016/j.ejro.2020.100319.
96. Birnie DH, et al. HRS Expert Consensus Statement on the Diagnosis and Management of Arrhythmias Associated With Cardiac Sarcoidosis. Heart Rhythm. 2014;11(7):1304–23. https://doi.org/10.1016/j.hrthm.2014.03.043.
97. Cheung E, et al. Combined simultaneous FDG-PET/MRI with T1 and T2 mapping as an imaging biomarker for the diagnosis and prognosis of suspected cardiac sarcoidosis. Eur J Hybrid Imaging. 2021;5(1):24. https://doi.org/10.1186/s41824-021-00119-w.
98. Maurer MS, Elliott P, Comenzo R, Semigran M, Rapezzi C. Addressing Common Questions Encountered in the Diagnosis and Management of Cardiac Amyloidosis. Circulation. 2017;135(14):1357–77. https://doi.org/10.1161/CIRCULATIONAHA.116.024438.
99. Vogelsberg H, et al. Cardiovascular Magnetic Resonance in Clinically Suspected Cardiac Amyloidosis. J Am Coll Cardiol. 2008;51(10):1022–30. https://doi.org/10.1016/j.jacc.2007.10.049.
100. Maceira AM, et al. Cardiovascular Magnetic Resonance in Cardiac Amyloidosis. Circulation. 2005;111(2):186–93. https://doi.org/10.1161/01.CIR.0000152819.97857.9D.
101. Nappi C, et al. Identification and typing of cardiac amyloidosis by noninvasive imaging: Two cases for two patterns. J Nucl Cardiol. 2020;27(3):915–20. https://doi.org/10.1007/s12350-019-01982-8.
102. Ruberg FL. T1 Mapping in Cardiac Amyloidosis. JACC Cardiovasc Imaging. 2013;6(4):498–500. https://doi.org/10.1016/j.jcmg.2013.01.007.
103. Sado DM, et al. Cardiovascular magnetic resonance measurement of myocardial extracellular volume in health and disease. Heart. 2012;98(19):1436–41. https://doi.org/10.1136/heartjnl-2012-302346.
104. Pan JA, Kerwin MJ, Salerno M. Native T1 Mapping, Extracellular Volume Mapping, and Late Gadolinium Enhancement in Cardiac Amyloidosis. JACC Cardiovasc Imaging. 2020;13(6):1299–310. https://doi.org/10.1016/j.jcmg.2020.03.010.
105. Zarate YA, Hopkin RJ. Fabry's disease. Lancet. 2008;372(9647):1427–35. https://doi.org/10.1016/S0140-6736(08)61589-5.
106. Hagège A, et al. Fabry disease in cardiology practice: Literature review and expert point of view. Arch Cardiovasc Dis. 2019;112(4):278–87. https://doi.org/10.1016/j.acvd.2019.01.002.
107. Perry R, et al. The Role of Cardiac Imaging in the Diagnosis and Management of Anderson-Fabry Disease. JACC Cardiovasc Imaging. 2019;12(7):1230–42. https://doi.org/10.1016/j.jcmg.2018.11.039.
108. Ponsiglione A, et al. Advanced CMR Techniques in Anderson-Fabry Disease: State of the Art. Diagnostics. 2023;13(15):2598. https://doi.org/10.3390/diagnostics13152598.
109. Tao E, Moiseev A, Mershina E, Bobkova I, Moiseev S. Predictive Value of Cardiac MRI in Patients with Fabry Disease. Radiology. 2020;296(2):E123–E123. https://doi.org/10.1148/radiol.2020200909.
110. Ponsiglione A, et al. Cardiovascular magnetic resonance native T1 mapping in Anderson-Fabry disease: a systematic review and meta-analysis. J Cardiovasc Magn Reson. 2022;24(1):31. https://doi.org/10.1186/s12968-022-00859-z.
111. Imbriaco M, et al. Hybrid positron emission tomography-magnetic resonance imaging for assessing different stages of cardiac impairment in patients with Anderson-Fabry disease: AFFINITY study group. Eur Heart J Cardiovasc Imaging. 2019;20(9):1004–11. https://doi.org/10.1093/ehjci/jez039.
112. Ponsiglione A, et al. Cardiac hybrid imaging: novel tracers for novel targets. J Geriatr Cardiol. 2021;18(9):748–58. https://doi.org/10.11909/j.issn.1671-5411.2021.09.006.
113. Cuocolo R, et al. The cardiac conundrum: a systematic review and bibliometric analysis of authorship in cardiac magnetic resonance imaging studies. Insights Imaging. 2020;11(1):42. https://doi.org/10.1186/s13244-020-00850-1.
114. Modell B, Khan M, Darlison M, Westwood MA, Ingram D, Pennell DJ. Improved survival of thalassaemia major in the UK and relation to T2* cardiovascular magnetic resonance. J Cardiovasc Magn Reson. 2008;10(1):42. https://doi.org/10.1186/1532-429X-10-42.
115. Carpenter J-P, et al. Calibration of myocardial T2 and T1 against iron concentration. J Cardiovasc Magn Reson. 2014;16(1):62. https://doi.org/10.1186/s12968-014-0062-4.
116. Sado DM, et al. Noncontrast myocardial T_1 mapping using cardiovascular magnetic resonance for iron overload. J Magn Reson Imaging. 2015;41(6):1505–11. https://doi.org/10.1002/jmri.24727.
117. Torlasco C, et al. Role of T1 mapping as a complementary tool to T2* for non-invasive cardiac iron overload assessment. PLoS ONE. 2018;13(2):e0192890. https://doi.org/10.1371/journal.pone.0192890.
118. Lee H, et al. Noncontrast Myocardial T1 Mapping by Cardiac Magnetic Resonance Predicts Outcome in Patients With Aortic Stenosis. JACC Cardiovasc Imaging. 2018;11(7):974–83. https://doi.org/10.1016/j.jcmg.2017.09.005.
119. Pavon AG, et al. Myocardial extracellular volume by T1 mapping: a new marker of arrhythmia in mitral valve prolapse. J Cardiovasc Magn Reson. 2021;23(1):102. https://doi.org/10.1186/s12968-021-00797-2.
120. Bonow RO, Greenland P. Population-Wide Trends in Aortic Stenosis Incidence and Outcomes. Circulation. 2015;131(11):969–71. https://doi.org/10.1161/CIRCULATIONAHA.115.014846.
121. Milano AD, et al. Prognostic value of myocardial fibrosis in patients with severe aortic valve stenosis. J Thorac Cardiovasc Surg. 2012;144(4):830–7. https://doi.org/10.1016/j.jtcvs.2011.11.024.
122. Everett RJ, et al. Extracellular Myocardial Volume in Patients With Aortic Stenosis. J Am Coll Cardiol. 2020;75(3):304–16. https://doi.org/10.1016/j.jacc.2019.11.032.
123. Delling FN, Vasan RS. Epidemiology and Pathophysiology of Mitral Valve Prolapse. Circulation. 2014;129(21):2158–70. https://doi.org/10.1161/CIRCULATIONAHA.113.006702.
124. Nordhues BD, et al. Bileaflet Mitral Valve Prolapse and Risk of Ventricular Dysrhythmias and Death. J Cardiovasc Electrophysiol. 2016;27(4):463–8. https://doi.org/10.1111/jce.12914.

125. Basso C, et al. Arrhythmic Mitral Valve Prolapse and Sudden Cardiac Death. Circulation. 2015;132(7):556–66. https://doi.org/10.1161/CIRCULATIONAHA.115.016291.
126. Guglielmo M, et al. T1 mapping and cardiac magnetic resonance feature tracking in mitral valve prolapse. Eur Radiol. 2021;31(2):1100–9. https://doi.org/10.1007/s00330-020-07140-w.