



Effects of Netarsudil and Latanoprost Alone and in Fixed Combination on Corneal Endothelium and Corneal Thickness: Post-Hoc Analysis of MERCURY-2

C. Ellis Wisely · Huan Sheng · Theresa Heah · Terry Kim

Received: November 12, 2019 / Published online: January 24, 2020
© The Author(s) 2020

ABSTRACT

Introduction: To describe the changes in endothelial cell density (ECD), the coefficient of variation (CV), the percentage of hexagonal cells (%HEX), and central corneal thickness (CCT) following 3 months of therapy with netarsudil 0.02%/latanoprost 0.005% fixed combination, and to compare these changes with those seen with netarsudil 0.02% or latanoprost 0.005% in eyes with ocular hypertension or open-angle glaucoma.

Methods: A subset of subjects enrolled in a Phase 3 evaluation of the intraocular pressure-lowering efficacy and safety of netarsudil 0.02%/latanoprost 0.005% fixed combination once daily (QD) versus each of its individual components underwent corneal endothelial cell imaging by specular microscopy and ultrasound pachymetry at baseline and following 3 months of therapy. Images were evaluated in masked fashion at an independent reading center. Changes from baseline to 3 months in ECD, CV,

%HEX, and CCT were compared between treatment groups.

Results: Data from 415 subjects obtained at both baseline and Month 3 were included in this post hoc analysis. Changes from baseline to Month 3 in ECD, CV, and %HEX were clinically insignificant in all three groups, and the changes in the netarsudil/latanoprost fixed combination group demonstrated no statistical difference from those seen in the netarsudil and latanoprost groups. Mean CCT decreased more in the fixed combination group (− 6.4 μm) than in either the netarsudil group (− 3.3 μm, $p = 0.0248$) or the latanoprost group (− 1.2 μm, $p < 0.0001$).

Conclusions: Netarsudil 0.2%/latanoprost 0.005% fixed combination QD for 3 months in eyes with ocular hypertension or open-angle glaucoma had no clinically significant effects on endothelial cell density or morphology. The significant decrease in CCT in the fixed combination group compared to the two individual component groups may indicate that the potential effects of each drug on CCT are additive, although the magnitude of the observed effects is likely of negligible clinical significance.

Clinicaltrials.gov Identifier: NCT02674854.

Enhanced Digital Features To view enhanced digital features for this article go to <https://doi.org/10.6084/m9.figshare.11528235>.

C. E. Wisely · T. Kim
Duke University Eye Center, Durham, NC, USA

H. Sheng · T. Heah
Aerie Pharmaceuticals, Inc., Irvine, CA, USA
e-mail: hsheng@aeriepharma.com

Keywords: Glaucoma; Intraocular pressure; Latanoprost; Netarsudil; Netarsudil/latanoprost

fixed combination; Ocular hypertension; Open-angle glaucoma

Key Summary Points

Glaucoma affects an estimated 64 million people worldwide, and its prevalence is projected to double by 2040.

Clinical trials have demonstrated that the average intraocular pressure-lowering effect of netarsudil/latanoprost fixed combination was 1–3 mmHg greater than monotherapy with either netarsudil 0.02% or latanoprost 0.005% throughout 3 months in eyes with ocular hypertension or primary open-angle glaucoma.

The purpose of this analysis was to compare changes in endothelial cell density (ECD), the coefficient of variation (CV), the percentage of hexagonal cells (%HEX), and central corneal thickness (CCT) in the three treatment groups (netarsudil and latanoprost alone and in fixed combination).

Changes from baseline to month 3 in ECD, CV, and %HEX were clinically insignificant in all three groups; mean CCT decreased more in the fixed combination group than in either the netarsudil group or the latanoprost group.

Netarsudil/latanoprost fixed combination daily for 3 months has no clinically significant effects on ECD, CV, or %HEX; the statistically significant decrease in CCT in the fixed combination group compared to the two individual component groups may indicate that the potential effects of each drug on CCT are additive, although the magnitude of the observed effects is likely of negligible clinical relevance.

INTRODUCTION

Glaucoma affects an estimated 64 million people worldwide, and its prevalence is projected to grow to 112 million by 2040 [1]. The goal of glaucoma therapy is the reduction of intraocular pressure (IOP), and topical medical therapy is the most common first-line treatment modality. In 2017, netarsudil (Aerie Pharmaceuticals, Durham, NC, USA) was approved by the US Food and Drug Administration for the reduction of IOP in eyes with primary open-angle glaucoma (POAG) or ocular hypertension (OHT) [2]. Netarsudil is a Rho kinase inhibitor, which is believed to lower IOP through up to three distinct mechanisms of action: increasing trabecular outflow, reducing aqueous formation, and reducing episcleral venous pressure (EVP) [3, 4].

Netarsudil is the first Rho kinase inhibitor approved for glaucoma therapy in the US, and its effects on trabecular outflow and EVP represent novel therapeutic targets for glaucoma management [5]. In Phase 3 clinical trials, netarsudil provided 3.3–5.0 mmHg IOP reduction. Common adverse events included conjunctival hyperemia, corneal verticillata, and conjunctival hemorrhages [6, 7]. The latter two adverse events occurred more often than typically seen with other IOP-lowering medications, underscoring the importance of robust characterization of the safety profiles of novel therapies.

Netarsudil is also available as a fixed combination with latanoprost, a prostaglandin analogue. Latanoprost is the most commonly used first-line medical therapy for POAG in most global markets due to its efficacy, safety, convenient once-daily dosing, and low cost in generic formulation. The netarsudil/latanoprost fixed combination (Aerie Pharmaceuticals) has been evaluated in a pair of Phase 3 trials in the US (MERCURY-1 and -2) [8–10], and was approved by the US Food and Drug Administration in March 2019. The Phase 3 clinical trials of netarsudil/latanoprost fixed combination demonstrated an average IOP lowering effect 1–3 mmHg greater than monotherapy with either netarsudil 0.02% or latanoprost 0.005%

throughout 3 months, and IOP reductions were maintained throughout 12 months. In addition to the MERCURY-1 and -2 clinical trials, an additional Phase 3 trial (MERCURY-3) is ongoing in Europe to evaluate the noninferiority of netarsudil/latanoprost fixed combination to the bimatoprost/timolol fixed combination (Allergan, Irvine, CA, USA) [11].

In the MERCURY-2 trial, specular microscopy and pachymetry were performed at 31 study centers. The purpose of this analysis was to compare changes in endothelial cell density (ECD) as well as corneal endothelial cell morphology [the coefficient of variation (CV), the percent of hexagonal cells (%HEX)] and central corneal thickness (CCT) seen in the three treatment groups (netarsudil and latanoprost alone and in fixed combination) of the MERCURY-2 study.

METHODS

MERCURY-2 was a prospective, multicenter, double-masked, randomized, active-controlled, parallel-group Phase 3 clinical trial comparing the 3-month safety and IOP-lowering efficacy of netarsudil 0.02% and latanoprost 0.005% alone and in fixed combination. Details of the study design have been previously described [9]. The study was conducted in full accordance with the Declaration of Helsinki and the Health Information Portability and Accounting Act. The study protocol was reviewed and approved by all relevant ethics boards [the Institutional Review Board (IRB) of Duke University]. All participants provided informed consent in writing.

Eligibility criteria for MERCURY-2 have been described [9]. Briefly, subjects were adults (≥ 18 years of age in the United States and ≥ 19 years of age in Canada), diagnosed with bilateral POAG or OHT, with unmedicated IOP > 20 mmHg and < 36 mmHg at 8:00 AM at two qualifying visits and IOP > 17 mmHg and < 36 mmHg at 10:00 AM and 4:00 PM on the second qualifying visit. If both eyes qualified for all criteria, the eye with higher IOP was selected to be the study eye. Key exclusion criteria relevant to this analysis included clinically

significant corneal disease (such as corneal edema or severe keratoconjunctivitis sicca), prior corneal refractive surgery, corneal pathology precluding accurate applanation tonometry, and central corneal thickness > 620 μm .

Qualifying subjects were randomized to treatment with netarsudil 0.02%/latanoprost 0.005% fixed combination, netarsudil 0.02%, or latanoprost 0.005%, each dosed once daily in the evening (QHS). Subjects were evaluated 2, 6, and 12 weeks after treatment initiation. At the second qualifying visit (baseline) and each on-treatment visit, IOP was measured at 8:00 AM, 10:00 AM, and 4:00 PM by Goldmann applanation tonometry. At pre-qualifying screening and Month 3, central corneal endothelial images were obtained by specular microscopy (Konan Medical, Hyogo, Japan) at 31 sites to obtain these images. Images were analyzed in masked fashion at an independent reading center (Cornea Image Analysis Reading Center, Case Western Reserve University, Cleveland, OH, USA) using standardized methodology and quality control measures [12]. Parameters analyzed from these images included ECD, CV, and %HEX. Central corneal thickness (CCT) was measured by ultrasound pachymetry.

The primary statistical objective of this post hoc analysis was to characterize the changes in ECD, endothelial cell morphology, and CCT from baseline to Month 3, and to compare these changes between treatment groups. Differences in demographics between groups were evaluated using Fisher's exact tests for categorical variables and one-way analysis of variance for continuous variables. Changes from baseline in ECD, CV, and %HEX within groups were evaluated using paired *t* tests, while comparisons between groups were conducted using two-sample *t* tests. All tests were two-sided, and $p < 0.05$ was taken as the level of significance. The study was powered, and sample size determined, for its overall primary objective (IOP reduction) and not for safety analyses. Data were analyzed using SAS v.9.4 (SAS Institute, Cary, NC, USA).

RESULTS

Overall, 750 subjects were randomized to treatment (245 to the netarsudil/latanoprost fixed combination group, 255 to the netarsudil group, and 250 to the latanoprost group). Of these, 126 (51.4%), 143 (56.1%), and 146 (58.4%) subjects in each arm, respectively, underwent specular microscopy at both baseline and Month 3 and were seen within the protocol-specified window for the Month 3 visit (± 3 days). Demographic data for these 415 subjects are given in Table 1. Briefly, their mean (standard deviation) age was 63.6 (11.2) years, 59.3% were white and 36.1% were black, and 62.4% were female; there were no significant between-group differences in any demographic factors.

Baseline and Month 3 specular microscopy data (ECD, CV, and %HEX) are presented in Table 2. Representative images from each of the three treatment groups are given in Fig. 1. Mean baseline corneal ECD in the study eye of

patients in the netarsudil/latanoprost, netarsudil, and latanoprost groups was 2463, 2523, and 2445 cells/mm², respectively, and 2477, 2538, and 2445 cells/mm², respectively, at Month 3. Mean baseline CV in the study eye of patients in the netarsudil/latanoprost, netarsudil, and latanoprost groups was 32.0%, 32.5%, and 32.5%, respectively, and 31.4%, 31.4%, and 32.6%, respectively, at Month 3. Mean baseline %HEX in the study eye of patients in the netarsudil/latanoprost, netarsudil, and latanoprost groups was 59.8%, 59.9%, and 58.8%, respectively, and 59.9%, 59.7%, and 59.2%, respectively, at Month 3. Changes from baseline to Month 3 in ECD, CV, and %HEX were clinically insignificant in all three groups, and the changes in the netarsudil/latanoprost fixed combination group demonstrated no statistical difference from those seen in the netarsudil and latanoprost groups. Mean CV at Month 3 was significantly higher in the latanoprost group compared to the netarsudil/latanoprost group [32.6% (4.6) vs. 31.4% (4.4),

Table 1 Demographic data for the subgroup of the MERCURY-2 study sample that underwent specular microscopy

	Netarsudil/latanoprost (<i>n</i> = 126)	Netarsudil (<i>n</i> = 143)	Latanoprost (<i>n</i> = 146)	All subjects (<i>n</i> = 415)	Significance (<i>p</i> value)
Study eye diagnosis, <i>n</i> (%)					
Ocular hypertension	34 (27.0)	36 (25.2)	39 (26.7)	109 (26.3)	0.9404
Open-angle glaucoma	92 (73.0)	107 (74.8)	107 (73.3)	306 (73.7)	
Sex, <i>n</i> (%)					
Female	81 (64.3)	91 (63.6)	87 (59.6)	259 (62.4)	0.6828
Male	45 (35.7)	52 (36.4)	59 (40.4)	156 (37.6)	
Age (years)	63.5 (12.1)	64.0 (10.2)	63.4 (11.4)	63.6 (11.2)	0.8873
Race, <i>n</i> (%)					
White	77 (61.1)	84 (58.7)	85 (58.2)	246 (59.3)	0.8888
Black or African American	43 (34.1)	52 (36.4)	55 (37.7)	150 (36.1)	
Other	6 (4.8)	7 (4.9)	6 (4.1)	19 (4.5)	

Values not given as *n* (%) are mean (SD)
SD standard deviation

Table 2 Endothelial cell density (ECD), cell morphology [coefficient of variation (CV) and percent of hexagonal cells (%HEX)], and central corneal thickness (CCT) results in the corneal safety study subgroup of the MERCURY-2 study sample

Parameter	Netarsudil/latanoprost (n = 126)			Netarsudil (n = 143)			Latanoprost (n = 146)		
	Baseline	Month 3	Change from baseline	Baseline	Month 3	Change from baseline	Baseline	Month 3	Change from baseline
ECD (cells/mm ²)									
Mean	2463.4	2477.3	13.9 (147.9)	2522.5	2538.4	15.9 (131.3)	2445.7	2444.7	- 1.00 (67.9)
(SD)	(398.9)	(416.3)		(369.4)	(361.3)		(445.2)	(447.4)	
p value ^b	-	-	-	0.2101	0.2027	0.9098	0.7297	0.5343	0.2995
CV (%)									
Mean	32.0	31.4	- 0.6 (4.5)	32.5	31.4	- 1.1 (3.8)	32.5	32.6	0.1 (2.7)
(SD)	(3.6)	(4.4)		(4.5)	(4.2)		(4.4)	(4.6)	
p value ^b	-	-	-	0.3352	0.9676	0.3329	0.3695	0.0355	0.1181
%HEX (%)									
Mean	59.8	59.9	0.1 (6.2)	59.9	59.7	- 0.2 (6.9)	58.8	59.2	0.4 (4.1)
(SD)	(5.3)	(6.4)		(5.1)	(7.0)		(5.9)	(6.4)	
p value ^b	-	-	-	0.8123	0.8573	0.7080	0.1473	0.3842	0.6385
CCT (µm)									
Mean	555.8	549.4	- 6.4 (10.3)	547.0	543.6	- 3.3 (12.3)	549.3	548.0	- 1.2 (10.4)
(SD)	(34.2)	(33.2)		(36.1)	(35.8)		(36.4)	(36.4)	
p value ^b	-	-	-	0.0431	0.1756	0.0248	0.1332	0.7574	< 0.0001

^a Within-group comparison

^b Versus netarsudil/latanoprost

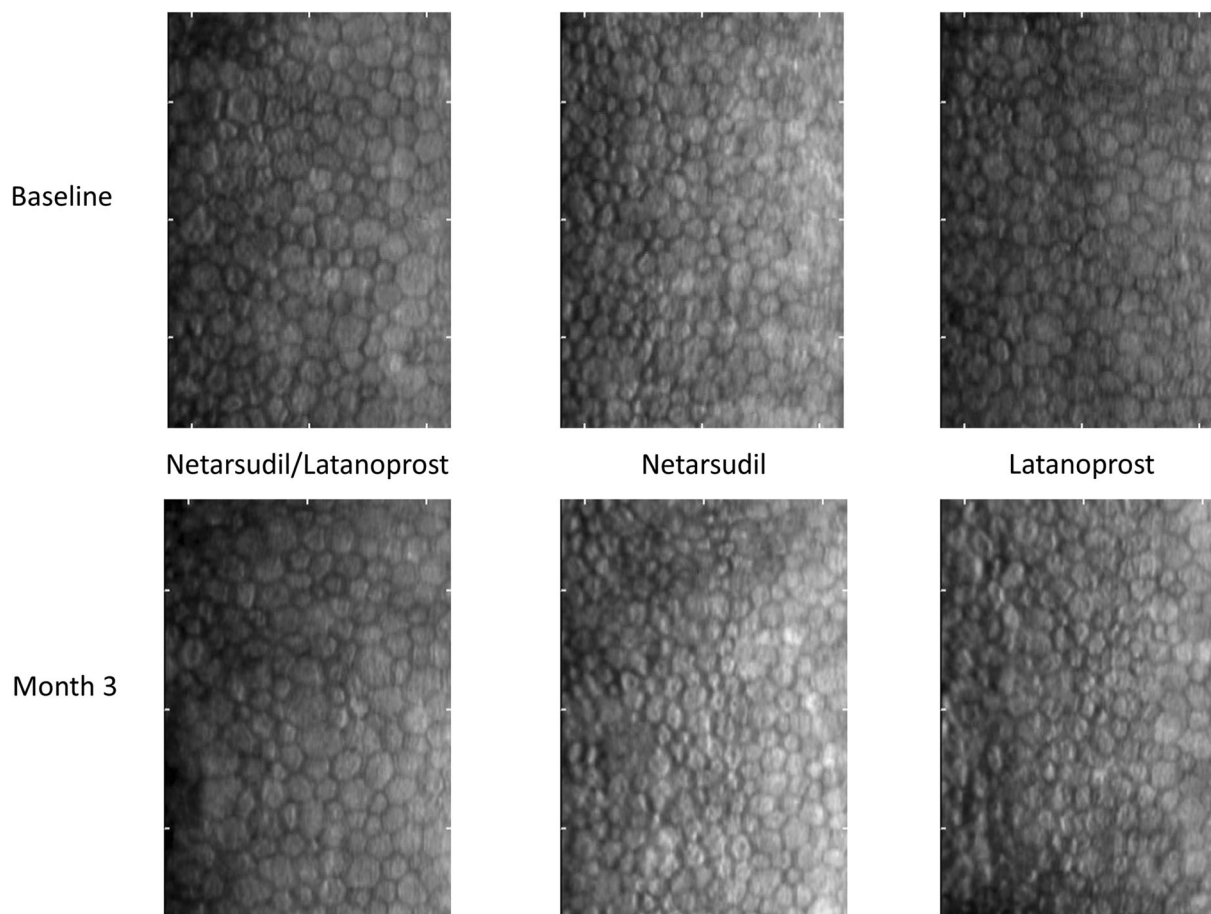


Fig. 1 Specular microscopy images at baseline (top) and Month 3 (bottom) from one eye each treated with netarsudil/latanoprost fixed combination (left), netarsudil (middle), or latanoprost (right). Respective endothelial cell

densities at baseline and Month 3 were 2216.2 and 2096.6 cells/mm² in the netarsudil/latanoprost eye, 3073.5 and 3091.0 cells/mm² in the netarsudil eye, and 2601.5 and 2531.2 cells/mm² in the latanoprost eye

$p = 0.0355$], but the change in the latanoprost group from baseline was not significantly different [0.1 (2.7) vs. -0.6 (4.5), $p = 0.1181$]. Within groups, CV in the netarsudil group declined (1.1%, $p = 0.0006$), while all other within-group changes in ECD, CV, and %HEX were not statistically significant ($p > 0.05$).

CCT data are also given in Table 2. Mean CCT in the study eyes of patients in the netarsudil/latanoprost, netarsudil, and latanoprost groups was 556, 547, and 549 μm , respectively, at baseline and 549, 544, and 548 μm , respectively, at Month 3. Mean CCT decreased from baseline to Month 3 in both the netarsudil group [-3.3 (12.3) μm , $p = 0.0018$] and the netarsudil/latanoprost fixed combination group

[-6.4 (10.3) μm , $p < 0.0001$], but not in the latanoprost group [-1.2 (10.4) μm , $p = 0.1625$]. These changes from baseline were significantly greater in the fixed combination group than in either the netarsudil ($p = 0.0248$) or latanoprost ($p < 0.0001$) groups.

Among the reported treatment-emergent adverse events were 18 eyes of 9 subjects (4 in the fixed combination group and 5 in the netarsudil group) with temporary endothelial cell pleomorphism, all of which were moderate in severity, deemed related to therapy, and resolved by study exit without discontinuation of therapy. In addition, 32 eyes of 16 subjects (10 in the fixed combination group and 6 in the netarsudil group) exhibited distortion of

specular microscopy endothelial cell morphology, all of which were mild in severity, deemed related to therapy, and resolved without discontinuation of therapy in all but 1 subject by study end.

DISCUSSION

The analysis of data from the Phase 3 MERCURY-2 study comparing the IOP-lowering efficacy and safety of netarsudil 0.02%/latanoprost 0.005% fixed combination QD to its components demonstrated that 3 months of treatment yielded no statistically or clinically significant changes in ECD or morphology. Subclinical findings of endothelial cell pleomorphism or distortion of endothelial cell morphology were seen in 50 eyes of 25 subjects (56% of these subjects were in the fixed combination group) and resolved while the subjects remained on study drug therapy in all but 1 subject. These findings were not associated with any clinical findings such as corneal edema and were thus subclinical in all cases. These results are consistent with similar findings recently reported from the Phase 3 ROCKET-2 study evaluating the IOP-lowering efficacy and safety of netarsudil versus timolol. Rho kinase inhibitors are known to have transient effects on endothelial cell morphology, including distortion of cell borders; as in our study, this was not associated with corneal edema or changes in ECD [13].

However, statistically significant reductions in mean CCT were seen in the netarsudil and netarsudil/latanoprost groups. Both prostaglandin analogues (PGA) and Rho kinase inhibitors are known to cause central corneal thinning. Numerous studies have documented a reduction of approximately 5–15 μm in mean CCT with long-term (> 18 months) use of latanoprost [14–19], manifesting in the first 6–24 months of therapy [16–19], and resolving with discontinuation of therapy [14]. One possible mechanism by which prostaglandins may reduce CCT is by upregulation of matrix metalloproteinases (specifically MMP-9) that promote degradation of the ocular surface matrix [20]. This PGA-related corneal thinning is likely

of negligible clinical significance, given that millions of prescriptions for PGAs have been dispensed worldwide over the past two decades and there are no reports in the literature of which we are aware of complications associated with this phenomenon.

Rho kinase inhibitors can also produce central corneal thinning, although this has only been reported in eyes with pathology associated with corneal edema in which the thinning is an approach to normalization of CCT [21, 22]. Rho kinase inhibitors have several properties that promote corneal thinning, including promotion of endothelial cell proliferation and migration [23, 24], suppression of apoptosis [25], and faster corneal wound healing [26–29]. In the current study, the greater reduction in CCT in the fixed combination group may indicate that the potential effects of each drug on CCT are additive. However, the magnitude of these effects seen in this study (on the order of 0.6–1.2%) are likely of negligible clinical significance.

The conclusion of this study—that netarsudil alone or in fixed combination with latanoprost demonstrates no corneal endothelial safety issues, with no changes in ECD, CV, or %HEX—is strengthened by several features of this study's design. MERCURY-2 was a prospective, randomized, double-masked trial, and specular microscopy data were analyzed in masked fashion by an independent data center. Limitations of this analysis include its relatively short (3 months) exposure to netarsudil, as well as a possible selection bias, in that not all MERCURY-2 study subjects underwent specular microscopy, although the demographics of the current sample are similar to those of the full MERCURY-2 cohort.

CONCLUSIONS

In summary, 3 months of exposure to netarsudil—alone or in fixed combination with latanoprost—produced no statistically or clinically relevant changes in ECD or morphology. Small reductions in CCT—on the order of 0.6–1.2%—were seen in the netarsudil and netarsudil/latanoprost groups; these changes were

statistically significant but of negligible clinical significance. No clinical adverse events related to changes in ECD, morphology, or CCT were observed.

ACKNOWLEDGEMENTS

The authors thank the participants of the study.

Funding. Sponsorship for this study and the journal's Rapid Service Fee were funded by Aerie Pharmaceuticals, Inc., Irvine, CA, USA. All authors had full access to all of the data in this study and take complete responsibility for the integrity of the data and accuracy of the data analysis.

Medical Writing and Editorial Assistance. The authors acknowledge the technical input of Dr. Jonathan Lass, Cornea Image Analysis Reading Center, Case Western Reserve University and University Hospital, Cleveland, OH, USA. Support for manuscript preparation was provided by Tony Realini, MD, MPH.

Authorship. All named authors meet the International Committee of Medical Journal Editors (ICMJE) criteria for authorship for this article, take responsibility for the integrity of the work as a whole, and have given their approval for this version to be published.

Prior Presentation. An abstract of these data was submitted to the American Academy of Ophthalmology annual meeting (October 12–15, 2019), San Francisco, CA, USA.

Disclosures. C Ellis Wisely declares that he has no conflict of interest. Terry Kim is a consultant to Aerie Pharmaceuticals, Alcon/Novartis, Allergan/Actavis, Avedro, Avellino Labs, B&L/Valeant, Blephex, CoDa/Ocunexus Therapeutics, CorneaGen, Johnson & Johnson Vision, Kala Pharmaceuticals, NovaBay Pharmaceuticals, Ocular Therapeutix, Omeros, Powervision, Presbyopia Therapies, Shire, Simple Contacts, TearLab, Zeiss and is a shareholder in Avellino Labs, CorneaGen, Kala Pharmaceuticals, NovaBay Pharmaceuticals, Ocular

Therapeutix, Omeros, and Simple Contacts. Huan Sheng is a salaried employee of and owns stock in Aerie Pharmaceuticals. Theresa Heah was a salaried employee of Aerie Pharmaceuticals from 2015 to July 2019; Theresa Heah is a current employee of AGTC, Cambridge, MA, USA.

Compliance with Ethics Guidelines. The study was conducted in full accordance with the Declaration of Helsinki and the Health Information Portability and Accounting Act. The study protocol was reviewed and approved by all relevant ethics boards (Institutional Review Board (IRB) of Duke University). All participants provided informed consent in writing.

Open Access. This article is licensed under a Creative Commons Attribution-NonCommercial 4.0 International License, which permits any non-commercial use, sharing, adaptation, distribution and reproduction in any medium or format, as long as you give appropriate credit to the original author(s) and the source, provide a link to the Creative Commons licence, and indicate if changes were made. The images or other third party material in this article are included in the article's Creative Commons licence, unless indicated otherwise in a credit line to the material. If material is not included in the article's Creative Commons licence and your intended use is not permitted by statutory regulation or exceeds the permitted use, you will need to obtain permission directly from the copyright holder. To view a copy of this licence, visit <http://creativecommons.org/licenses/by-nc/4.0/>.

REFERENCES

1. Tham YC, Li X, Wong TY, Quigley HA, Aung T, Cheng CY. Global prevalence of glaucoma and projections of glaucoma burden through 2040: a systematic review and meta-analysis. *Ophthalmology*. 2014;121:2081–90.
2. United States Food and Drug Administration. Rho-pressa (netarsudil) Ophthalmic Solution. https://www.accessdata.fda.gov/drugsatfda_docs/nda/

- [2017/208254Orig1s000TOC.cfm](#). Accessed 22 Jan 2019.
3. Dasso L, Al-Khaled T, Sonty S, Aref AA. Profile of netarsudil ophthalmic solution and its potential in the treatment of open-angle glaucoma: evidence to date. *Clin Ophthalmol*. 2018;12:1939–44.
 4. Khouri AS, Serle JB, Bacharach J, et al. Once-daily netarsudil vs twice-daily timolol in patients with elevated intraocular pressure, the randomized phase 3 ROCKET-4 study. *Am J Ophthalmol*. 2019;204:97–104.
 5. Kazemi A, McLaren JW, Kopczynski CC, Heah TG, Novack GD, Sit AJ. The effects of netarsudil ophthalmic solution on aqueous humor dynamics in a randomized study in humans. *J Ocul Pharmacol Ther*. 2018;34:380–6.
 6. Serle JB, Katz LJ, McLaurin E, et al. Two phase 3 clinical trials comparing the safety and efficacy of netarsudil to timolol in patients with elevated intraocular pressure: Rho Kinase Elevated IOP Treatment Trial 1 and 2 (ROCKET-1 and ROCKET-2). *Am J Ophthalmol*. 2018;186:116–27.
 7. Kahook MY, Serle JB, Mah FS, et al. Long-term safety and ocular hypotensive efficacy evaluation of netarsudil ophthalmic solution: Rho Kinase Elevated IOP Treatment Trial (ROCKET-2). *Am J Ophthalmol*. 2019;200:130–7.
 8. Double-masked study of PG324 ophthalmic solution in patients with glaucoma or ocular hypertension. <https://clinicaltrials.gov/ct2/show/NCT02558400>. Accessed 3 Mar 2019.
 9. Double-masked study of PG324 ophthalmic solution in patients with open-angle glaucoma or ocular hypertension. <https://clinicaltrials.gov/ct2/show/NCT02674854>. Accessed 26 Jan 2019.
 10. Walters TR, Ahmed IIK, Lewis RA, et al. Once-daily netarsudil/latanoprost fixed-dose combination for elevated intraocular pressure in the randomized phase 3 MERCURY-2 study. *Ophthalmol Glaucoma*. 2019 (in press).
 11. Safety and efficacy study of PG324 (netarsudil/latanoprost 0.02%/0.005%) ophthalmic solution compared to GANFORT® ophthalmic solution in open angle glaucoma or ocular hypertension. <https://clinicaltrials.gov/ct2/show/NCT03284853>. Accessed 3 Mar 2019.
 12. Benetz BA, Gal RL, Ruedy KJ, et al. Specular microscopy ancillary study methods for donor endothelial cell density determination of Cornea Donor Study images. *Curr Eye Res*. 2006;31:319–27.
 13. Nakagawa H, Koizumi N, Okumura N, Suganami H, Kinoshita S. Morphological changes of human corneal endothelial cells after rho-associated kinase inhibitor eye drop (ripasudil) administration: a prospective open-label clinical study. *PLoS ONE*. 2015;10:e0136802.
 14. Yoo R, Choi YA, Cho BJ. Change in central corneal thickness after the discontinuation of latanoprost in normal tension glaucoma—change in central corneal thickness after stop of latanoprost. *J Ocul Pharmacol Ther*. 2017;33:57–61.
 15. Kim HJ, Cho BJ. Long-term effect of latanoprost on central corneal thickness in normal tension glaucoma. *J Ocul Pharmacol Ther*. 2011;27:73–6.
 16. Lee H, Cho BJ. Long-term effect of latanoprost on central corneal thickness in normal-tension glaucoma: five-year follow-up results. *J Ocul Pharmacol Ther*. 2015;31:152–5.
 17. Maruyama Y, Mori K, Ikeda Y, Ueno M, Kinoshita S. Effects of long-term topical prostaglandin therapy on central corneal thickness. *J Ocul Pharmacol Ther*. 2014;30:440–4.
 18. Zhong Y, Shen X, Yu J, Tan H, Cheng Y. The comparison of the effects of latanoprost, travoprost, and bimatoprost on central corneal thickness. *Cornea*. 2011;30:861–4.
 19. Viswanathan D, Goldberg I, Graham SL. Longitudinal effect of topical antiglaucoma medications on central corneal thickness. *Clin Exp Ophthalmol*. 2013;41:348–54.
 20. Honda N, Miyai T, Nejima R, et al. Effect of latanoprost on the expression of matrix metalloproteinases and tissue inhibitor of metalloproteinase 1 on the ocular surface. *Arch Ophthalmol*. 2010;128:466–71.
 21. Koizumi N, Okumura N, Ueno M, Nakagawa H, Hamuro J, Kinoshita S. Rho-associated kinase inhibitor eye drop treatment as a possible medical treatment for Fuchs corneal dystrophy. *Cornea*. 2013;32:1167–70.
 22. Okumura N, Koizumi N, Kay EP, et al. The ROCK inhibitor eye drop accelerates corneal endothelium wound healing. *Investig Ophthalmol Vis Sci*. 2013;54:2493–502.
 23. Ishizaki T, Uehata M, Tamechika I, et al. Pharmacological properties of Y-27632, a specific inhibitor of rho-associated kinases. *Mol Pharmacol*. 2000;57:976–83.
 24. Meekins LC, Rosado-Adames N, Maddala R, Zhao JJ, Rao PV, Afshari NA. Corneal endothelial cell migration and proliferation enhanced by Rho

- kinase (ROCK) inhibitors in in vitro and in vivo models. *Investig Ophthalmol Vis Sci.* 2016;57:6731–8.
25. Goldstein AS, Aldrich BT, Skeie JM, et al. Assessing the effects of ripasudil, a novel Rho kinase inhibitor, on human corneal endothelial cell health. *J Ocul Pharmacol Ther.* 2018. <https://doi.org/10.1089/jop.2018.0063>.
 26. Okumura N, Okazaki Y, Inoue R, et al. Effect of the Rho-associated kinase inhibitor eye drop (ripasudil) on corneal endothelial wound healing. *Investig Ophthalmol Vis Sci.* 2016;57:1284–92.
 27. Okumura N, Nakano S, Kay EP, et al. Involvement of cyclin D and p27 in cell proliferation mediated by ROCK inhibitors Y-27632 and Y-39983 during corneal endothelium wound healing. *Investig Ophthalmol Vis Sci.* 2014;55:318–29.
 28. Okumura N, Koizumi N, Ueno M, et al. The new therapeutic concept of using a rho kinase inhibitor for the treatment of corneal endothelial dysfunction. *Cornea.* 2011;30(Suppl 1):S54–9.
 29. Okumura N, Koizumi N, Ueno M, et al. Enhancement of corneal endothelium wound healing by Rho-associated kinase (ROCK) inhibitor eye drops. *Br J Ophthalmol.* 2011;95:1006–9.