



# Cervical Sympathetic Trunk-Centered Inflammatory Myofibroblastic Tumor Complicated with Postoperative First Bite Syndrome

Liu Yang<sup>1</sup> · Wen Li<sup>1</sup>

Received: 19 December 2020 / Accepted: 21 April 2021 / Published online: 26 April 2021  
© The Author(s) 2021

## Abstract

Inflammatory myofibroblastic tumors (IMTs) in the head and neck region are common, but those with sympathetic trunk involvement are extremely rare. Here we present a case of cervical sympathetic trunk-centered IMT which is also accompanied by ipsilateral carotid artery, internal jugular vein, and vagus nerve involvement. The patient initially complained of an episodic painful swelling on the right side of the neck and underwent surgery. Preoperative and postoperative serum IgG4 level during 3-year follow-up time is within normal limits. Immunohistochemical study of the tumor has also revealed negativity to IgG4. Postoperative first bite syndrome (FBS) was observed. Surgery seems to be first-line therapy in the patient with IgG4-negative IMT.

**Keywords** Inflammatory pseudotumor · Neck mass · Cervical sympathetic nerve · Surgery · First bite syndrome

Inflammatory myofibroblastic tumors (IMTs) are a series of tumefactive entities with uncertain histogenesis and prognosis. It is also called inflammatory pseudotumor, originally reported in the lung and has been described in almost every anatomical site throughout the body. IMTs in the head and neck region are not uncommon, with the orbit as the most common site [1]. Less than 20 cases involving the peripheral nervous system throughout the body have been described in the literature [2]. We present a case of extremely rare cervical sympathetic trunk-centered IMT without preoperative nervous dysfunction. The patient has postoperative first bite syndrome (FBS) and Horner's syndrome after surgery.

## Clinical Case

A 51-year-old man presented to the hospital with a right-sided neck mass. The mass was initially asymptomatic for more than a year and then developed to paroxysmal headache within 6 months before admission. Because preoperative two-time fine-needle aspiration biopsy implied a lymphocyte proliferative reaction, the patient was treated with a combination of antibiotics and traditional Chinese herbs. Though these remedies got pain

relief and slight regression of the mass, the symptoms resumed repeatedly during the therapeutic time. The computed tomography angiography showed the mass (25mm×30mm×30mm in dimension) was mildly enhanced with obscure boundaries, almost behind the carotid sheath, extending up to the skull base (Fig. 1). The carotid bifurcation was more separated from each other in comparison with that of the left side (Fig. 2). The fiberoptic laryngoscopy was otherwise normal. His serum immunoglobulin G4 (IgG4) was within normal limits (0.535 g/L). The tuberculin skin test was negative.

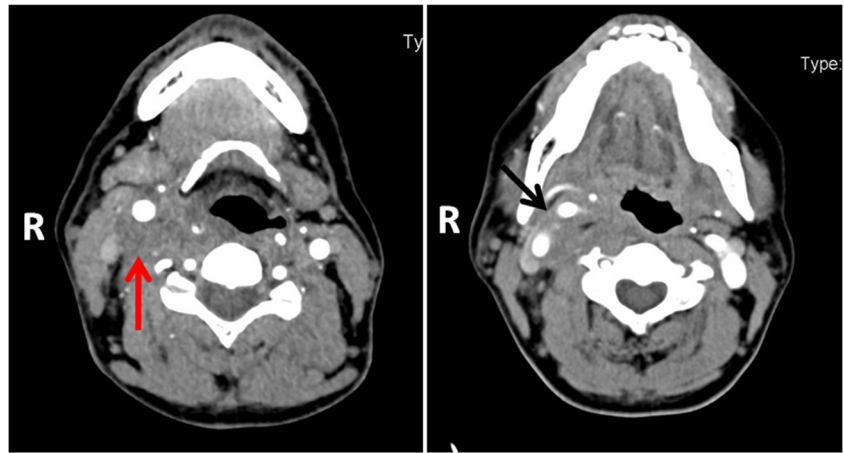
Surgical exploration was carried out under general anesthesia. During surgery, the cervical sympathetic trunk was found in the center of the lesion with the involvement of carotid arteries, internal jugular vein, vagus nerve, and descending branches of the hypoglossal nerve (Fig. 3). The tumor could completely free from the surrounding significant structures as there were some anatomical spaces between the tumor and these structures (CA, IJV, and VN). But the lesion originated from the nerve membrane and cannot be separated from the cervical sympathetic trunk which was sacrificed finally. Microscopically, massive proliferative fibrotic tissues deposit and extensive lymphocyte infiltration were observed in the neural fasciculus (Fig. 4a, b). Immunohistochemical staining showed negativity for CDK4, MDM2, P16, CD34, S-100, desmin, SMA, and EMA. The plasmocytoma was also negative for IgG4 (Fig. 4c). The diagnosis of IMT was concluded.

The primary healing was achieved, while Horner's syndrome appeared on the second day after surgery. Besides, 6 weeks after surgery, the patient experienced unilateral jaw pain on the

✉ Wen Li  
church.ent.wc@163.com

<sup>1</sup> Department of Otolaryngology Head & Neck Surgery, West China Hospital, Sichuan University, 37 E Guoxue Alley, Chengdu, Sichuan 610041, People's Republic of China

**Fig. 1** Computed tomography demonstrated that a lump of obscure boundaries with mild enhancement was almost behind the carotid sheath (red arrow) and made the carotid bifurcation more separated than usual (black arrow)



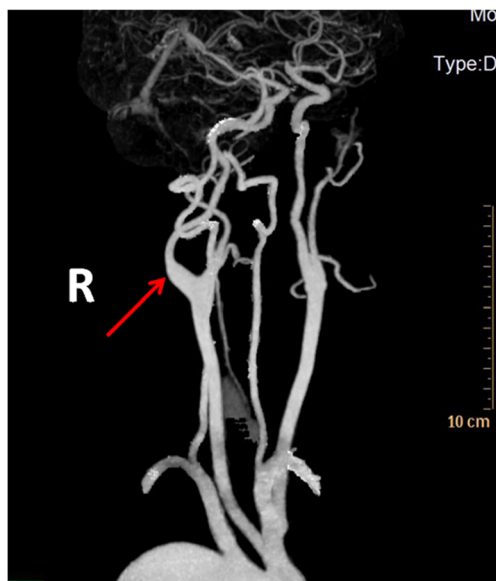
operative side when he started to open his mouth. The pain was worse with the first bite of each meal and dissipated over subsequent bites, and it was a typical syndrome of FBS. He consulted a neurological physician and was treated with tiapride and eperisone tablets for 4 weeks. The FBS occurred occasionally, while Homer’s syndrome persisted during the 3-year follow-up. There was no recurrence during the follow-up time.

**Discussion**

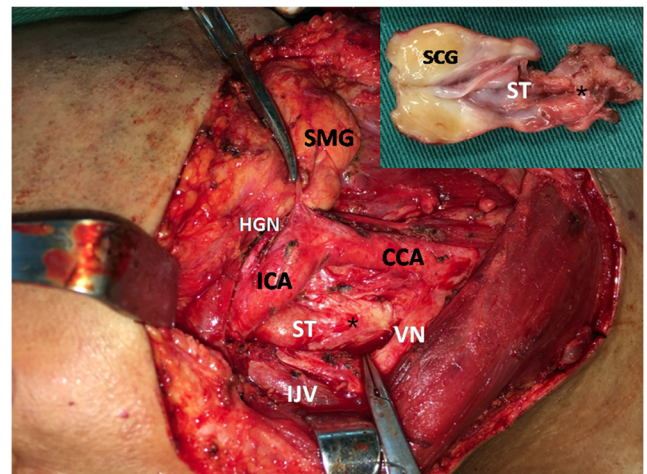
IMT is rare in the neck, especially in the carotid region. Only a few cases located in the carotid region have been documented in English literature. IMTs rarely affect nerves. In contrast to those reported cases with peripheral neuropathy, this case had no pre-operative dysneuria. To our knowledge, this is the second case in which the cervical sympathetic trunk is affected [3, 4].

It is now considered a real tumor with some IMT subtypes considered as IgG4-related disease. However, neither serum IgG4 nor positive immunohistochemical staining of IgG4 was remarkable in this case [5]. The cervical sympathetic trunk-centered IMT makes the diagnosis more difficult than those at other anatomic sites due to minimal incidence. According to previous studies and observation of this case, when nerves are involved, histological changes are mainly confined to epineurium, and adipocytes increase in varying degrees.

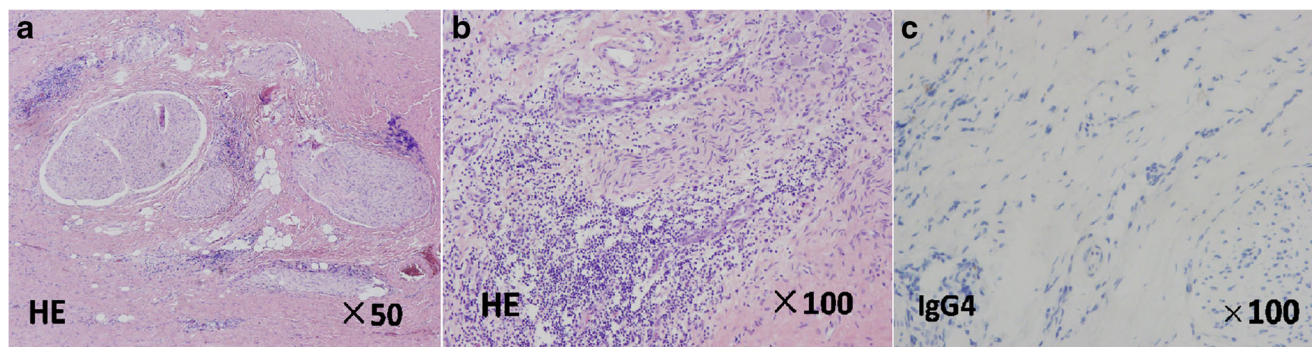
The rational therapy depends on histopathological subtype, location, single or multiple sites, and initial or recurrent lesions. As the clinical symptoms, biopsy, and treatment of this case are very similar to that of a previous case which we reported in 2016 [6], serum IgG4 should be detected before an operation. It is believed that most IgG4-positive IMTs showed a better response to corticosteroid therapy than that of IgG4-negative ones. Moreover, the lymphocytic infiltrative IMTs are considered being more sensitive to steroids than the fibroproliferative ones.



**Fig. 2** Computed angiography revealed a more separated carotid bifurcation and a more dilated internal carotid artery start (red arrow)



**Fig. 3** The surgical field after partial resection of the tumor showed that the cervical sympathetic trunk (ST) was found in the center of the lesion with the involvement of carotid arteries, internal jugular vein (IJV), vagus nerve (VN), and descending branches of the hypoglossal nerve (HGN) (CCA, common carotid artery; ICA, internal carotid artery; SMG, submandibular gland). Inset: sympathetic trunk (SCG, superior cervical ganglion). The tumor was marked by a single asterisk symbol



**Fig. 4** **a** Histopathologically, massive proliferative fibrotic tissue deposit and scattered lymphocyte infiltration were observed in the neural fasciculus. Some fat cells with heteromorphism scattered in the focal area (hematoxylin-eosin staining, original magnification  $\times 50$ ). **b** Histopathologically, in some perspectives, less proliferative fibrotic tissue deposit and extensive

lymphocyte infiltration were observed in the neural fasciculus (hematoxylin-eosin staining, original magnification  $\times 100$ ). **c** Immunohistochemistry, the plasmocytosis was negative for IgG4. (immunohistochemical staining, original magnification  $\times 100$ )

Local excision with a rim of normal tissue advocated preventing recurrence of IMT especially in the case with a malignant tendency or aggressive process [5]. As an IgG4-negative IMT case, whether it is worthwhile to sacrifice the sympathetic trunk for the non-recurrence remains a question. Radiotherapy is supposed to be the last resort for those cases which have a poor response to steroid treatment.

FBS was firstly described as a symptom resulting from cervical sympathetic trunk injury [7]. Recent studies indicated that FBS not only appeared postoperatively but also in the patient experiencing chemotherapy or presurgical patient with parotid malignancy [8].

## Conclusion

Radical surgery has got satisfactory outcomes in this extremely rare cervical sympathetic trunk-centered inflammatory myofibroblastic tumor case. In addition, first bite syndrome shall also be noted as a potential postoperative complication.

**Author's Contribution** Liu Yang: design of work, drafting, revising, and final approval. Wen Li: revising and final approval.

## Declarations

**Statement of Ethics** The patient described in this report provided consent for the publication of this work, and images and institutional review board approval of the Sichuan University was obtained. Research was conducted ethically in accordance with the World Medical Association Declaration of Helsinki.

**Conflict of Interest** The authors declare no competing interests.

**Open Access** This article is licensed under a Creative Commons Attribution 4.0 International License, which permits use, sharing, adaptation, distribution and reproduction in any medium or format, as long as you give appropriate credit to the original author(s) and the source, provide a link to the Creative Commons licence, and indicate if changes were made. The images or other

third party material in this article are included in the article's Creative Commons licence, unless indicated otherwise in a credit line to the material. If material is not included in the article's Creative Commons licence and your intended use is not permitted by statutory regulation or exceeds the permitted use, you will need to obtain permission directly from the copyright holder. To view a copy of this licence, visit <http://creativecommons.org/licenses/by/4.0/>.

## References

- Narla LD, Newman B, Spottswood SS, Narla S, Kolli R (2003) Inflammatory pseudotumor. *Radiographics* 23(3):719–729. <https://doi.org/10.1148/rg.233025073>
- Mauermann ML, Scheithauer BW, Spinner RJ, Amrami KK, Nance CS, Kline DG, O'Connor MI, Dyck PJ EJ, Dyck PJ (2010) Inflammatory pseudotumor of nerve: clinicopathological characteristics and a potential therapy. *J Peripher Nerv Syst* 15(3):216–226. <https://doi.org/10.1111/j.1529-8027.2010.00273.x>
- Okamoto M, Takahashi H, Yamanaka J, Nemoto S, Kuno K, Ishii T (1997) Sclerosing inflammatory pseudotumor arising from the carotid artery region. *Auris Nasus Larynx* 24(3):315–320. [https://doi.org/10.1016/s0385-8146\(96\)00030-2](https://doi.org/10.1016/s0385-8146(96)00030-2)
- Farage L, Motta AC, Goldenberg D, Aygun N, Yousem DM (2007) Idiopathic inflammatory pseudotumor of the carotid sheath. *Arq Neuropsiquiatr* 65(4B):1241–1244. <https://doi.org/10.1590/s0004-282x2007000700030>
- Ryu G, Cho HJ, Lee KE, Lee JJ, Hong SD, Kim HY, Chung SK, Dhong HJ (2019) Clinical significance of IgG4 in sinonasal and skull base inflammatory pseudotumor. *Eur Arch Otorhinolaryngol* 276: 2465–2473. <https://doi.org/10.1007/s00405-019-05505-6>
- Yang L, Li W, Zhang H (2016) Inflammatory myofibroblastic tumor of carotid artery resulting in recurrent syncope: a case report. *Head Neck* 38(7):E2461–E2463. <https://doi.org/10.1002/hed.24422>
- Avinçal MÖ, Hiroshima Y, Shinomiya H, Shinomiya H, Otsuki N, Nibu KI (2017) First bite syndrome - an 11-year experience. *Auris Nasus Larynx* 44(3):302–305. <https://doi.org/10.1016/j.anl.2016.07.012>
- Lee BJ, Lee JC, Lee YO, Wang SG, Kim HJ (2009) Novel treatment of first bite syndrome using botulinum toxin type A. *Head Neck* 31(8):989–993. <https://doi.org/10.1002/hed.21054>

**Publisher's Note** Springer Nature remains neutral with regard to jurisdictional claims in published maps and institutional affiliations.