

A potentially fatal cause of rash

Fabrizio Elia · Franco Aprà

Received: 17 January 2010 / Accepted: 19 April 2010 / Published online: 20 August 2010
© Springer-Verlag London Ltd 2010

An 87-year-old woman was admitted for fever and maculopapular rash that had appeared 1 week before presentation. The patient had a history of hypertension and was being treated with allopurinol, which had been started 3 weeks earlier for hyperuricemia. She denied any history of allergies or recent contact with sick people. On arrival she presented with hypotension, oliguria and fever. Physical examination revealed a diffuse pruriginous maculopapular rash most prominent on the trunk and extremities (Figs. 1 and 2). Laboratory tests showed leucocytosis, eosinophilia and acute renal failure. Blood cultures, monospot test and parasitologic fecal examination were all negative. Chest radiography and electrocardiography performed on admission were both unremarkable.

DRESS (drug reaction with eosinophilia and systemic symptoms) is a drug-induced life-threatening hypersensitivity syndrome that presents with skin rash, fever, eosinophilia and multiple organ involvement (especially kidney and liver injury). Normally clinical signs present within 8 weeks after starting medication. Drugs most frequently implicated are aromatic antiepileptic agents, sulfonamides and allopurinol. Differential diagnosis includes viral, bacterial and parasitologic infections, hypereosinophilic syndrome, neoplastic and autoimmune diseases.

One in 260 patients treated with allopurinol develops DRESS [1]. Renal failure is common, and maculopapular exanthema is the most frequent skin manifestation [2]. The mortality rate is higher in comparison to hypersensitivity

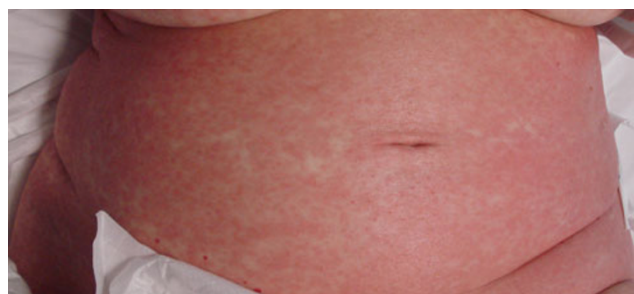

Fig. 1 Maculopapular rash on the trunk

reactions due to other drugs, reaching approximately 25% in some studies [3].

When our patient met the DRESS syndrome criteria [4], allopurinol was stopped, and fluids and steroids were administered. The patient responded to treatment and was discharged in good condition with normal renal function and partial resolution of her skin rash.

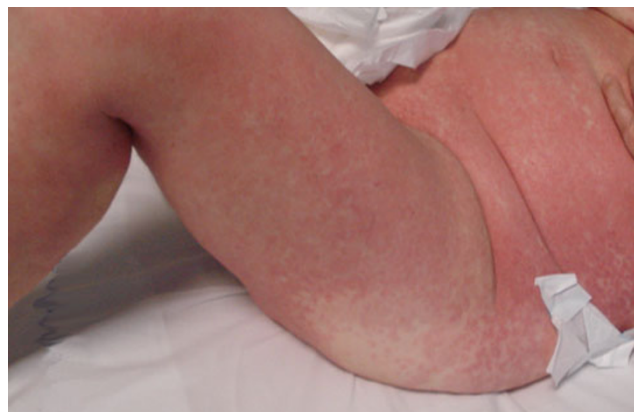


Fig. 2 Maculopapular rash on the trunk and lower extremities

F. Elia (✉) · F. Aprà
High Dependency Unit, San Giovanni Bosco Hospital,
Piazza Donatore del Sangue 3,
10154 Torino, Italy
e-mail: fabrizioelia@yahoo.it

F. Aprà
e-mail: francoapra@tiscali.it

References

1. McInnes GT, Lawson DH, Jick H (1981) Acute adverse reactions attributed to allopurinol in hospitalized patients. *Ann Rheum Dis* 40:245–249
2. Peyrière H, Dereure O, Breton H et al (2006) Variability in the clinical pattern of cutaneous side-effects of drugs with systemic symptoms: does a DRESS syndrome really exist? *Br J Dermatol* 155:422–428
3. Arellano F, Sacristán JA (1993) Allopurinol hypersensitivity syndrome: a review. *Ann Pharmacother* 27:337–343
4. Singer JZ, Wallace SL (1986) The allopurinol hypersensitivity syndrome. Unnecessary morbidity and mortality. *Arthritis Rheum* 29:82–87