



# A Single Institution Cadaveric Study on Anatomical Variation of the Sublingual Gland Duct

Nurul Asma Che Ab Rahim<sup>1</sup> · Yew Toong Liew<sup>1</sup> ·  
Sakina Ghauth<sup>1</sup> · Prepageran Narayanan<sup>1</sup> ·  
Zulkiflee Abu Bakar<sup>1</sup>

Received: 18 February 2022 / Accepted: 23 October 2022 / Published online: 7 November 2022  
© Association of Otolaryngologists of India 2022

**Abstract** The purpose of this study was to conduct a cadaveric dissection study on the anatomical variation of the sublingual (SLG) excretory ducts and dictate an improved understanding of the anatomical communication between the SLG duct and submandibular (SMG) ducts. This study is carried out by standardized dissection of anterior floor of mouth in 6 formalin-fixed adult cadavers in Silent Mentor Workshop University Malaya in August 2020. The cadavers had no trace of scars, adhesions, signs of trauma or operation. SMG duct opening was identified lateral to the lingual frenulum through a papilla in the floor of mouth behind the lower incisor tooth. A horizontal incision line was done over floor of mouth just lateral to the opening. SMG duct and SLG was traced and skeletonized. Any presence of major duct arising from the SLG and its communication with SMG duct were investigated. We found there are 3 patterns of SLG excretory duct variants; (1) One major (Bartholin's) duct which open independently at its own orifice adjacent to the orifice of the Wharton's duct of SMG. (2) One major (Bartholin's) duct which joined into the Wharton's duct of

SMG. (3) Absent of a major duct arising from SLG. The overall mean diameter of SLG ducts were  $1.3 \pm 0.41$  and the mean length of SLG ducts were  $18.5 \pm 6.55$ . The overall mean diameter of SMG ducts was  $2.6 \pm 0.74$  and the mean length of SMG ducts were  $46.5 \pm 6.57$ . Excretory ductal system of SLG showed great variations, not only between the different cadavers but also within the different sides of the same cadaver. Awareness of potential anatomical variations can aid in the accurate diagnosis and treatment of patients with salivary gland pathology as well as help surgeons reveal potential risk factor and avoid complications during surgical procedures in the floor of mouth.

**Keywords** Sublingual gland duct · Bartholin's duct · Submandibular gland · Wharton's duct

## Introduction

Sublingual gland (SLG) is smallest of the three major salivary glands, which includes parotid and submandibular gland (SMG). It is almond-shaped and weighs about 3–4 g. Each SLG lies medial to the sublingual fossa of the mandible and immediately lateral to the Wharton's duct of SMG and associated lingual nerve. It consists mainly of mucous acinar cells, and lies inferolateral to the tongue in the submucosal plane of the floor of the mouth superior to the mylohyoid muscles. The superior margin of the SLG raises an elongate fold of mucosa (sublingual fold), which extends from the posterolateral aspect of the floor of the oral cavity to the sublingual papilla beside the base of the frenulum of the tongue at the midline anteriorly. SLG contributes approximately 3–5% of the total salivary volume. It produces thick mucinous saliva which being continuously secretes in the interdigestive period. This helps to lubricates the oral cavity

✉ Yew Toong Liew  
lyewtoong@um.edu.my  
Nurul Asma Che Ab Rahim  
nrul.asma@gmail.com  
Sakina Ghauth  
sakina.ghauth@gmail.com  
Prepageran Narayanan  
prepa@um.edu.my  
Zulkiflee Abu Bakar  
abzulkiflee@um.edu.my

<sup>1</sup> Department of Otorhinolaryngology, Faculty of Medicine, University of Malaya, Jalan Universiti, 50603 Kuala Lumpur, Malaysia

which allows for swallowing, initiating digestion, buffering pH and dental hygiene.

Each SLG is subdivided into anterior and posterior parts, and each part has a different drainage system. Two excretory duct types of the SLG has been recorded in the literature, namely the Rivinus's and Bartholin's duct [1]. Rivinus duct is made up of 8–20 small minor ducts originating from the posterior part of SLG and empties in the floor of mouth at the crest of sublingual folds. The ducts from anterior SLG may unite to form a major duct, sublingual duct of Bartholin's and were first described by Caspar Bartholin in 1685 [1]. There were multiple anatomical variation of the major duct reported in the literature [2–4], where the two most common patterns are where the ducts open independently and drained via a separate opening in the sublingual papilla, or it joins and drained via the Wharton's duct of the SMG. The purpose of this study was to conduct a cadaveric study on anatomical variation of the SLG excretory ducts and dictate an improved understanding of the anatomical communication between the SLG duct and SMG ducts, which should be helpful for surgery related to the SLG and SMG.

## Methodology

This research was approved by University Malaya Ethics Committee and the Silent Mentor Workshop organization. Written and verbal informed consent was taken from next of kin and family members for usage of cadaver for teaching and medical research. This study was carried out by standardized dissection of the anterior floor of mouth in adult cadavers in the Silent Mentor Workshop University Malaya in August 2020 under surgical loupes guidance with magnification of 2.5 mm. The cadavers were fixed with 10% formalin and had no trace of scars, adhesions, signs of trauma or operation. Opening of mouth is sustained using bite block with retraction of the tongue towards the opposite site. SMG duct opening identified lateral to the lingual frenulum through a papilla in the floor of mouth behind the lower incisor tooth. A horizontal incision line done over floor of mouth just lateral to the opening. SMG duct and SLG was traced and skeletonized. Any presence of major duct arising from the SLG and its communication with Wharton's duct were investigated.

This study consisted of three parts; (1) recording demographic data of cadaver which includes age, gender and ethnicity, (2) obtaining non metrical morphological data of the anatomical variation of the SMG and SLG ducts, (3) obtaining morphometric diameter and length measurement of SMG and SLG duct. All measurements were taken using sliding calliper with an accuracy of 0.5 mm. All the measurements were performed by the same examiner (first author) and descriptive analyses reporting on the mean and

standard deviation of length and diameter of SMG and SLG duct was performed using SPSS 20.

## Results

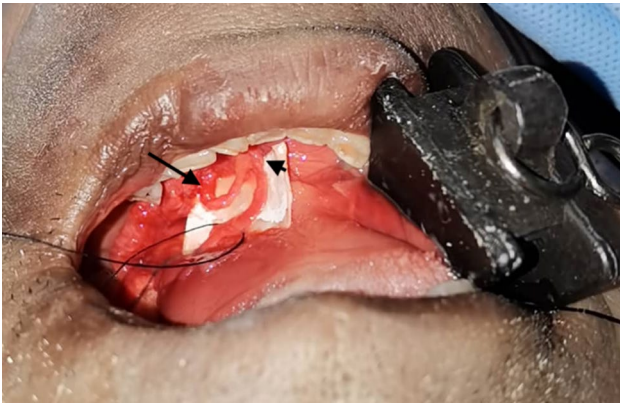Six adult cadavers which consist of 4 male cadavers and 2 female cadavers in Silent Mentor Workshop UM were the subjects of the anatomic study, which accounts for a total 12 SMG and SLG ducts. All 6 cadavers were of Chinese ethnicity. 4 (33.3%) of the 12 SLGs were found to have a major (Bartholin's) duct originate from the anterior part of the gland (Table 1). We observed 3 excretory SLG duct pattern in this study. (1) In 3 (25%) of the 12 glands a major SLG duct was fused to the middle section of the SMG duct, with a mean diameter of the duct 1.5 mm and mean length of 15.3 mm (Fig. 1). (2) In 1 (8.3%) of the 12 glands, a major SLG runs parallel to the Wharton's duct and open independently at the sublingual papilla with a diameter of 1.5 mm and length of 28 m (Fig. 2). (3) The rest of the 8 (66.7%) glands have no major excretory duct. The overall mean diameter of SLG ducts were  $1.5 \pm 0.41$  and the mean length of SLG ducts were  $18.5 \pm 6.55$ .

All the SMG duct courses between the mylohyoid and hyoglossus muscles, extends anteriorly, and opens at the sublingual papilla. The mean diameter of SMG ducts was  $2.6 \pm 0.74$  and the mean length of SMG ducts were  $46.5 \pm 6.57$ .

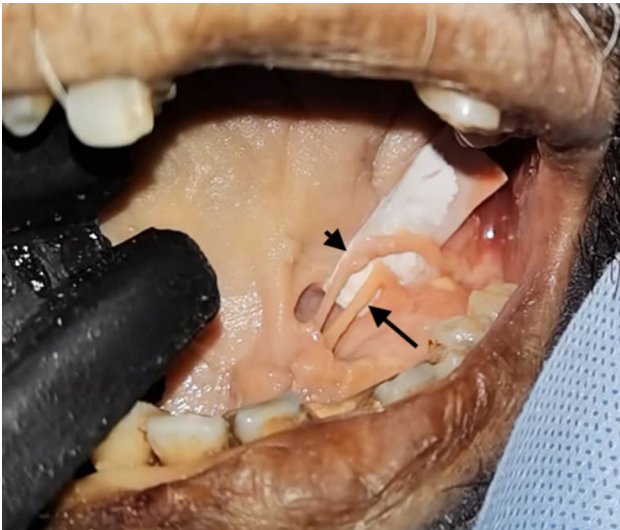
The majority of lingual nerve course inferior to Wharton's duct as it passes upwards and forwards into the hyoglossus muscle which accounts for 75% (9 of 12 cases). 1 (8.3%) of

**Table 1** Demographic and morphometric data analysis

<i>Age</i>	
Range	40–76
Mean + SD	$64.8 \pm 12.7$
<i>Sex</i>	
Male	4 (66.7%)
Female	2 (33.3%)
<i>Ethnicity</i>	
Chinese	6 (100%)
<i>Major SLG duct</i>	
Present	4 (33.3%)
Absent	8 (66.7%)
<i>Exit point of major SLG duct</i>	
Join SMG duct	3
Open independently	1
Mean diameter of SLG duct (mm)	$1.3 \pm 0.41$ (1–2)
Mean length of SLG duct (mm)	$18.5 \pm 6.55$ (13–17)
Mean diameter of SMG duct (mm)	$2.6 \pm 0.74$ (2–4)
Mean length of SMG duct (mm)	$46.5 \pm 6.57$ (40–55)

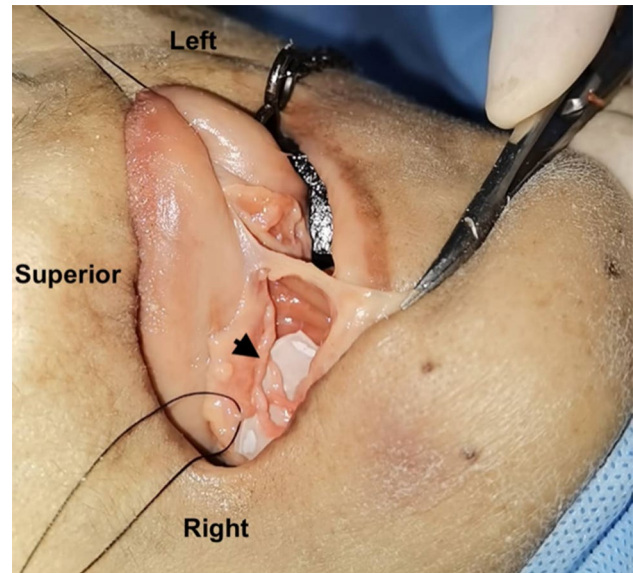


**Fig. 1** Image showed left SLG has a major duct (black arrow) that joins the SMG duct (black arrowhead) prior opening at the papilla



**Fig. 2** Image showed left SLG has a major duct (black arrow) that runs parallel with SMG duct (black arrowhead) and opens independently at the papilla

12 lingual nerve loops superiorly to the Wharton's duct. One cadaver has a rare duplication of SMG ducts bilaterally where two ducts arise from each gland (Fig. 3). The main duct was larger whereas the accessory duct was slightly narrower. Both ducts rose independently from the submandibular gland and merged together to become the Wharton's duct, and opens into the floor of mouth on the top of the sublingual papilla next to the frenulum of the tongue. Both lingual nerve (16.7%) transverse in between both ducts prior descending anteromedially to the hyoglossus muscle.



**Fig. 3** Image showed two SMG duct merged together (arrowhead) and heading towards the papilla, with right lingual nerve course in between (tied with suture)

## Discussion

The most common pathology of the SLG is the ranula, which is a pseudocyst of the floor of the mouth resulting from mucus retention in the SLG ductal system or extravasation of saliva as a result of SLG ductal disruption due to trauma or inflammation [4, 5]. One of the possible cause of intraoral ranula formation was suggested to be due to anatomical variation of the excretory ductal system of the SLG [4, 5], where one of the anatomic variant of a major Bartholin's duct of SLG that joined and emptied into the Wharton's duct. As the major salivary flow of the Wharton's duct increases, it may lead to increase back pressure on the fragile Bartholin's duct causing functional obstruction of the duct and rupture of the SLG acini [4]. As a result, saliva of the SLG may accumulate in the floor of mouth, leading to intraoral non-plunging ranula.

Zhang et al. [2] reported three patterns of excretory SLG duct in 30 cadaveric dissection of normal population and 63 patients with keratoconjunctivitis sicca undergone autologous SMG transfer. From the 60 sublingual ducts in the cadaveric dissection arm; (1) 23.3% (14 of 60 SLG) have a major duct opened independently at the sublingual caruncle, (2) 40% (24 of 60 SLG) have a major duct joined into the middle section of the SMG duct, and (3) 36.7% (22 of 60 SLG) have many fine ducts that open at the floor of mouth. This mirrors our cadaveric study where we also found three patterns of excretory SLG duct, although the percentages of patterns were quite different which may be attributed to the differences in sample size.

A definitive treatment of choice for intraoral ranula is complete excision of the pseudocyst and SLG. Division and ligation of the Bartholin's duct near the Wharton's duct is imperative to avoid fistula of the duct after surgery [3–5]. Chen et al. [3] concluded recurrence of cystic mass post SLG excision might be due to iatrogenic saliva accumulation through previous surgically damaged remnant branch of Bartholin's duct which connected to the Wharton's duct. In addition, marsupialization of the SLG duct at the floor of mouth could theoretically decrease the incidence of recurrence.

The SLGs accounts for 1% sialolithiasis and sialadenitis cases [6]. Because of its low incidence, it may be underdiagnosed and mistaken for SMG sialolithiasis. Goodstein et al. [6] reported 4 cases of sublingual gland sialolithiasis presented with single episode of gland swelling unrelated to meals. All four cases were managed with a combined approach, using sialoendoscopy and transoral excision of the sialolith. 3 out of the 4 sialolith was located in the major Bartholin's duct where it empties into the Wharton's duct. If an anatomic variant where a major Bartholin's duct opens directly into the sublingual papilla, it can be difficult to distinguish the orifice of the SMG duct from that of the SLG during sialoendoscopy or sialography procedures. Avril et al. [7] reported a series of cases in whom inadvertent sialography of the sublingual ducts occurred during attempts at submandibular sialography. In the case series performed retrospectively over a 6 years period, from a total of 104 attempted SMG digital subtraction sialography (DSS), 6 unintended SLG DSS studies were found. Nahlieli et al. [8] also cited Bartholin duct as one the anatomic variant that have been encountered in the course of sialoendoscopic procedures for patients with inflammatory salivary gland disease. Corbett et al. [9] briefly addresses this technical aspect relevant for sequential catheterization and sialography of Wharton's and Bartholin's duct, where it was noted that during cannulation of SMG duct, if a cannula is inserted up to 1 cm through the sublingual papilla, it will generally pass into the Wharton duct and therefore bypass the point of potential confluence with the Bartholin's duct, which would exclude the possibility of inadvertent cannulation of SLG duct. This aligned with our findings where the mean length of Bartholin's ducts were  $18.5 \pm 6.55$  mm whereas length of Wharton's duct were  $46.5 \pm 6.57$  mm. It is also important to be aware of rare congenital anomalies of the Wharton's duct that can render interpretation confusing [10, 11], as that was found in one of the cadaver in our studies where there was a duplicated Wharton's duct arising from each SMG.

A renewed interest of this anatomical variation recently arises in microvascular autologous submandibular gland duct transfer for treatment of severe keratoconjunctivitis sicca [7]. Key element of this procedure is harvesting an intact Wharton/s duct without damaging the duct draining the SLG before transferring the Wharton's duct with its gland

to the upper lateral conjunctival fornix to replace the lacrimal gland. The need to preoperatively confirmed the precise anatomic relations between the Bartholin's and Wharton's ducts in the floor of mouth is crucial and irrigation of the duct with normal saline solution is necessary to check for fistula of the duct.

This is a descriptive cadaveric research; hence it has limited novelty as compared to a meta-analysis. We employed on the practical and clinical significance of the variations of sublingual gland ducts when designing this study and to provide us with additional information to fill our current gaps on knowledge with regards to the sublingual glands excretory ducts variation among Malaysians.

During the execution of this research, Malaysia has ordered a restrict movement due to a pandemic COVID-19 cases worldwide. Since the movement control order is being enforced in a lengthy duration of time, we were limited by the number of cadavers and silent mentor workshop available. In addition, the population of the research is limited to single institution and single ethnicity, the findings may not be possible to be extrapolated to the general population.

## Conclusion

Excretory ductal system of SLG showed great variations, not only between the different cadavers but also within the different sides of the same cadaver. Awareness of potential anatomical variations can aid in the accurate diagnosis and treatment of patients with salivary gland pathology as well as help surgeons reveal potential risk factor and avoid complications during surgical procedures in the floor of mouth.

## Declaration

**Conflict of interest** There is no conflict of interest or financial relationships relevant to this project to disclose.

## References

1. Lydiatt DD, Bucher GS (2012) The historical evolution of the understanding of the submandibular and sublingual salivary glands. *Clin Anat* 25(1):2–11
2. Zhang L, Xu H, Cai ZG et al (2010) Clinical and anatomic study on the ducts of the submandibular and sublingual glands. *J Oral Maxillofac Surg* 68:606–610
3. Chen CJ, Guo P, Chen XY (2015) Recurrent sublingual ranula or saliva leakage from the submandibular gland? Anatomical consideration of the ductal system of the sublingual gland. *J Oral Maxillofac Surg* 73(4):675.e1–675.e7
4. Mun SJ, Choi HG, Kim H, Park JH, Jung YH, Sung M-W et al (2014) Ductal variation of the sublingual gland: a predisposing factor for ranula formation. *Wiley Online Library* 36(4):540–544

5. Zhang B, Yang Z, Zhang RM, Liu L, Zhang F, Chen J et al (2016) Are the patient with anatomic variation of the sublingual/Wharton's duct system predisposed to ranula formation? *Int J Pediatr Otorhinolaryngol* 83:69–73
6. Goodstein L, Galinat L, Curry J, Luginbuhl A, Cognetti D (2017) Sialendoscopy for sublingual gland sialolithiasis. *Ann Otol Rhinol Laryngol* 126(3):216–218
7. Horsburgh A, Massoud TF (2013) Lessons learned from unintended sublingual sialography: imaging anatomy, technical considerations, and diagnostic implication. *AJR Am J Roentgenol* 200(4):879–883
8. Nahlieli O, Abraham M (2000) Baruchin: long-term experience with endoscopic diagnosis and treatment of salivary gland inflammatory diseases. *Laryngoscope* 110(6):988–993
9. Corbett RH (1975) Submandibular sialography: an unusual complication. *Br J Radiol* 48:1032–1033
10. Billakanti PB (2017) Accessory duct of the submandibular gland. *Sultan Qaboos Univ Med J* 17(1):e119-120
11. Ramalingam S (2019) A rare occurrence of unilateral duplication of Wharton's duct with their intrasublingual glandular course: a cadaveric report. *JMS* 2(1):12–17

**Publisher's Note** Springer Nature remains neutral with regard to jurisdictional claims in published maps and institutional affiliations.

Springer Nature or its licensor (e.g. a society or other partner) holds exclusive rights to this article under a publishing agreement with the author(s) or other rightsholder(s); author self-archiving of the accepted manuscript version of this article is solely governed by the terms of such publishing agreement and applicable law.