



# Neuroendocrine Liver Metastasis—A Specific Set of Markers to Detect Primary Tumor Sites

Andreas Selberherr<sup>1</sup> · Oskar Koperek<sup>2</sup> · Philipp Riss<sup>1</sup> · Christian Scheuba<sup>1</sup> · Reto Kaderli<sup>1</sup> · Aurel Perren<sup>3</sup> · Bruno Niederle<sup>1</sup>

Published online: 19 November 2018  
© The Author(s) 2018

## Abstract

The diagnosis of neuroendocrine neoplasia (NEN) is often made at an advanced stage of disease, including hepatic metastasis. At this point, the primary may still be unknown and sometimes cannot even be detected by functional imaging, especially in very small tumors of the pancreas (pan) and small intestinal (si) entities. The site of the primary may be based on biopsy specimens of the liver applying a specific set of markers. Specimens of liver metastases from 87 patients with NENs were studied. In retrospect, 50 patients had si and 37 pan NENs. Tissue samples were evaluated by immunohistochemistry. The markers applied were insulin gene enhancer protein Islet-1 (ISL-1), homeobox protein CDX-2 (CDX2), thyroid transcription factor 1 (TTF-1), and serotonin. Positive stains for CDX2 were documented in 43 (86%) and for serotonin in 45 (90%) of 50 siNENs. Three panNENs were positive for CDX2 and one for serotonin, respectively. ISL-1 was negative throughout in siNENs and also negative in 8 of 50 panNENs (21.6%). TTF-1 was negative in more than 90% of the specimens of either entity. Immunohistochemical markers in liver metastasis can lead the way to the site of the primary NEN. They should always be used in combined clusters.

**Keywords** Neuroendocrine neoplasia · Liver metastasis · CDX2 · Serotonin · Islet 1

## Introduction

Neuroendocrine neoplasia of the pancreas (pan) and especially the small intestine (si) is rare [1, 2], frequently has a long asymptomatic course [3, 4], and remains undiagnosed until radiological examinations are done due to diffuse abdominal symptomatology [5].

As shown recently, 43 (23.8%) of 181 patients with NEN located in various sites of the gastroenteropancreatic tract were diagnosed at presentation with liver metastasis. In five (1.8%)

additional patients, the primary could not be located. Even functional imaging failed to identify the primary in these patients [1].

The hint to the origin of the “unknown primary” may occasionally be based on biopsies of the liver applying specific immunohistochemical markers [6]. Insulin gene enhancer protein Islet-1 (ISL-1), thyroid transcription factor 1 (TTF-1), serotonin, and homeobox protein CDX-2 (CDX2) are transcription factors that can be expressed in pan and siNENs [7, 8].

To our knowledge, no systematic studies on differences regarding the expression of those markers in liver metastases of either entity have so far been published.

---

This paper is not based on a previous communication to a society or a meeting

---

✉ Andreas Selberherr  
andreas.selberherr@meduniwien.ac.at

## Methods

Fifty patients with siNENs of the ileum (20 females, 30 males; mean age 61, range 37–81) and 37 patients with panNENs (21 females, 16 males; mean age 54, range 25–81) and synchronous liver metastasis were retrospectively analyzed. The metastases were evaluated histologically, and immunohistochemical staining of chromogranin A, synaptophysin, Ki-67, ISL-1, TTF-1, CDX2, and serotonin was performed.

<sup>1</sup> Section “Endocrine Surgery”, Division of General Surgery, Department of Surgery, Medical University Vienna, Währinger Gürtel 18-20, 1090 Vienna, Austria

<sup>2</sup> Department of Pathology, Medical University, Währinger Gürtel 18-20, 1090 Vienna, Austria

<sup>3</sup> Institute of Pathology, University of Bern, Murtenstrasse 31, 3012 Bern, Switzerland

Tumor tissue was routinely formalin-fixed and paraffin-embedded. Hematoxylin and eosin staining was applied to 3- $\mu$ m sections of each block. Immunostainings against proliferation marker Ki-67 antigen (Molecular Immunology Borstel 1 [MIB-1] mouse monoclonal, Novocastra, Newcastle, UK, dilution 1:20), CDX2 (1H9 mouse monoclonal, abcam, Cambridge, UK, undiluted), ISL-1 (1H9 mouse monoclonal, abcam, Cambridge, UK, dilution 1:400), TTF-1 (SP141 rabbit monoclonal, Ventana, Tucson, Arizona, USA, undiluted), and serotonin (5HT-H209 mouse monoclonal, DakoCytomation, Denmark, dilution 1:100) were performed using an automatic immunostainer (Ventana Medical Systems Inc., BenchMark® or BenchMark® ULTRA, Tucson, Arizona, USA). For antigen retrieval, slides for Ki-67, CDX2, ISL-1, and TTF-1 staining were boiled with a commercially available puffer (Ventana Medical Systems Inc., Cell Conditioning 1, Tucson, Arizona, USA) for 256, 256, 64, and 180 min, respectively. A commercially available amplification kit (Ventana Medical Systems Inc., Amplification Kit, Tucson, Arizona, USA) was used for Ki-67 staining. Protease 1 pretreatment (for 8 min) was applied for serotonin staining.

The histologies of all cases were reviewed by one experienced pathologist (O.K.), classified according to the WHO classification outlined in 2017 [9, 10] and staged according to the European Neuroendocrine Tumor Society guidelines of 2006 and Union international contre le cancer 2010 [9–11]. For grading, the Ki-67 labeling index with MIB-1 antibody was used and the Ki-67 index was assessed in 500 tumor cells in areas in which the highest nuclear labeling was observed using an eye grid ocular. Expression of ISL-1, TTF-1, CDX2, and serotonin was evaluated semiquantitatively as follows: no tumor staining (–), weak: staining in  $\leq 10\%$  (+), moderate: staining in  $> 10$  and  $< 100\%$  (++) and strong: 100% of cells (+++).

## Results

All 87 liver metastases were of neuroendocrine origin confirmed by both synaptophysin and chromogranin A expression. The primary tumor was detected with further evaluations of the patients (functional imaging, endoscopic ultrasound with biopsy), and adequate treatment was performed as feasible. The immunohistochemic profile of the primary was identical to the liver metastasis in all cases. The details of the staining patterns are summarized in Table 1.

### CDX2

The stains for CDX2 were at least moderately positive in 92% of the siNENs and negative in 92% of the panNENs.

**Table 1** Staining pattern in siNENs and panNENs

	siNEN <i>n</i> = 50 (%)	panNEN <i>n</i> = 37 (%)
Serotonin		
+++	45 (90)	0
++	0	1 (2.7)
+	0	0
–	5 (10)	36 (97.3)
CDX2		
+++	43 (86)	1 (2.7)
++	3 (6)	0
+	0	2 (5.4)
–	4 (8)	34 (91.9)
ISL-1		
+++	0	24 (64.9)
++	0	4 (10.8)
+	0	1 (2.7)
–	50 (100)	8 (21.6)
TTF-1		
+++	2 (4)	3 (8.1)
++	0	0
+	0	0
–	48 (96)	34 (91.9)

Semiquantitative analysis: (–) no staining, (+) weak staining  $\leq 10\%$ , (++) moderate staining  $> 10$  and  $< 100\%$ , (+++) strong staining 100%

*Si* small intestine (ileal), *pan* pancreatic, *NEN* neuroendocrine neoplasia

### ISL-1

ISL-1 was negative in all siNENs, whereas 75% of the pan tumors showed at least a moderate stain.

### Serotonin

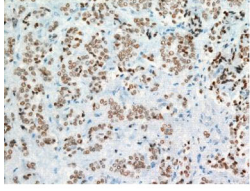
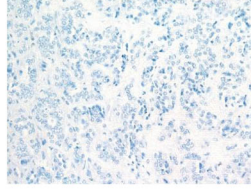
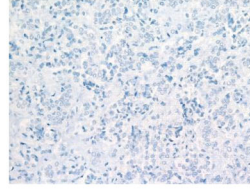
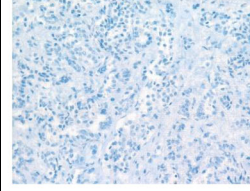
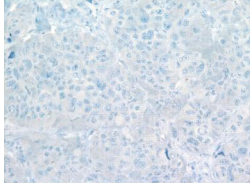
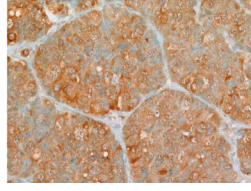
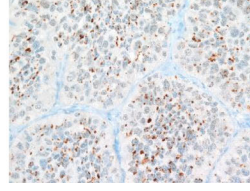
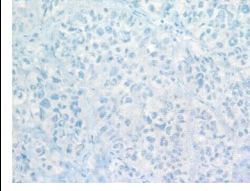
Serotonin showed strong positive stains in 90% of the siNENs, whereas it was moderately positive in only one panNEN (2.7%).

### TTF-1

Immunostaining for TTF-1 was negative in most siNENs (96%) and panNENs (92%).

### Combined Staining

Positive staining of CDX2 and serotonin yielded an almost 100% specificity for the siNENs. Photomicrographs of the typical staining pattern of liver metastasis of an ileal NEN compared to a pancreatic NEN are shown in Fig. 1.

Stain of liver metastasis	ISL-1	Serotonin	CDX2	TTF-1
Pancreas				
Ileum				

**Fig. 1** The top row shows the typical staining pattern of a neuroendocrine liver metastasis of pancreatic provenience with strong positivity of ISL-1, whereas the bottom row illustrates the staining pattern of a liver metastasis of an ileal NEN, yielding positivity for serotonin and CDX2

## Discussion

Patients with NENs frequently share a long way of suffering due to uncertainty. Unspecific abdominal symptoms lead to radiological examinations of liver lesions, and biopsy may evidence NENs. The journey then continues, as the primary is still missing. As shown recently [1], at least 2% of all NENs are diagnosed with an unknown primary. In this study, the expression of various immunohistochemical markers in the liver metastases of subjects with NEN was examined and the frequency of the positivity of the set of markers was analyzed. Retrospectively, the staining quality of the markers was correlated with the sites of the NEN, by definition being either the si or the pan. The results of the analysis applying a specific set of neuroendocrine markers on liver biopsies should help to gain information concerning the possible sites of the NEN in patients with unknown primary but liver metastasis.

Serotonin has been proposed to be a potent marker for siNENs in biopsies [6]. In the current series, however, serotonin was positive in 90% of the siNENs and only moderately positive in one panNEN, thus being consistent with the literature [12] and resulting in high levels of sensitivity and specificity. While CDX2 has been reported to be positive in almost all siNENs [13–15], we can only confirm that it was at least moderately positive in 90% in our series. CDX2 was negative in over 90% of the panNENs, thus showing higher specificity than previous findings [13, 16] and suggesting that CDX2 is a key marker (in combination with serotonin) to differentiate siNENs from panNENs.

ISL-1 was seen to be an ideal marker to exclude siNENs, as no positive stain was found in our specimens. In line with other authors' findings [17–19], however, panNENs can neither be excluded nor confirmed with this single marker, as more than 20% of the liver metastases of panNENs in our series were immunohistochemically negative for ISL-1.

TTF-1 should not be considered a valuable marker to distinguish between siNENs and panNENs, as the vast majority of liver metastases of either entity were negative for TTF-1 labeling. Still, it remains highly useful to discriminate gastroenteropancreatic NENs from those of the lung [20].

In the current study, the combination of these markers was applied to differentiate siNENs with ileal primaries from panNENs. As demonstrated, the combination of positivity for CDX2 and serotonin in liver metastasis showed an almost 100% level of specificity for NENs of si origin. Therefore, (at least) this combination of markers should be used when considering si provenance in patients with liver metastasis and an unknown primary. Furthermore, functional imaging should be applied in any patient with a metastatic NEN. Therefore, immunohistochemical markers must always be seen in connection with clinical and diagnostic findings to serve the patient best. A single marker cannot replace the diagnostic algorithm in complex neuroendocrine tumors.

**Funding Information** Open access funding provided by Medical University of Vienna.

## Compliance with Ethical Standards

**Conflict of Interest** The authors declare that they have no conflict of interest.

**Ethical Approval** All procedures performed in this study involving human material were in accordance with the ethical standards of the institutional research committee and with the 1964 Helsinki declaration and its later amendments or comparable ethical standards.

**Informed Consent** Informed consent was obtained from all individual participants included in the study.

**Open Access** This article is distributed under the terms of the Creative Commons Attribution 4.0 International License (<http://creativecommons.org/licenses/by/4.0/>)

creativecommons.org/licenses/by/4.0/), which permits unrestricted use, distribution, and reproduction in any medium, provided you give appropriate credit to the original author(s) and the source, provide a link to the Creative Commons license, and indicate if changes were made.

## References

- Niederle MB, Hackl M, Kaserer K, Niederle B. Gastroenteropancreatic neuroendocrine tumours: the current incidence and staging based on the WHO and European Neuroendocrine Tumour Society classification: an analysis based on prospectively collected parameters. *Endocr Relat Cancer*. 2010;17(4):909–918.
- Selberherr A, Niederle MB, Niederle B. Surgical Treatment of Small Intestinal Neuroendocrine Tumors G1/G2. *Visc Med*. 2017;33(5):340–343.
- Lawrence B, Gustafsson BI, Chan A, Svejda B, Kidd M, Modlin IM. The epidemiology of gastroenteropancreatic neuroendocrine tumors. *Endocrinology and metabolism clinics of North America*. 2011;40(1):1–18, vii.
- Yao JC, Hassan M, Phan A, Dagohoy C, Leary C, Mares JE, Abdalla EK, Fleming JB, Vauthey JN, Rashid A, Evans DB. One hundred years after "carcinoid": epidemiology of and prognostic factors for neuroendocrine tumors in 35,825 cases in the United States. *Journal of clinical oncology : official journal of the American Society of Clinical Oncology*. 2008;26(18):3063–3072.
- Niederle MB, Niederle B. Diagnosis and treatment of gastroenteropancreatic neuroendocrine tumors: current data on a prospectively collected, retrospectively analyzed clinical multicenter investigation. *Oncologist*. 2011;16(5):602–613.
- Kloppel G, Couvelard A, Perren A, Komminoth P, McNicol AM, Nilsson O, et al. ENETS Consensus Guidelines for the Standards of Care in Neuroendocrine Tumors: towards a standardized approach to the diagnosis of gastroenteropancreatic neuroendocrine tumors and their prognostic stratification. *Neuroendocrinology*. 2009;90(2):162–166.
- Johnson A, Wright JP, Zhao Z, Komaya T, Parikh A, Merchant N, et al. Cadherin 17 is frequently expressed by 'sclerosing variant' pancreatic neuroendocrine tumour. *Histopathology*. 2014.
- Schmitt AM, Riniker F, Anlauf M, Schmid S, Soltermann A, Moch H, Heitz PU, Klöppel G, Komminoth P, Perren A. Islet 1 (Isl1) expression is a reliable marker for pancreatic endocrine tumors and their metastases. *The American journal of surgical pathology*. 2008;32(3):420–425.
- Lloyd RV. WHO classification of tumours of Endocrine Organs. 4th ed. Lyon: IARC Press; 2017.
- Rindi G, Kloppel G, Alhman H, Caplin M, Couvelard A, de Herder WW, et al. TNM staging of foregut (neuro)endocrine tumors: a consensus proposal including a grading system. *Virchows Archiv : an international journal of pathology*. 2006;449(4):395–401.
- Sobin L, Gospodarowicz M, Wittekind C. TNM classification of malignant tumours. 7th ed. New York: Wiley-Blackwell; 2009. 58–62 p.
- Kloppel G, Rindi G, Anlauf M, Perren A, Komminoth P. Site-specific biology and pathology of gastroenteropancreatic neuroendocrine tumors. *Virchows Arch*. 2007;451 Suppl 1:S9–27.
- Zimmermann N, Lazar-Karsten P, Keck T, Billmann F, Schmid S, Brabant G, Thoms C. Expression Pattern of CDX2, Estrogen and Progesterone Receptors in Primary Gastroenteropancreatic Neuroendocrine Tumors and Metastases. *Anticancer research*. 2016;36(3):921–924.
- Chan ES, Alexander J, Swanson PE, Jain D, Yeh MM. PDX-1, CDX-2, TTF-1, and CK7: a reliable immunohistochemical panel for pancreatic neuroendocrine neoplasms. *Am J Surg Pathol*. 2012;36(5):737–743.
- Yang MX, Coates RF, Ambaye A, Cortright V, Mitchell JM, Buskey AM, Zubarik R, Liu JG, Ades S, Barry MM. NKX2.2, PDX-1 and CDX-2 as potential biomarkers to differentiate well-differentiated neuroendocrine tumors. *Biomark Res*. 2018;6:15.
- Lin X, Saad RS, Luckasevic TM, Silverman JF, Liu Y. Diagnostic value of CDX-2 and TTF-1 expressions in separating metastatic neuroendocrine neoplasms of unknown origin. *Appl Immunohistochem Mol Morphol*. 2007;15(4):407–414.
- Koo J, Zhou X, Moschiano E, De Peralta-Venturina M, Mertens RB, Dhall D. The immunohistochemical expression of islet 1 and PAX8 by rectal neuroendocrine tumors should be taken into account in the differential diagnosis of metastatic neuroendocrine tumors of unknown primary origin. *Endocrine pathology*. 2013;24(4):184–190.
- Agaimy A, Erlenbach-Wunsch K, Konukiewicz B, Schmitt AM, Rieker RJ, Vieth M, et al. ISL1 expression is not restricted to pancreatic well-differentiated neuroendocrine neoplasms, but is also commonly found in well and poorly differentiated neuroendocrine neoplasms of extrapancreatic origin. *Modern pathology : an official journal of the United States and Canadian Academy of Pathology, Inc*. 2013;26(7):995–1003.
- Graham RP, Shrestha B, Caron BL, Smyrk TC, Grogg KL, Lloyd RV, Zhang L. Islet-1 is a sensitive but not entirely specific marker for pancreatic neuroendocrine neoplasms and their metastases. *The American journal of surgical pathology*. 2013;37(3):399–405.
- Zhang C, Schmidt LA, Hatanaka K, Thomas D, Lagstein A, Myers JL. Evaluation of napsin A, TTF-1, p63, p40, and CK5/6 immunohistochemical stains in pulmonary neuroendocrine tumors. *American journal of clinical pathology*. 2014;142(3):320–324.