

The Classic

Clinical and Experimental Observations with Regard to the Injection of Certain Agents (Pregl's Solution) into Chronic Arthritic Joints*

J. E. M. Thomson MD (1889–1962)
The 14th President of the AAOS 1946

J.E.M. (Tommy) Thomson was born in Los Angeles, California in 1889, of “pious and scholarly” parents with “evangelistic...interests” [3]. His grandfather had been a missionary bishop in the Methodist Church. He attended Evanston Academy and then Northwestern University. While he began his medical studies at Texas Christian College, he completed his medical education at Rush Medical College in 1915. He took an internship in Chicago, where his mentors reportedly included Drs. Edwin Ryerson (first President of the AAOS), John Ridlon, and Dallas Phemister [3]. In 1916 he began medical practice with H. Winnett Orr in Lincoln, Nebraska. During WW I he served in the University of Nebraska Overseas Base Hospital No. 49. He returned to practice after the war in 1919 and remained in Lincoln during his professional life. In addition to his professional interests, he and his wife shared an interest in cattle breeding and for a while had extensive ranching interests in Nebraska. The last few years of his life were spent in semiretirement in Rancho Santa Fe, California.

Dr. Thomson traveled widely and made many friends worldwide. In 1955 he took a trip around the world but he had many other travels and was an honorary member of a number of foreign orthopaedic societies including the Czechoslovakian Orthopaedic Society, The Polish Orthopaedic and Trauma Society, the Finnish Orthopaedic Association, and the Latin American Society of Orthopaedics and Traumatology. Dr. Thomson traveled to all continents except Australia. He was a founding member of the Orthopaedic Research society. As with a number of the early offices of the AAOS, Dr. Thomson was active in the American Orthopaedic Association and the Clinical Orthopaedic Society and served as President of the latter in 1936. The Instructional Course Lectures were evidently his

“brainchild” [3]. The record is unclear of the beginnings, although they evidently arose out of motion picture exhibits. What is clear is the first Instructional Course Lectures were presented in 1942 and published in 1943 with Dr. Thomson as editor. At the 1946 annual meeting, Dr. Thomson was selected to “establish and monitor the Instructional Course Lectures” [2]. He continued to serve as editor of the published Instructional Course Lectures until 1948. One account suggests the idea of a central office was his, and that he personally furnished a temporary central office in Lincoln until permanent headquarters could be established [1]. He was a man of great energy and bearing. In his Presidential Lecture he commented, “There is an old saying – you can’t make a silk purse out of a pig’s ear. I sometimes feel that in our post-war fervor, in behalf of the veterans separated from military service, we tend to encourage some conscientious young men to enter a field of training for which they are totally unsuited.” Despite infirmities in his last years (he had bilateral hip prostheses), he continued to be active, and died while giving lectures at the University of Kansas (“as he would have wished ‘with his boots on.’” [3]).

The article we reprint here reflects Thomson’s innovative thinking. Surgical alternatives for chronic arthritis were not well developed in 1932 and Thomson explored a method described by Pregl of Vienna [4]. Pregl injected a “secret preparation” that was a “non-irritating, non-staining, watery solution of free and combined iodine with certain iodides.” Thomson described his own similar solution, and used two to five injections spaced five to seven days apart. He reported the results in 15 patients, most with undefined or posttraumatic arthritis, but one with gonorrheal and one with likely acute joint sepsis, and two



J.E.M. Thomson, MD is shown. Photograph is reproduced with permission and ©American Academy of Orthopaedic Surgeons. *Fifty Years of Progress*, 1983.

with bursitis (olecranon and prepatellar). He further produced experimental arthritis in four rabbits by injection of microbes or a dilute carbolic acid solution. Two to four weeks later, he injected Pregl's solution and noted resolution. His observations, he concluded, warranted "further investigation and a more general use of Pregl's solution in treating chronic effusion of arthritic and traumatized joints."

Richard A. Brand MD

References

1. Heck CV. *Commemorative Volume 1933–1983 Fifty Years of Progress*. Chicago, IL: American Academy of Orthopaedic Surgeons; 1983.
2. Heck CV. *Fifty Years of Progress: In Recognition of the 50th Anniversary of the American Academy of Orthopaedic Surgeons*. Chicago, IL: American Academy of Orthopaedic Surgeons; 1983.
3. James E. M. Thomson 1889–1962. *J Bone Joint Surg Am*. 1963;45:206–208.
4. Thomson JEM. Clinical and experimental observations with regard to the injection of certain agents (Pregl's solution) into chronic arthritic joints. *J Bone Joint Surg Am*. 1933;15:483–490.

© The Association of Bone and Joint Surgeons 2008

(The Classic Article is ©1933 by the Journal of Bone and Joint Surgery, Inc. and is reprinted with permission from Thomson JEM. Clinical and experimental observations with regard to the injection of certain agents (Pregl's solution) into chronic arthritic joints. *J Bone Joint Surg Am*. 1933;15:483–490.)

*Presented at the Annual Meeting of the American Orthopaedic Association, Toronto, Canada, June 16, 1932.

Richard A. Brand MD (✉)
Clinical Orthopaedics and Related Research, 1600 Spruce Street,
Philadelphia, PA 19103, USA
e-mail: dick.brand@clinorthop.org

Chronic arthritis with persistent effusion and thickening of the capsule, whether due to infection or injury, or both, often defies the ordinary methods of treatment and proves disabling. Frequently, patients come with the story of painful swelling of the knee which has been constant for months, perhaps starting with an attack of rheumatism, a fall, or a sprain. The joint has become progressively larger, stiffer, and more disabling.

Certain of these conditions which are due to mechanical derangement of the knee cartilage, ligaments, etc., must be treated surgically for the correction of the derangement; even these cases often present a convalescence associated with chronic swelling of the joint. A small group of chronic infectious arthritis patients are benefited by synovectomy. It is difficult, however, to determine what cases are suitable for this treatment; but, if it could be accurately determined at what stage in the progress of an infectious arthritis the operation is indicated, the results would be gratifying. The operation has a definite field of usefulness, but, as Swett and others have indicated, it is not a panacea.

The results of injections have been uncertain. Occasionally there has been a decided shrinking in the size of the swelling and diminution of the secretion within the knee with relief of these symptoms, particularly when

accompanied by accurate treatment of the arthritic process.

Subsequent observations seem to justify the opinion that there is a mechanical or chemical reaction caused by the pathological phenomena of increased synovial secretion that has a retarding effect on the healing process of the arthritic joint. Furthermore, if some substance could be brought in contact with the synovia that would tend to diminish its secretion and shrink the tissue substance within the joint, there would be relief of the symptoms of distention, and of the mechanical irritation of the pathological synovial formations; and, by producing a more normal joint relationship of tissues, a better opportunity would be afforded by immunization, medication, physiotherapy, etc., to render an effective result.

My attention has been directed to Pregl's solution with which, in the clinics of Vienna, rather striking results have been obtained in the treatment of empyema, meningitis, and gonorrhoeal arthritis. This solution appeared first as a secret preparation, described by Pregl in 1919 as a non-irritating, non-staining, watery solution of free and combined iodine with certain iodides. He advocated its use in infections of all kinds, and it has been used by a large number of observers.

A résumé of the recent observations in regard to the therapeutic value of Pregl's solution convinced me that its

introduction into the joints would at least do no harm; furthermore, that the antiseptic properties and the astringent qualities exhibited by this iodine solution might prove valuable in treating chronic synovial effusions associated with chronic arthritis.

I had as a patient a doctor who, following an injury on the golf course, sustained a disabling swelling of an old arthritic knee joint. This condition had persisted for several weeks. He was willing to try anything; so with great temerity I drew out some clear, straw-colored fluid from the knee and injected five cubic centimeters of Pregl's solution. The result was indeed commendable. Within twenty-four hours he was better and the effusion remained markedly diminished. After three injections, five to seven days apart, the effusion had entirely disappeared and he started east on a trip. To date he has had no return of his former condition.

With this initial experience, a second case was tried with an equally gratifying result. The effusion seemed to melt away; or, at least, with each injection less effusion resulted, until finally practically normal contour was established in the joint. Unfortunately, no photographs have as yet been taken of any of our patients before or after treatment. Case histories themselves must tell the story. The formula used in the method of preparation of the solution which I use is as follows:¹

To a solution of crystallized sodium carbonate sixteen grams to thirty grams of water, add three grams of finely powdered iodine and allow it to stand for twenty-four hours, rotating frequently, or warm to forty degrees, centigrade, on a water bath. When all the iodine is in solution, add four grams of sodium chloride and water to make one liter.

Bring this to .035–.04 per cent. iodine by gently warming the solution, or part of it, until twenty cubic centimeters is decolorized by .55–.65 cubic centimeters of tenth normal sodium thiosulphate; or until the tint is the same, in equal liquid depth, as that obtained by a mixture of ten drops of tenth normal iodine and fifteen cubic centimeters of water.

The Pregl's solution may be injected into the knee joint, with the patient in the prone or the sitting position. When possible, it is preferable to have the patient sitting with the affected thigh flexed on the abdomen, and the patient's hands clasping the flexed leg on the thigh. This position separates the joint surfaces and places the effusion under considerable tension, thereby making it much easier to remove. It is not at all difficult to insert the aspirating needle into the joint from a point one-half inch internal to the lower patellar tendon, and half an inch above the articulating margin of the tibia. After painting a small area with iodine, two cubic centimeters of one per cent. novocain

are used to infiltrate the tissues down to and through the capsules; the aspirating needle is then inserted into the joint with little discomfort and the effusion withdrawn. No effort is made to remove all the synovial fluid. Into a small syringe are drawn five or ten cubic centimeters of Pregl's solution warmed to body temperature. This is injected into the joint, the needle removed, a small dressing applied, and the patient allowed to go about his business as usual.

No reaction has been noted either of a general or local type. Sometimes a patient will complain of pain and discomfort for the first few hours; after that considerable relief is expressed uniformly. In five to seven days this procedure is repeated, and usually two to five injections are sufficient to stop the effusion and relieve the symptoms.

Thirteen cases are summarized in the table. The synovial fluid withdrawn in each instance was cultured, and no growth occurred in a single instance. The following brief survey of two cases is illustrative of the uniform results obtained in the series summarized. The first case is one in which arthritis is complicated by injury; the second is of undetermined etiology.

CASE 1. (No. 0267.) Miss H., female, aged thirty, dietitian by occupation, had had an old arthritis in the right knee for many years. She slipped on the dance floor of the club in which she was employed, severely injuring the knee. She had all the symptoms of injury to the internal semilunar cartilage. On June 16, 1931, operation was performed. The cartilage was removed and was of the "bucket-handle" type. There was a destructive change in the cartilage surface of the condyles, and a generalized synovial pannus. Exploration of the outer side of the knee showed no evidence of injury to the external cartilage, but a similar arthritic process existed. She had an uneventful convalescence from the operation, and the wound healed by first intention. She continued to have swelling and profound disability and inability to use the knee. After four and a half months of physiotherapy and treatment of the arthritis, on October 3, 1931, twenty cubic centimeters of clear, straw-colored fluid were withdrawn from the knee, and five cubic centimeters of Pregl's solution were injected. Injections were continued at irregular intervals until April 18, 1932, there being sixteen injections in all. We were unable to withdraw any fluid at the occasion of the seventh injection. Function of the knee is very markedly improved, and she has a range of motion to eighty per cent. The knee is still quite thickened, but, as the knee has been enlarged for two or three years, it is a little difficult to tell how much shrinkage will result. Two months after the operation she resumed her duties, although she wore a brace until about four months ago. The effusion has entirely disappeared; she is much improved, and has no pain or discomfort in the knee. This has been by far the most serious case I have treated, and one which showed absolutely no progress until

¹ The method described is that which appeared in the *Journal of the American Medical Association*, LXXXI, 1628, 1923.

Table 1. Summary of cases with Pregl's solution

No.	Sex	Age	Occupation	Part injured	History	Previous treatment	Fluid withdrawn	Amount of Pregl's	No.	Result
Dr. C. 0237	M.	40	M.D.	Right knee	Old arthritis, injured by fall and twist, effusion, persistent for four weeks.	Aspiration, hot packs—temporary relief	18 c.c.	5 c.c.	4	Recovered
M. H. 0267	F.	30	Dietitian	Right knee	Injury to old arthritic knee, tear of internal semilunar cartilage; chronic synovitis; effusion.	Operation, physiotherapy, vaccines	5 to 30 c.c. clear	5 to 7 c.c.	16	No effusion or acute condition
C. N. 0297	M.	30	Lineman	Right knee	Chronic arthritis of long standing. Injury to internal semilunar cartilage. Arthritic changes discovered at operation. Second operation after Pregl's showed no evidence of previous arthritic condition.	Operation, physiotherapy, rest	Bloody fluid		5	Effusion destroyed; arthritis relieved
E. N. 01320	M.	27	Mechanic	Left knee	Extensive osteo-arthritis and synovitis. Previous operation and cast five years ago. Recent injury to crucial and external semilunar destruction of cartilage apparent at operation.	Operation, brace, physiotherapy, vaccines	15 c.c., of bloody fluid	5 to 7 c.c.	6	No effusion; arthritis arrested
D. H. Orth.	M.	26	Mechanic	Right knee	Internal semilunar injury and operation. Two months later, external cartilage injury. Destructive arthritic changes discovered at second operation. Wound filled with Pregl's solution.	Tried to work after first operation but could not	Bloody fluid, first two aspirations	7 c.c.	4	Recovered
B. 01689	M.	33	Farmer	Left knee	Injury four weeks prior to examination. X-ray negative. Persistent swelling and stiffness, pain.	Packs, rest	Clear fluid	5 c.c.	2	Complete recovery
H. C. C.	M.	29	Laborer	Left knee	Injury five weeks ago. Swelling and stiffness; completely disabled. X-ray negative. Arthritic history.	Iodides, packs, rest, vaccines	10 c.c., clear	5 c.c.	2	Recovered
L. C. C.	F.	56	H.W.	Right knee	Swelling and pain for two weeks, flare-up of old arthritis of knee.	Vaccines	Clear, straw	5 c.c.	2	Recovered
D. E. C. C.	F.	14	Child	Both knees	Effusion of both knees for two months, worse on right. No pain; some stiffness. All tests negative.	Vaccines	20 c.c., clear fluid, right	8 c.c.	5	Very much improved
K. 01787	F.	53	H.W.	Right knee	Chronic arthritis with effusion.	Vaccines	10 c.c., clear	5 c.c.	2	Recovered
F. 01788	M.	49	Mechanic	Right ankle	Acute pain and swelling following accident, few days previous. Fluctuation, redness. Temp. 101; W.B.C. 14500.		7 c.c., purulent	5 c.c.	1	Recovered
L. B. C. C.	M.	35	Laborer	Bursitis of elbow	Olecranon bursa—two weeks.		3 c.c., clear	3 c.c.	1	Recovered
G. G. C. C.	M.	20	Student	Left ankle	Gonorrhoeal arthritis of ankle—three weeks.	Vaccines	Purulent fluid	5 c.c.	1	Improved
Mrs. B.	F.	58	H.W.	Prepatellar bursitis	Bursitis from scrubbing.		Bloody	4 c.c.	1	Improved

Fig. 1 Rabbit No. L. Knee Joint No. 21 treated with Pregl's solution shows much less hypertrophy of the synovia and pannus than the untreated Knee Joint No. 29. There was considerable erosion of the cartilage in Knee Joint No. 29, whereas cartilage of No. 21 was smooth.

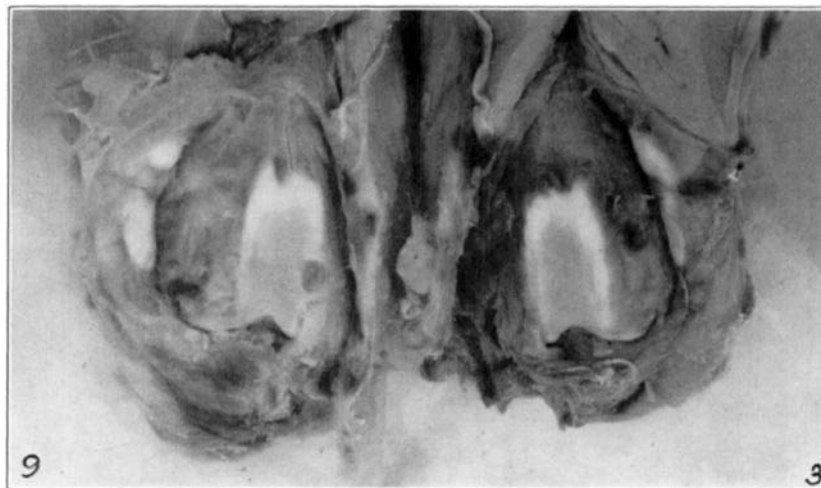
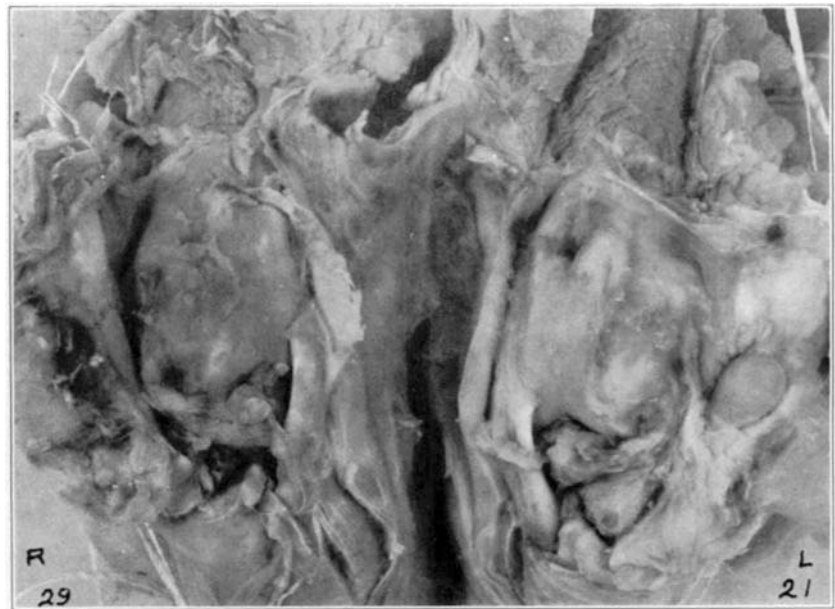
Fig. 2 Rabbit No. N. Note the marked difference in the synovia and cartilage edges between Knee Joint No. 9, which was treated with Pregl's solution, and Knee Joint No. 3, in which no treatment was administered. No. 3 was extremely red, thickened, with extension of

synovia over the femur with adhesions on the inner aspect, frayed margins, and destruction of the cartilage along the edges of the condyle as well as of the patella; while No. 9 had a clean, bright, normal-appearing synovia and the cartilage injury was apparently healing.

injections of Pregl's solution were started. She has received no treatment since the first part of April. Prior to that time she had come in occasionally and desired another injection of Pregl's solution as it seemed to give a certain amount of relief of discomfort in the knee. In this case, under ordinary circumstances, I would have performed a synovectomy, but she would not consent to an operative procedure.

CASE 2. Dorothy E. (City Clinic), female, aged fourteen. For six months she had had persistent swelling in both knees, the right more severe than the left. She was left with some stiffness and swelling together with pain. All tests for tuberculosis, syphilis, and gonococcus were negative.

Cultures from the effusion were negative. She was under observation for three or four months. About six weeks ago twenty-four cubic centimeters of clear, straw-colored fluid were drawn from the right knee and seven cubic centimeters of Pregl's solution were injected. After five injections the right knee had assumed nearly normal appearance and the swelling of the left knee had remained constant. Crowe's stock vaccine was given during this period, rather empirically. Two weeks ago the left knee was aspirated and injected with Pregl's solution, and improvement was evident at the time of the second injection. Although one of our more recent cases, she has proved most interesting in

that a similar condition existed in both knees with a chronic effusion that had lasted over six months. An accurate diagnosis has not been made; but, until this treatment was instituted, the condition had become progressively worse. The right knee, which was the more severely affected, was treated for five weeks with the result that it had assumed almost normal appearance, while the left knee remained constant. Now the Pregl's solution has been injected into the left knee, with the result that the effusion has disappeared. Both knees have assumed normal contour and appearance, and the patient now has no discomfort or disability.

The clinical manifestation of the value of Pregl's solution in the first few cases of chronic synovitis, or effusion associated with trauma and arthritis, led me to attempt an experimental study to determine the effect of the solution on the joints of rabbits affected with similar pathological conditions. This work was started in November 1931, and carried out in the experimental laboratory of the Lincoln General Hospital with the assistance of Dr. Fritz Teal, and Miss Mildred Wieland. We endeavored to follow the methods of stimulating arthritis and synovitis developed by Key and others. Our space was limited and few animals could be worked with at a time; therefore, we have not progressed very far with this problem. To date sixteen rabbits have been used, but, in order to carry out the project accurately, only four were brought to a sufficient culmination to allow a report of the results obtained.

Arthritis was produced by two methods, first, by introducing infection into the joint directly; second, by

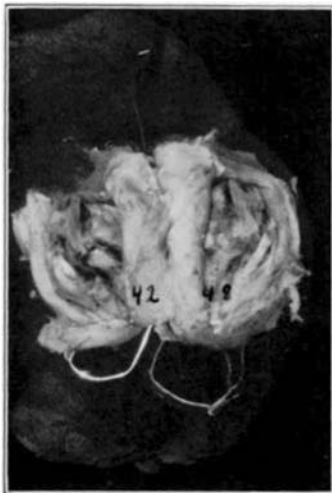


Fig. 3 Rabbit No. P. Knee Joint No. 42 was treated with Pregl's solution, four injections, while Knee Joint No. 48 was untreated. Cartilage of both joints was extensively destroyed before treatment was started. Knee Joint No. 42 into which the Pregl's solution was injected showed grossly marked healing of the diseased synovia; however there was but little healing of the cartilage; while the synovia of knee Joint No. 48, which was untreated, was very much thickened, red, and infected, and was filled with a purulent exudate.

introduction of one-half of a cubic centimeter of one per cent. carbolic solution and one-half strength tincture of iodine. In most instances a period of two to four weeks elapsed between the operative intervention and the beginning of treatment. All operations were carried out under strictly aseptic conditions. On account of the fact that we wanted exactly similar conditions in both knee joints of the same rabbit, an exploratory arthrotomy was performed before treatment was instituted, in order to determine whether the condition of both joints was similar. Then one joint was treated with Pregl's solution and the other allowed to heal without treatment. So far only gross specimens have been studied.

In adult rabbit No. L., streptococcus was introduced into both knee joints. Two weeks later the arthrotomy was performed and there was found a profound pannus and increase in synovia with changes about the joint surfaces of the condyles. Both knees appeared relatively the same. The rear extremities of the rabbit were numbered 21 and 29. The knee joint of No. 21 was injected with one and one-half cubic centimeters of Pregl's solution three days following the arthrotomy. Every three or four days thereafter a similar amount of Pregl's solution was introduced. At the end of four weeks the rabbit developed a respiratory infection and was sacrificed. There was marked synovial change and the knee joint cartilages of both looked slightly eroded. However, knee joint No. 21 (treated with Pregl's) showed much less hypertrophy and pannus of the synovia; the joint had margins which looked almost normal, but there was some cartilage erosion of the condyles similar to No. 29.

No. N., a young rabbit fourteen weeks old, had an arthrotomy in which extremity No. 3 had the synovia scraped and injured about the margins of the joint. In the knee of extremity No. 9 a section was taken out of the external condyle and the synovial edges about the joint were scraped. Two weeks later arthrotomy was again performed. Both joints seemed extremely red, swollen, and inflamed. Profound pannus existed throughout the joints with marked increase of synovial fluid. The knee joint of No. 9 was treated with Pregl's solution every three to five days for three weeks. The rabbit was then sacrificed. There was quite evident difference between the synovia of the treated and untreated joints. The knee joint of No. 3, showed a redness, thickening, and extension of synovia over the femur with adhesions about the inner aspect of the knee. However, the knee joint of No. 9 had a smooth, clean synovia similar to a normal rabbit's knee joint. The cartilage appeared to be healing, but with considerable thickening at the border.

Rabbit No. P. was a young rabbit fourteen weeks old. Both knee joints were injected with a culture of staphylococcus albus. Two weeks after injection was administered,

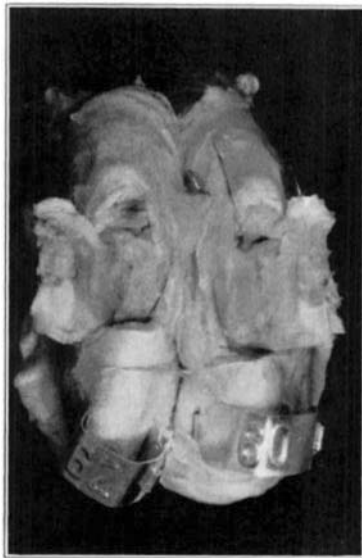

Fig. 4 Rabbit No. K. Knee Joint No. 60, after treatment with Pregl's solution appeared practically normal, while Knee Joint No. 62, which was untreated, showed considerable loss of cartilage and synovial thickening.

both joints were extremely swollen and fluctuating. Effort was made to remove the effusion by needle, but the material could not be withdrawn. Exploratory arthrotomy was performed in this instance and the thick seropurulent fluid withdrawn. Knee joint of No. 42 was treated with Pregl's solution every three to five days, while the knee joint of No. 48 was untreated. Thereafter the rabbit developed a generalized infection, and died three weeks after treatment was started. Although the cartilage of the femoral articulation of both joints was largely destroyed, there was considerable pannus thickening of the synovia about the margins of the knee joint of No. 48. The synovia of the knee joint of No. 42 was in no wise thickened, although it did give evidence of an extensive diseased process.

Rabbit No. K. had an arthrotomy of both knees with injury to the external condyle. The knees were washed with ten per cent. carbolic acid and iodine. However, the knee of extremity No. 60 was washed and filled with Pregl's solution prior to closing the wound. No. 62 was simply closed after the carbolic and iodine had been applied in the joint. Immediate treatment was started on extremity No. 60 and was continued at intervals of from three to five days for six weeks. The result was quite striking. The knee into which the Pregl's solution was injected after the injury and chemical trauma was practically normal, but the knee which was not treated showed extensive loss of cartilage.

Admittedly there are several sources of error in such experimental work. Microscopic sections have not been run

in any of these joints. Nevertheless, there seems to be something in the use of Pregl's solution that quite definitely affects the synovia, even in the presence of severe infection, to the extent that it apparently produces an inactivity or diminution of synovial secretion with an atrophy or shrinking of the synovia, very definitely inhibiting an infectious process and perhaps promoting cartilage regeneration. Of course this experimental data is in no wise conclusive, and the clinical material represents but a small group of cases; nevertheless, the similarity in results between the clinical cases and the experimental animals seems to warrant further investigation and a more general use of Pregl's solution in treating chronic effusion of arthritic and traumatized joints.

Bibliography

1. APFEL, H.: Pneumococcal Meningitis. Treated with Pregl's Solution: Recovery. Report of a Case. *Arch. Pediat.*, XLVI, 516, 1929.
2. BICK, E. M.: Surgical Pathology of Synovial Tissue. *J. Bone and Joint Surg.*, XII, 33, Jan. 1930.
3. CAJORI, F. A., CROUTER, C. Y., AND PEMBERTON, R.: The Physiology of Synovial Fluid. *Arch. Int. Med.*, XXXVII, 92, 1926.
4. COWAN, A.: Subconjunctival Injection of Pregl's Solution in Gonorrheal Ophthalmia. *Arch. Ophth.*, III, 325, 1930.
5. CRAWFORD, A. S.: Intracarotid Treatment of Meningitis and Experiments with Pregl's Iodine. *Trans. Assn. Resid. and ex-Resid. Physicians, Mayo Clinic (1929)*, X, 129, 1930.
6. The Intracarotid Treatment of Meningitis. Experiences with Pregl's Solution of Iodine: A Further Report. *J. Am. Med. Assn.*, XCVIII, 1531, 1932.
7. HEYMAN, C. H.: Synovectomy of the Knee Joint. *Surg. Gynec. Obstet.*, XLVI, 127, 1928.
8. KEY, J. A.: The Reformation of Synovial Membrane in the Knees of Rabbits after Synovectomy. *J. Bone and Joint Surg.*, VII, 793, Oct. 1925.
9. Experimental Arthritis: The Changes in Joints Produced by Creating Defects in the Articular Cartilage. *J. Bone and Joint Surg.*, XIII, 725, Oct. 1931.
10. Cytology of Synovial Fluid of Normal Joints. *Anat. Rec.*, XL, 193, 1928.
11. KOLMER, J. A.: Pneumococcus and Streptococcus Meningitis. Chemotherapy and Serum Therapy, with Especial Reference to Newer Methods. *J. Am. Med. Assn.*, XCII, 874, 1929.
12. LANGENDORF, F. J.: Die Presojod-Augensalbe in der Augenheilkunde. *Ztschr. Augenh.*, LXIX, 240, 1929.
13. MACKENZIE, A. V.: Pregl's Solution in Treatment of Organized Exudate in Tissue of the Eye. *Atlantic Med. J.*, XXX, 432, 1927.
14. STELLWAGEN, T. C., AND McCAHEY, J. F.: Gonorrheal Arthritis in Adult Male; Correlation of Clinical and Urological Findings; Treatment by Injection of Seminal Vesicles. *J. Urol.*, XVIII, 1, 1927.
15. STELLWAGEN, T. C.: Gonorrheal Arthritis; Preliminary Report of New Treatment. *J. Urol.*, XIV, 661, 1925.
16. SWETT, P. P.: The Present Status of Synovectomy. *Am. J. Surg.*, VI, 807, 1929.