

Robotically assisted radical laparoscopic prostatectomy in a patient with ectopic ureteral insertion into the prostate

Scott G. Hubosky · John W. Davis · Robert W. Given · Michael D. Fabrizio

Accepted: 28 November 2006 / Published online: 27 February 2007
© Springer London 2007

Abstract Robotically assisted laparoscopic radical prostatectomy (RaLRP) has become an alternative surgical treatment option for patients with localized prostate cancer. Rare anatomic variations result in modification of established techniques. We describe the first successful completion of RaLRP for localized prostate cancer in a patient with coexisting complete left ureteral duplication and ectopic insertion of the upper pole moiety ureter into the prostatic urethra. After standard radical prostate excision and vesicourethral anastomosis, the unique anatomy in this case required additional reconstructive maneuvers including construction of a Y-type conjoined ureteral anastomosis and ureteroneocystotomy. The procedure was safely completed without open conversion. Operative time was 420 min and EBL was 200 mL. Ureteral stents were removed in six weeks and IVP showed no evidence of obstruction. When faced with a ureteral anomaly, RaLRP can be safely completed. Robotic technology is helpful in performing additional delicate reconstructive maneuvers.

Keywords Robotic surgery · Laparoscopy · Prostatectomy · Ectopic ureter · Ureteral duplication · Ureteroneocystotomy

Introduction

Robot-assisted laparoscopic radical prostatectomy (RaLRP) combines the advantages of minimal invasive surgery and

quicker learning compared with conventional laparoscopic radical prostatectomy. As more patients seek RaLRP, more anatomic variants will be encountered by surgeons performing this procedure. Successful open radical retropubic prostatectomy has been described in patients with abnormalities of wolffian duct derivatives, including ectopic ureteral insertion into the seminal vesicle [1]. We describe successful performance of RaLRP on a patient with localized prostate cancer and complete left ureteral duplication with ectopic insertion into the prostatic urethra.

Materials and methods

A 52-year-old man presented with PSA of 5.1 ng mL⁻¹ and was found to have Gleason 3 + 3 adenocarcinoma of the prostate with clinical stage T1C. He specifically desired RaLRP after reviewing treatment options. His baseline creatinine was 0.9 mg dL⁻¹; no prior urological history or childhood illness existed. Preoperative upper tract imaging was not obtained secondary to the clinical stage.

Flexible cystoscopy was performed in the operating room immediately before RaLRP. The right ureteral orifice was in the orthotopic position and the left ureteral orifice was not initially seen. Closer inspection revealed a ureteral orifice on the left, draining into the prostatic urethra with urine effluxing from this position. A double pigtail ureteral stent was then placed with the flexible cystoscope.

To completely excise the prostate, the left ureter would require reimplantation. We proceeded with a transperitoneal approach to RaLRP using the four-armed da Vinci surgical system (Intuitive Surgical, Sunnyvale, CA, USA), with six trocars, as previously reported [2]. Before releasing the bladder from the anterior abdominal wall we elected to identify the left ureter by incising the peritoneum

S. G. Hubosky (✉) · J. W. Davis · R. W. Given · M. D. Fabrizio
Eastern Virginia Medical School,
400 W. Brambleton Ave., Suite # 100, Norfolk,
VA 23503, USA
e-mail: hubo31@aol.com

anterior to the common iliac artery. We localized the ureter with our stent seen within; an additional second ureter running parallel was appreciated, thus confirming ureteral duplication. Both ureters were traced down to the posterior detrusor using robotic instruments while leaving adequate surrounding adventitia. The ipsilateral vas deferens and medial umbilical ligament were divided.

We proceeded with radical prostatectomy, including bladder mobilization from the abdominal wall, followed by incision of endopelvic fascia and ligation of the dorsal venous complex. The anterior portion of the prostatovesicular junction was incised, exposing the urothelial surface and trigone. The previously placed stent was emanating from the ectopic insertion in the prostatic urethra (Fig. 1). Given the finding of the second ureter, we closely observed for a second left ureteral orifice and this was appreciated very close to the bladder neck within the confines of the bladder. The patient therefore had complete left ureteral duplication with ectopic insertion of one ureter within the prostatic urethra.

The posterior portion of the prostatovesicular junction was then incised. In performing this maneuver, we purposefully transected the left distal ectopic ureter as it entered the prostate. The dome of the bladder was lifted up with forceps using the fourth robotic arm. This exposed the posterior surface of the bladder. Both left ureters were traced down along the posterior detrusor muscle to maximize ureteral length. The duplicated ureters were then transected by use of the robotic curved scissors at the level of the bladder hiatus where the lower pole moiety ureter entered the bladder. This defect in the posterior bladder was closed with running 2-0 vicryl in two layers.

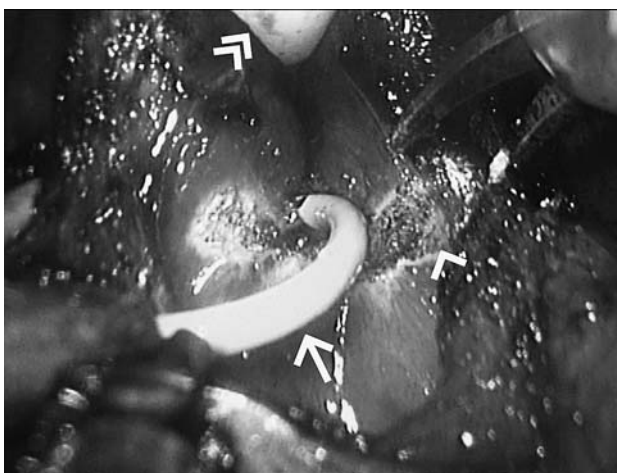


Fig. 1 Incision of posterior prostatovesicular junction (*single arrow-head*) with prostate above and bladder neck below. Note the foley catheter (*double arrow-head*) providing upward traction and the ureteral stent (*arrow*) located in the ectopic ureter inserting into the prostatic urethra

The remainder of the prostatectomy was completed including dissection of both vas deferens and seminal vesicles, incision of Denonvilliers' fascia, and control of the vascular pedicles with preservation of the bilateral neurovascular bundles. The dorsal venous complex was transected, followed by the urethra and rectourethralis muscle. The urethrovesical anastomosis was completed using our modified running suture technique, which utilizes a single Lapra-Ty to secure approximation of the posterior plate [3].

Attention was turned to the transected ureters. The ectopic ureter was previously stented and the second left ureter was cannulated with a 0.38 glidewire inserted through the assistant's 10–12 mm lateral port. This was followed by a five-french ureteral catheter, which was trimmed. A stay suture of 3-0 vicryl was placed in the lateral and medial adventitia surrounding the duplicated ureters. Next, each ureter was spatulated by incising a short segment of their adjoining walls. A Y-type conjoined ureteral anastomosis was then configured by bringing the respective posterior walls together using interrupted 5-0 pds followed by suturing the respective anterior walls together in the same fashion (Fig. 2). A double pigtail ureteral stent was exchanged for the ureteral catheter leaving two stents emanating, one from each left ureter.

The bladder was filled with saline and a cystostomy was made in the left posterior bladder. A ureteroneocystostomy was then performed using interrupted 5-0 pds. This is the Wallace anastomotic technique [4] applied to ureteroneocystostomy with duplicated ureters. The bladder was then pexed to left lateral pelvic peritoneum. A single JP drain was left in the pelvis.

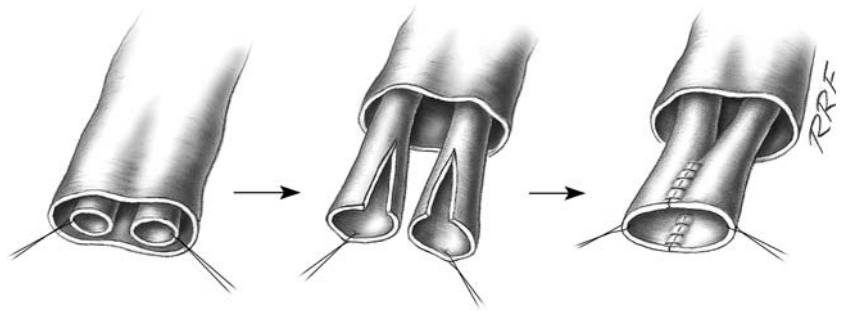
Results

This procedure was successfully completed in approximately 420 min without open conversion and the estimated blood loss was 200 mL. The patient had the pelvic drain removed on POD #3 and was discharged on POD# 4. A cystogram performed on POD #14 revealed left-sided reflux to both moieties but no extravasation. Subsequently, the foley catheter was removed. The ureteral stents were removed in 6 weeks. An intravenous pyelogram was obtained which demonstrated no obstruction. Final pathology demonstrated a 26 g gland with organ confined Gleason 3 + 3 adenocarcinoma and negative surgical margins.

Discussion

The incidence of partial and complete ureteral duplication, on the basis of autopsy studies, is 1 in 125 or 0.8% [5]. The exact incidence of ectopic ureter is unknown because many

Fig. 2 Y-type conjoined ureteral anastomosis for duplicated ureters. After spatulation, an anterior and a posterior suture line provide for a common opening for both left ureters before ureteroneocystostomy



cases manifest no symptoms. Although 80% of ectopic ureters are associated with duplication, many ectopic ureters in males are associated with a single system [6]. The most common sites of termination of ectopic ureters in males are the posterior urethra (47%) and the seminal vesicles (33%) [7].

Ideal cases for applying robotic assistance in laparoscopy involve a reconstructive component in a relatively confined working space. Robot-assisted procedures are well described in the urological literature and include radical prostatectomy [8], radical cystoprostatectomy [9, 10] dismembered pyeloplasty [11], and vaso-vasostomy [12]. A recent report of ureteral reimplantation during RaLRP has been published [13]. The authors describe incidental right distal ureteral transection at the level of the seminal vesical, which was identified intraoperatively with indigo carmine. A stent was placed, the distal ureter was spatulated, and ureteroneocystostomy was performed. Our case is similar but more complex, because of complete ureteral duplication and the elective nature of proceeding despite a potentially troublesome anatomic variant. We performed three reconstructive maneuvers during one case including vesicourethral anastomosis, a Y-type conjoined ureteral anastomosis, and ureteroneocystostomy. Although this complex procedure could have been performed with conventional laparoscopic techniques, we feel robotic assistance was extremely useful in saving time and minimizing operator fatigue.

The reconstructive technique used for this duplicated system was a Wallace anastomotic variant in which both ureters were brought together in a Y-typed conjoined anastomosis before ureteroneocystostomy. This is a known refluxing type anastomosis classically described as a ureteral-intestinal anastomotic technique used during cystectomy and creation of urinary diversion [14]. Advantages of this technique include low occurrence of stricture and the ability to keep duplicated ureters together in a common sheath to be mobilized as a unit without risk of compromising a shared blood supply. The theoretical disadvantage is that obstruction of one ureter may lend to obstruction of the other, which is in immediately close proximity. Accordingly, the Wallace technique is not recommended

during radical cystectomy when great concern for ureteral recurrence exists. Other options for reconstruction were considered, for example ureteroureterostomy with the upper pole ureter joining the lower pole ureter proximal to the bladder hiatus. This course of action would have been difficult in this case given the extreme close proximity of the lower pole ureteral orifice to the bladder neck. Consideration was also given to separately implanting each ureter into the bladder at separate locations. We felt this option was suboptimum because of theoretical concern for a shared blood supply between the duplicated ureters which if compromised could lead to stricture formation.

This case demonstrates the possible utility of preoperative flexible cystoscopy in prostatectomy patients. At our institution flexible cystoscopy is routinely performed either in the office or in the operating room immediately before prostatectomy. This is not a practice uniformly accepted by all who perform radical prostatectomy but we agree with others who advocate performing flexible cystoscopy that it provides information about bladder pathology, preexisting urethral abnormalities, and the location and status of the ureteral orifices [15]. In our teaching institution, we have also found that excision of the prostatovesicular junction is a relatively challenging step in teaching and learning this procedure and that immediate cystoscopy facilitates the learning process.

In conclusion, ureteral anomalies, although uncommonly encountered, are detectable and do not preclude safe and effective performance of RaLRP without the need for open conversion. In this case, robotic assistance enabled timely performance of three laparoscopic reconstructive maneuvers in one setting and improved surgeon ergonomics compared with conventional laparoscopic prostatectomy.

References

1. Shariat SF, Naderi AS, Miles B et al (2005) Anomalies of the wolffian duct derivatives encountered at radical prostatectomy. *Rev Urol* 7(2):75–80
2. Menon M, Tewari A, Peabody JO et al (2004) Vattikuti institute prostatectomy, a technique of robotic radical prostatectomy for

- management of localized carcinoma of the prostate: experience of over 1,100 cases. *Urol Clin North Am* 31(4):701–717
3. Ball AJ, Bordeau KP, Davis JW et al (2005) Modified running vesicourethral anastomosis after robotically assisted laparoscopic radical prostatectomy: use of solitary Lapra-Ty to secure posterior approximation. *Urology* 66:16–18
 4. Wallace DM (1970) Uretero-ileostomy. *BJU Int* 42:529–534
 5. Schlüssel RN, Retik AB (2002) Ectopic ureter, ureterocele, and other anomalies of the ureter. In: Walsh PC, Retik AB, Vaughan ED (eds) *Campbell's urology*, 8th edn. WB Saunders, Philadelphia, pp 2007–2052
 6. Ahmed S, Barker A (1992) Single-system ectopic ureters: a review of 12 cases. *J Pediatr Surg* 27:491
 7. Ellerker AG (1958) The extravescical ectopic ureter. *Br J Surg* 45:344
 8. Menon M, Tewari A, Peabody J (2003) Vattikuti institute prostatectomy: technique. The VIP team. *J Urol* 169:2289–2292
 9. Menon M, Hemal A, Tewari A et al (2003) Nerve sparing robot-assisted radical cystoprostatectomy and urinary diversion. *BJU Int* 92:232–236
 10. Beecken W, Wolfram M, Engl T (2003) Robotic-assisted laparoscopic radical cystectomy and intra-abdominal formation of an orthotopic neobladder. *Eur Urol* 44:337–339
 11. Sung G, Gill I (1999) Robotic assisted laparoscopic pyeloplasty: a pilot study. *Urology* 53:1099–1103
 12. Hemal A, Menon M (2004) Robotics in urology. *Curr Opin Urol* 14(2):89–93
 13. Dinlenc C, Gerber E, Wagner J (2004) Ureteral reimplantation during robot assisted laparoscopic radical prostatectomy. *J Urol* 172:905
 14. McDougal WS (2002) Use of intestinal segments and urinary diversion. In: Walsh PC, Retik AB, Vaughan ED (eds) *Campbell's Urology*, 8th edn. WB Saunders, Philadelphia, pp 3745–3788
 15. Kim ED, Ignatoff JM (1994) Unsuspected bladder carcinoma in patients undergoing radical prostatectomy. *J Urol* 152:397–400