



Brain-based Sex Differences in Depression: A Systematic Review of Neuroimaging Studies

Soheil Mohammadi¹ · Homa Seyedmirzaei^{1,2} · Mohammad Amin Salehi¹ · Ali Jahanshahi³ · Seyed Sina Zakavi⁴ · Fatemeh Dehghani Firouzabadi⁵ · David M. Yousem⁶

Accepted: 31 March 2023 / Published online: 14 April 2023

© The Author(s), under exclusive licence to Springer Science+Business Media, LLC, part of Springer Nature 2023

Abstract

Major depressive disorder (MDD) is a common psychiatric illness with a wide range of symptoms such as mood decline, loss of interest, and feelings of guilt and worthlessness. Women develop depression more often than men, and the diagnostic criteria for depression mainly rely on female patients' symptoms. By contrast, male depression usually manifests as anger attacks, aggression, substance use, and risk-taking behaviors. Various studies have focused on the neuroimaging findings in psychiatric disorders for a better understanding of their underlying mechanisms. With this review, we aimed to summarize the existing literature on the neuroimaging findings in depression, separated by male and female subjects. A search was conducted on PubMed and Scopus for magnetic resonance imaging (MRI), functional MRI (fMRI), and diffusion tensor imaging (DTI) studies of depression. After screening the search results, 15 MRI, 12 fMRI, and 4 DTI studies were included. Sex differences were mainly reflected in the following regions: 1) total brain, hippocampus, amygdala, habenula, anterior cingulate cortex, and corpus callosum volumes, 2) frontal and temporal gyri functions, along with functions of the caudate nucleus and prefrontal cortex, and 3) frontal fasciculi and frontal projections of corpus callosum microstructural alterations. Our review faces limitations such as small sample sizes and heterogeneity in populations and modalities. But in conclusion, it reflects the possible roles of sex-based hormonal and social factors in the depression pathophysiology.

Keywords Depression · Neuroimaging · Systematic review · Sex · Gender · MRI

Introduction

Major depressive disorder (MDD) presents with mood decline, loss of interest, irritability, and feelings of guilt and worthlessness (McCarter, 2008; Yang et al., 2022). Moreover, it is associated with decreased appetite, weight changes, and sleep disturbances (Caroleo et al., 2019). Altogether, these chronic symptoms significantly lower the quality of life and may, in the most extreme of cases, lead to suicide (Hoobehfekar et al., 2021). MDD used to rank fourth in the global burden of the diseases in 2000 (Ustün et al., 2004); however, estimates show that it will be the leading cause of disease by 2030 (Lépine & Briley, 2011). The high prevalence of depression comorbidities among people play a significant role in its pathophysiology (Gadermann et al., 2012). Notably, its presence with chronic medical diseases is associated with increased medical symptoms burden, functional impairment, medical costs, poor adherence to treatments, and elevated morbidity and mortality (Gold et al., 2020; Katon, 2011). Additionally, about 80% of people with

Soheil Mohammadi, Homa Seyedmirzaei and Mohammad Amin Salehi contributed equally to this work.

✉ David M. Yousem
dyousem1@jhu.edu

- ¹ School of Medicine, Tehran University of Medical Sciences, Tehran, Iran
- ² Interdisciplinary Neuroscience Research Program (INRP), Tehran University of Medical Sciences, Tehran, Iran
- ³ School of Medicine, Guilan University of Medical Sciences, Rasht, Iran
- ⁴ School of Medicine, Tabriz University of Medical Sciences, Tabriz, Iran
- ⁵ Department of Radiology, Boston Children's Hospital, Harvard Medical School, Boston, MA, USA
- ⁶ Russell H. Morgan Department of Radiology and Radiological Science, Johns Hopkins Medical Institution, Baltimore, MD, USA

depression have other mental illnesses, including anxiety, personality disorder, or alcohol abuse (Melartin et al., 2002).

The manifestation of depression between men and women shows dissimilarities. Women are more likely to develop depression; however, depressed men are more than three times more likely to die from depression-related suicide than women (Herreen et al., 2022). The gender gap in incidence rates starts at age 12, peaks at adolescence (Cavanagh et al., 2016, 2017; Ogrodniczuk & Oliffe, 2011; Romans et al., 2007), and remains constant afterwards (Salk et al., 2017). Moreover, the presentation of depression varies between the two sexes. Male depression usually manifests as anger attacks, aggression, substance use, and risk-taking behaviors that mainly do not fit the diagnosis criteria for depression in the first stages (Cavanagh et al., 2016). In contrast, depressed women show appetite disturbance, impaired sleep, and depressed mood at a higher frequency and intensity than men. These symptoms are included as diagnostic criteria for MDD and are in line with the fact that females are more likely to be diagnosed with depression (Cavanagh et al., 2017; Romans et al., 2007). Depressed men are more prone to escaping behaviors as well; these include over-involvement at work and high sexual activities in the forms of extramarital affairs or a series of limited sexual encounters (Ogrodniczuk & Oliffe, 2011). Meanwhile, when compared to males, depressed females show more frequent depressive episodes in their lives and report higher rates of atypical depressive symptoms (excessive fatigue, overeating, and oversleeping), anxiety, and somatization (Smith et al., 2008).

On the other hand, social factors could affect one's susceptibility to depression. For example, various studies have reported lower gender equality is significantly associated with higher rates of female depression and that populations with high gender equality experience a lower gender gap in depression (Kuehner, 2017). Other social factors, such as the lack of a partner in the household and having a small social network, can predict the onset of depression in men, and not in women, in later life (Sonnenberg et al., 2013). These factors imply that not only the biological sex but also the socially-constructed roles, behaviors, and expressions of sexes can affect depression.

The introduction of different neuroimaging tools such as magnetic resonance imaging (MRI), functional MRI (fMRI), and diffusion tensor imaging (DTI) in recent years has enabled researchers to study patterns of brain changes in various diseases (Filippi & Agosta, 2016). In healthy people, various studies have demonstrated brain-based sex differences. For example, whole-brain volumes and volumes of the amygdala and cerebellum are commonly reported to be larger in males, while exhibiting a high density of sex steroid receptors (Giedd et al., 2012). In fMRI studies, greater regional homogeneity (ReHo) in the orbitofrontal areas of females

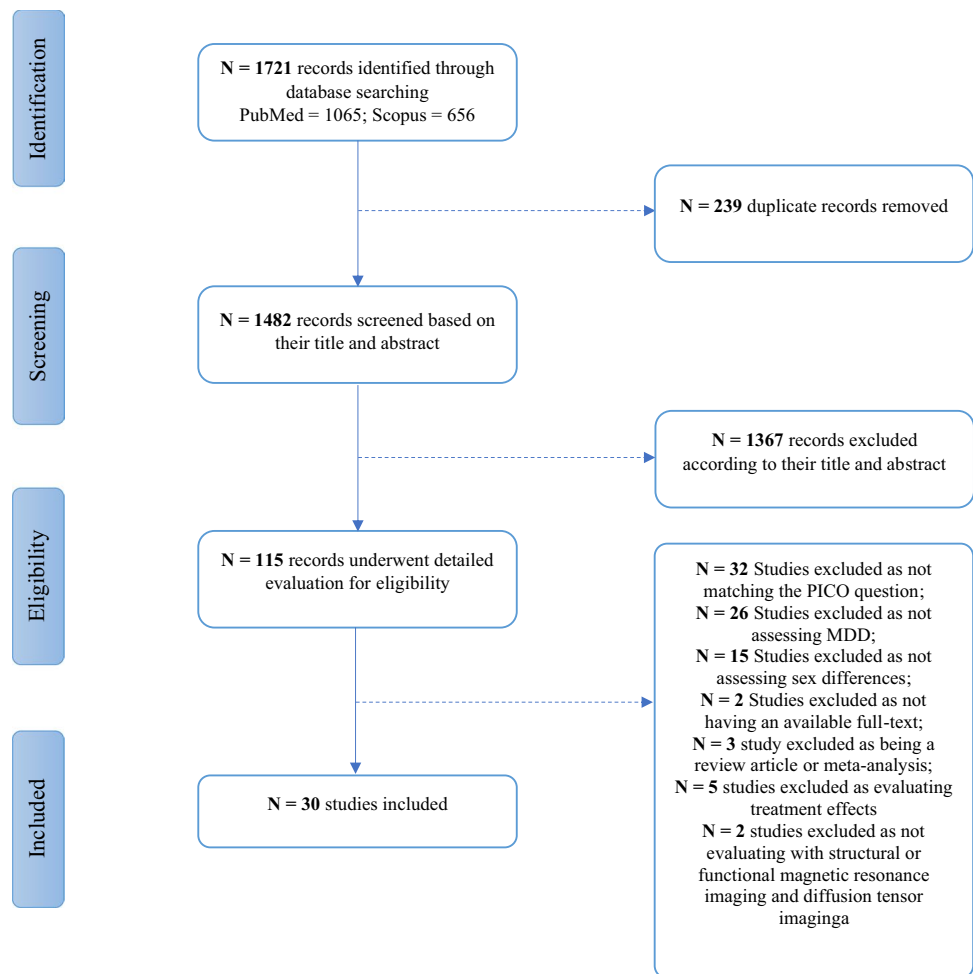
has been reported, which may be responsible for females' higher emotion perception ability (Zhang et al., 2020). Moreover, DTI findings indicate higher fractional anisotropy (FA) and radial diffusivity (RD) in healthy males' thalamus, corpus callosum (cc), and cingulum (Menzler et al., 2011). These changes in the thalamus and cingulum might be a result of sex differences in awareness, the neural processing of emotional stimuli, and interpersonal conflicts. Meanwhile, alterations of the corpus callosum might be associated with possible sex differences in hemispheric lateralization (Menzler et al., 2011).

Meanwhile, assessing depressed subjects, these imaging modalities suggest that depression affects the brain in various ways. For example, anatomical MRI studies show that the frontal lobe, parietal lobe, thalamus, caudate, pallidum, putamen, and temporal lobes of people with depression are distinct from those without it (Zhang et al., 2018). Moreover, depression is associated with lateral ventricle enlargement and larger cerebrospinal fluid (CSF) volume in people (Kempton et al., 2011). Ultra-high field (UHF, ≥ 7 T) MRI of depressed subjects has revealed smaller hippocampal in depressed people than controls and smaller subiculum in depressed individuals with multiple major depressive episodes compared to those with one episode (Cattarinussi et al., 2021).

DTI findings also reflect the microstructural changes of white matter: the FA of the corpus callosum (cc), bilateral anterior limb of the internal capsule, right inferior temporal gyrus, and right superior frontal gyrus are reduced in depression (Chen et al., 2017). The most prominent finding of functional studies is the abnormal involvement of the cortico-limbic mood-regulating circuit in depressed subjects (Wang et al., 2012). Although the literature provides data on brain changes in depression and on sex-based differences in the brain of healthy people, there is insufficient data regarding the male and female patterns of brain alterations during depression. Herein, we aim to contrast the sex differences in structural and functional changes of the brain in depression. To our knowledge, this is the first systematic review of neuroimaging studies to discuss so.

Methods and Materials

The present systematic review was prepared following the Preferred Reporting Items for Systematic Review and MetaAnalysis (PRISMA) guidelines (Swartz, 2011). Figure 1 illustrates the flow diagram of our study. Moreover, the study protocol was registered on the International Prospective Register of Systematic Reviews (PROSPERO) website (<https://www.crd.york.ac.uk/PROSPERO/>) with the code CRD42021288043.

Fig. 1 Flow chart of the study selection

Literature Search and Study Selection

Using a combination of keywords, we searched two major databases, Pubmed and Scopus, to find relevant studies on November 19, 2022. Keywords adopted for the search were: "Diffusion Tensor Imaging" or "Diffusion weighted magnetic resonance imaging" or "Diffusion Tractography" or "Diffusion weighted imaging" or "Diffusion weighted MRI" or "DTI" or "White Matter" or "Grey Matter" or "Gray Matter" or "Magnetic Resonance Imaging" or "NMR Imaging" or "tomography NMR" or "tomography MR" or "Steady State Free Precession MRI" or "MRI" or "Zeugmatography" or "Imaging Chemical Shift" or "Magnetic Resonance Image" or "Magnetization Transfer Contrast Imaging" or "MRI Scan" or "Proton Spin Tomography" or "fMRI" or "Functional MRI" or "Functional Magnetic Resonance Imaging" or "Spin Echo Imaging" or "morphometry" or "VBM" or "cortical thickness" or "cortical surface area" or "subcortical volume" and "Phenotypic Sex" or "sex phenotypic" or "Genotypic Sex" or "Sex" or "Women" or "Female" or "Men" or "Male" or "Gender" or "Sex Difference" or "Gender Difference" and "Major Depressive Disorder" or "MDD"

or "Depression" or "Depressive Symptoms" or "Depressive Symptom" or "Emotional Depression." Two reviewers independently screened articles by title and abstract to find potential relevant ones in the first step. Then, the full texts were retrieved to find eligible studies, and the discrepancies were resolved through discussion with a third reviewer. The third reviewer also monitored the whole process.

Inclusion and Exclusion Criteria

In this systematic review, we included observational case–control, cross-sectional, or cohort studies matching the PICO question that aimed to investigate the differences in neuroimaging findings of depression in both sexes. These studies could be case–control or cohort. Furthermore, we excluded the following: 1) studies that included participants suffering from other neurologic disorders 2) studies not related to major depressive disorder, 3) studies that did not assess brain neuroimaging alterations, 4) studies that did not evaluate both sexes, 5) review articles, book chapters, opinions, letters, and conference abstracts, 6) animal, in-vitro, and other nonhuman studies.

Data Items

We extracted the following data points from studies: basic study characteristics such as author name, publication date, and study design, the sample size and sex ratio, the age of participants, their medications, means of neuroimaging, and measuring tools of depression. We also mentioned if the probands were matched for variables such as sex, age, and education. Two reviewers independently extracted the aforementioned data. Discrepancies were resolved through discussion with a third reviewer.

Quality Assessment

The quality of included studies was assessed using the e Newcastle–Ottawa scale (NOS) for case–control studies (Stang, 2010). This scale evaluates the data quality in three aspects: selection, comparability, and exposure in case–control studies or cohort study outcomes. A maximum score of nine and eight stars in cohort and case–control studies can be allocated to a particular study in this assessment tool. Furthermore, the risk of publication bias was assessed for each study. We used the publication bias criteria introduced by Viswanathan et al. in a design-specific manner (Viswanathan et al., 2008).

Results

Overview

The initial search yielded 1721 results. After removing the automatic and manual duplicates, we screened the remaining 1482 studies based on titles and abstracts to find potentially eligible studies. 115 studies went through screening the full-texts, of which 85 were excluded due to following reasons: 32 studies due to not matching the PICO question of our study (Acosta et al., 1991; Cohen et al., 2013; Dean et al., 2018; Deng et al., 2018; Elbejjani et al., 2014; Frodl et al., 2002; Gorham et al., 2019; Acosta et al., 2020; Hay et al., 2020; Keller et al., 2021; Lebedeva et al., 2015; Lee et al., 2019; Li et al., 2022; MacMaster et al., 2008; Maller et al., 2007; Meruelo et al., 2021; Perlman et al., 2017; Pettemeridou et al., 2021; Pimontel et al., 2013; Saleh et al., 2012; Savitz et al., 2011; Schmaal et al., 2017a; Soe et al., 2018; Takahashi et al., 2016; Tol et al., 2010; Wang et al., 1991, 2019; Wei et al., 2021; Wen et al., 2017; Woo et al., 2009; Wu et al., 1993; Zhang et al., 1991), 26 studies due to not assessing major depression (Averill et al., 2017; Brébion et al., 2021a, 2021b; Carlson et al., 2015; Čermaková et al., 2020; Chahal et al., 2022a; Dotson et al., 2013; Elbejjani et al., 2015; Ellis et al., 2019; Frodl et al., 2010, 2017; Hayakawa et al., 2014; Kim et al., 2019; Kircanski et al., 2019;

Kirton et al., 2014; Kronmüller et al., 2008; Li et al., 2020; Liu et al., 2012; Maglanoc et al., 2020; Moulinet et al., 2021; Murray et al., 2013; Rajagopalan et al., 1994; Rakesh et al., 2021; Spalletta et al., 2014; Tozzi et al., 2020; Victor et al., 2017), 15 due to not assessing sex differences, 5 studies due to evaluating treatment effects (Domschke et al., 2008; Reinlieb et al., 2014; Vakili et al., 2000; Wei et al., 2018; Williams et al., 2021), 2 studies due to unavailable full-texts (Huang et al., 2014; Lavretsky et al., 2004), 2 studies as not assessing with MRI, fMRI, or DTI (Binesh et al., 2004; Staley et al., 2006), and 3 study due to being review articles or meta-analyses (Binnewies et al., 2022; Delvecchio et al., 2017; Peng et al., 2016).

Thirty studies were included in our systematic review: 15 MRI studies (Ancelin et al., 2019; Carceller-Sindreu et al., 2015; Cyprien et al., 2014; Furtado et al., 2008; Hastings et al., 2004; Kong et al., 2013; Kronmüller et al., 2009; Lavretsky et al., 1998; Lewine et al., 1995; MacMaster et al., 2006; Nielsen et al., 2020; Piani et al., 2021; Ritter et al., 2021; Soriano-Mas et al., 2011; Yang et al., 2017), 12 fMRI studies (De Almeida et al., 2011; Amiri et al., 2021; Briceño et al., 2015; Chuang et al., 2017; Dong et al., 2022; Geng et al., 2019; Jenkins et al., 2018; Mei et al., 2022; Piani et al., 2021; Talishinsky et al., 2022; Yao et al., 2014; Young et al., 2017), and 4 DTI ones (Ho et al., 2021; Kliamovich et al., 2021; Lyon et al., 2019; Ugwu et al., 2015) (One study had assessed both MRI and fMRI findings (Piani et al., 2021). The publication year of MRI studies varied from 1995 to 2022. However, due to their novelty, fMRI and DTI studies were all published after 2011. All studies had recruited more females than males, except three with exact equal numbers (Lavretsky et al., 1998; Mei et al., 2022; Young et al., 2017) and one with less females (Yang et al., 2017). Moreover, most studies focused only on the presence of major depressive disorder. Regarding the depression phenotype, however, some others assessed only treatment-resistant (Amiri et al., 2021; Furtado et al., 2008; Talishinsky et al., 2022), late-life (Cyprien et al., 2014), somatic/non-somatic (Geng et al., 2019), remitted (Jenkins et al., 2018), first episode/chronic/recurrent (Carceller-Sindreu et al., 2015), and early/late-onset depression (Lavretsky et al., 1998).

While Healthy probands formed the majority of controls, one study included patients with schizophrenia, schizoaffective, and bipolar disorder as controls as well (Lewine et al., 1995) and another study only compared early-onset and late-onset depression patients (Lavretsky et al., 1998). One study had also categorized both the case and control participants regarding their child adversity history (Ugwu et al., 2015). Details of medication regimens in depressed subjects were provided in 25 studies. Among these, participants of 12 studies did not take any medications (Dong et al., 2022; Hastings et al., 2004; Jenkins et al., 2018; Kliamovich et al., 2021; Kong et al., 2013; Lavretsky et al., 1998; MacMaster et al.,

2006; Mei et al., 2022; Piani et al., 2021; Ritter et al., 2021; Yang et al., 2017; Yao et al., 2014; Young et al., 2017). Eleven studies' probands administered antidepressants (De Almeida et al., 2011; Ancelin et al., 2019; Chuang et al., 2017; Cyprien et al., 2014; Furtado et al., 2008; Geng et al., 2019; Kronmüller et al., 2009; Lyon et al., 2019; Piani et al., 2021; Talishinsky et al., 2022; Ugwu et al., 2015). Of note, the probands' medications were a combination of Imipramine, selective serotonin reuptake inhibitors (SSRI), Venlafaxine, Clomipramine, and other antidepressants (Soriano-Mas et al., 2011). The characteristic data of included studies are presented in Table 1.

Quality of the Included Studies

The quality of included studies is provided in Supplementary Tables S1 and S2. Studies were assessed regarding the case selection, comparability, and exposure in case-control studies or cohort study outcomes. Moreover, as presented in Table 1, participants were matched for age in 14 studies, for sex in 14 studies, and for education in 7 studies. The publication bias risk of each included study is demonstrated in Supplementary Table S3.

Analysis of Depression

Included studies used various tools to measure depression in participants. The 17-item Hamilton Depression Rating Scale (HAM-D-17/ HDRS) (Hamilton, 1960) was the most frequently used depression assessment (De Almeida et al., 2011; Amiri et al., 2021; Briceño et al., 2015; Carceller-Sindreu et al., 2015; Dong et al., 2022; Furtado et al., 2008; Geng et al., 2019; Kong et al., 2013; Kronmüller et al., 2009; Lyon et al., 2019; Mei et al., 2022; Piani et al., 2021; Ritter et al., 2021; Soriano-Mas et al., 2011; Talishinsky et al., 2022; Ugwu et al., 2015; Yang et al., 2017; Yao et al., 2014). Some others used interviews such as the Mini-International Neuropsychiatric Interview (MINI) (Ancelin et al., 2019; Cyprien et al., 2014; Furtado et al., 2008; Geng et al., 2019; Sheehan et al., 1998) and structural clinical interview for DSM disorders (SCID) (Hastings et al., 2004; Kronmüller et al., 2009; Ritter et al., 2021; Spitzer et al., 1992; Young et al., 2017) to evaluate depression in subjects. To diagnose depression, one study (Ho et al., 2021a) also used Kiddie Schedule for Affective Disorders and Schizophrenia—Present and Lifetime (K-SADS-PL) (Kaufman et al., 1997). Another study (Kliamovich et al., 2021) employed the Semi-Structured Assessment for the Genetics of Alcoholism (SSAGA) (Brown et al., 2015). Some studies also scored the severity of depression in participants; the measurement tools included the Centre for Epidemiologic Studies-Depression Scale (CDS-D) (Cyprien et al., 2014; Radloff, 1977), Children's Depression Inventory (CDI) (Kovacs n.d.; Nielsen

et al., 2020), Beck's Depression Inventory (BDI) (Beck et al., 1961; Ritter et al., 2021; Ugwu et al., 2015), Reynolds Adolescent Depression Scale (RADS-2) (Ho et al., 2021a; Reynolds, 2004), Depression Anxiety and Stress Scales-21 (DASS-21) (Osman et al., 2012; Piani et al., 2021), Childhood Depression Rating Scale-Revised (MacMaster et al., 2006; Poznanski et al., 1985), and Montgomery-Asberg Depression Rating Scale (MADRS) (Montgomery & Asberg, 1979; Ritter et al., 2021; Ugwu et al., 2015). The details of all measurement tools are provided in Table 1.

MRI Studies

A total of 15 studies were selected. As presented in Table 2, most studies explored merely the volume of brain regions. Among these, three studies reported changes in the amygdala. Assessing people with a lifetime history of depression and people with current MDD, the first one revealed that there was an association between depression history and lower gray matter (GM) volumes in men's amygdala, in contrast to women (Ancelin et al., 2019). The other reported that females with MDD tend to have a smaller amygdala than healthy females (Hastings et al., 2004). Other findings of these studies included a larger rostral anterior cingulate cortex in women with a lifetime MDD than their male counterparts (Ancelin et al., 2019) and a smaller inferior anterior cingulate normalized volume in MDD males than their healthy counterparts (Hastings et al., 2004). Their exploration of the orbitofrontal cortex, total cerebral volume, and hippocampus did not show any sex differences.

Another MRI study assessed both GM density and volume of the amygdala in depressed people and healthy controls (Kong et al., 2013). They reported reduced GM density in the bilateral amygdala of MDD females compared to HC females and reduced GM density and volume in the bilateral caudate of MDD males compared to their healthy counterparts. Regarding the hippocampus, in contrast to previous studies, sex differences were reflected in its lower GM density in MDD females than in HC females, which was not seen in males (Kong et al., 2013).

Similar to the latter study, the hippocampus reflected sex differences in another study. Males with the first episode of MDD exhibited a left-right asymmetry in hippocampal volume with smaller left hippocampal volume compared to healthy controls based on their findings (Kronmüller et al., 2009). The researchers also tested if total brain volume differed in people with MDD and healthy controls, which was disproven (Kronmüller et al., 2009). However, an association between smaller size of total brain volumes and depressive symptoms in women with treatment-resistant depression was observed (Furtado et al., 2008). Other results were as follows: 1) lower intracranial volume and total brain volume to intracranial volume ratios in male patients than in male

Table 1 Characteristics of included studies

Study	Study design	Study groups	Sample size (F/M)	Age (years) (mean± SD)	MRI/DTI/fMRI	Measure of depression	Medication	Matched for
Amiri et al., 2021	Case-control	TRD HC	21/10 18/11	35.7±9.1 31.7±6.1	fMRI	HAMD-17	NR	-
Ancelin et al., 2019	Case-control	Lifetime MDD No lifetime MDD	320/290 (total)	70.7 (median)	MRI	DSM-IV MINI	Antidepressants	-
Briceño et al., 2015	Case-control	MDD HC	27/26 31/26	46.1 (mean) 44.1 (mean)	fMRI	DSM-IV HDRS	NR	Age, sex
Carceller-Sindreu et al., 2015	Case-control	First-episode MDD Remitted-recurrent MDD Chronic MDD HC	14/7 18/2 16/4 24/10	44.4±6.7 47.1±8.2 48.6±8.0 47.9±8.1	MRI	DSM-IV-TR HDRS	Psychotropic medication	Age, gender distribution, educational level
Chuang et al., 2017	Case-control	MDD HC	82/24 24/10	15.72±1.10 (F) 15.25±1.52 (M) 15.89±1.42 (F) 15.26±1.22 (M)	fMRI	DSM-IV	Antidepressants	Age, sex, handedness
Cyprien et al., 2014	Cohort	LLD Non-LLD	75/45 137/210	70.8±4.0 71.1±4.0	MRI	MINI CES-D Antidepressant intake	Antidepressants, Antihypertensives	-
De Almeida et al., 2011	Case-control	MDD HC	12/7 12/7	30.3±7 31.8±6.8	fMRI	HDRS	Antidepressant, mood stabilizer, antipsychotic, and anxiolytics	Age, sex
Dong et al., 2022	Case-control	MDD HC	76/48 137/106	25.68±7.90 (F) 24.75±5.16 (M) 21.33±4.28 (F) 20.54±2.13 (M)	fMRI	DSM-IV-TR HAM-D-17	No	Sex
Furtado et al., 2008	Case-control	TRD HC	23/22 17/13	37.53±11.3 36.6±11.09	MRI	DSM-IV MINI HDRS	Antidepressants (TCA, NaSSA, NRI, RIMA, SNRI)	Age, sex
Geng et al., 2019	Case-control	SD NSD HC	15/13 16/14 13/17	37.21±7.16 34.10±9.91 35.83±8.15	fMRI	DSM-IV MINI HAM-D-17	Antidepressants (SSRI, SNRI, NaSSA, Benzodiazepines)	Age, education, gender
Hastings et al., 2004	Case-control	MDD HC	10/8 10/8	38.9±11.4 34.8±13.6	MRI	DSM-III-R SCID-P SCID-NP	No	Sex
Ho et al., 2021	Case-control	MDD HC	34/14 19/16	16.32±1.19 15.75±1.22	DTI	DSM-IV K-SADS-PL RADS-2	Psychotropic medication	-
Jenkins et al., 2018	Case-control	rMDD HC	32/16 25/15	21.72±1.28 (F) 20.69±1.62 (M) 21.00±1.63 (F) 20.67±1.76 (M)	fMRI	DSM-IV-TR	No	Sex
Kliamovich et al., 2021	Cohort	MDD HC	39/24 184/215	14.88±1.44 14.87±1.78	DTI	DSM-IV SSAGA	No	-
Kong et al., 2013	Case-control	MDD HC	16/13 17/16	28.88±9.71 (F) 31.23±8.39 (M) 28.00±9.09 (F) 31.81±7.05 (M)	MRI	DSM-IV HAMD	No	Age, education
Kronmuller et al., 2009	Case-control	FEMD RMD HC	13/13 20/11 19/11	41.46±16.64 (F) 38.08±11.88 (M) 45.85±11.78 (F) 48.27±8.73 (M) 42.68±13.98 (F) 42.00±11.28 (M)	MRI	DSM-IV SCID HDRS	Antidepressants (TCA, SSRI, Other new antidepressants)	-
Lavretsky et al., 1998	Case-control	EOD LOD	21/12 27/36	57.0±5.9 63.9±8.0	MRI	DSM-III-R HAM-D	No	-
Lewine et al., 1995	Case-control	Schizophrenia Schizoaffective Major depression Bipolar HC	26/82 13/7 20/7 15/5 91/59	33.9±7.3 (F) 32.4±8.1 (M) 39.6±10.1 (F) 39.4±9.0 (M) 41.4±10.4 (F) 39.3±11.9 (M) 39.7±6.9 (F) 32.6±6.3 (M) 35.2±9.9 (F) 31.5±8.2 (M)	MRI	DSM-III-R	NR	-
Lyon et al., 2019	Cohort	MDD HC	115/106 34/33	33.6±11.7 30.3±12.8	DTI	DSM-IV HAMD	Escitalopram, sertraline, or venlafaxine-extended release	Sex, education

Table 1 (continued)

Study	Study design	Study groups	Sample size (F/M)	Age (years) (mean±SD)	MRI/DTI/fMRI	Measure of depression	Medication	Matched for
MacMaster et al., 2006	Case-control	MDD HC	20/15 20/15	14.72±2.16 (F) 13.82±2.81 (M) 14.72±2.33 (F) 14.19±2.83 (M)	MRI	DSM-IV CDRS-R	No	Age, sex
Mei et al., 2022	Case-control	MDD HC	36/25 36/25	36.1±10.7 (F) 36.4±12.8 (M) 36.6±11.8 (F) 34.9±11.9 (M)	fMRI	DSM-IV HAM-D	No	Age, sex, education
Nielsen et al., 2020	Cohort	MDD High-risk Low-risk	30/22 (total)	17.34±0.98 (total)	MRI	CDI	NR	-
Piani et al., 2021	Case-control	MDD HC	7/5 5/7	66.5±9.1 68.7±12.3	MRI fMRI	DSM-V HDRS DASS-21	Antidepressants, anticonvulsants, mood stabilizer, antipsychotics, and NSAIDs	Age
Ritter et al., 2021	Case-control	Current MDD Past MDD Healthy	20/12 41/9 128/71	24.9±6.23 (F) 27.8±3.93 (M) 23.9±4.34 (F) 23.4±2.88 (M) 24.9±4.48 (F) 24.8±1.53 (M)	MRI (PWI)	DSM-IV SCID-IV HAM-D MADRS BDI	No	-
Soriano-Mas et al., 2011	Cohort	MDD HC	41/29 23/17	61.56±9.68 59.23±7.09	MRI	DSM-IV HAM-D	Imipramine SSRI Venlafaxine Clomipramine Other antidepressants	-
Talishinsky et al., 2022	Cohort	TRD HC	223/148 103/79	41.9±11.4 35.1±13.0	fMRI	DSM-V HDRS	Antidepressants, Psychotropic medication	-
Ugwu et al., 2015	Case-control	MDD with CA MDD without CA HC with CA HC without CA	11/13 17/5 9/8 18/11	40±9.1 41±11.2 36±13.5 36±12.0	DTI	DSM-IV-TR HDRS BDI-II MADRS	Antidepressants	Age, gender
Yang et al., 2017	Case-control	MDD HC	53/29 53/29	30.21±10.79 (F) 27.48±7.55 (M) 29.06±9.10 (F) 26.38±6.91 (M)	MRI	DSM-IV-TR HAM-D	No	Age, education, intelligence quotient
Yao et al., 2014	Case-control	MDD HC	13/14 15/15	35.3±7.3 (F) 31.1±9.6 (M) 31.3±7.8 (F) 30.9±6.6 (M)	fMRI	DSM-IV-TR HDRS	NR	Age, education
Young et al., 2017	Case-control	MDD HC	20/20 20/20	35.5±8.13 (F) 36.1±10.2 (M) (HC NR)	fMRI	SCID HDRS	No	Age, sex

Abbreviations: MRI: Magnetic resonance imaging, DTI: Diffusion tensor imaging, fMRI: Functional magnetic resonance imaging, DSM (-TR): Diagnostic and Statistical Manual of Mental Disorders (-Text revision), HAM-D or HDRS: Hamilton Depression Rating Scale, MINI: Mini-International Neuropsychiatric Interview, CES-D: Centre for Epidemiologic Studies-Depression Scale, SCID: Structured Clinical Interview DSM-III-R, K-SADS-PL: Kiddie Schedule for Affective Disorders and Schizophrenia - Present and Lifetime, RADS: Reynolds Adolescent Depression Scale, SSAGA: Semi-Structured Assessment for the Genetics of Alcoholism, CDRS-R: Childhood Depression Rating Scale-Revised, CDI: Children's Depression Inventory, DASS-21: Depression Anxiety and Stress Scales-21, NSAID: nonsteroidal anti-inflammatory drugs, MADRS: Montgomery-Asberg Depression Rating Scale, BDI: Beck's Depression Inventory, MDD: Major depressive disorder, rMDD: Remitted major depressive disorder, TRD: Treatment-resistant depression, LLD: Late-life depression, SD: Somatic depression, NSD: Non-somatic depression, FEMD: First episode major depression, RMD: Recurrent major depression, EOD: Early-onset depression, LOD: Late-onset depression, CA: Childhood adversity, HC: Healthy control, TCA: Tricyclic antidepressant, SSRI: Selective serotonin reuptake inhibitor, NaSSA: Noradrenergic and specific serotonergic antidepressant, NRI: Norepinephrine reuptake inhibitor, SNRI: Serotonin-norepinephrine reuptake inhibitor antidepressant, RIMA: Reversible inhibitor of monoamine oxidase A antidepressant, NR: Not reported, F: Female, M: Male, SD: Standard deviation, PWI: Perfusion-weighted imaging.

-. Data not reported.

controls and 2) greater entorhinal cortex volume in male patients than in female patients (Furtado et al., 2008).

In another study assessing late-onset depression (onset after 50), authors investigated whole-brain GM volume of probands. They realized that normalized GM volumes of

calcarine, olfactory, and orbitofrontal regions are increased in healthy females than in healthy males but decreased in MDD females compared to MDD males (Piani et al., 2021). Another study by Yang et al. focused on various gyri alterations in MDD (Yang et al., 2017). What they reported was that the GM volume of the middle/superior temporal gyrus and ventromedial prefrontal gyrus were decreased in MDD males compared to HC males. Meanwhile, in females, the dorsomedial prefrontal gyrus (extending to the supplementary motor area) and lingual (extending to the parahippocampal gyrus) were smaller in the patients (Yang et al., 2017). The pituitary gland volume was explored in only one study, suggesting larger volumes in pediatric MDD males compared to HC males, while there were no significant diagnostic group differences in pediatric females (MacMaster et al., 2006). The authors also reported that non-familial (without a family history of mood disorder) males with MDD had significantly larger pituitary glands than familial patients and healthy controls (MacMaster et al., 2006).

More other studies employed structural MRI tools to assess sex or gender disparities in depression. One aimed to measure the habenula changes during the depression and found out females with a first-episode depression had larger habenula white matter (WM) volumes than both healthy probands and people with treatment-resistant/chronic depression (Carceller-Sindreu et al., 2015). On the other hand, another study performed a volumetric MRI study on people with only late-life depression, meaning that they developed depression at age 65 and over (Cyprien et al., 2014). In that study, there was a positive association between late-life depressive symptoms and smaller anterior, mid, posterior, and total corpus callosum regions in women, as opposed to men. Nevertheless, there was no correlation between the total brain volume and depression in the two sexes (Cyprien et al., 2014).

White-matter hyperintensities were also studied in two relatively old studies in the field of depression (Lavretsky et al., 1998; Lewine et al., 1995). One of them employed MRI to find qualitative brain morphologic anomalies in MDD, schizophrenic, schizoaffective, and bipolar disorder patients along with healthy volunteers. They reported that men with either schizophrenia or major depression had more frequently reported abnormal scans than women in either group, predominantly showing deep white matter hyperintensity signals, volume loss, enlargement or asymmetry of ventricles, and other incidental findings (Lewine et al., 1995). Meanwhile, the other study focused on people with early and late-onset depression. In their research, both early-onset (meaning having the first episode before 50) and late-onset males had larger amounts of white matter intensities (Lavretsky et al., 1998).

Assessing the cortical thickness, different matter volumes, and perfusion measures, further studies have reported the sex differences in depression neuroimaging findings. For example, a study examined the thickness of the orbitofrontal cortex (OFC) in adolescents with depression (Nielsen et al., 2020). What they observed was an inverse correlation between depressive symptoms and the left lateral OFC in males and a positive one between depressive symptoms and left medial OFC in females. However, the right hemisphere did not reflect any sex differences (Nielsen et al., 2020). On the other hand, a structural whole-brain study tested white and gray matter disparities between the two sexes. They recruited people with melancholic depression alongside healthy controls; the results indicated a significant reduction in the gray matter volume of the right thalamus in MDD males, which was not seen in their female counterparts (Soriano-Mas et al., 2011). Finally, a recent study conducted perfusion tests in people with depression and reported cerebral perfusion alterations that varied with Hamilton Depression Scale (HAM-D)(Hamilton, 1960), Beck's Depression Inventory (BDI)(Beck et al., 1961), and Montgomery-Asberg Depression Rating Scale (MADRS) (Montgomery and Asberg, 1979) scores. Sexual dimorphism appeared as a positive association between whole-brain perfusion and female depressive symptoms in the HAM-D, BDI, and MADRS scores. In contrast, male patients' cerebral perfusion exhibited a positive association for the MADRS score (Ritter et al., 2021).

DTI Studies

As previously explained, only four studies assessed sex differences in DTI findings in depression. The detailed data of these are presented in Table 3. One study focused on WM pathways involved in emotional regulation in subjects with and without MDD. Their results showed that males with MDD had lower FA in the parahippocampal cingulum and higher longitudinal diffusivity (LD) in fronto-occipital fasciculus than healthy males. Also, MDD males showed greater LD in superior longitudinal fasciculus compared with MDD females (Ugwu et al., 2015). Another study examined the whole brain changes in adolescent-onset depression. They reported that mean diffusion indices of a cluster of precentral gyrus white matter bordering on the superior corona radiata differ in males and females; MDD females showed lower FA and higher radial diffusivity (RD) in this area compared to healthy probands. By contrast, males with MDD had higher FA, higher axial diffusivity (AD), and lower RD in the same region (Kliamovich et al., 2021).

Another recent study similarly focused on adolescents with depression. Women with MDD had a significantly

Table 2 Overview of MRI studies on sex differences in depression

Study	Tesla sequence	Measures	Brain areas	Methods for Sex Differences Analyses		Covariates	Results
				Sex by Diagnosis Effects			
				Model	Tested? Findings		
Ancelin et al., 2019	1.5 T T1	Volume	Hippocampus Amygdala Orbitofrontal cortex ACC	GLM	Yes	Yes	A positive association between lifetime MDD and smaller GM volumes in men's amygdala and caudate nucleus. No such association in women. Women exhibited larger rostral ACC volumes than men.
Carceller-Sindreu, 2015	3 T T1	Volume	Habenular nuclei TIV	GLM	Yes	Yes	Increased Hb-WM volume in women with a first-episode MDD.
Cyprien et al., 2014	1.5 T T1	Volume	Corpus callosum TBV	GLM	Yes	Yes	A positive association in women between the incidence of LLD and smaller anterior, mid, posterior, and total CC areas.
Furtado et al., 2008	1.5 T T1	Volume	ERC ICV TBV	GLM	Yes	Yes	No associations in men. Lower ICV and TBV/ICV in male patients than male controls. No such association in females. Lower TBV in female patients than female controls.
Hastings et al., 2004	1.5 T T1	Volume	Amygdala Hippocampus IAC OPFC TCV	GLM	Yes	Yes	Larger L and R ERC in male patients than female patients. Depressed females had a 23% smaller R amygdala and a 15% smaller L amygdala than healthy females. Depressed males had a 22% smaller IAC normalized volume than healthy males.

Table 2 (continued)

Study	Tesla sequence	Measures	Brain areas	Methods for Sex Differences Analyses		Covariates	Results
				Sex by Diagnosis Effects			
				Model	Tested? Findings		
Kong et al., 2013	3 T	GM volume GM density	Bilateral amygdala, hippocampus, striatum, and PFC	ANOVA	Yes Yes	N/A	Reduced GM density in the bilateral amygdala and hippocampus of MDD females compared to HC females Reduced GM density in the bilateral caudate extending to the left ventral striatum of MDD males compared to the HC males Reduced GM volume in bilateral caudate of MDD males compared to HC males
Kronmuller et al., 2009	1.5 T T1	Volume	Hippocampus TBV	GLM	Yes Yes	Age, diagnostic group, TCV	A L-R asymmetry in hippocampal volume with smaller L hippocampal volume in FEMD males than Healthy males. No difference in TBV. More males had large WMH than females. No significant difference in VBR.
Lavretsky et al., 1998	1.5 T T1, T2	WMH, VBR	Whole brain	GLM	Yes No	Age, age at onset	Less normal scans in schizophrenic and MDD men than women in either group.
Lewine et al., 1995	1.5 T T2	Volume WMH Ventricular anomaly	Whole brain	NR	Yes Yes	History of substance abuse or physical trauma	Larger pituitary gland volumes in MDD males compared to HC males, while there were no significant diagnostic group differences in the pituitary volume of females.
MacMaster et al., 2006	1.5 T	Volume	Pituitary gland	ANCOVA	Yes Yes	Age, intracranial volume	

Table 2 (continued)

Study	Tesla sequence	Measures	Brain areas	Methods for Sex Differences Analyses		Covariates	Results	
				Sex by Diagnosis Effects				
				Model	Tested? Findings			
Nielsen et al., 2020	NR	CT	OFC	MLM	Yes	Yes	Age at the time of scan, maternal depression history	Inverse association between depressive symptoms and CT of the L lateral OFC in males. Positive association in the L medial OFC in females between CT and depressive symptoms. Comparable regional GM volumes between MDD and HC groups across diagnosis by sex subsets. Larger normalized GM volumes of calcarine, olfactory, and orbitofrontal regions in healthy females than in healthy males, but lower in MDD females compared to MDD males.
Piani et al., 2021	3 T	GM volume	Whole brain	GLM	Yes	Yes	None (univariate)	Comparable regional GM volumes between MDD and HC groups across diagnosis by sex subsets. Larger normalized GM volumes of calcarine, olfactory, and orbitofrontal regions in healthy females than in healthy males, but lower in MDD females compared to MDD males.
Ritter et al., 2021 (PWI)	3 T	Perfusion	Whole brain	GLM	Yes	Yes	Whole-brain perfusion	Negative association between perfusion and depressive symptoms in females for the HAM-D, BDI, and MADRS. Positive association in males for the MADRS.
Soriano-Mas et al., 2011	1.5 T	Gray and white matter volume	Whole brain	GLM	Yes	Yes	Age, time between scans, global tissue volume	A significant GM volume reduction in the R thalamus in male MDD patients.

Table 2 (continued)

Study	Tesla sequence	Measures	Brain areas	Methods for Sex Differences Analyses		Covariates	Results
				Sex by Diagnosis Effects			
				Model	Tested? Findings		
Yang et al., 2017	3 T	GM volume	Whole brain	ANCOVA	Yes	Age, GM volume, whole brain volume	Decreased GM volume of middle/superior temporal gyrus and ventromedial prefrontal gyrus in MDD males compared to HC males Increased GM volume of cerebellum in MDD males compared to HC males Decreased GM volume of dorsomedial prefrontal gyrus extending to SMA and lingual extending to parahippocampal gyrus in MDD females compared to HC females

Abbreviations: MRI: Magnetic resonance imaging, ACC: Anterior cingulate cortex, TBV: Total brain volume, ICV: Intracranial volume, TCV: Total cerebral volume, ERC: Entorhinal cortex, IAC: Inferior anterior cingulate, OPFC: Orbital prefrontal cortex, OFC: Orbitofrontal cortex, MDD: Major depressive disorder, GM: Gray matter, WM: White matter, WML: White matter lesions, Hb: Habenula, CC: Corpus callosum, LLD: Late-life depression, PFC: prefrontal cortex, FEMD: First episode major depression, MADRS: Montgomery-Asberg Depression Rating Scale, BDI: Beck's Depression Inventory, HAM-D: Hamilton Depression Rating Scale, WMH: White-matter hyperintensities, VBR: Ventricle-to-brain ratio, CT: Cortical thickness, PWI: Perfusion-weighted imaging, GLM: General linear model, ANCOVA: Analysis of covariance, MLM: Multilevel modeling, SMA: supplementary motor area, T: Tesla, L: Left, R: Right, NR: Not reported, N/A: Not applicable.

higher R1 of left uncinate fasciculus (UF) and corpus callosum genu than healthy women. Furthermore, severe depressive symptoms in females correlated with greater R1 in the left uncinate fasciculus (Ho et al., 2021a). These regions were also assessed in another DTI study. In this study, Lyon et al. observed elevated FA in the genu of the corpus callosum, bilateral cerebral peduncle, and left UF in HC females compared to MDD females and higher AD in the left frontal projection of the corpus callosum in HC females compared to those with MDD (Lyon et al., 2019). Moreover, in their longitudinal assessment of 8-week treatment with escitalopram, sertraline, or venlafaxine-extended release, they assessed if DTI metrics' alterations vary by sex. However, no significant difference was observed in the two sexes regarding the remission vs. non-remission status (Lyon et al., 2019).

fMRI Studies

As provided in Table 4, 12 studies explored sex differences in functional brain alterations during MDD. Two studies focused on the resting-state functional connectivity (rs-FC) of the treatment-resistant depression (TRD) probands and healthy controls. The first one reported that, compared to TRD males, TRD females had higher degree values of functional connectivity in various regions: subcallosal cingulate gyrus, ventral caudate, nucleus accumbens, inferior thalamic peduncle, and left lateral habenula (Amiri et al., 2021). The second study similarly explored the sex differences in rs-FA of TRDs (Talishinsky et al., 2022). Their large cohort study, which comprised 371 TRD patients and 182 HCs, revealed elevated connectivity in subgenual and posterior cingulate areas and decreased connectivity in the anterior insula, temporal pole, and lateral prefrontal cortex in male patients compared to HC males. No significant difference was seen in females (Talishinsky et al., 2022).

Literature provided more evidence of sex differences in resting-state fMRI findings by measuring the amplitude of low-frequency fluctuation (ALFF). For example, a study demonstrated decreased ALFF in the bilateral caudate nucleus and posterior cingulate gyrus of MDD males compared to MDD females and HC females (Mei et al., 2022). Plus, ALFF in the bilateral caudate nucleus and posterior cingulate gyrus of MDD females was increased when compared to HC males. Disease duration was also positively correlated with the ALFF of the right caudate nucleus in MDD females (Mei et al., 2022). The other study mainly focused on the gyri of the probands (Yao et al., 2014). In their study, male MDD patients had significant differences when compared to the patients of the opposite sex. These differences included higher ALFF values in the left postcentral gyrus and right superior temporal gyrus and lower ALFF values in

the left superior temporal pole, left superior temporal gyrus, and left superior frontal gyrus (Yao et al., 2014).

Various studies also measured fMRI metrics' changes in response to different facial expressions. For instance, to examine the prefrontal cortical–amygdala neural circuitry, a study made the participants complete an emotional dynamic face-processing task (De Almeida et al., 2011). They suggested that in response to happy faces, MDD females show abnormal inverse left ventromedial prefrontal cortex (vmPFC)–amygdala connectivity, left subgenual anterior cingulate cortex (sgACC)–amygdala connectivity, and reduced positive left vmPFC–sgACC compared to healthy females. In response to fearful faces, affected females also had abnormally increased positive left sgACC–amygdala connectivity in this comparison. Regarding males, however, there was not any significant result (De Almeida et al., 2011). Another study also administered facial emotion perception (happy, sad, angry, and fearful) to assess the fMRI metrics' alterations in MDD (Briceño et al., 2015). However, among fronto-limbic regions, there were no regions significant for an MDD status by gender interaction (Briceño et al., 2015). The last study, which assessed resistant MDD patients had different results. Their whole-brain study revealed the effects of depression on facial emotion processing. Compared to their male counterparts, resistant MDD females presented greater activities in the right thalamic cluster and right superior frontal gyrus cluster for neutral and sad contrasts, respectively. In contrast, there were associations between male resistant depression and activities of the left middle temporal gyrus and bilateral midbrain for the sad face contrast (Jenkins et al., 2018).

Interestingly, two studies explored sex differences in depression by using the Go/No-Go paradigm, a well-established tool to measure sustained attention (Piani et al., 2021). The first study showed negative responses during the go/no-go condition in the right parahippocampus of MDD females compared to MDD males and in that of HC males than HC females (Piani et al., 2021). The second study similarly assessed MDD and HC participants of two sexes. Results suggested more activation of the supramarginal gyrus and posterior cingulate cortex in healthy males than healthy females and in MDD females than in MDD males (Chuang et al., 2017). Both studies showed that the diagnosis of depression reverses the fMRI findings.

Two studies implemented different approaches to find the sex differences of MDD. One explored brain activation during the recall of autobiographical memories (Young et al., 2017). Their results of positive memories assessment were as follows: higher activity in the right dorsomedial prefrontal cortex (dmPFC) of MDD males and lower activity in the right caudate of MDD females compared to all other groups. Moreover, they showed that during a negative memory recall, activity in the posterior cingulate cortex (PCC)

Table 3 Overview of DTI studies on sex differences in depression

Study	Tesla sequence	Measures	Brain areas	Methods for Sex Differences Analyses		Covariates	Results	
				Sex by Diagnosis Effects				
				Model	Tested? Findings			
Ho et al., 2021	3T T1	RI, FA, MD, AD, RD	Corpus callosum genu and splenium, cingulum cingulate, uncinate fasciculus	GLM	Yes	Yes	Study group, psychotropic medication status, Tanner stage, age of initial depression onset, duration of current episode, age of menarche	Increased RI in the L uncinate fasciculus and corpus callosum genu in MDD females compared to healthy females. Association between higher RI in the L uncinate fasciculus and severe depressive symptoms in females. No gender-specific association in FA.
Kliamovich et al., 2021	3T	FA, MD, AD, RD	Whole brain	GLM	Yes	Yes	Age, groups, GAD, OCD, baseline depression symptoms	Lower FA and higher RD in MDD females, higher FA and AD and lower RD in MDD males in a cluster of precentral gyrus WM bordering on the superior corona radiata.
Lyon et al., 2019	3T	FA, AD, ADC, RD	Whole brain	GLM	Yes	Yes	Age	Elevated FA in genu of cc, bilateral cerebral peduncle, and left UF in HC females compared to MDD females
Ugwu et al., 2015	3T	FA, LD, RD	RC, DC, PC, UF, Crus of the fornix, SLF, Inferior FOF	GLM	Yes	Yes	Age	Elevated AD in left frontal projection of the cc in HC females compared to MDD females
								Lower FA in PC and higher LD in FOF in MDD males than male controls. Greater LD in SLF in MDD males than females

Abbreviations: DTI: Diffusion tensor imaging, FA: Fractional anisotropy, MD: Mean diffusivity, AD: Axial diffusivity, RD: Radial diffusivity, LD: Longitudinal diffusivity, ADC: Apparent diffusion coefficient, cc: corpus callosum, RC/DC/PC: Rostral/Dorsal/Parahippocampal Cingulum, UF: Uncinate fasciculus, SLF: Superior longitudinal fasciculus, FOF: Fronto-occipital fasciculus, GAD: General anxiety disorder, OCD: Obsessive-Compulsive disorder, MDD: Major depressive disorder, WM: White matter, GLM: General linear model, T: Tesla, L: Left.

and insula of HC females increases when compared to both male groups, and the precuneus of HC males becomes less active than all other groups (Young et al., 2017). The other study made participants undergo the Montreal imaging stress task, in which acute psychosocial stressor (time limit to do arithmetic questions) affected the patients and their subsequent fMRI results (Dong et al., 2022). In the study, there was less deactivation in the amygdala, hippocampus, and nucleus accumbens of the female MDD group compared to healthy females. This difference was not seen in males (Dong et al., 2022).

Finally, the last study explored fMRI alterations in people with somatic and non-somatic depression. Based on their reports, depressed participants develop elevated regional homogeneity (ReHo) in the left inferior triangular frontal gyrus (Geng et al., 2019). This measure evaluates functional similarity of a given voxel with its nearest neighbors (Liu et al., 2008). In their study, in contrast to men, women with somatic depression had increased ReHo in the right superior temporal gyrus and decreased ReHo in the right middle frontal gyrus compared to their non-somatic counterparts (Geng et al., 2019).

Discussion

This systematic review summarizes the current literature on sex differences in abnormal neuroimaging findings among depression patients. As the results explained, most conventional MRI studies reflected the sex effect on temporal lobe components in depression; the hippocampus and amygdala, along with total brain volume and orbitofrontal regions, differed between the two sexes. However, the specific changes were heterogeneous. Also, connections of the limbic pathways showed disparities in males and females with MDD; these included habenula, anterior cingulate cortex, and corpus callosum. Meanwhile, DTI findings were mainly associated with frontal connections like uncinate fasciculus, superior longitudinal fasciculus, and fronto-occipital fasciculus, and even frontal projections of the cc. Other microstructural alterations in the white matter involved cingulum, thalamic radiations, and corpus callosum. Moreover, regarding fMRI, functions of various frontal and temporal gyri, along with caudate nucleus and prefrontal cortex, were different between the two sexes. Similar to DTI findings, the cingulum-related regions, especially posterior cingulate cortex, showed disparities as well.

Being a part of the limbic system, the hippocampus has long been implicated in emotional memory recalling and regulation (Zhu et al., 2019). Regarding depression, a systematic review and meta-analysis of late-life depression reported hippocampal size reduction as the most consistent evidence (Geerlings & Gerritsen, 2017). Healthy males and

females tend to have similar sizes of the hippocampus (Eijk et al., 2020; Perlaki et al., 2014), but sex might affect the volumetric hippocampal changes in depression. The proof of higher binding potential in healthy females compared with healthy males in positron emission tomography (PET) receptor-binding studies of the serotonin receptor also supports this effect (Parsey et al., 2002). Another component of the limbic system, the amygdala, manages the fear response and processing of facial emotional expressions (Burke et al., 2011). Reports show that lower amygdala volumes are associated with a longer disease duration (Zavorotnyy et al., 2018) and predict anxiety symptoms (Hu et al., 2020). The fact that depressed women experience higher symptom severity and higher lifetime anxiety disorders (Eid et al., 2019; Schuch et al., 2014) might explain a smaller amygdala in female depression than in healthy ones. Regarding its gray matter volumes changes, stress might be involved, as a study showed that mindfulness-based stress reductions decrease right basolateral amygdala gray matter density (Hölzel et al., 2010).

The DTI and fMRI studies reflected gender differences in the cingulum. An example is the active subcallosal cingulate gyrus. Notably, the higher activity of this gyrus is associated with negative emotional processing in a depression setting (Laxton et al., 2013). This higher activity reduces after depression treatment interventions, such as deep brain stimulation, anti-depressants, cingulotomy, electroconvulsive therapy, and repetitive transcranial magnetic stimulation (Hamani et al., 2011). Another gender disparity example was parahippocampal cingulum. More research needs to be conducted on this association, as hippocampal pathways play significant roles in reward processing (Bracht et al., 2015). Recent research on neuroimaging of the two sexes has revealed that diffusion findings could predict susceptibility to depressive symptoms across adolescence during the COVID-19 pandemic: females show lower fiber density and cross-section (FDC) of the cingulum than males, which leads to higher chances of depressive symptoms, lower resilience, and more stress (Chahal et al., 2022b).

The two hemispheres connector, the corpus callosum (cc), has also shown disparities in included volumetric and microstructural studies. Nevertheless, there is evidence of similar cc volumes in depressed and healthy subjects (Piras et al., 2021) and that only familial MDD is associated with cc thinning (Lacerda et al., 2005). However, there might be underlying physiological mechanisms of hormones for the latter sex difference. Low estrogen levels could lead to mood disturbances, and besides, estradiol is reported to regulate interhemispheric communication in women (Weis et al., 2008). Another reported dissimilarity was the corpus callosum genu. In MDD subjects, lower FA of some cc regions is associated with a longer illness duration. These regions include premotor and supplementary motor cortices

Table 4 Overview of fMRI studies on sex differences in depression

Study	Tesla sequence	Brain areas	Connectivity/activation	Task	Methods for Sex Differences Analyses		Covariates	Results
					Sex by Diagnosis Effects	Model		
Amiri et al., 2021	3 T	SCG VCa NAC ITP LHb	Rs-FC	N/A	Nonparametric permutation	Yes	N/A	Difference in degree values in the SCG between males and females of the TRD. Higher degree values in all regions in the TRD females except in the R LHb.
Briceño et al., 2015	3 T	Fronto-limbic regions	Activation	Facial emotion perception test	ANOVA	Yes	N/A	Among fronto-limbic regions, there were no regions significant for an MDD status by gender interaction.
Chuang et al., 2017	3 T	Whole brain	Activation	Affective go/no-go task	GLM	Yes	Age	Significant group-by-sex differences in the activation of the supramarginal gyrus and posterior cingulate cortex, as those of male controls were more activated than female controls, but the activation of those in depressed males was lower than in depressed females.

Table 4 (continued)

Study	Tesla sequence	Brain areas	Connectivity/activation	Task	Methods for Sex Differences Analyses Sex by Diagnosis Effects		Covariates	Results
					Model	Tested? Findings		
De Almeida et al., 2011	3 T	prefrontal cortical–amygdala neural circuitry	Activation	Facial emotion perception test	Spearman rank correlation tests and Mann–Whitney U-tests	Yes	N/A	In MDD patients, there were no significant effects of sex on any of the connectivity measures. In between-group analysis, there were abnormal inverse left-sided top-down vmPFC–amygdala connectivity, left-sided sgACC–amygdala connectivity, and reduced positive left-sided vmPFC–sgACC to happy faces in females with MDD when compared to their healthy counterparts. In response to fearful faces, there was an abnormally increased positive left-sided sgACC–amygdala connectivity in MDD females. For males with MDD relative to healthy males, there were no significant abnormal findings.

Table 4 (continued)

Study	Tesla sequence	Brain areas	Connectivity/activation	Task	Methods for Sex Differences Analyses Sex by Diagnosis Effects		Covariates	Results
					Model	Tested? Findings		
Dong et al., 2022	3 T	Amygdala, hippocampus, medial orbitofrontal cortex, nucleus accumbens, and dorsolateral prefrontal cortex	Activation	Montreal imaging stress task	GLM	Yes	Age	Less deactivation in the amygdala, hippocampus, and nucleus accumbens of the female MDD group relative to the female HC group, whereas the male MDD and HC did not differ regarding the deactivation/activation of these regions.
Geng et al., 2019	3 T	Whole brain	Rs-FC	N/A	GLM	Yes	Age, years of education, disease duration, age at onset, number of depressive episodes, HAMD-17 score	Increased ReHo in the R STG and decreased ReHo in the R MFG in SD women compared to NSD women. Higher ReHo in the L inferior triangular frontal gyrus in both SD and NSD males.
Jenkins et al., 2018	3 T	Whole brain	Activation	Facial emotion perception test	GLM	Yes	Accuracy for each emotion, site	Greater activity in male HCs and rMDD females compared to their counterparts in either groups in the R thalamic cluster for the neutral contrast and in the R SFG cluster for the sad contrast. The opposite pattern in the L MTG and bilateral midbrain for sad contrast. No significant associations in the amygdala.

Table 4 (continued)

Study	Tesla sequence	Brain areas	Connectivity/activation	Task	Methods for Sex Differences Analyses Sex by Diagnosis Effects		Covariates	Results	
					Model	Tested? Findings			
Mei et al., 2022	3 T	Whole brain	Rs-FC	N/A	ANOVA	Yes	Yes	N/A	Decreased ALFF in the bilateral caudate nucleus and posterior cingulate gyrus of MDD males compared to MDD females and HC females. Increased ALFF in the bilateral caudate nucleus and posterior cingulate gyrus of MDD females compared to HC males.
Piani et al., 2021	3 T	Whole brain	Activation	Affective go/no-go task	GLM	Yes	Yes	Percent of responses to target stimuli, time of response to target stimuli, and percent of responses to non-target stimuli	More negative responses during the overall task and go/no-go condition in the right parahippocampus of MDD females compared to MDD males and in that of HC males than HC females More negative response during the task in the right calcarine of MDD females compared to MDD males and in that of HC males than HC females

Table 4 (continued)

Study	Tesla sequence	Brain areas	Connectivity/activation	Task	Methods for Sex Differences Analyses Sex by Diagnosis Effects		Covariates	Results
					Model	Tested? Findings		
Talishinsky et al., 2022	3 T	Whole brain	Rs-FC	N/A	ANOVA	Yes	N/A	Increased connectivity in subgenual cingulate and posterior cingulate areas and decreased connectivity in the anterior insula, temporal pole, and lateral prefrontal cortex in MDD males compared to HC males. None were seen in females.
Yao et al., 2014	3 T	Frontoparietal networks and attention network	Rs-FC	N/A	ANOVA	Yes	N/A	Higher ALFF values in the left postcentral gyrus and right superior temporal gyrus and lower ALFF values in the left superior temporal pole, left superior temporal gyrus, and the left superior frontal gyrus in male MDD patients when compared to female MDD patients

Table 4 (continued)

Study	Tesla sequence	Brain areas	Connectivity/activation	Task	Methods for Sex Differences Analyses Sex by Diagnosis Effects		Covariates	Results	
					Model	Tested? Findings			
Young et al., 2017	3 T	Whole brain	Activation	Autobiographical memory recall	ANOVA	Yes	Yes	N/A	Increased activity in the right dmPFC of MDD males compared to all other groups during recall of positive memories. Decreased activity in the right caudate of MDD females compared to all other groups during recall of positive memories. Increased activity in PCC and insula of HC females compared to both male groups during recall of negative memories. Decreased activity in precuneus of HC males compared to all other groups during recall of negative memories

Abbreviations: fMRI: Functional magnetic resonance imaging, Rs: Resting state, FC: Functional connectivity, SCG: Subcallosal cingulate gyrus, VCa: Ventral caudate, NAc: Nucleus accumbens, LHb: Lateral habenula, ITP: Inferior thalamic peduncle, ANOVA: analysis of variances, vmPFC: ventromedial prefrontal cortex, sgACC: subgenual anterior cingulate cortex, STG: Superior temporal gyrus, MFG: Middle frontal gyrus, MTG: middle temporal gyrus, SFG: Superior frontal gyrus, ReHo: Regional homogeneity, MDD: major depressive disorder, rMDD: Remitted major depressive disorder, SD: Somatic depression, NSD: Non-somatic depression, TRD: Treatment-resistant depression, ALFF: amplitude of low-frequency fluctuation, dmPFC: dorsomedial prefrontal cortex, PCC: posterior cingulate cortex, HC: Healthy control, HAMD: Hamilton Depression Rating Scale, GLM: General linear model, T: Tesla, N/A: Not applicable, R: Right, L: Left.

along with parietal, temporal, and occipital cortices (Zhao et al., 2021). Moreover, a related study suggested epigenetic changes during the cc microstructural changes in depression. They reported higher DNA methylation of the serotonin transporter gene and lower FA of the cc body were significantly correlated (Won et al., 2016). Note that the serotonin transporter gene (SLC6A4) reuptakes serotonin molecules, and the disturbed serotonergic system has been reported as a key factor in depression etiology (El-Mallakh & Ali, 2019).

Finally, a variety of brain fasciculi have also shown sex or gender dissimilarities in white matter studies. In males, it was the FOF and SLF, and in females, it was the left uncinate fasciculus (UF) that reflected sex differences. Notably, the onset time might affect the microstructure of FOF, as only late-onset MDD patients have shown decreased FA in the white matter (WM) of the FOF, with an inverse correlation with the severity of the disease (Cheng et al., 2014). Regarding the SLF, a study has shown that its FA degree values negatively correlate with depression severity, and the right SLF FA values associate with illness duration (Lai & Wu, 2014). Meanwhile, a report shows that lower FA in the left UF correlates with higher anhedonia scores, not the total depression scores (Fernandes et al., 2021). Anhedonia, meaning the inability to feel pleasure from pleasurable experiences, is reported to be comparable in the two sexes (Rueda 2019). However, there are reports that females experience seasonal variations of anhedonia in contrast to males, with peaks in the winter (Lyll et al., 2018).

As demonstrated in the results, there was heterogeneity among the reports of included studies. A potential factor leading to the results' heterogeneity could be the different definitions of *sex* and *gender* among the included studies. The term "sex" refers to the biological dissimilarities between males and females, while "gender" indicates a subjective sexual identity, masculine or feminine (Reale et al., 2021). Some of the included studies have used these terms interchangeably (Cyprien et al., 2014; Furtado et al., 2008; Hastings et al., 2004; Kronmüller et al., 2009). Most studies do not define the terms in their methodology. There were inconsistent reports of the same regions in studies using the terms "sex" and "gender". For example, as explained in the DTI results section, the study by Ho et al. showed no sex-specific changes in the FA of the genu of the corpus callosum (Ho et al., 2021a), while Lyon et al. reported gender differences in this region (Lyon et al., 2019).

One limitation is worth noting. Our study systematically searched all available relevant articles on sMRI, DTI, and fMRI investigations; however, we found no specific brain region showing alterations in all three of these imaging tools. The most frequently repeated regions with significant changes include limbic areas like the amygdala and hippocampus (mentioned in DTI and sMRI studies) and cingulum (in DTI and fMRI papers) as we have discussed in

previous paragraphs. This heterogeneity might result from different regions of interest, various methodologies, and the diverse nature of these modalities and the comorbidities of the subjects. Such differences include studies of the whole brain vs. specific brain areas, GM vs. WM, volume vs. density assessments, and activation vs. resting-state connectivity investigations. Moreover, DTI measures the diffusion of water molecules, making it more suitable for WM explorations along tracts, in contrast to fMRI and sMRI modalities which interrogate the gray matter (Ghazi Sherbaf et al., 2019).

We did not include results from other reviews or meta-analyses in the present systematic review. However, the comparison between our findings and well-known meta-analyses might shed light on the precise differences in depression of the two sexes. The Enhancing Neuro Imaging Genetics through Meta-Analysis (ENIGMA) consortium is an international collaborative group that currently includes 40 research samples from 14 different countries globally (Institute UMaMSNaI, 2023). In an sMRI study, the ENIGMA MDD working group assessed subcortical brain alterations in 1728 MDD cases and 7199 normal controls from 15 cohorts. They observed no significant diagnosis-by-sex interaction effects in the subcortical GM of subjects (Schmaal et al., 2016). Similarly, they found no significant impact of sex when assessing structural cortical abnormalities of 2148 MDD patients and 7957 normal controls from 20 research sites (Schmaal et al., 2017b). They also performed a DTI-based analysis of 1305 MDD cases and 1602 HCs from 20 samples. These results revealed a significant diagnosis-by-sex interaction; male adolescent patients (age ≤ 21) had higher uncinate fasciculus radial diffusivity than adolescent male controls, and this interaction was absent in females (Velzen et al., 2020). In our review, uncinate fasciculus alterations mainly reflected differences between females with and without depression. We did find sex differences in the composite of sMRI studies that we reviewed.

Of the underlying mechanisms of depression, the contribution of sex hormones to female and male differences remains to be discussed. As previously explained, the incidence rates of depression are similar in the sexes before puberty, and the gender gap starts afterward (Wesselhoeft et al., 2015). According to a systematic review by Morsinkhof et al., sex hormones, including estradiol, progesterone, luteinizing hormone (LH), and follicle-stimulating hormone (FSH), do not seem to have different absolute levels in depressed subjects and healthy controls (Morsinkhof et al., 2020). Previous reports have demonstrated associations between sex hormones and neuroimaging findings. For example, the GM volumes of the supplementary motor area, inferior frontal gyrus, and superior temporal gyrus are positively correlated with serum levels of estradiol in healthy post- and pre-menopause women (Kim et al., 2018),

and there have been reports of associations between higher midlife testosterone levels and larger hemispheric, frontal, and parietal regional brain volumes and with smaller left occipital brain volume (Lessov-Schlaggar et al., 2005).

As most studies have reported comparable levels of sex hormones in healthy and depressed people (Morssinkhof et al., 2020), it is unlikely that brain alterations in depression are directly related to sex hormones. However, the sex hormones may still play a role in depression. For example, post-partum depression affects 7–20% of women following delivery, and there are reports that prophylactically administering conjugated estrogen after delivery can prevent its symptoms (Schiller et al., 2015). This response of patients may suggest the role of estrogen/progesterone withdrawal in depression development (Schiller et al., 2015). Similar hormonal withdrawal happens in the menopause transition in older age, and various studies have indicated the short-term efficacy of estradiol in depressed perimenopausal women (Schmidt & Rubinow, 2009). However, further studies are needed to unravel the interactions between sex hormones and brain alterations in these depressed people.

The findings of our systematic review should be interpreted in light of some limitations. First, we only included case–control and cohort studies, and therefore, clinical trials, case reports, narrative reviews, and systematic reviews were excluded. We could not also add all the eligible demographic and patient characteristic data, as these specifics of some studies were not available. Moreover, the included studies themselves had varying degrees of different biases, which could have affected the power of our systematic review. Concerning the sample of studies, some studies had recruited a small sample size, and not all of them matched participants for potential confounding variables. The onset of the disease, the response to treatment, and history of anti-depressants use might also affect the neuroimaging results, which differed in the included studies.

Another significant limitation of our study was the heterogeneity of study samples regarding the age of patients. Studies have repeatedly reported that depression often emerges during adolescence (Ho et al., 2021b) and that depression symptoms of adolescent and adult patients differ (e.g., adults experience more anhedonia, while appetite and weight change, loss of energy, and insomnia are more common in adolescents) (Rice et al., 2019). These differences in epidemiology and clinical manifestations might have affected the results of our study. Moreover, the diagnosis of patients in studies varied, as some assessed MDD subjects of all ages and status of treatment, while others only assessed treatment-resistant or early/late-onset depression. Finally, the imaging methodology and precision play a role in the final results; for example, not all studies assessed the whole-brain alterations.

In conclusion, our study provides information on the current literature regarding the neuroimaging findings of sex differences in depression. These findings should be interpreted alongside the differences in phenotype and clinical manifestations of the disease so that a better understanding of male and female depression emerges. In order to achieve more reliable results, further studies should be conducted with larger sample sizes and homogenous imaging methodologies considering the depression onset, age, treatment status, and treatment response of the participants. Moreover, future studies would better consider and define gender and biological sex in their investigations, since not all people with the same sex present the same subjective sexual identity and social behaviors. Treating gender as a continuous variable rather than a categorical dichotomous one, as suggested by previous neuropsychiatric researchers (Reilly, 2019), may be a useful research practice in this regard.

Supplementary Information The online version contains supplementary material available at <https://doi.org/10.1007/s11682-023-00772-8>.

Authors' contributions Soheil Mohammadi and Mohammad Amin Salehi designed the project, developed the protocol, contributed to screening and data extraction, and contributed to the writing of the original and final draft. Homa Seyedmirzaei contributed to the writing of the original and final draft. Ali Jahanshahi contributed to the data extraction. Seyed Sina Zakavi contributed to the screening. Fatemeh Dehghani Firouzabadi contributed to the writing of the original and final draft. David M. Yousem encouraged and supervised the project and contributed to writing of the original and final draft.

Data availability Not applicable.

Declarations

Ethical Approval Not applicable.

Competing interests Authors declare no conflicts of interest.

References

- Acosta, H., Tuulari, J. J., Scheinin, N. M., Hashempour, N., Rajasilta, O., & Lavonius, T. I. (2020). Prenatal maternal depressive symptoms are associated with smaller amygdalar volumes of four-year-old children. *Psychiatry research Neuroimaging.*, *304*, 111153.
- Acosta, H., Kantojärvi, K., Hashempour, N., Pelto, J., Scheinin, N. M., Lehtola, S. J., et al. (2020). Partial Support for an Interaction Between a Polygenic Risk Score for Major Depressive Disorder and Prenatal Maternal Depressive Symptoms on Infant Right Amygdalar Volumes. *Cerebral cortex (New York, NY 1991)*, *30*(12), 6121–34.
- Amiri, S., Arbabi, M., Kazemi, K., Parvareh-Rizi, M., & Mirbagheri, M. M. (2021). Characterization of brain functional connectivity in treatment-resistant depression. *Progress in Neuro-Psychopharmacology & Biological Psychiatry.*, *111*, 110346.
- Ancelin, M. L., Carrière, I., Artero, S., Maller, J., Meslin, C., Ritchie, K., et al. (2019). Lifetime major depression and grey-matter

- volume. *Journal of Psychiatry & Neuroscience : JPN.*, 44(1), 45–53.
- Averill, C.L., Satodiya, R.M., Scott, J.C., Wrocklage, K.M., Schweinsburg, B., Averill, L.A., et al (2017). Posttraumatic Stress Disorder and Depression Symptom Severities Are Differentially Associated With Hippocampal Subfield Volume Loss in Combat Veterans. Chronic stress (Thousand Oaks, Calif) 1.
- Beck, A. T., Ward, C. H., Mendelson, M., Mock, J., & Erbaugh, J. (1961). An inventory for measuring depression. *Archives of General Psychiatry*, 4, 561–571.
- Binesh, N., Kumar, A., Hwang, S., Mintz, J., & Thomas, M. A. (2004). Neurochemistry of late-life major depression: A pilot two-dimensional MR spectroscopic study. *Journal of Magnetic Resonance Imaging : JMRI*, 20(6), 1039–1045.
- Binnewies, J., Nawijn, L., Brandmaier, A. M., Baaré, W. F. C., Barrés-Faz, D., Drevon, C. A., et al. (2022). Associations of depression and regional brain structure across the adult lifespan: Pooled analyses of six population-based and two clinical cohort studies in the European Lifebrain consortium. *Neuroimage Clin.*, 36, 103180.
- Bracht, T., Jones, D. K., Müller, T. J., Wiest, R., & Walther, S. (2015). Limbic white matter microstructure plasticity reflects recovery from depression. *Journal of Affective Disorders.*, 170, 143–149.
- Brébion, G., Núñez, C., Lombardini, F., Senior, C., Sánchez Laforga, A. M., Siddi, S., et al. (2021a). Subclinical depression and anxiety impact verbal memory functioning differently in men and women—an fMRI study. *Journal of Psychiatric Research.*, 140, 308–315.
- Brébion, G., Núñez, C., Lombardini, F., Senior, C., Sánchez Laforga, A. M., Siddi, S., et al. (2021b). Subclinical depression and anxiety impact verbal memory functioning differently in men and women -an fMRI study. *Journal of Psychiatric Research.*, 140, 308–315.
- Briceño, E. M., Rapport, L. J., Kassel, M. T., Bieliauskas, L. A., Zubieta, J. K., Weisenbach, S. L., et al. (2015). Age and gender modulate the neural circuitry supporting facial emotion processing in adults with major depressive disorder. *The American Journal of Geriatric Psychiatry*, 23(3), 304–313.
- Brown, S. A., Brumback, T., Tomlinson, K., Cummins, K., Thompson, W. K., Nagel, B. J., et al. (2015). The National Consortium on Alcohol and NeuroDevelopment in Adolescence (NCANDA): A Multisite Study of Adolescent Development and Substance Use. *Journal of Studies on Alcohol and Drugs*, 76(6), 895–908.
- Burke, J., McQuoid, D. R., Payne, M. E., Steffens, D. C., Krishnan, R. R., & Taylor, W. D. (2011). Amygdala volume in late-life depression: Relationship with age of onset. *The American Journal of Geriatric Psychiatry : Official Journal of the American Association for Geriatric Psychiatry.*, 19(9), 771–776.
- Carceller-Sindreu, M., de Diego-Adelino, J., Serra-Blasco, M., Vives-Gilbert, Y., Martín-Blanco, A., Puigdemont, D., et al. (2015). Volumetric MRI study of the habenula in first episode, recurrent and chronic major depression. *European Neuropsychopharmacology : The Journal of the European College of Neuropsychopharmacology.*, 25(11), 2015–2021.
- Carlson, J. M., Depetro, E., Maxwell, J., Harmon-Jones, E., & Hajcak, G. (2015). Gender moderates the association between dorsal medial prefrontal cortex volume and depressive symptoms in a subclinical sample. *Psychiatry Research - Neuroimaging.*, 233(2), 285–288.
- Caroleo, M., Carbone, E. A., Primerano, A., Foti, D., Brunetti, A., & Segura-Garcia, C. (2019). The role of hormonal, metabolic and inflammatory biomarkers on sleep and appetite in drug free patients with major depression: A systematic review. *Journal of Affective Disorders.*, 250, 249–259.
- Cattarinussi, G., Delvecchio, G., Maggioni, E., Bressi, C., & Brambilla, P. (2021). Ultra-high field imaging in Major Depressive Disorder: A review of structural and functional studies. *Journal of Affective Disorders.*, 290, 65–73.
- Cavanagh, A., Wilson, C. J., Caputi, P., & Kavanagh, D. J. (2016). Symptom endorsement in men versus women with a diagnosis of depression: A differential item functioning approach. *International Journal of Social Psychiatry*, 62(6), 549–559.
- Cavanagh, A., Wilson, C. J., Kavanagh, D. J., & Caputi, P. (2017). Differences in the Expression of Symptoms in Men Versus Women with Depression: A Systematic Review and Meta-analysis. *Harvard Review of Psychiatry*, 25(1), 29–38.
- Čermaková, P., Andrášková, L., Brázdil, M., Marečková, K. (2020). Socioeconomic deprivation in early life and symptoms of depression and anxiety in young adulthood: mediating role of hippocampal connectivity. *Psychological medicine.* 1–10.
- Chahal, R., Ho, T. C., Miller, J. G., Borchers, L. R., & Gotlib, I. H. (2022a). Sex-specific vulnerability to depressive symptoms across adolescence and during the COVID-19 pandemic: The role of the cingulum bundle. *JCPP Adv.*, 2(1), e12061.
- Chahal, R., Ho, T. C., Miller, J. G., Borchers, L. R., & Gotlib, I. H. (2022b). Sex-specific vulnerability to depressive symptoms across adolescence and during the COVID-19 pandemic: The role of the cingulum bundle. *JCPP Advances.*, 2(1), e12061.
- Chen, G., Guo, Y., Zhu, H., Kuang, W., Bi, F., Ai, H., et al. (2017). Intrinsic disruption of white matter microarchitecture in first-episode, drug-naïve major depressive disorder: A voxel-based meta-analysis of diffusion tensor imaging. *Progress in Neuro-Psychopharmacology and Biological Psychiatry*, 76, 179–187.
- Cheng, Y., Xu, J., Yu, H., Nie, B., Li, N., Luo, C., et al. (2014). Delineation of Early and Later Adult Onset Depression by Diffusion Tensor Imaging. *PLoS ONE*, 9(11), e112307.
- Chuang, J. Y., Hagan, C. C., Murray, G. K., Graham, J. M. E., Ooi, C., Tait, R., et al. (2017). Adolescent Major Depressive Disorder: Neuroimaging Evidence of Sex Difference during an Affective Go/No-Go Task. *Front Psychiatry.*, 8, 119.
- Cohen, J. D., Nichols, T., Keller, J., Gomez, R. G., Schatzberg, A. F., & Reiss, A. L. (2013). Insular cortex abnormalities in psychotic major depression: Relationship to gender and psychotic symptoms. *Neuroscience Research.*, 75(4), 331–339.
- Cyprien, F., Courtet, P., Poulain, V., Maller, J., Meslin, C., Bonafé, A., et al. (2014). Corpus callosum size may predict late-life depression in women: A 10-year follow-up study. *Journal of Affective Disorders.*, 165, 16–23.
- De Almeida, J.R.C., Kronhaus, D.M., Sibille, E.L., Langenecker, S.A., Versace, A., LaBarbara, E.J., et al. (2011). Abnormal left-sided orbitomedial prefrontal cortical-amygdala connectivity during happy and fear face processing: A potential neural mechanism of female MDD. *Frontiers in Psychiatry.* 2(DEC).
- Dean, D. C., 3rd., Planalp, E. M., Wooten, W., Kecskemeti, S. R., Adluru, N., Schmidt, C. K., et al. (2018). Association of Prenatal Maternal Depression and Anxiety Symptoms With Infant White Matter Microstructure. *JAMA Pediatrics.*, 172(10), 973–981.
- Delvecchio, G., Altamura, A. C., Soares, J. C., & Brambilla, P. (2017). Pituitary gland in Bipolar Disorder and Major Depression: Evidence from structural MRI studies: Special Section on “Translational and Neuroscience Studies in Affective Disorders”. Section Editor, Maria Nobile MD, PhD. This Section of JAD focuses on the relevance of translational and neuroscience studies in providing a better understanding of the neural basis of affective disorders. The main aim is to briefly summarise relevant research findings in clinical neuroscience with particular regards to specific innovative topics in mood and anxiety disorders. *Journal of affective disorders.*, 218, 446–50.
- Deng, Y., McQuoid, D. R., Potter, G. G., Steffens, D. C., Albert, K., Riddle, M., et al. (2018). Predictors of recurrence in remitted late-life depression. *Depression and Anxiety.*, 35(7), 658–667.

- Domschke, K., Dannlowski, U., Ohrmann, P., Lawford, B., Bauer, J., Kugel, H., et al. (2008). Cannabinoid receptor 1 (CNR1) gene: Impact on antidepressant treatment response and emotion processing in major depression. *European Neuropsychopharmacology: The Journal of the European College of Neuropsychopharmacology*, 18(10), 751–759.
- Dong, D., Ironside, M., Belleau, E. L., Sun, X., Cheng, C., Xiong, G., et al. (2022). Sex-specific neural responses to acute psychosocial stress in depression. *Translational Psychiatry*, 12(1), 2.
- Dotson, V. M., Zonderman, A. B., Kraut, M. A., & Resnick, S. M. (2013). Temporal relationships between depressive symptoms and white matter hyperintensities in older men and women. *International Journal of Geriatric Psychiatry*, 28(1), 66–74.
- Eid, R. S., Gobinath, A. R., & Galea, L. A. M. (2019). Sex differences in depression: Insights from clinical and preclinical studies. *Progress in Neurobiology*, 176, 86–102.
- Elbejjani, M., Fuhrer, R., Abrahamowicz, M., Mazoyer, B., Crivello, F., Tzourio, C., et al. (2014). Hippocampal atrophy and subsequent depressive symptoms in older men and women: Results from a 10-year prospective cohort. *American Journal of Epidemiology*, 180(4), 385–393.
- Elbejjani, M., Fuhrer, R., Abrahamowicz, M., Mazoyer, B., Crivello, F., Tzourio, C., et al. (2015). Depression, depressive symptoms, and rate of hippocampal atrophy in a longitudinal cohort of older men and women. *Psychological Medicine*, 45(9), 1931–1944.
- Ellis, R., Fernandes, A., Simmons, J. G., Mundy, L., Patton, G., Allen, N. B., et al. (2019). Relationships between adrenarcheal hormones, hippocampal volumes and depressive symptoms in children. *Psychoneuroendocrinology*, 104, 55–63.
- El-Mallakh, R. S., & Ali, Z. (2019). Therapeutic implications of the serotonin transporter gene in depression. *Biomarkers in Neuropsychiatry*, 1, 100004.
- Fernandes, B., Diaz, A. P., Scaini, G., Mwangi, B., Wu, M.-J., Quevedo, J., et al. (2021). C-Reactive Protein and the Uncinate Fasciculus in Anhedonia and Depression. *Biological Psychiatry*, 89(9), S272.
- Filippi, M., & Agosta, F. (2016). Diffusion tensor imaging and functional MRI. *Handbook of Clinical Neurology*, 136, 1065–1087.
- Frodil, T., Meisenzahl, E. M., Zetzsche, T., Born, C., Groll, C., Jäger, M., et al. (2002). Hippocampal changes in patients with a first episode of major depression. *The American Journal of Psychiatry*, 159(7), 1112–1118.
- Frodil, T., Reinhold, E., Koutsouleris, N., Reiser, M., & Meisenzahl, E. M. (2010). Interaction of childhood stress with hippocampus and prefrontal cortex volume reduction in major depression. *Journal of Psychiatric Research*, 44(13), 799–807.
- Frodil, T., Janowitz, D., Schmaal, L., Tozzi, L., Dobrowolny, H., Stein, D. J., et al. (2017). Childhood adversity impacts on brain subcortical structures relevant to depression. *Journal of Psychiatric Research*, 86, 58–65.
- Furtado, C. P., Maller, J. J., & Fitzgerald, P. B. (2008). A magnetic resonance imaging study of the entorhinal cortex in treatment-resistant depression. *Psychiatry Research*, 163(2), 133–142.
- Gadernann, A. M., Alonso, J., Vilagut, G., Zaslavsky, A. M., & Kessler, R. C. (2012). Comorbidity and disease burden in the National Comorbidity Survey Replication (NCS-R). *Depression and Anxiety*, 29(9), 797–806.
- Geerlings, M. I., & Gerritsen, L. (2017). Late-Life Depression, Hippocampal Volumes, and Hypothalamic-Pituitary-Adrenal Axis Regulation: A Systematic Review and Meta-analysis. *Biological Psychiatry*, 82(5), 339–350.
- Geng, J., Yan, R., Shi, J., Chen, Y., Mo, Z., Shao, J., et al. (2019). Altered regional homogeneity in patients with somatic depression: A resting-state fMRI study. *Journal of Affective Disorders*, 246, 498–505.
- Ghazi Sherbaf, F., Aarabi, M. H., Hosein Yazdi, M., & Haghshomar, M. (2019). White matter microstructure in fetal alcohol spectrum disorders: A systematic review of diffusion tensor imaging studies. *Human Brain Mapping*, 40(3), 1017–1036.
- Giedd, J. N., Raznahan, A., Mills, K. L., & Lenroot, R. K. (2012). Review: Magnetic resonance imaging of male/female differences in human adolescent brain anatomy. *Biology of Sex Differences*, 3(1), 19.
- Gold, S. M., Köhler-Forsberg, O., Moss-Morris, R., Mehnert, A., Miranda, J. J., Bullinger, M., et al. (2020). Comorbid depression in medical diseases. *Nature Reviews Disease Primers*, 6(1), 69.
- Gorham, L. S., Jernigan, T., Hudziak, J., & Barch, D. M. (2019). Involvement in Sports, Hippocampal Volume, and Depressive Symptoms in Children. *Biological Psychiatry Cognitive Neuroscience and Neuroimaging*, 4(5), 484–492.
- Hamani, C., Mayberg, H., Stone, S., Laxton, A., Haber, S., & Lozano, A. M. (2011). The subcallosal cingulate gyrus in the context of major depression. *Biological Psychiatry*, 69(4), 301–308.
- Hamilton, M. (1960). A rating scale for depression. *Journal of Neurology, Neurosurgery and Psychiatry*, 23(1), 56–62.
- Hastings, R. S., Parsey, R. V., Oquendo, M. A., Arango, V., & Mann, J. J. (2004). Volumetric analysis of the prefrontal cortex, amygdala, and hippocampus in major depression. *Neuropsychopharmacology: Official Publication of the American College of Neuropsychopharmacology*, 29(5), 952–959.
- Hay, R. E., Reynolds, J. E., Grohs, M. N., Paniukov, D., Giesbrecht, G. F., Letourneau, N., et al. (2020). Amygdala-Prefrontal Structural Connectivity Mediates the Relationship between Prenatal Depression and Behavior in Preschool Boys. *The Journal of Neuroscience: The Official Journal of the Society for Neuroscience*, 40(36), 6969–6977.
- Hayakawa, Y. K., Sasaki, H., Takao, H., Hayashi, N., Kunimatsu, A., Ohtomo, K., et al. (2014). Depressive symptoms and neuroanatomical structures in community-dwelling women: A combined voxel-based morphometry and diffusion tensor imaging study with tract-based spatial statistics. *NeuroImage Clinical*, 4, 481–487.
- Herreen, D., Rice, S., & Zajac, I. (2022). Brief assessment of male depression in clinical care: Validation of the Male Depression Risk Scale short form in a cross-sectional study of Australian men. *British Medical Journal Open*, 12(3), e053650.
- Ho, T. C., Sisk, L. M., Kulla, A., Teresi, G. I., Hansen, M. M., Wu, H., et al. (2021b). Sex differences in myelin content of white matter tracts in adolescents with depression. *Neuropsychopharmacology*, 46(13), 2295–2303.
- Ho, T.C., Sisk, L.M., Kulla, A., Teresi, G.I., Hansen, M.M., Wu, H., et al. (2021a). Sex differences in myelin content of white matter tracts in adolescents with depression. *Neuropsychopharmacology: official publication of the American College of Neuropsychopharmacology*.
- Hölzel, B. K., Carmody, J., Evans, K. C., Hoge, E. A., Dusek, J. A., Morgan, L., et al. (2010). Stress reduction correlates with structural changes in the amygdala. *Soc Cogn Affect Neurosci*, 5(1), 11–17.
- Hoobehfekar, S., Moghaddam, H. S., Shalbanan, M., Hashemi, M. G., Pirmoradi, M. M., Sakenian, A., et al. (2021). Efficacy and safety of tipepidine as adjunctive therapy in major depressive disorder: A randomized, double-blind, placebo-controlled clinical trial. *Psychiatry and Clinical Neurosciences*, 75(2), 57–62.
- Hu, Y., Moore, M., Bertels, Z., Phan, K. L., Dolcos, F., & Dolcos, S. (2020). Smaller amygdala volume and increased neuroticism predict anxiety symptoms in healthy subjects: A volumetric approach using manual tracing. *Neuropsychologia*, 145, 106564.
- Huang, G. Q., Wang, H. B., Xu, L. Y., Wang, J. W., Li, X. H., & Yu, Y. Q. (2014). Functional MRI study on gender-related difference of caudate nucleus activation for emotional memory in major

- depressive disorder. *Chinese Journal of Interventional Imaging and Therapy.*, 11(9), 582–586.
- Institute UMaMSNaI. (2023). ENIGMA MDD [Available from: <https://enigma.ini.usc.edu/ongoing/enigma-mdd-working-group/>].
- Jenkins, L. M., Kendall, A. D., Kassel, M. T., Patrón, V. G., Gowins, J. R., Dion, C., et al. (2018). Considering sex differences clarifies the effects of depression on facial emotion processing during fMRI. *Journal of Affective Disorders.*, 225, 129–136.
- Katon, W. J. (2011). Epidemiology and treatment of depression in patients with chronic medical illness. *Dialogues in Clinical Neuroscience.*, 13(1), 7–23.
- Kaufman, J., Birmaher, B., Brent, D., Rao, U., Flynn, C., Moreci, P., et al. (1997). Schedule for Affective Disorders and Schizophrenia for School-Age Children-Present and Lifetime Version (K-SADS-PL): Initial reliability and validity data. *Journal of the American Academy of Child and Adolescent Psychiatry.*, 36(7), 980–988.
- Keller, M., Zweerings, J., Klasen, M., Zvyagintsev, M., Iglesias, J., Mendoza Quiñones, R., et al. (2021). fMRI Neurofeedback-Enhanced Cognitive Reappraisal Training in Depression: A Double-Blind Comparison of Left and Right vPFC Regulation. *Frontiers in Psychiatry.*, 12, 715898.
- Kempton, M. J., Salvador, Z., Munafò, M. R., Geddes, J. R., Simmons, A., Frangou, S., et al. (2011). Structural neuroimaging studies in major depressive disorder Meta-analysis and comparison with bipolar disorder. *Arch Gen Psychiatry.*, 68(7), 675–90.
- Kim, G. W., Park, K., & Jeong, G. W. (2018). Effects of Sex Hormones and Age on Brain Volume in Post-Menopausal Women. *The Journal of Sexual Medicine.*, 15(5), 662–670.
- Kim, H., Kwak, S., Kim, J., Youm, Y., & Chey, J. (2019). Social Network Position Moderates the Relationship between Late-life Depressive Symptoms and Memory Differently in Men and Women. *Scientific Reports.*, 9(1), 6142.
- Kircanski, K., Sisk, L. M., Ho, T. C., Humphreys, K. L., King, L. S., Colich, N. L., et al. (2019). Early life stress, cortisol, frontolimbic connectivity, and depressive symptoms during puberty. *Development and Psychopathology.*, 31(3), 1011–1022.
- Kirton, J. W., Resnick, S. M., Davatzikos, C., Kraut, M. A., & Dotson, V. M. (2014). Depressive symptoms, symptom dimensions, and white matter lesion volume in older adults: A longitudinal study. *The American Journal of Geriatric Psychiatry : Official Journal of the American Association for Geriatric Psychiatry.*, 22(12), 1469–1477.
- Kliamovich, D., Jones, S. A., Chiapuzio, A. M., Baker, F. C., Clark, D. B., & Nagel, B. J. (2021). Sex-specific patterns of white matter microstructure are associated with emerging depression during adolescence. *Psychiatry Research Neuroimaging.*, 315, 111324.
- Kong, L., Chen, K., Womer, F., Jiang, W., Luo, X., Driesen, N., et al. (2013). Sex differences of gray matter morphology in cortico-limbic-striatal neural system in major depressive disorder. *Journal of Psychiatric Research.*, 47(6), 733–739.
- Kovacs M. (n.d). Children's Depression Inventory (CDI and CDI 2). The Encyclopedia of Clinical Psychology. p. 1–5.
- Kronmüller, K. T., Pantel, J., Götz, B., Köhler, S., Victor, D., Mundt, C., et al. (2008). Life events and hippocampal volume in first-episode major depression. *Journal of Affective Disorders.*, 110(3), 241–247.
- Kronmüller, K. T., Schröder, J., Köhler, S., Götz, B., Victor, D., Unger, J., et al. (2009). Hippocampal volume in first episode and recurrent depression. *Psychiatry Research.*, 174(1), 62–66.
- Kuehner, C. (2017). Why is depression more common among women than among men? *Lancet Psychiatry.*, 4(2), 146–158.
- Lacerda, A. L., Brambilla, P., Sassi, R. B., Nicoletti, M. A., Mallinger, A. G., Frank, E., et al. (2005). Anatomical MRI study of corpus callosum in unipolar depression. *Journal of Psychiatric Research.*, 39(4), 347–354.
- Lai, C. H., & Wu, Y. T. (2014). Alterations in white matter micro-integrity of the superior longitudinal fasciculus and anterior thalamic radiation of young adult patients with depression. *Psychological Medicine.*, 44(13), 2825–2832.
- Lavretsky, H., Lesser, I. M., Wohl, M., & Miller, B. L. (1998). Relationship of age, age at onset, and sex to depression in older adults. *The American Journal of Geriatric Psychiatry : Official Journal of the American Association for Geriatric Psychiatry.*, 6(3), 248–256.
- Lavretsky, H., Kurbanyan, K., Ballmaier, M., Mintz, J., Toga, A., & Kumar, A. (2004). Sex differences in brain structure in geriatric depression. *The American Journal of Geriatric Psychiatry : Official Journal of the American Association for Geriatric Psychiatry.*, 12(6), 653–657.
- Laxton, A. W., Neimat, J. S., Davis, K. D., Womelsdorf, T., Hutchison, W. D., Dostrovsky, J. O., et al. (2013). Neuronal coding of implicit emotion categories in the subcallosal cortex in patients with depression. *Biological Psychiatry.*, 74(10), 714–719.
- Lebedeva, A., Borza, T., Häberg, A. K., Idland, A. V., Dalaker, T. O., Aarsland, D., et al. (2015). Neuroanatomical correlates of late-life depression and associated cognitive changes. *Neurobiology of Aging.*, 36(11), 3090–3099.
- Lee, A., Poh, J. S., Wen, D. J., Guillaume, B., Chong, Y. S., Shek, L. P., et al. (2019). Long-term Influences of Prenatal Maternal Depressive Symptoms on the Amygdala-Prefrontal Circuitry of the Offspring From Birth to Early Childhood. *Biological Psychiatry Cognitive Neuroscience and Neuroimaging.*, 4(11), 940–947.
- Lépine, J. P., & Briley, M. (2011). The increasing burden of depression. *Neuropsychiatric Disease and Treatment.*, 7(Suppl 1), 3–7.
- Lessov-Schlaggar, C. N., Reed, T., Swan, G. E., Krasnow, R. E., DeCarli, C., Marcus, R., et al. (2005). Association of sex steroid hormones with brain morphology and cognition in healthy elderly men. *Neurology.*, 65(10), 1591–1596.
- Lewine, R. R., Hudgins, P., Brown, F., Caudle, J., & Risch, S. C. (1995). Differences in qualitative brain morphology findings in schizophrenia, major depression, bipolar disorder, and normal volunteers. *Schizophrenia Research.*, 15(3), 253–259.
- Li, C., Schreiber, J., Bittner, N., Li, S., Huang, R., Moebus, S., et al. (2020). White Matter Microstructure Underlies the Effects of Sleep Quality and Life Stress on Depression Symptomatology in Older Adults. *Frontiers in Aging Neuroscience.*, 12, 578037.
- Li, G. Z., Liu, P. H., Zhang, A. X., Andari, E., & Zhang, K. R. (2022). A resting state fMRI study of major depressive disorder with and without anxiety. *Psychiatry Research.*, 315, 114697.
- Liu, Y., Wang, K., Yu, C., He, Y., Zhou, Y., Liang, M., et al. (2008). Regional homogeneity, functional connectivity and imaging markers of Alzheimer's disease: A review of resting-state fMRI studies. *Neuropsychologia.*, 46(6), 1648–1656.
- Liu, C. H., Ma, X., Li, F., Wang, Y. J., Tie, C. L., Li, S. F., et al. (2012). Regional homogeneity within the default mode network in bipolar depression: A resting-state functional magnetic resonance imaging study. *PLoS ONE.*, 7(11), e48181.
- Lyall, L. M., Wyse, C. A., Celis-Morales, C. A., Lyall, D. M., Cullen, B., Mackay, D., et al. (2018). Seasonality of depressive symptoms in women but not in men: A cross-sectional study in the UK Biobank cohort. *Journal of Affective Disorders.*, 229, 296–305.
- Lyon, M., Welton, T., Varda, A., Maller, J. J., Broadhouse, K., Korgaonkar, M. S., et al. (2019). Gender-specific structural abnormalities in major depressive disorder revealed by fixel-based analysis. *Neuroimage Clin.*, 21, 101668.
- MacMaster, F. P., Russell, A., Mirza, Y., Keshavan, M. S., Taormina, S. P., Bhandari, R., et al. (2006). Pituitary volume in treatment-naïve pediatric major depressive disorder. *Biological Psychiatry.*, 60(8), 862–866.
- MacMaster, F. P., Leslie, R., Rosenberg, D. R., & Kusumakar, V. (2008). Pituitary gland volume in adolescent and young adult

- bipolar and unipolar depression. *Bipolar Disorders.*, 10(1), 101–104.
- Maglanoc, L. A., Kaufmann, T., Jonassen, R., Hilland, E., Beck, D., Landrø, N. I., et al. (2020). Multimodal fusion of structural and functional brain imaging in depression using linked independent component analysis. *Human Brain Mapping.*, 41(1), 241–255.
- Maller, J. J., Daskalakis, Z. J., & Fitzgerald, P. B. (2007). Hippocampal volumetrics in depression: The importance of the posterior tail. *Hippocampus*, 17(11), 1023–1027.
- McCarter, T. (2008). Depression overview. *Am Health Drug Benefit.*, 1(3), 44–51.
- Mei, L., Wang, Y., Liu, C., Mou, J., Yuan, Y., Qiu, L., et al. (2022). Study of Sex Differences in Unmedicated Patients With Major Depressive Disorder by Using Resting State Brain Functional Magnetic Resonance Imaging. *Frontiers in Neuroscience*, 16, 814410.
- Melartin, T. K., Rytysälä, H. J., Leskelä, U. S., Lestelä-Mielonen, P. S., Sokero, T. P., & Isometsä, E. T. (2002). Current comorbidity of psychiatric disorders among DSM-IV major depressive disorder patients in psychiatric care in the Vantaa Depression Study. *The Journal of Clinical Psychiatry.*, 63(2), 126–134.
- Menzler, K., Belke, M., Wehrmann, E., Krakow, K., Lengler, U., Jansen, A., et al. (2011). Men and women are different: Diffusion tensor imaging reveals sexual dimorphism in the microstructure of the thalamus, corpus callosum and cingulum. *NeuroImage*, 54(4), 2557–2562.
- Meruelo, A. D., Brumback, T., Nagel, B. J., Baker, F. C., Brown, S. A., & Tapert, S. F. (2021). Neuroimaging markers of adolescent depression in the National Consortium on Alcohol and Neurodevelopment in Adolescence (NCANDA) study. *Journal of Affective Disorders*, 287, 380–386.
- Montgomery, S. A., & Asberg, M. (1979). A new depression scale designed to be sensitive to change. *The British Journal of Psychiatry: The Journal of Mental Science.*, 134, 382–389.
- Morssinkhof, M. W. L., van Wylick, D. W., Priester-Vink, S., van der Werf, Y. D., den Heijer, M., van den Heuvel, O. A., et al. (2020). Associations between sex hormones, sleep problems and depression: A systematic review. *Neuroscience and Biobehavioral Reviews*, 118, 669–680.
- Moulinet, I., Landeau, B., Touron, E., De La Sayette, V., Desgranges, B., Vivien, D., et al. (2021). Sex-specificities in anxiety and depressive symptoms across the lifespan and their links with multimodal neuroimaging. *Journal of Affective Disorders.*, 296, 593–602.
- Murray, A. D., Staff, R. T., McNeil, C. J., Salarirad, S., Phillips, L. H., Starr, J., et al. (2013). Depressive symptoms in late life and cerebrovascular disease: The importance of intelligence and lesion location. *Depression and Anxiety.*, 30(1), 77–84.
- Nielsen, J. D., Case, J. A. C., Divers, R. M., Kautz, M. M., Alloy, L. B., & Olino, T. M. (2020). Trajectories of depressive symptoms through adolescence as predictors of cortical thickness in the orbitofrontal cortex: An examination of sex differences. *Psychiatry Research Neuroimaging.*, 303, 111132.
- Ogrodniczuk, J. S., & Oliffe, J. L. (2011). Men and depression. *Canadian Family Physician*, 57(2), 153–155.
- Osman, A., Wong, J. L., Bagge, C. L., Freedenthal, S., Gutierrez, P. M., & Lozano, G. (2012). The Depression Anxiety Stress Scales-21 (DASS-21): Further examination of dimensions, scale reliability, and correlates. *Journal of Clinical Psychology*, 68(12), 1322–1338.
- Parsey, R. V., Oquendo, M. A., Simpson, N. R., Ogden, R. T., Van Heertum, R., Arango, V., et al. (2002). Effects of sex, age, and aggressive traits in man on brain serotonin 5-HT_{1A} receptor binding potential measured by PET using [C-11]WAY-100635. *Brain Research*, 954(2), 173–182.
- Peng, W., Chen, Z., Yin, L., Jia, Z., & Gong, Q. (2016). Essential brain structural alterations in major depressive disorder: A voxel-wise meta-analysis on first episode, medication-naïve patients. *Journal of Affective Disorders*, 199, 114–123.
- Perlaki, G., Orsi, G., Plozer, E., Altbacker, A., Darnai, G., Nagy, S. A., et al. (2014). Are there any gender differences in the hippocampus volume after head-size correction? A volumetric and voxel-based morphometric study. *Neuroscience Letters*, 570, 119–123.
- Perlman, G., Bartlett, E., DeLorenzo, C., Weissman, M., McGrath, P., Ogden, T., et al. (2017). Cortical thickness is not associated with current depression in a clinical treatment study. *Human Brain Mapping.*, 38(9), 4370–4385.
- Petteimeridou, E., Kallousia, E., & Constantinidou, F. (2021). Regional Brain Volume, Brain Reserve and MMSE Performance in Healthy Aging From the NEUROAGE Cohort: Contributions of Sex, Education, and Depression Symptoms. *Front Aging Neurosci.*, 13, 711301.
- Piani, M. C., Maggioni, E., Delvecchio, G., Ferro, A., Gritti, D., Pozzoli, S. M., et al. (2021). Sexual Dimorphism in the Brain Correlates of Adult-Onset Depression: A Pilot Structural and Functional 3T MRI Study. *Front Psychiatry.*, 12, 683912.
- Pimontel, M. A., Reinlieb, M. E., Johnert, L. C., Garcon, E., Sneed, J. R., & Roose, S. P. (2013). The external validity of MRI-defined vascular depression. *International Journal of Geriatric Psychiatry.*, 28(11), 1189–1196.
- Piras, F., Vecchio, D., Kurth, F., Piras, F., Banaj, N., Ciullo, V., et al. (2021). Corpus callosum morphology in major mental disorders: a magnetic resonance imaging study. *Brain Communications.*, 3(2), fcab100.
- Poznanski, E., Mokros, H. B., Grossman, J., & Freeman, L. N. (1985). Diagnostic criteria in childhood depression. *American Journal of Psychiatry*, 142(10), 1168–1173.
- Radloff, L. S. (1977). The CES-D Scale: A self-report depression scale for research in the general population.
- Rajagopalan, P., Passe, T. J., Doraiswamy, P. M., Figiel, G. S., Macfall, J. R., & Krishnan, K. R. (1994). Changes in pituitary gland signal intensity and morphology as evaluated by magnetic resonance imaging in aging, depression, and by gender. *Depression*, 2(6), 303–307.
- Rakesh, D., Kelly, C., Vijayakumar, N., Zalesky, A., Allen, N. B., & Whittle, S. (2021). Unraveling the Consequences of Childhood Maltreatment: Deviations From Typical Functional Neurodevelopment Mediate the Relationship Between Maltreatment History and Depressive Symptoms. *Biological Psychiatry Cognitive Neuroscience and Neuroimaging.*, 6(3), 329–342.
- Reale, C., Invernizzi, F., Panteghini, C., Garavaglia, B. (2021). Genetics, sex, and gender. *J Neurosci Res*.
- Reilly, D. (2019). Gender can be a continuous variable, not just a categorical one: Comment on Hyde, Bigler, Joel, Tate, and van Anders (2019). *American Psychologist*, 74(7), 840–841.
- Reinlieb, M. E., Persaud, A., Singh, D., Garcon, E., Rutherford, B. R., Pelton, G. H., et al. (2014). Vascular depression: Overrepresented among African Americans? *International Journal of Geriatric Psychiatry.*, 29(5), 470–477.
- Reynolds, W. (2004). Reynolds Adolescent Depression Scale (RADS) Second Edition. p. 224–36.
- Rice, F., Riglin, L., Lomax, T., Souter, E., Potter, R., Smith, D. J., et al. (2019). Adolescent and adult differences in major depression symptom profiles. *Journal of Affective Disorders*, 243, 175–181.
- Ritter, C., Buchmann, A., Müller, S. T., Hersberger, M., Haynes, M., Ghisleni, C., et al. (2021). Cerebral perfusion in depression: Relationship to sex, dehydroepiandrosterone sulfate and depression severity. *NeuroImage Clinical.*, 32, 102840.
- Romans, S. E., Tyas, J., Cohen, M. M., & Silverstone, T. (2007). Gender differences in the symptoms of major depressive disorder. *The Journal of Nervous and Mental Disease*, 195(11), 905–911.

- Rueda, A. (2019). editor Gender Differences in Rates of Anhedonia and the Effect of Menstrual Cycles in University Students.
- Saleh, K., Carballedo, A., Lisiecka, D., Fagan, A. J., Connolly, G., Boyle, G., et al. (2012). Impact of family history and depression on amygdala volume. *Psychiatry Research.*, *203*(1), 24–30.
- Salk, R. H., Hyde, J. S., & Abramson, L. Y. (2017). Gender differences in depression in representative national samples: Meta-analyses of diagnoses and symptoms. *Psychological Bulletin*, *143*(8), 783–822.
- Savitz, J. B., Nugent, A. C., Bogers, W., Roiser, J. P., Bain, E. E., Neumeister, A., et al. (2011). Habenula volume in bipolar disorder and major depressive disorder: A high-resolution magnetic resonance imaging study. *Biological Psychiatry*, *69*(4), 336–343.
- Schiller, C. E., Meltzer-Brody, S., & Rubinow, D. R. (2015). The role of reproductive hormones in postpartum depression. *CNS Spectrums*, *20*(1), 48–59.
- Schmaal, L., Veltman, D. J., van Erp, T. G., Sämann, P. G., Frodl, T., Jahanshad, N., et al. (2016). Subcortical brain alterations in major depressive disorder: Findings from the ENIGMA Major Depressive Disorder working group. *Molecular Psychiatry*, *21*(6), 806–812.
- Schmaal, L., Yücel, M., Ellis, R., Vijayakumar, N., Simmons, J. G., Allen, N. B., et al. (2017a). Brain Structural Signatures of Adolescent Depressive Symptom Trajectories: A Longitudinal Magnetic Resonance Imaging Study. *Journal of the American Academy of Child and Adolescent Psychiatry.*, *56*(7), 593–601.e9.
- Schmaal, L., Hibar, D. P., Sämann, P. G., Hall, G. B., Baune, B. T., Jahanshad, N., et al. (2017b). Cortical abnormalities in adults and adolescents with major depression based on brain scans from 20 cohorts worldwide in the ENIGMA Major Depressive Disorder Working Group. *Molecular Psychiatry*, *22*(6), 900–909.
- Schmidt, P. J., & Rubinow, D. R. (2009). Sex hormones and mood in the perimenopause. *Annals of the New York Academy of Sciences*, *1179*, 70–85.
- Schuch, J. J., Roest, A. M., Nolen, W. A., Penninx, B. W., & de Jonge, P. (2014). Gender differences in major depressive disorder: Results from the Netherlands study of depression and anxiety. *Journal of Affective Disorders.*, *156*, 156–163.
- Sheehan, D.V., Lecrubier, Y., Sheehan, K.H., Amorim, P., Janavs, J., Weiller, E., et al. (1998). The Mini-International Neuropsychiatric Interview (M.I.N.I.): the development and validation of a structured diagnostic psychiatric interview for DSM-IV and ICD-10. *The Journal of clinical psychiatry*. *59* Suppl 20:22–33;quiz 4–57.
- Smith, D. J., Kyle, S., Forty, L., Cooper, C., Walters, J., Russell, E., et al. (2008). Differences in depressive symptom profile between males and females. *Journal of Affective Disorders*, *108*(3), 279–284.
- Soe, N. N., Wen, D. J., Poh, J. S., Chong, Y. S., Broekman, B. F., Chen, H., et al. (2018). Perinatal maternal depressive symptoms alter amygdala functional connectivity in girls. *Human Brain Mapping.*, *39*(2), 680–690.
- Sonnenberg, C. M., Deeg, D. J., van Tilburg, T. G., Vink, D., Stek, M. L., & Beekman, A. T. (2013). Gender differences in the relation between depression and social support in later life. *International Psychogeriatrics*, *25*(1), 61–70.
- Soriano-Mas, C., Hernández-Ribas, R., Pujol, J., Urretavizcaya, M., Deus, J., Harrison, B. J., et al. (2011). Cross-sectional and longitudinal assessment of structural brain alterations in melancholic depression. *Biological Psychiatry.*, *69*(4), 318–325.
- Spalletta, G., Piras, F., Caltagirone, C., & Fagioli, S. (2014). Hippocampal multimodal structural changes and subclinical depression in healthy individuals. *Journal of Affective Disorders.*, *152–154*, 105–112.
- Spitzer, R. L., Williams, J. B., Gibbon, M., & First, M. B. (1992). The Structured Clinical Interview for DSM-III-R (SCID) I: History, rationale, and description. *Arch Gen Psychiatry.*, *49*(8), 624–9.
- Staley, J. K., Sanacora, G., Tamagnan, G., Maciejewski, P. K., Malison, R. T., Berman, R. M., et al. (2006). Sex differences in diencephalon serotonin transporter availability in major depression. *Biological Psychiatry.*, *59*(1), 40–47.
- Stang, A. (2010). Critical evaluation of the Newcastle-Ottawa scale for the assessment of the quality of nonrandomized studies in meta-analyses. *European Journal of Epidemiology*, *25*(9), 603–605.
- Swartz, M. K. (2011). The PRISMA statement: A guideline for systematic reviews and meta-analyses. *Journal of Pediatric Health Care*, *25*(1), 1–2.
- Takahashi, T., Nishikawa, Y., Yücel, M., Whittle, S., Lorenzetti, V., Walterfang, M., et al. (2016). Olfactory sulcus morphology in patients with current and past major depression. *Psychiatry Research Neuroimaging.*, *255*, 60–65.
- Talishinsky, A., Downar, J., Vértes, P. E., Seidlitz, J., Dunlop, K., Lynch, C. J., et al. (2022). Regional gene expression signatures are associated with sex-specific functional connectivity changes in depression. *Nature Communications*, *13*(1), 5692.
- Tozzi, L., Garczarek, L., Janowitz, D., Stein, D. J., Wittfeld, K., Dobrowolny, H., et al. (2020). Interactive impact of childhood maltreatment, depression, and age on cortical brain structure: Mega-analytic findings from a large multi-site cohort. *Psychological Medicine.*, *50*(6), 1020–1031.
- Ugwu, I. D., Amico, F., Carballedo, A., Fagan, A. J., & Frodl, T. (2015). Childhood adversity, depression, age and gender effects on white matter microstructure: A DTI study. *Brain Structure & Function.*, *220*(4), 1997–2009.
- Ustün, T. B., Ayuso-Mateos, J. L., Chatterji, S., Mathers, C., & Murray, C. J. (2004). Global burden of depressive disorders in the year 2000. *The British Journal of Psychiatry : The Journal of Mental Science.*, *184*, 386–392.
- Vakili, K., Pillay, S. S., Lafer, B., Fava, M., Renshaw, P. F., Bonello-Cintron, C. M., et al. (2000). Hippocampal volume in primary unipolar major depression: A magnetic resonance imaging study. *Biological Psychiatry.*, *47*(12), 1087–1090.
- van Eijk, L., Hansell, N. K., Strike, L. T., Couvy-Duchesne, B., de Zubicar, G. I., Thompson, P. M., et al. (2020). Region-specific sex differences in the hippocampus. *NeuroImage*, *215*, 116781.
- van Tol, M. J., van der Wee, N. J., van den Heuvel, O. A., Nielen, M. M., Demenescu, L. R., Aleman, A., et al. (2010). Regional brain volume in depression and anxiety disorders. *Archives of General Psychiatry.*, *67*(10), 1002–1011.
- van Velzen, L. S., Kelly, S., Isaev, D., Aleman, A., Aftanas, L. I., Bauer, J., et al. (2020). White matter disturbances in major depressive disorder: A coordinated analysis across 20 international cohorts in the ENIGMA MDD working group. *Molecular Psychiatry.*, *25*(7), 1511–1525.
- Victor, T. A., Drevets, W. C., Misaki, M., Bodurka, J., & Savitz, J. (2017). Sex differences in neural responses to subliminal sad and happy faces in healthy individuals: Implications for depression. *Journal of Neuroscience Research.*, *95*(1–2), 703–710.
- Viswanathan, M., Ansari, M.T., Berkman, N.D., Chang, S., Hartling, L., McPheeters, M., et al., (2008) AHRQ Methods for Effective Health Care Assessing the Risk of Bias of Individual Studies in Systematic Reviews of Health Care Interventions. *Methods Guide for Effectiveness and Comparative Effectiveness Reviews*. Rockville (MD): Agency for Healthcare Research and Quality (US).
- Wang, L., Hermens, D. F., Hickie, I. B., & Lagopoulos, J. (2012). A systematic review of resting-state functional-MRI studies in major depression. *Journal of Affective Disorders.*, *142*(1–3), 6–12.

- Wang, Q., Poh, J. S., Wen, D. J., Broekman, B. F. P., Chong, Y. S., Yap, F., et al. (2019). Functional and structural networks of lateral and medial orbitofrontal cortex as potential neural pathways for depression in childhood. *Depression and Anxiety*, 36(4), 365–374.
- Wang, Q., Zhang, H., Poh, J. S., Pecheva, D., Broekman, B. F. P., Chong, Y. S., et al. (2020). Sex-Dependent Associations among Maternal Depressive Symptoms, Child Reward Network, and Behaviors in Early Childhood. *Cerebral cortex (New York, NY 1991)*, 30(3), 901–12.
- Wei, W., Karim, H.T., Lin, C., Mizuno, A., Andreescu, C., Karp, J.F., et al (2018) Trajectories in Cerebral Blood Flow Following Anti-depressant Treatment in Late-Life Depression: Support for the Vascular Depression Hypothesis. *The Journal of clinical psychiatry*. 79(6).
- Wei, D., Zhang, H., Broekman, BFP., Chong, Y.S., Shek, L.P., Yap, F., et al (2021) Cortical Development Mediates Association of Prenatal Maternal Depressive Symptoms and Child Reward Sensitivity: A Longitudinal Study. *Journal of the American Academy of Child and Adolescent Psychiatry*.
- Weis, S., Hausmann, M., Stoffers, B., Vohn, R., Kellermann, T., & Sturm, W. (2008). Estradiol modulates functional brain organization during the menstrual cycle: An analysis of interhemispheric inhibition. *Journal of Neuroscience*, 28(50), 13401–13410.
- Wen, D. J., Poh, J. S., Ni, S. N., Chong, Y. S., Chen, H., Kwek, K., et al. (2017). Influences of prenatal and postnatal maternal depression on amygdala volume and microstructure in young children. *Translational Psychiatry*, 7(4), e1103.
- Wesselhoeft, R., Pedersen, C. B., Mortensen, P. B., Mors, O., & Bilenberg, N. (2015). Gender-age interaction in incidence rates of childhood emotional disorders. *Psychological Medicine*, 45(4), 829–839.
- Williams, L. M., Coman, J. T., Stetz, P. C., Walker, N. C., Kozel, F. A., George, M. S., et al. (2021). Identifying response and predictive biomarkers for Transcranial magnetic stimulation outcomes: Protocol and rationale for a mechanistic study of functional neuroimaging and behavioral biomarkers in veterans with Pharmacoresistant depression. *BMC Psychiatry*, 21(1), 35.
- Won, E., Choi, S., Kang, J., Kim, A., Han, K. M., Chang, H. S., et al. (2016). Association between reduced white matter integrity in the corpus callosum and serotonin transporter gene DNA methylation in medication-naive patients with major depressive disorder. *Transl Psychiatry*, 6(8), e866-e.
- Woo, S. L., Prince, S. E., Petrella, J. R., Hellegers, C., & Doraiswamy, P. M. (2009). Modulation of a human memory circuit by subsyndromal depression in late life: A functional magnetic resonance imaging study. *The American Journal of Geriatric Psychiatry : Official Journal of the American Association for Geriatric Psychiatry*, 17(1), 24–29.
- Wu, J. C., Buchsbaum, M. S., Johnson, J. C., Hershey, T. G., Wagner, E. A., Teng, C., et al. (1993). Magnetic resonance and positron emission tomography imaging of the corpus callosum: Size, shape and metabolic rate in unipolar depression. *Journal of Affective Disorders*, 28(1), 15–25.
- Yang, X., Peng, Z., Ma, X., Meng, Y., Li, M., Zhang, J., et al. (2017). Sex differences in the clinical characteristics and brain gray matter volume alterations in unmedicated patients with major depressive disorder. *Science and Reports*, 7(1), 2515.
- Yang, Y., Wei, K., Zhang, H., Hu, H., Yan, L., Gui, W., et al. (2022). Identifying functional brain abnormalities in migraine and depression comorbidity. *Quantitative Imaging in Medicine and Surgery*, 12(4), 2288–2302.
- Yao, Z., Yan, R., Wei, M., Tang, H., Qin, J., & Lu, Q. (2014). Gender differences in brain activity and the relationship between brain activity and differences in prevalence rates between male and female major depressive disorder patients: A resting-state fMRI study. *Clinical Neurophysiology*, 125(11), 2232–2239.
- Young, K. D., Bodurka, J., & Drevets, W. C. (2017). Functional neuroimaging of sex differences in autobiographical memory recall in depression. *Psychological Medicine*, 47(15), 2640–2652.
- Zavorotnyy, M., Zöllner, R., Schulte-Güstenberg, L. R., Wulff, L., Schöning, S., Dannlowski, U., et al. (2018). Low left amygdala volume is associated with a longer duration of unipolar depression. *Journal of Neural Transmission (vienna)*, 125(2), 229–238.
- Zhang, F.-F., Peng, W., Sweeney, J. A., Jia, Z.-Y., & Gong, Q.-Y. (2018). Brain structure alterations in depression: Psychoradiological evidence. *CNS Neuroscience & Therapeutics*, 24(11), 994–1003.
- Zhang, H., Wong, T. Y., Broekman, B. F. P., Chong, Y. S., Shek, L. P., Gluckman, P. D., et al. (2021). Maternal Adverse Childhood Experience and Depression in Relation with Brain Network Development and Behaviors in Children: A Longitudinal Study. *Cerebral cortex (New York, NY 1991)*, 31(9), 4233–44.
- Zhang, X., Liang, M., Qin, W., Wan, B., Yu, C., Ming, D. (2020) Gender Differences Are Encoded Differently in the Structure and Function of the Human Brain Revealed by Multimodal MRI. *Frontiers in Human Neuroscience*. 14.
- Zhao, W., Zhu, D., Zhang, Y., Zhang, C., Zhang, B., Yang, Y., et al. (2021). Relationship between illness duration, corpus callosum changes, and sustained attention dysfunction in major depressive disorder. *Quantitative Imaging in Medicine and Surgery*, 11(7), 2980–2993.
- Zhu, Y., Gao, H., Tong, L., Li, Z., Wang, L., Zhang, C., et al (2019) Emotion Regulation of Hippocampus Using Real-Time fMRI Neurofeedback in Healthy Human. *Frontiers in Human Neuroscience*. 13.

Publisher's note Springer Nature remains neutral with regard to jurisdictional claims in published maps and institutional affiliations.

Springer Nature or its licensor (e.g. a society or other partner) holds exclusive rights to this article under a publishing agreement with the author(s) or other rightsholder(s); author self-archiving of the accepted manuscript version of this article is solely governed by the terms of such publishing agreement and applicable law.