

Obere Extremität 2021 · 16:8–15

<https://doi.org/10.1007/s11678-021-00634-z>

Received: 15 November 2020

Accepted: 28 January 2021

Published online: 4 March 2021

© The Author(s) 2021

Angelos Trellopoulos¹ · Emmanouil Brilakis^{1,2} · Emmanouil Antonogiannakis¹¹3rd Orthopaedic Department of Hygeia General Hospital, Athens, Greece²Palaio Faliro, Greece

Alternative and additive arthroscopic soft-tissue procedures for anterior shoulder instability

Subscapularis tenodesis, remplissage, and more

Introduction

The shoulder is the joint with the greatest range of motion in the human body. The mobility precedes stability, making this joint prone to dislocation or subluxation, often in the anterior direction [14]. Regarding instability, the most relevant anatomical factors are static and dynamic stabilizers of the shoulder. The term static describes the glenoid, the labrum, the rotator cuff interval, and the glenohumeral ligaments. In contrast, the rotator cuff and the muscles that support the scapula are considered the dynamic stabilizers. One of the glenoid labrum's stability properties is to serve as an attachment for the capsule and the ligaments to the glenoid and increase the depth of the concavity [20]. Shoulder dislocations predominantly occur anteriorly, leading to an anterior labral injury with or without a glenoid or humeral head bone defect. Thus, every case should be individualized. In addition to the underlying lesion(s), appropriate management should take into account the age and laxity of the patient, as well as the type and level of his/her sporting activity.

While the Bankart repair was first described in 1923 [3], the arthroscopic modification was first reported in 1993 [21]. In recent decades, this procedure was considered the gold standard for the treatment of anterior instability. Many

papers studied the recurrence of instability following a simple Bankart repair, with variation in the results from 3.4 to 33.3% in the long term. According to a literature review, the average rate obtained in 12 high-quality trials was 13.1% [15].

The reasons for failure are multifactorial. Burkhart [8] was the first to highlight the role of bone defects in the failure of the procedure. He reported a very high failure rate of 67% due to either significant bone loss from the anterior inferior glenoid or a large engaging Hill–Sachs lesion (■ Fig. 1). Bone loss, considered critical and requiring the surgeon to perform a bony procedure, is >25% [34]. Shin et al. [44] reported that the optimal critical value of glenoid bone loss was 17.3% and highlighted that the shoulder with anterior bone defects after repair leads to a posteroinferior shift of the humeral head in the abduction and external rotation (ABER) position. The current literature provides an even lower threshold of bone loss as an indication for treatment using bone graft procedures [27]. Thus, appropriate treatment indications with no severe glenoid bone loss are not well defined, especially if capsulolabral insufficiency is also considered [28].

Therefore, several soft tissue techniques have been proposed (■ Table 1) to augment the Bankart repair and im-

prove results, decreasing the recurrence rate of repair. This article summarizes the most important studies concerning these techniques and their outcomes.

Interval closure

The capsule within the rotator interval is gently abraded with a rasp or a shaver without using suction to promote the healing process. A spinal needle, preloaded with a number 1 nylon suture, is then placed percutaneously, or through an existing portal, penetrating the middle glenohumeral ligament and the capsule superior to the subscapularis tendon. The superior edge of the subscapularis tendon can be incorporated if the tissue quality is inadequate for repair. A tissue penetrator is placed through the anterosuperior portal piercing the superior glenohumeral ligament and the capsule just anterior to the edge of the supraspinatus tendon. Care should be taken to avoid incorporation of the long head of the biceps into the repair. The suture is then retrieved with the tissue penetrator and used to shuttle a high strength orthopedic suture through the capsular tissue. Both suture limbs are then delivered through the anterosuperior portal and tied using a sliding knot. Special care is taken to ensure that the inferior suture limb is passed in the subacromial space just anterior to

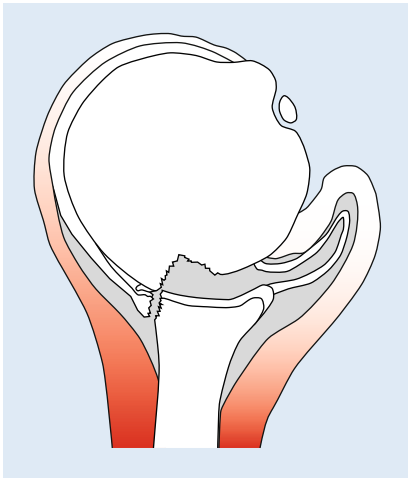


Fig. 1 ▲ Engaging Hill-Sachs lesion

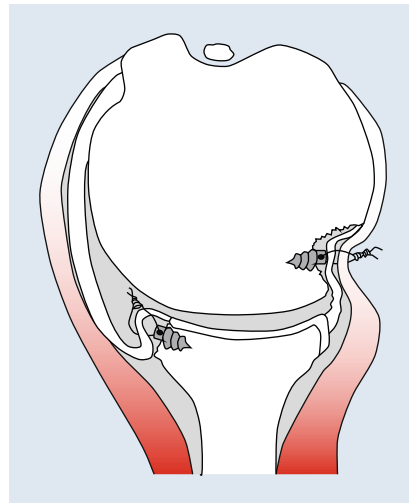


Fig. 2 ▲ Remplissage augmenting the classic Bankart repair

the capsule and underneath the deltoid muscle. If needed, additional sutures can be placed, although this maneuver is rarely necessary. Alternatively, the knot can be tied in the subacromial space under direct visualization [12].

Remplissage

In 1972, during an interractional American Academy of Orthopaedic Surgery (AAOS) course, understanding the importance of the Hill-Sachs lesions, Connolly [30] proposed an open surgical technique that transformed the humeral defect to extraarticular, transferring the infraspinatus and part of the greater tuberosity into the lesion (■ Fig. 2). An arthroscopic modification termed “remplissage” was first described in 2008 by Purchase et al. [41]. This involved a capsulodesis of the posterior capsule combined with the myotenodesis of the infraspinatus to the humeral defect (■ Fig. 3), which made the lesion non-engaged to the glenoid rim [34, 32].

Remplissage, a French word meaning “fill-in,” comes to fill the grey zone of the treatment of anterior instability with glenoid bone defects of less than 25%, combined with off-track Hill-Sachs lesions [34]. The classic remplissage, or any modification of this procedure [31], is principally introduced as one or more anchors placed in the humeral head defect. The sutures are passed through the

posterior capsule and tendon of the infraspinatus and then tied, holding the soft tissues inside the Hill-Sachs lesion.

Remplissage is the first arthroscopic procedure that specifically aimed to treat the Hill-Sachs lesion. Park et al. [39] evaluated patients that had undergone arthroscopic remplissage for recurrent glenohumeral instability and characterized the postoperative appearance of the remplissage on high-resolution magnetic resonance imaging (MRI). The average follow-up was 18 months (range 8.8–27.2 months), concluding that the range of deformity filled in with tendon fluctuated from 75% to 100%, and there was 0–25% muscle atrophy for all patients studied.

The biomechanical properties of remplissage were estimated using several cadaveric studies. In 2012, Giles et al. [25] compared three different treatment strategies (remplissage, humeral head allograft, and partial resurfacing arthroplasty) for Hill-Sachs defect sizes of 30% and 45%. They proved that remplissage is an effective procedure for preventing engagement and dislocation in defects of such dimensions. In another analysis by Elkinson et al. [22], eight cadaveric shoulders with 15% and 30% Hill-Sachs defects were tested. They performed the Bankart repair, with and without remplissage, and measured the outcomes. They found that 15% of lesions could be treated successfully with the Bankart

repair alone. However, 30% of the lesions had engagement and dislocations, with a significant reduction after the combination of remplissage and the Bankart repair. Argintar et al. [2] tested six different conditions: intact, Bankart lesion, Bankart with 40% Hill-Sachs lesion, Bankart repair, remplissage, and Bankart repair with remplissage. They found that remplissage did not increase translational stability, but remplissage combined with Bankart repair decreased humeral translation. Additionally, a change in the shoulder’s kinematics after the procedure revealed that remplissage might lead to glenohumeral arthritis; however, more clinical studies are needed to investigate this condition. Finally, it was concluded that remplissage alongside the Bankart repair prevented re-engagement of the humeral defect. Moreover, the range of motion of the shoulder with Hill-Sachs lesions remained uncompromised.

In another cadaveric study [29] based on the glenoid track concept, bipolar bone loss models with either on-track (15%) or off-track (30%) Hill-Sachs lesions were tested for whether they could be stabilized with the Bankart repair, with or without remplissage. The authors provoked the engagement during translational force to one shoulder with a 15% defect, while they provoked the engagement in all eight shoulders with 30%. The Bankart repair alone prevented engagement in the shoulder with a 15% Hill-Sachs lesion, and in all eight specimens, there was a continued engagement at 90 degrees of the external rotation. Remplissage, on the other hand, prevented engagement after the translational test to all 30% of humeral lesions. The study concluded that Bankart, combined with remplissage, caused a necessary stiffness to the shoulder that, in turn, prevented instability.

The first case of loss of external rotation was described by Deutsch and Kroll [17] in 2008. In their report, they demonstrated a patient with significant loss of external rotation after the remplissage procedure. As a treatment option, the authors decided to make an arthroscopic release of the infraspinatus tenodesis. It was proposed that the tenodesis of the infraspinatus and posterior capsule lim-

ited the shoulder motion through mechanical blocking. In a large case series (45 patients), with follow-up ranging from 2 years to 10 years, Wolf et al. [46] evaluated the outcomes of arthroscopic remplissage combined with Bankart repair in patients with recurrent anterior shoulder instability and Bigliani grade IIIA (glenoid deficiency < 25%). No significant loss of external rotation was observed. Similar results were reported by Cho et al. [11]. This study reported a limitation in external rotation of 8 degrees in the remplissage group, a functional score with no clinical value. Also, Lazarides et al. [33], in a systematic review of clinical and biomechanical studies, showed a decrease in postoperative range of motion without clinically significant outcomes. A systematic review [1] based on Level II and III studies analyzed the results of seven biomechanical and six clinical studies. Biomechanical studies have reported that the combination of Bankart with remplissage prevents engagement of the Hill–Sachs lesion, with a cost in stiffness and range of motion. Furthermore, these studies highlighted a clear loss in external rotation, while clinical studies reported a smaller amount of loss with no major impact on the clinical motion or statistical significance. It becomes clear that the loss of external rotation after the procedure is not clinically important, and the difference in range of motion between the cadaveric and clinical studies is probably from the need of the patient to perform the external rotation in his daily living that forces him to use different movement patterns, like the motion of the scapula.

Clinically, several studies have introduced the role of remplissage in the treatment of Hill–Sachs lesions. Longo et al. [35] evaluated the clinical outcomes, rate of recurrence, complications, and range of motion after all the procedures (open or arthroscopic) used for treating anterior or posterior shoulder instability associated with humeral bone loss. They concluded that remplissage has the lowest rate of recurrence and is the safest technique. In 2011, Park et al. [40] presented 20 patients with recurrent anterior glenohumeral instability and large Hill–Sachs defects. The author reported that after

Obere Extremität 2021 · 16:8–15 <https://doi.org/10.1007/s11678-021-00634-z>
© The Author(s) 2021

A. Trellopoulos · E. Brilakis · E. Antonogiannakis

Alternative and additive arthroscopic soft-tissue procedures for anterior shoulder instability. Subscapularis tenodesis, remplissage, and more

Abstract

Anterior glenohumeral instability is a widespread pathological condition, not only in athletes but also in the general population. The variations in the lesions (soft tissue and bone defects) that occur after traumatic dislocation or recurrence, combined with the degree of ligamentous laxity and activity, have led to numerous surgical techniques. Following the introduction of arthroscopy in the treatment of shoulder pathology, several new procedures and modifications of old methods were introduced to treat anterior instability. Despite this, there is still controversy regarding the proper management of instability cases combined with bone loss or insufficient anterior soft

tissue wall or laxity. Additional soft tissue procedures, along with the simple Bankart repair, strengthen the stability of the repair and can fill the gap in the transition from the classic Bankart repair to the potential overtreatment of bony procedures. This literature review attempts to summarize all the critical studies referring to soft tissue techniques and highlight the most crucial points of their conclusions.

Keywords

Anterior dislocation · Bankart repair · Augmentation · Subscapularis tenodesis · Remplissage

Alternative und additive arthroskopische Weichteileingriffe bei vorderer Schulterinstabilität. Subscapularistenodese, Remplissage und weitere Verfahren

Zusammenfassung

Die anteriore Schulterinstabilität ist ein häufiger pathologischer Zustand nicht nur bei Sportlern, sondern auch in der Allgemeinbevölkerung. Die verschiedenen möglichen Läsionen (Weichteil- und Knochendefekte) nach erstmaliger oder rezidivierter traumatischer Luxation haben zusammen mit dem Ausmaß der Bandinstabilität und der Patientenaktivität zur Entwicklung diverser operativer Techniken geführt. Nach Etablierung der Arthroskopie in der Schulterchirurgie wurden einige neue Ansätze sowie Modifikationen bekannter Techniken für die Behandlung der vorderen Schulterinstabilität entwickelt. Es besteht jedoch keine einheitliche Meinung zur besten operativen Therapie der Schulterinstabilität, insbesondere bei zusätzlichen knöchernen Defekten, nicht ausreichender vorderer

Weichteilschicht oder bei Laxität. Die Kombination verschiedener Weichteileingriffe mit einer Labrumrekonstruktion kann durch additive Effekte die wiederhergestellte Gelenkstabilität verbessern. Dieses Verfahren ist eine Alternative zwischen klassischem Bankart-Repair und potenzieller Übertherapie mit knöchernen Rekonstruktionen. In diesem Übersichtsbeitrag sollen alle wesentlichen Studien über mögliche additive Weichteileingriffe zusammengefasst und die Kernaussagen für die klinische Praxis erläutert werden.

Schlüsselwörter

Anteriore Schulterluxation · Bankart-Repair · Augmentation · Subscapularistenodese · Remplissage

the operations, the patients had restored function, the pain was reduced, and they had a high satisfaction rate. From 2005 to 2009, Boileau et al. [5] performed 459 operations on patients with traumatic recurrent anterior shoulder instability. A total of 47 patients (10.2%) underwent remplissage combined with the Bankart repair to address engaging large Hill–Sachs

lesions (Calandra grade III) without significant bone defect. The mean instability severity index (ISIS) score was 3.8 (range 3–6). This study raised three hypotheses: a) There was a healing of the capsulodesis in the humeral defect without any significant effect on postoperative shoulder motion; b) the total number of the athletes operated on returning to the

Table 1 Arthroscopic soft-tissue procedures for anterior shoulder instability, used to augment Bankart repair

Additional procedures to the classic Bankart repair at a glance	Description
Interval closure	Closure of the rotator interval with sutures
Remplissage	Posterior capsulodesis combined with myotendosis of the infraspinatus within the humeral head defect
Arthroscopic subscapularis augmentation (ASA)	Tenodesis of the upper third of the subscapularis tendon on the top of the Bankart repair
Dynamic anterior stabilization (DAS)	Long head of biceps tendon transfer to the anterior glenoid through the subscapularis tendon creating a sling effect
Between glenohumeral ligaments and subscapularis tendon (BLS)	A sliver of the subscapularis tendon together with the capsule between the glenohumeral ligaments and the subscapularis tendon is tied on the top of the classic Bankart repair
Tenodesis of the posterior portion of the superior half of the subscapularis to the anterior part of the glenoid	The title fully describes the technique
Transfer of conjoint tendon without the use of coracoid in the anterior part of the glenoid	The title fully describes the technique
Bankart-Plus	An allogenic spongy bone matrix is inserted between the glenoid neck and the labrum

pre-injury level of the sport; and c) there was a positive correlation between the improvement of healing and shoulder stability after the surgery. All of these hypotheses were confirmed. Also, there was postoperative evidence of capsule healing, the defect of the infraspinatus tendon was detected in 31 (74%) patients that underwent postoperative MRI, and there were only two with a filling < 50%. After the surgery, 90% of the patients returned to their pre-injury level of athletic activity. Only a slight restriction in external rotation occurred (approximately 10 degrees) compared to the contralateral side. One of the most important conclusions of the study was that remplissage achieves stability by affecting the humeral translation and not the rotation.

Several studies compare the outcome of the Bankart repair alone and that in combination with the remplissage. Franceschi et al. [23] studied 50 patients and split them into two groups. In the first group (remplissage and Bankart repair), no instability recurrence was reported, while in the second (Bankart repair alone), there were five patients with recurrent instability (20%). Garcia et al. [24] found that the failure rate was even higher for the patients with a large engaging Hill-Sachs lesion, treated by

isolated Bankart repair (57%), while the patients treated with remplissage and Bankart repair had a 20% failure rate.

Similar results were presented in a meta-analysis by Camus et al. [9]. In all, 145 patients from three different studies underwent anterior instability surgery, 74 had isolated Bankart repairs, and 72 had Bankart and remplissage. The recurrence rate was 14.8% in the Bankart group and 1.4% in the combination group. More specifically, the risk of re-dislocation and recurrent instability was 4- to 4.5-fold higher in the Bankart group, with a predisposition to more revision surgeries.

In a long-term follow-up (8 years) case series established by Brilakis et al. [6], 65 patients underwent arthroscopic remplissage combined with Bankart repair for recurrent anterior shoulder instability, without inverted pear appearance of the glenoid during arthroscopy. Three of these experienced a new dislocation of 5.6%, but the majority of the patients were satisfied with the postoperative result (94.4%). Post-procedure, most patients returned to their daily activities, and a significant percent (71%) participated in sports. There was an improvement in all functional scores, and no

clinically significant restriction in range of motion was documented.

Bastard et al. [4], in a retrospective comparative study of 10 years of follow-up compared two groups of patients, group B, with 39 patients that underwent Bankart repair, and group BR, with 28 patients treated with a combination of Bankart repair and remplissage. The BR group had no recurrence or apprehension compared to group B, which had three patients (8%) that experienced a new dislocation.

Domos et al. [19] examined the impact of primary and recurrent anterior dislocation of the shoulder in collision athletes with non-engaging Hill-Sachs lesions and bone loss of < 20%. Two patient groups were formed, one consisting of 20 athletes that underwent the Bankart-remplissage combination, and a second consisting of 20 athletes that underwent only Bankart repair. The recurrence rate was 5% for the combination group and 30% for the Bankart repair group, with one patient from the first group and seven from the second needing reoperation. There was an external rotation deficit of 10 degrees with no clinical effects on the outcome.

In summary, remplissage has several advantages, such that it comes with no major complications and is the only arthroscopic procedure used to fill the humeral head defect. The recovery period is short, and the complications described are minimal and easily managed. Postoperative range of motion, pain, and potential arthritis from this non-anatomic procedure have been reported. Moreover, the procedure is not indicated for patients with insufficiency of the anterior capsular soft tissues [18].

As far as the authors' perspective is concerned, they concluded that remplissage combined with Bankart is a safe and effective procedure for treating bipolar engaging Hill-Sachs lesions without inverted pear appearance of the glenoid (major bone loss defect < 25).

Arthroscopic subscapularis augmentation (ASA; ■ Fig. 4)

In 2013, Chaudhury et al. [10] presented two cases with recurrent anterior instabil-

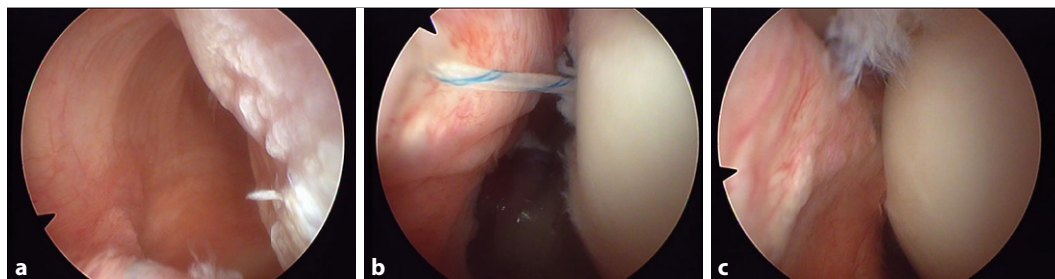


Fig. 3 ▲ **a** Arthroscopic view of the Hill–Sachs lesion. The distance between the humeral defect and the posterior capsule is clearly depicted. **b** The sutures of one or two anchors, implanted in the humeral bone defect, are passed through the posterior capsule and the infraspinatus tendon in a mattress configuration. **c** After knot tying, firm contact between the capsule–tendon complex and the humeral head is created

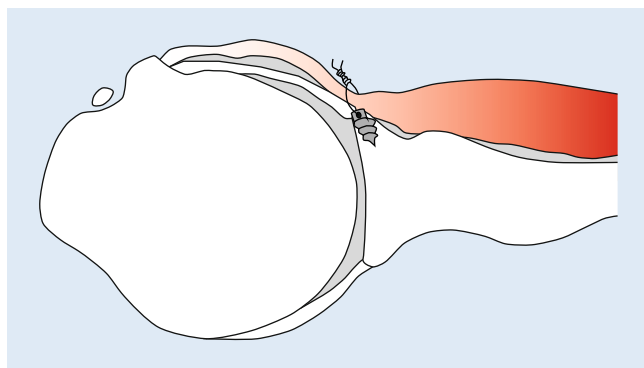


Fig. 4 ◀ Arthroscopic subscapularis augmentation

ity and prior stabilization surgery treated with a subscapularis tenodesis technique. This method was selected as a salvage procedure for highly demanding instability cases. Three anchors were placed into the anterior glenoid, and their sutures were passed through the capsule and subscapularis tendon using a penetrating device. The subscapularis tendon and stitches were tied like a mattress, resulting in complete tenodesis of the tendon onto the anterior glenoid rim. Both patients that underwent the procedure presented with an excellent range of motion, no translation instability, and returned to their pre-injury level of activity. The authors concluded that the described technique is ideal for patients with recurrent instability and insufficiency in the soft tissues of the anterior part of the glenoid rim with no bone defect. In the authors' opinion, this tenodesis is ideal for revision cases with poor soft tissue quality and no bone loss and for athletes that do not participate in contact sports.

A therapeutic case series by Maiotti et al. [36] presented short-term outcomes from an almost identically described technique. The ASA consisted

of tenodesis of the upper third of the subscapularis on top of a Bankart repair (► Fig. 5). The indications for patient selection were a history of traumatic recurrence in athletes that participated in contact sports, glenoid bone loss of <25%, and insufficiency of the shoulder's anterior soft tissue. A total of 110 patients participated in the study, 98 of which had a Hill–Sachs lesion and 57 an anterior capsular deficiency. Three patients (2.7%) suffered from re-dislocation. The reported loss of external rotation was 8 ± 2.5 degrees with the arm in the neutral position, and 4 ± 1.5 degrees in 90 degrees of abduction. The authors concluded that their procedure effectively restores stability in patients with recurrent traumatic instability, participation in contact sports, glenoid lesions of <25%, and anterior capsular defects with restriction in external rotation.

A cadaver biomechanical study by Schröter et al. [43] investigated the role of the ASA technique in instability and range of motion. This study tested the method's stability on translation and rotation to specimens with Bankart lesions combined with a glenoid bone

defect and compared the result with the Bankart repair. The results showed that ASA affected stability in abduction and external rotation, with variations in external rotation range. Furthermore, the procedure showed promise in the prevention of dislocations in shoulders with bone lesions. On the other hand, the joint translation was similar between ASA and physiological shoulders, with no statistically significant difference. The technique significantly increased the stability of the anterior and anteroinferior directions of the arm in abduction and external rotation in shoulders with Bankart lesions. The study highlighted the potential sling effect of the procedure, similar to that of the Bristow–Latarjet. The authors could not confirm their hypothesis that the external rotation deficit was less than 10 degrees. Russo et al. [42] investigated Latarjet versus ASA combined with Bankart repair to treat chronic shoulder instability with moderate glenoid bone loss. The study presented short-term results from two groups of patients. In group A, 20 patients underwent open Latarjet, while 20 patients in group B were treated with ASA and Bankart. No complications from either group were presented. In addition, no statistically significant difference was observed between the two groups. The deficit in external rotation with the arm at the side of the trunk was -9 degrees in group A and -8 degrees in group B, while with the arm in 90 degrees of abduction it was -5 degrees in both groups. The study reported no differences in the treatment of recurrent shoulder instability with bone loss of <25% for either technique. The authors

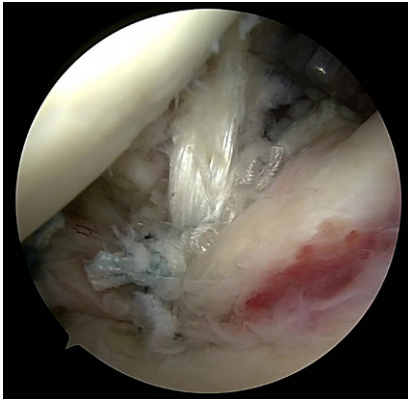


Fig. 5 ▲ Arthroscopic subscapularis augmentation of Bankart repair. One anchor is implanted in the anterior part of the glenoid (around 9 o'clock), and the sutures are passed through the upper part of the subscapularis tendon. After tying them, the upper part of the subscapularis, fixated on the glenoid, pulls back the humeral head, especially when the arm is rotated externally

considered Latarjet as overtreatment for patients with recurrent instability and moderate bone loss compared to ASA.

The ASA procedure is an effective technique for patients that suffer from recurrent instability, anterior soft tissue insufficiency, and glenoid lesions less than 25%. Extra caution must be taken to avoid restriction in range of motion. However, this technique is not very popular due to the fact that long-term results are needed to prove this technique's efficacy. The low re-dislocation rate in the short-term results needs to be confirmed for long-term outcomes.

Dynamic anterior stabilization

Collin and Lädermann [13] presented dynamic anterior stabilization (DAS) to treat anterior shoulder instability by transferring the long head of the biceps to the anterior glenoid rim, creating the sling effect. The paper highlighted the procedure's indications, which included anteroinferior glenohumeral instability with a glenoid bone defect of less than 20%, and that it is ideal for patients with superior labral anterior posterior (SLAP) lesions and those participating in overhead sports. As mentioned above, the technique's biomechanical concept is similar to the Latarjet procedure, producing a sling effect that prevents an-

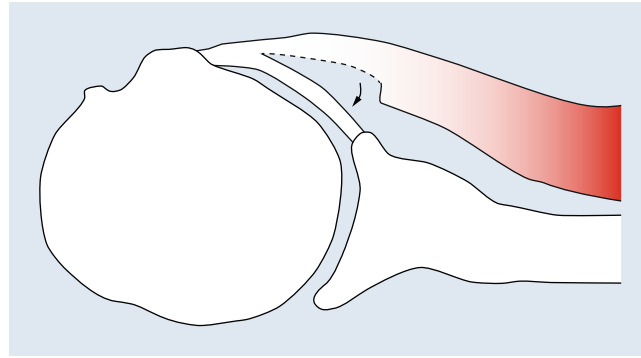


Fig. 6 ◀ Bankart augmentation using a flap from the posterior portion of the superior half of the subscapularis tendon

terior instability, especially in the at-risk position of abduction and external rotation. Various investigators have shown the benefits of the sling effect's working mechanics and the fact that it does not affect the range of motion for external and internal rotation [26]. Based on this speculation, the authors concluded that the main benefit of the DAS technique is that it provides the sling effect and is simultaneously a comfortable and safe technique without major complications, especially compared to the Latarjet procedure. Mehl et al. [37] designed a cadaveric study to investigate the effects on stability and biomechanically compare the DAS and Bankart repairs. The authors reported that the DAS procedure decreased anterior translation of the humerus into the glenoid with small bone defects. This decrease is significant compared to the simple Bankart repairs to shoulders with 10% and 20% glenoid bone defects. When treated with DAS, in cases with >20% bone lesions, a posterior and inferior shift of the humeral head in the ABER position is present. Studies that describe this technique's clinical outcome are needed to prove that this creative idea can offer a low re-dislocation rate in the long term.

Other described techniques

Brzóška et al. [7] described a modification of the Bankart technique. They named it "between glenohumeral ligaments and subscapularis tendon" (BLS). According to the authors, this procedure is indicated in patients with anterior instability and insufficiency of the anterior soft tissue wall, without major bone loss (<20%). The procedure

requires careful separation of the capsule from the subscapularis tendon. This sliver of the subscapularis is separated together with the capsule to augment the repair. The sutures from two double-loaded anchors must pass from outside-to-inside through the subscapularis pouch, the anterior capsule, and glenohumeral ligaments. Then the sutures are tied mattress with their knots remaining extracapsular. According to the authors, this procedure restores the original capsulolabral footprint without impacting external rotation loss.

In total, 100 patients underwent the procedure; their clinical condition was anterior shoulder instability with anterior soft tissue insufficiency without major glenoid bone defects (<20%). The authors separated the patients into four groups according to their anterior glenoid bone loss (<5%, 6–10%, 11–15%, >15%). After a mean follow-up of 82.9 months, 86 (86%) had a favorable clinical outcome, while post-operatively, 14 patients (14%) suffered a new dislocation. As expected, there was a correlation between the clinical outcomes after the operation and the glenoid bone loss. Thus, patients with recurrence instability had a medium bone loss of 11–15%, while those with positive clinical outcomes had 6–10%. Finally, the authors concluded that the BLS procedure is an effective technique for treating patients with anterior shoulder instability and glenoid bone loss of <11%.

Denard et al. [16] understood the clinical gap in treating anterior shoulder instability with a capsulolabral deficiency without significant glenoid bone loss. They published a technical note with a new technique based on arthro-

scopical immobilization of a flap from the posterior portion of the superior half of the subscapularis tendon using electrocautery (■ Fig. 6). After immobilization, this flap works in a “trapdoor” fashion, and as a separate lamina, it undergoes tenodesis to the anterior glenoid. This technique provides anterior coverage and containment by augmenting part of the subscapularis to the classic Bankart procedure.

For the authors, the indication for this procedure was revision surgery after multiple instability procedures and deficiency of the anterior soft tissue wall without significant bone loss. At the same time, one of the contraindications was engaging lesions.

Tennent et al. [45] proposed a transfer of the conjoint tendon to the anterior glenoid without the use of coracoid for patients with recurrent instability and significant glenoid bone loss (<15%). This technique maintains the benefit of the sling effect, as described by Latarjet. This operation cannot eliminate the risk of traction and injury of the musculocutaneous nerve, but can minimize the need to exteriorize the coracoid tip. Finally, this procedure avoids intraarticular damage from prominent screws or mispositioning of the coracoid.

Finally, a procedure that cannot be characterized as a pure bony procedure is called Bankart-Plus and described by Moroder et al. [38]. According to the authors, this procedure is indicated to treat anterior shoulder instability with small to intermediate bony glenoid defects. In addition to the conventional capsulolabral repair, an allogeneic demineralized spongy bone matrix is inserted between the glenoid neck and the labrum to compensate for the glenoid bone loss by increasing the volume of the labrum and thus its stabilizing effect.

Conclusion

In recent years, several studies have demonstrated an unacceptable long-term recurrence rate when the classic Bankart repair is used alone for the management of cases with glenoid bone loss <25%. This is the reason for using additional techniques to lower the

failure rates and to individualize the treatment, considering not only the type of the lesions and the percentage of the bone defects, but also other factors such as, e.g., age, ligamentous laxity, gender, overhead activity, and level of sport participation. This makes the definition of an algorithm for selecting the appropriate technique, and especially for choosing between the use of a soft-tissue or a bony procedure, an important issue. The reported studies showed promising results for the alternative and additive arthroscopic soft-tissue procedures. Nevertheless, the treatment of anterior shoulder instability with glenoid bone loss of <25% is still controversial. This creates the need for more studies with longer-term follow-ups, greater patient numbers, and prospective in character.

Corresponding address

Emmanouil Brilakis, MD, MSc, PhD

2 Str. Alkionis, 175 61 Palaio Faliro, Athens, Greece

Emmanuel.Brilakis@gmail.com

Compliance with ethical guidelines

Conflict of interest. E. Brilakis, A. Trellopoulos, and E. Antonogiannakis declare that they have no competing interests.

For this article no studies with human participants or animals were performed by any of the authors. All studies mentioned were in accordance with the ethical standards indicated in each case.

Open Access. This article is licensed under a Creative Commons Attribution 4.0 International License, which permits use, sharing, adaptation, distribution and reproduction in any medium or format, as long as you give appropriate credit to the original author(s) and the source, provide a link to the Creative Commons licence, and indicate if changes were made. The images or other third party material in this article are included in the article's Creative Commons licence, unless indicated otherwise in a credit line to the material. If material is not included in the article's Creative Commons licence and your intended use is not permitted by statutory regulation or exceeds the permitted use, you will need to obtain permission directly from the copyright holder. To view a copy of this licence, visit <http://creativecommons.org/licenses/by/4.0/>.

References

1. Alkadumi H, Verweij LPE, Willigenburg NW, van Deurzen DFP, van den Bekerom MPJ (2019)

- Remplissage with Bankart repair in anterior shoulder instability: a systematic review of the clinical and cadaveric literature. *Arthroscopy* 35(4):1257–1266
2. Argintar E, Heckmann N, Wang L, Tibone JE, Lee TQ (2016) The biomechanical effect of shoulder remplissage combined with Bankart repair for the treatment of engaging Hill-Sachs lesions. *Knee Surg Sports Traumatol Arthrosc* 24(2):585–592
3. Bankart AS (1923) Recurrent or habitual dislocation of the shoulder joint. *Br Med J* 2(3285):1132–1133
4. Bastard C, Herisson O, Gaillard J, Nourissat G (2019) Impact of remplissage on global shoulder outcome: a long-term comparative study. *Arthroscopy* 35(5):1362–1367
5. Boileau P, O'Shea K, Vargas P, Pinedo M, Old J, Zumstein M (2012) Anatomical and functional results after arthroscopic Hill-Sachs remplissage. *J Bone Joint Surg Am* 94(7):618–626
6. Brilakis E, Avramidis G, Malahias MA, Stathellis A, Deligeorgis A, Chiotis I, Mataragas E, Chronopoulos E, Antonogiannakis E (2019) Long-term outcome of arthroscopic remplissage in addition to the classic Bankart repair for the management of recurrent anterior shoulder instability with engaging Hill-Sachs lesions. *Knee Surg Sports Traumatol Arthrosc* 27(1):305–313
7. Brzóska R, Laprus H, Michniowski P, Solecki W, Klön W, Błasiak A (2019) Novel and effective arthroscopic extracapsular stabilization technique for anterior shoulder instability-BLS. *Knee Surg Sports Traumatol Arthrosc* 27(12):3897–3904
8. Burkhart SS, De Beer JF (2000) Traumatic glenohumeral bone defects and their relationship to failure of arthroscopic Bankart repairs: significance of the inverted-pear glenoid and the humeral engaging Hill-Sachs lesion. *Arthroscopy* 16(7):677–694
9. Camus D, Doms P, Berard E, Toulemonde J, Mansat P, Bonneville N (2018) Isolated arthroscopic Bankart repair vs. Bankart repair with “remplissage” for anterior shoulder instability with engaging Hill-Sachs lesion: a meta-analysis. *Orthop Traumatol Surg Res* 104(6):803–809
10. Chaudhury S, Delos D, Dines JS, Altchek DW, Dodson CC, Newman AM, O'Brien SJ (2014) Arthroscopic subscapularis bankart technique as a salvage procedure for failed anterior shoulder stabilization. *HSS J* 10(1):73–78
11. Cho NS, Yoo JH, Juh HS, Rhee YG (2016) Anterior shoulder instability with engaging Hill-Sachs defects: a comparison of arthroscopic Bankart repair with and without posterior capsulodesis. *Knee Surg Sports Traumatol Arthrosc* 24(12):3801–3808
12. Cole BJ, Mazzocca AD, Meneghini RM (2003) Indirect arthroscopic rotator interval repair. *Arthroscopy* 19(6):E28–E31
13. Collin P, Lädermann A (2018) Dynamic anterior stabilization using the long head of the biceps for anteroinferior glenohumeral instability. *Arthrosc Tech* 7(1):e39–e44
14. Cutts S, Prempeh M, Drew S (2009) Anterior shoulder dislocation. *Ann R Coll Surg Engl* 91(1):2–7
15. DeFroda S, Bokshan S, Stern E, Sullivan K, Owens BD (2017) Arthroscopic Bankart repair for the management of anterior shoulder instability: indications and outcomes. *Curr Rev Musculoskelet Med* 10(4):442–451
16. Denard PJ, Narbona P, Lädermann A, Burkhart SS (2011) Bankart augmentation for capsulolabral deficiency using a split subscapularis tendon flap. *Arthroscopy* 27(8):1135–1141

17. Deutsch AA, Kroll DG (2008) Decreased range of motion following arthroscopic remplissage. *Orthopedics* 31(5):492
18. Di Giacomo G, Itoi E, Burkhart SS (2014) Evolving concept of bipolar bone loss and the Hill-Sachs lesion: from “engaging/non-engaging” lesion to “on-track/off-track” lesion. *Arthroscopy* 30(1):90–98
19. Domos P, Ascione F, Wallace AL (2019) Arthroscopic Bankart repair with remplissage for non-engaging Hill-Sachs lesion in professional collision athletes. *Shoulder Elbow* 11(1):17–25
20. Dumont GD, Russell RD, Robertson WJ (2011) Anterior shoulder instability: a review of pathoanatomy, diagnosis, and treatment. *Curr Rev Musculoskelet Med* 4(4):200–207
21. el Akad AM, Winge S, Molinari M, Eriksson E (1993) Arthroscopic Bankart procedures for anterior shoulder instability. A review of the literature. *Knee Surg Sports Traumatol Arthrosc* 1(2):113–122
22. Elkinson I, Giles JW, Faber KJ, Boons HW, Ferreira LM, Johnson JA et al (2012) The effect of the remplissage procedure on shoulder stability and range of motion: an in vitro biomechanical assessment. *J Bone Joint Surg Am* 94(11):1003–1012
23. Franceschi F, Papalia R, Rizzello G, Franceschetti E, Del Buono A, Panasci M et al (2012) Remplissage repair—new frontiers in the prevention of recurrent shoulder instability: a 2-year follow-up comparative study. *Am J Sports Med* 40(11):2462–2469
24. Garcia GH, Park MJ, Zhang C, Kelly JD 4th, Huffman GR (2015) Large Hill-Sachs lesion: a comparative study of patients treated with arthroscopic Bankart repair with or without remplissage. *HSSJ* 11(2):98–103
25. Giles JW, Boons HW, Elkinson I, Faber KJ, Ferreira LM, Johnson JA et al (2013) Does the dynamic sling effect of the Latarjet procedure improve shoulder stability? A biomechanical evaluation. *J Shoulder Elbow Surg* 22(6):821–827
26. Giles JW, Elkinson I, Ferreira LM, Faber KJ, Boons H, Litchfield R et al (2012) Moderate to large engaging Hill-Sachs defects: an in vitro biomechanical comparison of the remplissage procedure, allograft humeral head reconstruction, and partial resurfacing arthroplasty. *J Shoulder Elbow Surg* 21(9):1142–1151
27. Gottschalk LJ, Bois AJ, Shelby MA, Miniaci A, Jones MH (2017) Mean glenoid defect size and location associated with anterior shoulder instability: a systematic review. *Orthop J Sports Med* 5(1):2325967116676269
28. Habermeyer P, Gleyze P, Rickert M (1999) Evolution of lesions of the labrum-ligament complex in posttraumatic anterior shoulder instability: a prospective study. *J Shoulder Elbow Surg* 8(1):66–74
29. Hartzler RU, Bui CN, Jeong WK, Akeda M, Peterson A, McGarry M, Denard PJ, Burkhart SS, Lee TQ (2016) Remplissage of an off-track Hill-Sachs lesion is necessary to restore biomechanical glenohumeral joint stability in a bipolar bone loss model. *Arthroscopy* 32(12):2466–2476
30. Connolly J (1972) Humeral head defects associated with shoulder dislocation: their diagnostic and surgical significance. *AAOS Instr Course Lect* 21:42–54
31. Koo SS, Burkhart SS, Ochoa E (2009) Arthroscopic double-pulley remplissage technique for engaging Hill-Sachs lesions in anterior shoulder instability repairs. *Arthroscopy* 25(11):1343–1348
32. Lädemann A, Arrigoni P, Barth J, Narbona P, Hanyasiak B, Burkhart SS, Denard PJ (2016) Is arthroscopic remplissage a tenodesis or capsulomyodesis? An anatomic study. *Knee Surg Sports Traumatol Arthrosc* 24(2):573–577
33. Lazarides AL, Duchman KR, Ledbetter L, Riboh JC, Garrigues GE (2019) Arthroscopic remplissage for anterior shoulder instability: a systematic review of clinical and biomechanical studies. *Arthroscopy* 35(2):617–628
34. Lo IK, Parten PM, Burkhart SS (2004) The inverted pear glenoid: an indicator of significant glenoid bone loss. *Arthroscopy* 20(2):169–174
35. Longo UG, Loppini M, Rizzello G, Ciuffreda M, Berton A, Maffulli N, Denaro V (2014) Remplissage, humeral osteochondral grafts, weber osteotomy, and shoulder arthroplasty for the management of humeral bone defects in shoulder instability: systematic review and quantitative synthesis of the literature. *Arthroscopy* 30(12):1650–1666
36. Maiotti M, Massoni C, Russo R, Schroter S, Zanini A, Bianchedi D (2017) Arthroscopic subscapularis augmentation of Bankart repair in chronic anterior shoulder instability with bone loss less than 25% and capsular deficiency: clinical multicenter study. *Arthroscopy* 33(5):902–909
37. Mehl J, Otto A, Imhoff FB, Murphy M, Dyrna F, Obopilwe E et al (2019) Dynamic anterior shoulder stabilization with the long head of the biceps tendon: a biomechanical study. *Am J Sports Med* 47(6):1441–1450
38. Moroder P, Böhm E, Scheibel M (2018) The arthroscopic Bankart-plus procedure for treatment of anterior shoulder instability with small to intermediate glenoid defects. *Arthrosc Tech* 7(4):e379–e384
39. Park MJ, Garcia G, Malhotra A, Major N, Tjoumakaris FP, Kelly JD 4th (2012) The evaluation of arthroscopic remplissage by high-resolution magnetic resonance imaging. *Am J Sports Med* 40(10):2331–2336
40. Park MJ, Tjoumakaris FP, Garcia G, Patel A, Kelly JD 4th (2011) Arthroscopic remplissage with Bankart repair for the treatment of glenohumeral instability with Hill-Sachs defects. *Arthroscopy* 27(9):1187–1194
41. Purchase RJ, Wolf EM, Hobgood ER, Pollock ME, Smalley CC (2008) Hill-Sachs “remplissage”: an arthroscopic solution for the engaging hill-sachs lesion. *Arthroscopy* 24(6):723–726
42. Russo R, Della Rotonda G, Cautiero F, Ciccarelli M, Maiotti M, Massoni C et al (2017) Arthroscopic Bankart repair associated with subscapularis augmentation (ASA) versus open Latarjet to treat recurrent anterior shoulder instability with moderate glenoid bone loss: clinical comparison of two series. *Musculoskelet Surg* 101(1):75–83
43. Schröter S, Krämer M, Welke B, Hurschler C, Russo R, Herbst M et al (2016) The effect of the arthroscopic augmentation of the subscapularis tendon on shoulder instability and range of motion: a biomechanical study. *Clin Biomech* 38:75–83
44. Shin SJ, Kim RG, Jeon YS, Kwon TH (2017) Critical value of anterior glenoid bone loss that leads to recurrent glenohumeral instability after arthroscopic Bankart repair. *Am J Sports Med* 45(9):1975–1981
45. Tennent D, Colaço HB, Arnander M, Pearse E (2016) Arthroscopic conjoint tendon transfer: a technique for revision anterior shoulder stabilization. *Arthrosc Tech* 5(1):e201–e205
46. Wolf EM, Arianjam A (2014) Hill-Sachs remplissage, an arthroscopic solution for the engaging Hill-Sachs lesion: 2- to 10-year follow-up and incidence of recurrence. *J Shoulder Elbow Surg* 23(6):814–820