CLINICAL PRACTICE
Clinical Vignettes

A Case of Chronic Lymphocytic Leukemia Complicated by Hemophagocytic Lymphohistiocytosis: Identifying the Aberrant Immune Response

Adi Zoref-Lorenz[1,2,3,4], *Mona Yuklea*[1,2], *Guy Topaz*[2,5], *Michael B. Jordan*[3,4], *and Martin Ellis*[1,2]

[1]Hematology Institute, Meir Medical Center, Kfar Saba, Israel; [2]Sackler School of Medicine, Tel Aviv University, Tel Aviv, Israel; [3]Division of Immunobiology, Cincinnati Children's Hospital Medical Center, Cincinnati, OH, USA; [4]Division of Bone Marrow Transplantation and Immune Deficiency, Cancer and Blood Diseases Institute, Cincinnati Children's Hospital Medical Center, 3333 Burnet Ave, Cincinnati, OH, USA; [5]Department of Internal Medicine C, Meir Medical Center, Kfar Saba, Israel.

Hemophagocytic lymphohistiocytosis (HLH) is a life-threatening hyperinflammatory syndrome that may complicate hematologic malignancies. HLH and malignancies have common clinical features, and HLH diagnostic criteria (HLH-2004/Hscore) were not validated in this specific population. We describe a case of a 72-year-old patient with a history of chronic lymphocytic leukemia stable for over 10 years who presented with fever and cytopenia. After excluding infectious etiologies and the progression of her disease, HLH was diagnosed. The patient was treated with etoposide, dexamethasone, intravenous immunoglobulin, and rituximab. Despite initial clinical improvement, the patient deteriorated and developed pulmonary aspergillosis and CNS involvement that reflected uncontrolled HLH. The patient died 45 days after her presentation. An unusual feature of this case was that HLH was not triggered by infection, disease transformation, or treatment. This case emphasizes the challenges of differentiating the development of overwhelming HLH from other complications associated with hematologic malignancy.

KEY WORDS: hemophagocytic syndrome; HLH; CLL; chronic lymphocytic leukemia; hemophagocytic lymphohistiocytosis; pancytopenia; fever.

J Gen Intern Med 37(6):1542–6
DOI: 10.1007/s11606-022-07395-7
© The Author(s), under exclusive licence to Society of General Internal Medicine 2022

INTRODUCTION

Hemophagocytic lymphohistiocytosis (HLH) is a life-threatening hyperinflammatory syndrome. Familial HLH is a genetic disease in infants with a known etiology, caused by impaired natural killer (NK) and cytotoxic T-cell function and driven by interferon-γ.[1] Infections and malignancies are the primary triggers associated with HLH in adults, varying geographically.[2]Malignancy-associated HLH (M-HLH) is a multi-system disorder of unclear pathophysiology.[3] It has a heterogeneous presentation, course, and outcome and does not have a single clinical, laboratory, pathologic, or radiological "gold standard" diagnostic feature. While the 5-year overall survival of HLH of different etiologies has improved recently (inflammatory conditions 50–88%,[4, 5] infections 30–80%,[4, 5] familial HLH 50–70%)[6], the survival of M-HLH remains poor (10–30%).[4, 5, 7] Diagnosis is based on the HLH-2004 criteria [8] that have not been validated in M-HLH.[9] This creates a significant diagnostic challenge since the malignant clone itself may be responsible for developing nearly all the diagnostic features of HLH.[10] We report a case of HLH in a patient with chronic lymphocytic leukemia (CLL), which highlights the challenges in diagnosis and management of M-HLH and the need for validated, specific diagnostic tools.

Received July 19, 2021
Accepted January 3, 2022
Published online February 17, 2022

CASE REPORT

A 72-year-old woman with CLL presented emergently to the hematology clinic with a 10-day history of extreme weakness, fever, and night sweats. She had CLL for over 10 years, during which time she required no treatment for her disease. At diagnosis, she had lymphocytosis only—clinical-stage Binet A, no 17p chromosomal deletion—and was assessed as having an excellent prognosis. Her white blood count remained stable at approximately 80,000 lymphocytes/mm^3. A year before her presentation, she developed mild splenomegaly, 2 cm below the left costal margin, but had no lymphadenopathy. Upon presentation, her physical examination was unchanged, but hemoglobin dropped to 8.1 g/dL, and her platelet count fell to 61,000/mm^3 from previously normal levels, and her white cell count decreased to 22,000/mm^3 with 80% lymphocytes. A bone marrow aspiration and a biopsy were performed to investigate the possibility of disease progression/transformation. A few hours later after the procedure, her temperature rose to 40°C, and she appeared ill and diaphoretic. She was admitted for further investigation. Laboratory studies revealed creatinine of 1.7 mg/dL (baseline, 0.8 mg/dL), C-reactive protein (CRP) of 3 mg/L (normal<0.5 mg/L), and

normal lactate dehydrogenase (LDH). A chest X-ray(CXR) was normal.

During her hospitalization, temperature spikes above 40°C persisted and an extensive evaluation for an infectious etiology was performed. Urine and blood cultures were sterile and serologic tests for Epstein Barr virus, cytomegalovirus, hepatitis B, and C viruses were negative. Serum ferritin was 585 ng/mL (normal 10–120 ng/mL), and fibrinogen and triglyceride levels were normal. Urinalysis was consistent with prerenal azotemia, and the sediment was bland. Total body computed axial tomography (CT) revealed splenomegaly and mild generalized lymphadenopathy. The bone marrow aspirate and biopsy performed earlier revealed moderate involvement by CLL without aplasia, hemophagocytosis, or disease transformation. After 5 days of empiric antibiotic treatment without improvement, tetracycline was added. Eight days after her admission, rickettsia serology and repeat blood cultures were negative; the patient remained febrile. An extensive autoimmune serology panel was negative, and complement levels were normal. Notably, over this same time period, her serum albumin decreased to 2.1 g/dL (normal 3.5–5.4 g/dL) and her general condition declined.

After ruling out infectious etiology, empiric treatment with prednisone 1 mg/kg was administered as a "therapeutic test," assuming that an undiagnosed inflammatory condition was the cause of the patient's current condition. A rapid clinical response was noted. The fever and night sweats subsided immediately, serum creatinine level normalized, and serum albumin increased to 3.2 g/dL 2 days later.

On day 11 from her first admission, 3 days after the administration of prednisone, recrudescence occurred with a fever of 40°C, night sweats, and a marked decrease in blood counts. Her hemoglobin was 6.3 g/dL, white cell count was 5230/mm^3, and platelet count was 14,000/mm^3. Albumin was 2.5g/dL, total bilirubin was 3.3 mg/dL (normal < 1.2 mg/dL), and creatinine was again elevated at 1.4 mg/dL. Ferritin increased significantly to 8917 ng/mL. Soluble CD25 (sCD25) levels and natural killer activity testing were ordered to investigate the possibility of HLH.

Table 1. Diagnostic Criteria Used for the HLH-2004 Trial

HLH-2004 entry criteria
A. Molecular diagnosis consistent with HLH: Pathologic mutations of *PRF1, UNC13D, STXBP2, Rab27a, STX11, SH2D1A, or XIAP*;
-OR-
B. **Five** out of the **eight** criteria listed below are fulfilled:
1. Fever ≥38.3°C
2. Splenomegaly
3. Cytopenias (affecting at least 2 of 3 lineages in the peripheral blood):
Hemoglobin <9 g/dl (in infants <4 weeks: hemoglobin <10 g/dl)
Platelets <100×10^3/ml
Neutrophils <1×10^3/ml
4. Hypertriglyceridemia (> 265 mg/dl) and/or hypofibrinogenemia (<150 mg/dl)
5. Hemophagocytosis in bone marrow or spleen or lymph nodes or liver
6. Low or absent NK-cell activity
7. Ferritin > 500 ng/ml
8. Elevated Soluble CD25 (soluble IL-2 receptor alpha)

On day 12, a positron emission tomography-CT did not indicate disease transformation, and the most probable diagnosis was deemed to be HLH. Accordingly, and due to clinical deterioration, treatment for HLH with etoposide and dexamethasone was begun according to the HLH-94 protocol before the patient fulfilled 5 of the 8 requisite diagnostic criteria (Table 1[11]). The platelet count decreased to 10,000/mm^3 and fibrinogen was 117 mg/dL (normal 200–400 mg/dL).

Day 14: The patient reported minor clinical improvement, but the ferritin level increased further to 28,636 ng/mL. Confirmatory test results for HLH were received and supported this diagnosis: natural killer cell activity was 0.68% (control = 79%), and sCD25 was 11,400 U/mL (normal<2000 U/mL). A repeat bone marrow biopsy revealed hemophagocytosis (Fig. 1). Treatment with pulsed methylprednisolone 1000 mg/day for 5 days and intravenous immunoglobulin (IVIG) 2 g/kg was added to etoposide.

Day 17: The patient's condition was notably improved, and ferritin level decreased to 4528 mg/mL. Rituximab was administered as a treatment for CLL.

By day 30, the patient's temperature and blood count were normal, and her HLH appeared to be controlled. However, fever recurred and was accompanied by a cough that was now productive. Physical exam revealed crackles over the left lung base. A chest CT revealed nodular infiltrates in both lungs and an evolving fungus ball (Fig. 2). She underwent bronchoscopy and a bronchial lavage sample studied under direct microscopy demonstrated branched hyphae. Treatment with voriconazole was begun and *Aspergillus fumigatus* subsequently grew on culture.

On day 40, a fever of 39.4°C was noted and was accompanied by confusion and right arm paresis. Ferritin increased to 49,000 ng/mL, fibrinogen was 100 mg/dL, the neutrophil count decreased to 840/mm^3, and the platelet count was 10,000/mm^3. CT of the brain ruled out intracranial hemorrhage, and the clinical estimation was that the neurological

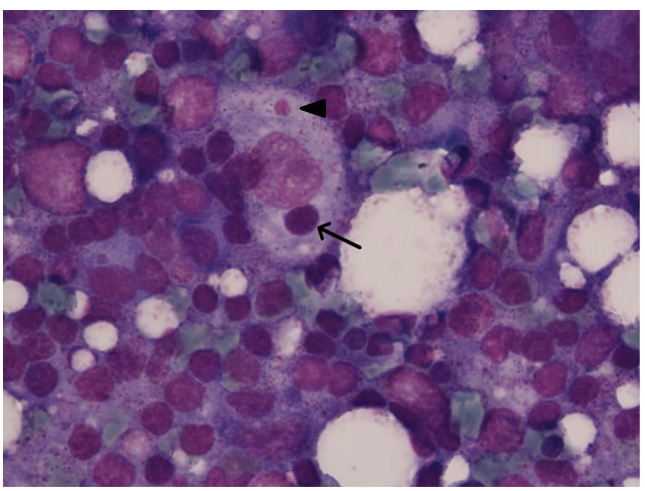

Figure 1. Hemophagocytosis was present on the second bone marrow aspirate. Touch-preparation of the bone marrow biopsy showing phagocytosis by a macrophage of a lymphocyte (arrow) and platelet (arrowhead).

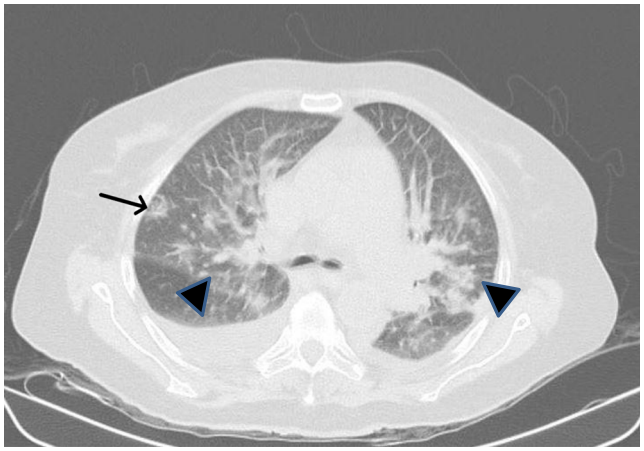

Figure 2. Lung aspergillosis further complicated the clinical course. A computed tomography image demonstrating bilateral nodular infiltrates (arrowheads) and an evolving fungus ball with a halo sign at the periphery of the right upper lobe (arrow).

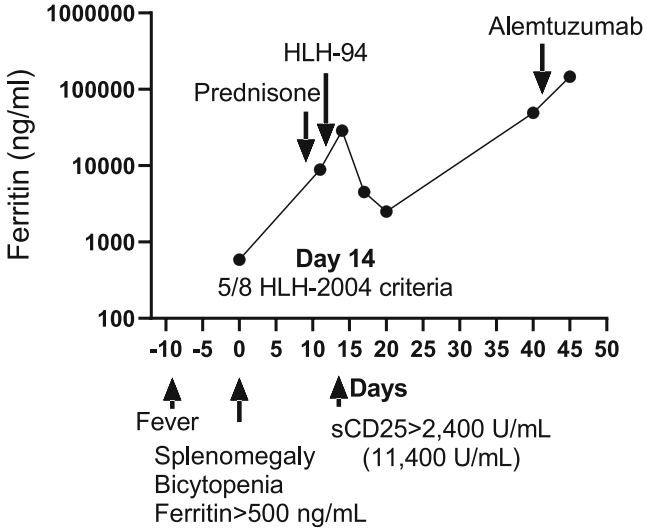

Figure 3. Key features of the patient's clinical course. Ferritin levels during the patient's clinical course. The days of HLH-2004 criteria fulfillment and treatment administered are noted. HLH-94 refers to an 8-week protocol of etoposide and dexamethasone.

symptoms reflect HLH reactivation. On day 42, the patient received alemtuzumab as salvage therapy.

On the 45th day after her initial admission, the patient's neurologic and general clinical condition deteriorated further. She became comatose and oliguric. Ferritin levels increased to 146,000 ng/mm^3. After discussing with her two children involved in all treatment decisions throughout her disease course, active treatment was withdrawn, and comfort measures were provided. She died peacefully 2 days later.

DISCUSSION

HLH is a syndrome of immune dysregulation that is often diagnosed using the HLH-2004 diagnostic criteria. The criteria are fulfilled when a patient has a genetic lesion associated with HLH or fulfills 5 of the 8 HLH-2004 criteria (Table 1[8]). The criteria are termed "diagnostic," although, by definition, they are classification criteria developed for the enrollment in the international HLH-2004 therapeutic clinical trial for the genetic form of the disease, familial HLH. These criteria were based on empiric observations in familial HLH using the technology and knowledge available at the time. Their specificity and sensitivity for M-HLH are unknown. They are used pragmatically as diagnostic criteria for all forms of HLH, which may result in a delay in diagnosis or misdiagnosis.[12]

The process of diagnosing multi-system inflammatory disorders requires an understanding of the difference between classification and diagnostic criteria. Classification criteria are most often derived from well-defined homogenous patient cohorts established for clinical research. These are very specific by design and thus risk missing patients with the relevant diagnosis. Diagnostic criteria are more sensitive and must reflect the different features of disease to broadly identify as many individuals with the condition as possible.[13] In light of this, the physician's clinical judgment is crucial in refining the diagnostic process. Our patient was diagnosed on day 14, and ordering the sCD25 test earlier could have expedited the diagnosis (Fig. 3). Furthermore, early empiric administration of corticosteroids may delay reaching a specific diagnosis, may mask possible disease transformation, and should generally be avoided.[10]

Diagnosing HLH precisely is important since treatment involves the administration of potentially toxic chemotherapy. HLH-2004 features such as splenomegaly may be a direct consequence of the underlying neoplasm.[14] Our patient had mild splenomegaly for at least a year as a feature of her CLL, and we were uncertain if we should consider it a diagnostic criterion. We (A.Z.L, M.J, M.E) recently examined 225 patients with hematologic malignancies HLH and demonstrated that most diagnostic features overlap among patients with or without M-HLH and cannot discriminate these clinical situations. We developed a novel diagnostic index based on the combined elevation of sCD25 (>3900 U/mL) and ferritin (>1000 ng/mL), the Optimized HLH Inflammatory (OHI) index for M-HLH diagnosis.[15] Our patient had a positive OHI index which we could calculate when sCD25 test results were obtained, highlighting the importance of early sCD25 testing. This study suggests that HLH diagnosis should be more reliant on inflammatory features than on features of tissue infiltration such as cytopenia and splenomegaly.

Diagnosis may also be hampered by over-reliance on finding hemophagocytosis on tissue biopsy. HLH is frequently diagnosed by hematologists who are used to pathology-based diagnosis and may be biased toward diagnosing HLH only when tissue evidence of hemophagocytosis is present, as implied by the name of the syndrome. However, the findings of hemophagocytosis are not sensitive or specific enough to diagnose familial or reactive HLH.[16] In our study of M-HLH in patients with hematologic malignancies, hemophagocytosis had a sensitivity of only 43%. Our patient did not have hemophagocytosis in her first biopsy, and there was no need

Table 2. Triggers for HLH in CLL Patients

Predisposing trigger	Case report/ series	N of CLL patients	The exact trigger	Conclusions
Disease transformation	(Picque et al., 2014)[19]	1	Transformation to PTCL under CLL treatment	Immune dysregulation may explain HLH and composite lymphomas and a high level of transformation suspicion should be kept in these cases
	(Ambinder et al., 2019)[27]	1	A spontaneous transformation to HSTCL	
Ibrutinib treatment	(Ambinder et al., 2019)[27]	4	In four of the cases, there is a clear temporal relationship between the initiation of ibrutinib and the onset of HLH.	Ibrutinib may rarely contribute to the development of HLH
	(Cavallari et al., 2017)[31]	1	Ibrutinib and EBV reactivation	Ibrutinib-induced impairment of NK degranulation, associated with EBV reactivation and CLL-related immunodeficiency may contribute to HLH development
Untreated CLL	(Bailey et al., 2017)[28]	1	No identified trigger	Untreated CLL may be a trigger for HLH
	(Kilari et al., 2013)[29]	1		
	(Meki et al., 2011)[32]	1		
EBV	(Lim et al., 2014)[22]	1	Cellulitis, EBV reactivation	EBV reactivation may trigger HLH in stable, low-risk, and untreated CLL
CMV	(Bergmann et al., 2018)[23]	1	CMV that developed under chemotherapy	CMV can trigger HLH in treated and untreated patients
	(Broe et al., 2014)[21]	1	CMV	
Histoplasma	(van Koeveringe et al., 2010)[24]	1	Histoplasma	Histoplasma reactivation can trigger HLH in a non-endemic area in an immunocompromised host
	(Rao et al., 2002)[25]	1	Histoplasma	
H1N1 influenza	(Lai et al., 2012)[26]	1	H1N1 causing CLL reactivation	H1N1 influenza A-associated hemophagocytic lymphohistiocytosis is often rapidly fatal

CLL chronic lymphocytic leukemia; EBV Epstein Barr virus; CMV cytomegalovirus; PTCL peripheral T cell lymphoma; HSTCL hepatosplenic T cell lymphoma

to repeat the biopsy once the diagnosis was already established.

HLH has been described in association with all hematologic malignancies and due to a variety of triggers.[17]M-HLH is usually diagnosed at presentation or transformation of lymphoma or after chemotherapy. Pasvolsky et al. recently described a case series highlighting the diagnostic challenge of M-HLH as the presenting manifestation of lymphoma, with two of the four patients dying before a diagnosis of lymphoma was made despite HLH-directed therapy.[18] HLH associated with CLL has been described with disease transformation,[19, 20] (seeTable 2) infections [21–26], or ibrutinib treatment[27] (Table 2). Ours is the fourth case reported in which no trigger was identified[28, 29, 32] (see Table 2). Furthermore, our patient demonstrated refractory HLH and aggressive measures to exclude disease transformation such as lymph node biopsy or splenectomy[33] and nucleic acid testing for EBV reactivation (serology indicated past infection) should be considered in these patients.

While making an accurate diagnosis is essential, persistent consideration of other processes "mimicking"[10] HLH is nonetheless important. Pulmonary aspergillosis developed in our patient with a high fever as the initial clinical feature. This temporarily raised the concern for progression of HLH, but appropriate investigations soon allowed the correct infectious etiology to be identified, highlighting the importance of maintaining a high level of suspicion for infectious complications of prolonged, profound immunosuppressive therapy. Patients complicated by these infections would probably be harmed from additional immunosuppressive therapy for HLH.

While understanding of the pathogenesis of inflammatory diseases continues to improve, most cases are not diagnosed using a single test.[30] Neither classification nor diagnostic criteria can accurately capture all patients, and clinical judgment is crucial in the diagnostic process. Therefore, clinical research to calibrate and validate current diagnostic criteria for M-HLH is needed. In addition, basic and translational research providing insights into the mechanisms of M-HLH may provide more specific diagnostic markers.

This case highlights the importance of early sCD25 testing, the need to apply HLH classification and diagnostic criteria while bearing in mind their limitations, and the importance of constant vigilance to detect possible HLH mimickers such as infection. Decision-making in HLH is challenging: improved understanding of the aberrant inflammation in this condition may yield tools to improve the diagnosis and management of these patients.

ACKNOWLEDGEMENTS: *The authors thank Tali Tohami Ph.D. and Rachel Shikler MSc for preparing the bone marrow photomicrograph and Mr. Amnon Liberman for insightful comments on earlier versions of the manuscript.*

Corresponding Author: *Adi Zoref-Lorenz, Division of Bone Marrow Transplantation and Immune Deficiency, Cancer and Blood Diseases Institute, Cincinnati Children's Hospital Medical Center, 3333 Burnet Ave, Cincinnati, OH, USA (e-mail: adilorenz@gmail.com).*

Declarations:

Conflict of Interest: *A.Z-L. and M.J have recieved consulting fees from Sobi. None of which are directly related to the conent of this paper.*

REFERENCES

1. Jordan MB, Hildeman D, Kappler J, Marrack P. An animal model of hemophagocytic lymphohistiocytosis (HLH): CD8+ T cells and interferon gamma are essential for the disorder. *Blood*. 2004;104(3):735-743.
2. Ramos-Casals M, Brito-Zeron P, Lopez-Guillermo A, Khamashta MA, Bosch X. Adult haemophagocytic syndrome. *Lancet*. 2014;383(9927):1503-1516.
3. Tamamyan GN, Kantarjian HM, Ning J, et al. Malignancy-associated hemophagocytic lymphohistiocytosis in adults: Relation to hemophagocytosis, characteristics, and outcomes. *Cancer*. 2016;122(18):2857-2866.
4. Ishii E, Ohga S, Imashuku S, et al. Nationwide survey of hemophagocytic lymphohistiocytosis in Japan. *Int J Hematol*. 2007;86(1):58-65.
5. Schram AM, Comstock P, Campo M, et al. Haemophagocytic lymphohistiocytosis in adults: a multicentre case series over 7 years. *Br J Haematol*. 2016;172(3):412-419.
6. Jordan MB, Allen CE, Weitzman S, Filipovich AH, McClain KL. How I treat hemophagocytic lymphohistiocytosis. *Blood*. 2011;118(15):4041-4052.
7. Lorenz F, Klimkowska M, Pawlowicz E, Bulanda Brustad A, Erlanson M, Machaczka M. Clinical characteristics, therapy response, and outcome of 51 adult patients with hematological malignancy-associated hemophagocytic lymphohistiocytosis: a single institution experience. *Leuk Lymphoma*. 2018;59(8):1840-1850.
8. Henter JI, Horne A, Arico M, et al. HLH-2004: Diagnostic and therapeutic guidelines for hemophagocytic lymphohistiocytosis. *Pediatr Blood Cancer*. 2007;48(2):124-131.
9. Aggarwal R, Ringold S, Khanna D, et al. Distinctions between diagnostic and classification criteria? *Arthritis Care Res (Hoboken)*. 2015;67(7):891-897.
10. Jordan MB, Allen CE, Greenberg J, et al. Challenges in the diagnosis of hemophagocytic lymphohistiocytosis: Recommendations from the North American Consortium for Histiocytosis (NACHO). *Pediatr Blood Cancer*. 2019;66(11):e27929.
11. Henter JI, Arico M, Egeler RM, et al. HLH-94: a treatment protocol for hemophagocytic lymphohistiocytosis. HLH study Group of the Histiocyte Society. *Med Pediatr Oncol*. 1997;28(5):342-347.
12. Otrock ZK, Daver N, Kantarjian HM, Eby CS. Diagnostic Challenges of Hemophagocytic Lymphohistiocytosis. *Clin Lymphoma Myeloma Leuk*. 2017;17S:S105-S110.
13. June RR, Aggarwal R. The use and abuse of diagnostic/classification criteria. *Best Pract Res Clin Rheumatol*. 2014;28(6):921-934.
14. Gurunathan A, Boucher AA, Mark M, et al. Limitations of HLH-2004 criteria in distinguishing malignancy-associated hemophagocytic lymphohistiocytosis. *Pediatr Blood Cancer*. 2018;65(12):e27400.
15. Zoref-Lorenz A, Murakami J, Hofstetter L, et al. An improved index for diagnosis and mortality prediction in malignancy associated hemophagocytic lymphohistiocytosis. *Blood*. 2021. https://doi.org/10.1182/blood.2021012764
16. Goel S, Polski JM, Imran H. Sensitivity and specificity of bone marrow hemophagocytosis in hemophagocytic lymphohistiocytosis. *Ann Clin Lab Sci*. 2012;42(1):21-25.
17. Lehmberg K, Nichols KE, Henter JI, et al. Consensus recommendations for the diagnosis and management of hemophagocytic lymphohistiocytosis associated with malignancies. *Haematologica*. 2015;100(8):997-1004.
18. Pasvolsky O, Zoref-Lorenz A, Abadi U, et al. Hemophagocytic lymphohistiocytosis as a harbinger of aggressive lymphoma: a case series. *Int J Hematol*. 2019;109(5):553-562.
19. Alomari A, Hui P, Xu M. Composite peripheral T-cell lymphoma not otherwise specified, and B-cell small lymphocytic lymphoma presenting with hemophagocytic lymphohistiocytosis. *Int J Surg Pathol*. 2013;21(3):303-308.
20. Picque M, Khoury E, Lenoble M, Chait Y. [Hemophacocytic syndrome as early sign for hepatosplenic T-cell lymphoma in a patient with chronic lymphocytic leukaemia]. *Ann Biol Clin (Paris)*. 2014;72(2):241-244.
21. Broe J, Lauritzen AF, Hansen PB. [Cytomegalovirus-associated haemophagocytic syndrome and acute renal failure in a patient with chronic lymphocytic leukaemia]. *Ugeskr Laeger*. 2014;176(25A):V10120603.
22. Lim MY, Fedoriw Y, Ramanayake H, Zeitler K, Bardy L, Moll S. Epstein-Barr virus reactivation and hemophagocytic lymphohistiocytosis in a patient with chronic lymphocytic leukemia. *Leuk Lymphoma*. 2014;55(12):2938-2941.
23. Bergmann K, Moller HEH, Bergmann OJ. Cytomegalovirus-associated haemophagocytic lymphohistiocytosis: a rare cause of febrile neutropenia during cancer chemotherapy. *BMJ Case Rep*. 2018;2018. https://doi.org/10.1136/bcr-2018-225592
24. van Koeveringe MP, Brouwer RE. Histoplasma capsulatum reactivation with haemophagocytic syndrome in a patient with chronic lymphocytic leukaemia. *Neth J Med*. 2010;68(12):418-421.
25. Rao RD, Morice WG, Phyliky RL. Hemophagocytosis in a patient with chronic lymphocytic leukemia and histoplasmosis. *Mayo Clin Proc*. 2002;77(3):287-290.
26. Lai S, Merritt BY, Chen L, Zhou X, Green LK. Hemophagocytic lymphohistiocytosis associated with influenza A (H1N1) infection in a patient with chronic lymphocytic leukemia: an autopsy case report and review of the literature. *Ann Diagn Pathol*. 2012;16(6):477-484.
27. Ambinder AJ, Hambley B, Shanbhag S, Merrill SA. Ibrutinib-associated hemophagocytic lymphohistiocytosis: A case series from Johns Hopkins. *Am J Hematol*. 2019;94(11):E296-E299.
28. Bailey C, Dearden C, Ardeshna K. Haemophagocytic lymphohistiocytosis as a consequence of untreated B-cell chronic lymphocytic leukaemia. *BMJ Case Rep*. 2017;2017. https://doi.org/10.1136/bcr-2016-219057.
29. Kilari D, Venci N, Friedberg J, Bennett JM. Hemophagocytic lymphohistiocytosis masquerading as progressive chronic lymphocytic leukemia. *Leuk Res Rep*. 2013;2(1):4-6.
30. Johnson SR, Goek ON, Singh-Grewal D, et al. Classification criteria in rheumatic diseases: a review of methodologic properties. *Arthritis Rheum*. 2007;57(7):1119-1133.
31. Cavallari M, Ciccone M, Falzoni S, et al. "Hemophagocytic Lymphohistiocytosis after EBV reactivation and ibrutinib treatment in relapsed/refractory Chronic Lymphocytic Leukemia". *Leuk Res Rep*. 2017;7:11-13.
32. Meki A, O'Connor D, Roberts C, Murray J. Hemophagocytic lymphohistiocytosis in chronic lymphocytic leukemia. *J Clin Oncol*. 2011;29(24):e685-687.
33. La Rosée P, Horne A, Hines M, et al. Recommendations for the management of hemophagocytic lymphohistiocytosis in adults. Blood. 2019 Jun 6;133(23):2465-2477. https://doi.org/10.1182/blood.2018894618

Publisher's Note: *Springer Nature remains neutral with regard to jurisdictional claims in published maps and institutional affiliations.*