



The impact of mucormycosis (black fungus) on SARS-CoV-2-infected patients: at a glance

Md. Rezaul Islam¹ · Md. Mominur Rahman¹ · Md. Tanjumul Ahasan¹ · Nadia Sarkar¹ · Shopnil Akash¹ · Mahfuzul Islam¹ · Fahadul Islam¹ · Most. Nazmin Aktar¹ · Mohd Saeed² · Md. Harun-Or-Rashid¹ · Md. Kawsar Hosain¹ · Md. Saidur Rahaman¹ · Sadia Afroz¹ · Shabana Bibi^{3,4} · Md. Habibur Rahman^{5,6} · Sherouk Hussein Sweilam^{7,8}

Received: 18 May 2022 / Accepted: 20 July 2022 / Published online: 19 August 2022
© The Author(s), under exclusive licence to Springer-Verlag GmbH Germany, part of Springer Nature 2022

Abstract

The emergence of various diseases during the COVID-19 pandemic made health workers more attentive, and one of the new pathogens is the black fungus (mucormycosis). As a result, millions of lives have already been lost. As a result of the mutation, the virus is constantly changing its traits, including the rate of disease transmission, virulence, pathogenesis, and clinical signs. A recent analysis revealed that some COVID-19 patients were also coinfecting with a fungal disease called mucormycosis (black fungus). India has already categorized the COVID-19 patient black fungus outbreak as an epidemic. Only a few reports are observed in other countries. The immune system is weakened by COVID-19 medication, rendering it more prone to illnesses like black fungus (mucormycosis). COVID-19, which is caused by a B.1.617 strain of the SARS-CoV-2 virus, has been circulating in India since April 2021. Mucormycosis is a rare fungal infection induced by exposure to a fungus called mucormycete. The most typically implicated genera are *Mucor* *rhyzuphrizopusdia* and *Cunninghamella*. Mucormycosis is also known as zygomycosis. The main causes of infection are soil, dumping sites, ancient building walls, and other sources of infection (reservoir words “mucormycosis” and “zygomycosis” are occasionally interchanged). Zygomycota, on the other hand, has been identified as polyphyletic and is not currently included in fungal classification systems; also, zygomycosis includes Entomophthorales, but mucormycosis does not. This current review will be focused on the etiology and virulence factors of COVID-19/mucormycosis coinfections in COVID-19-associated mucormycosis patients, as well as their prevalence, diagnosis, and treatment.

Keywords Black fungus · Mucormycosis · Zygomycosis · SARS-CoV-2 · Diagnosis · Etiology

Responsible Editor: Lotfi Aleya

✉ Sherouk Hussein Sweilam
s.sweilam@psau.edu.sa

Md. Habibur Rahman
pharmacisthabib@gmail.com

¹ Department of Pharmacy, Faculty of Allied Health Sciences, Daffodil International University, 1207 Dhaka, Bangladesh

² Department of Biology, College of Sciences, University of Hail, Hail, Saudi Arabia

³ Department of Biosciences, Shifa Tameer-E-Millat University, Islamabad, Pakistan

⁴ Yunnan Herbal Laboratory, College of Ecology and Environmental Sciences, Yunnan University, Kunming 650091, China

⁵ Department of Pharmacy, Southeast University, Banani, Dhaka 1213, Bangladesh

⁶ Department of Global Medical Science, Wonju College of Medicine, Yonsei University, Wonju 26426, Korea

⁷ Department of Pharmacognosy, College of Pharmacy, Prince Sattam Bin Abdulaziz University, Al-Kharj 11942, Saudi Arabia

⁸ Department of Pharmacognosy, Faculty of Pharmacy, Egyptian Russian University, Cairo-Suez Road, Badr City 11829, Egypt

Introduction

Mucormycosis is a deadly fungal disease caused by the Mucoraceae fungus. *Rhizopus*, *Mucor*, and *Absidia* species are the most common pathogens in this family. These organisms are members of the Phycomycetes class, which also includes the Entomophthorales order (Walther et al. 2019). Mucormycosis frequently affects immunocompromised people, such as those with diabetes, severe burns, blood dyscrasias, renal disease (Georgopoulou et al. 2003), sepsis, severe dehydration, and cirrhosis (Hoeprich 1995; Nussbaum and Hall 1994). The significant morbidity and mortality of rhino-orbit-cerebral mucormycosis make it stand out (Nussbaum and Hall 1994; Yohai et al. 1994). Early detection of this illness, especially in medically impaired patients, results in timely medical and surgical treatment, which leads to a better prognosis (Behl et al. 2022). In the past, only a few individuals survived without orbital exenteration to eliminate the infection (Kohn and Hepler 1985). The presenting complaints and care of twenty-seven patients of rhino-orbit-cerebral mucormycosis handled at our institute for 8 years were discussed.

Friedrich Küchenmeister may have described the first instance of mucormycosis in 1855 (Chander 2017). In 1884, Lichtheim reported two species of rabbits, *Mucor corymbiform* and *Mucor rhizopodiformis*, which eventually became known as *Lichtheimia* and *Rhizopus*, respectively. In three cases with significant sinus, brain, and ocular involvement, it was linked to poorly treated diabetes in 1943. *Saksenarae vasiiform* was isolated from Indian forest soil in 1953, and P.C. Misra studied soil from an Indian mango orchard in 1979 and identified *Apopophysomyces*, which was later discovered to be a major cause of mucormycosis. The term “mycosis” was coined by Arnold Paltauf. This disease has been linked to natural disasters and catastrophes, including a tsunami in the Indian Ocean in 2004 and a tornado in Missouri in 2011 (Wani 2021a). In the aftermath of the Joplin tornado in 2011, a cluster of infections arose. A total of 18 probable cases of mucormycosis of the skin have been identified by July 19, 2011, with 13 of them being confirmed. After television and press stories in response to a publication in a pediatric medical journal (Sundermann et al. 2019), details of a lethal mucormycosis outbreak that happened in 2008 became public in 2014. Many freshly cleaned hospital lines delivered to US transplant facilities were contaminated with Mucorales, according to a 2018 study (Seyedmousavi et al. 2018). In addition to humans, cases of mucormycosis have been reported in cats, dogs, cows, horses, dolphins, bison, and seals (Sen et al. 2021; Wani 2021b).

While the world struggles to cope with the deadly effects of COVID-19, a new menace known as the “black fungus”

has appeared throughout the world, particularly in India, Bangladesh’s neighbor. COVID-19-associated mucormycosis (CAM) has been found in several Asian nations (Garg et al. 2021; Kumer et al. 2021). Black fungus, also known as “mucormycosis,” is an uncommon but severe illness with a fatality rate of more than 50% (Jalal et al. 2022). When COVID-19 individuals are affected, the condition has grown deadlier. Mucormycosis is most linked with immunocompromised people with poorly managed diabetes, as well as long-term usage of steroids for COVID-19 therapy. More than 90% of CAM patients had diabetes, according to data throughout the world (Behl et al. 2022a; John et al. 2021).

Pulmonary mucormycosis, disseminated mucormycosis, rhinoorbital mucormycosis, and other CAM forms have clinical signs and pathogenesis (Otrisal et al. 2021b; Singh et al. 2021). The bulk of reported CAM cases (71%) came from India, with 14,872 instances (Raut and Huy 2021). In Bangladesh, however, the number is quite low, with only a few cases; all of them had diabetes. Both Bangladesh and India have comparable and higher diabetes rates (8.1% vs. 8.9% of total people), implying that Bangladesh is likewise in danger of CAM epidemic (“Federation ID, n. d. List of countries and territories in South-East Asia with members. Available via <https://idf.org/our-network/regions-members/south-east-asia/membershtml2020> (Accessed 23 June 2021),”).

Mucorales may also be found in a variety of settings, such as soil and decomposing organic waste including compost piles, leaves, rotten wood, and animal dung (Richardson and Infection 2009). People are continually exposed to Mucorales due to the extensive existence of Mucorales in the environment. As a result, excellent hygiene practices may aid in the prevention of mucormycosis. Unfortunately, many people in Bangladesh (about 107 million) still suffer from poor household hygiene (Organization 2021). Most of the fungal pathogens are opportunistic. Fungal infections have been increasing due to the increased number of immunocompromised hosts, and various types of mycoses may develop depending on the immune status of the patients (Huq et al. n.d). COVID-19 patients were also shown to have fungal infections such as *Aspergillus*, *Candida*, and mucormycetes. Mucormycosis, popularly known as the black fungus, is a fungal infection caused mostly by Mucorales species such as *Rhizopus* and *Mucor*. The disease is rare but may be serious around the globe, with a high incidence in India (Skiada et al. 2020; Slavin and Chakrabarti 2012). The majority of invasive fungal infections occur in immunocompromised patients due to the poor health management system (Badiee and Hashemizadeh 2014; Slavin and Chakrabarti 2012). Mucormycosis has been linked to a number of pre-existing health conditions, including diabetes mellitus, iron overload, cancers, organ transplant, kidney failure, coinfection with *Mycobacterium tuberculosis*, acquired

immunodeficiency syndrome (AIDS), and immunosuppressive therapy (Lin et al. 2017; Prakash and Chakrabarti 2019, 2021). In addition, COVID-19 patients may develop immunosuppression as well as increased blood glucose levels in both non-diabetic and diabetic cases. Therefore, CAM has been reported in the post-treated or recovered patients (Garg et al. 2021) (Boiko et al. 2022). CAM reports are currently on the rise all over the world, especially in Asiatic regions where the fatality rate among COVID-19 patients is high (Garg et al. 2021; Hoenigl et al. 2021). With various comorbid disorders such as diabetic mellitus, heart problems, and immune-impaired states, the effects of COVID-19 range from mild to moderate to life threatening (Apicella et al. 2020; Gandhi et al. 2020). Research articles further discussed how individuals with COVID-19 infection developed severe opportunistic infectious diseases such as pneumonia, candidiasis, and pulmonary aspergillosis (Chowdhary et al. 2020; Salehi et al. 2020). Additionally, there are stories of people with COVID-19 developing a strange fungal condition known as mucormycosis or black fungus (Sarkar et al. 2021). With 8848 cases of mucormycosis recorded as of May 22, 2021, COVID-19 patients in India also experience this epidemic disease (Akter et al. 2021a) (Afroze et al. 2017). However, given the high prevalence of untreated diabetes in Bangladesh, diabetes may be a critical risk factor for CAM. Furthermore, during COVID-19 infection, patients in Bangladesh are given steroids out of fear, which may damage their immune systems and put them at risk of mucormycosis ("Two black fungus cases detected in Bangladesh (9. Star TD, n. d. Two black fungus cases detected in Bangladesh. Available via <https://www.thedailystar.net/bangladesh/news/two-black-fungus-cases-detected-20983092021> (Accessed 23 June 2021).),"). Overall, there is a scarcity of information on the agents that cause mucormycosis and CAM. As a result, the taxonomy and genetic properties of mucormycosis etiologies, as well as transmission, clinical symptoms, pathogenesis, and other topics, are the subject of this review. This current review will be focused on the etiology and virulence factors of COVID-19/mucormycosis coinfections in CAM patients, as well as their prevalence, diagnosis, and treatment options.

Signs and symptoms

Fever, headache, coughing, shortness of breath, bloody vomit, and neurological symptoms, as well as discomfort and redness around the eyes or nose, are all warning signs (Tagde et al. 2021b) (Rahman et al. 2020) (Sharma et al. 2022) (Kaur et al. 2021) (Rahman et al. 2021a). Loss of sensation or swelling on one side of the face,

local discomfort on the cheekbone over the bridge of the nose/palate, there is a blackish discoloration. Teeth loosening, jaw involvement with discomfort and blurred or double vision, thrombosis, necrosis, and skin lesions are all examples of thrombosis. Chest discomfort, pleural effusion, and increased respiratory difficulties are all indications of a pleural effusion. Experts advise that all cases of blocked noses should not be mistaken for bacterial sinusitis, particularly in the event of immunosuppression and/or COVID-19 patients using immunomodulators. They advise that if you suspect a fungal infection, you should undergo rigorous examinations (Karthika et al. 2021) (Goyal et al. 2022) (Rahman et al. 2021b). Mucormycosis is a fungal infection that commonly affects the sinuses, brain, and lungs. Mucormycosis is most commonly found in the brain and mouth cavity, but the fungus can also infect other parts of the body, including the skin, gastrointestinal tract, and other organ systems (Muma and Chipalo-Mutati 2010). In rare circumstances, the maxilla may also be affected. Although more virulent fungi, such as those responsible for mucormycosis, can often overcome this obstacle, the strong blood vascular supply of craniofacial areas usually precludes fungal infections (Auluck 2007). Infection usually starts in the mouth or nose and spreads through the eyes to the central nervous system. When a sinus or the brain is impacted, the face swells one way, and headaches and congestion in the nose and sinuses are experienced, which leads to "black lesions" across the nose or upper side of the mouth; fever and eye swelling might develop. When the lungs are affected, the eyes may bulge, and fever, cough, chest pain, and difficulty in breathing can develop, as can coughing up blood. Nausea, abdominal soreness, vomiting, and bleeding are all symptoms of gastrointestinal system infection (Walia et al. 2021) (Purohit et al. 2022) (Zehravi et al. 2022). Due to tissue loss, the afflicted skin may appear as a darkish reddish sensitive patch with a darkening center (Hurt and Weedon 2012). Ulcers can arise at any time and can be extremely painful. When the fungus invades blood arteries, blood clots form and the surrounding tissue dies as a result of a lack of blood flow (Hurt and Weedon 2012). Because disseminated (widespread) mucormycosis usually occurs in patients who are already sick from other medical problems, it might be difficult to tell which symptoms are caused by the fungus (mucormycosis). Mental status changes or coma can occur in people who have a brain infection (Gambhir et al. 2021).

Transmission

Mucorales, also known as thermotolerant molds, are widespread in nature and are most usually discovered in soil and organic matter that has started to rot, such as leaves, compost

piles, rotting wood, and animal dung. Aerosolization makes it simple to disperse Mucorales sporangiospores in the environment, which range in diameter from 3 to 11 μm . Because the spores are airborne and can be found on any human surface that comes into touch with air, this is the main mechanism of transmission. Consumption of contaminated food and soil penetration through any burned, cut, or wounded skin are two additional potential transmission routes. Insects, such as those that sting or bite, can also spread fungi. And lastly, there are many different ways that nosocomial transmission can take place (Maniruzzaman et al. 2022) (Richardson and Infection 2009).

Risk factors

Mucormycosis is most common in those who are unable to resist infection (Wani 2021a). People with a low neutrophil count are at risk of infection, and tuberculosis (TB) is another risk factor. Mucormycosis has been linked to an increase in iron levels caused by deferoxamine treatment in kidney failure (Ibrahim et al. 2008). Steroids are widely used to treat COVID-19 and minimize damage produced by the body's variables (Tagde et al. 2022) (Howard 1999) (Akter et al. 2021a). Organ transplantation, AIDS, poorly controlled diabetes, iron overload, malignancies such as those of the immune system during coronavirus infection. Corticosteroids inhibit the immune system and raise blood sugar levels in both diabetic and non-diabetic people, which may lead to cases of mucormycosis. Immunocompromised individuals who have certain risk factors for mucormycosis may suffer negative effects from it. However, mucormycosis can also infect immunocompetent hosts in extremely small numbers (Chakrabarti et al. 2006b; Roden et al. 2005b). The hosts' immune systems are weakened by the risk factors for mucormycosis, which also encourage the growth of the agents and allow them to disseminate into the environment where they can cause harmful invasive infections. Risk factors for mucormycosis differed by geographic region, just like the etiological agents. For instance, compared to hematological malignancies in Europe, diabetes mellitus is more prevalent in India, Mexico, Iran, and various Middle Eastern and North African countries.

Mechanism

For cell growth and development, iron is a critical element, as it participates in various critical processes within the cell (Howard 1999). At present, it has been demonstrated that the level of accessible, free iron in serum is a significant element in the development of particular susceptibility to mucormycosis in individuals with diabetic ketoacidosis (DKA) (Artis et al. 1982). Iron is coupled to serum proteins in mammalian hosts, such as transferrin, ferritin, and lactoferrin, which transport iron throughout

the body. The sequestration of iron prevents the harmful effects of free iron (Artis et al. 1982; Howard 1999) from occurring. It is proved that *Rhizopus oryzae* growth is less in normal serum unless iron is supplied externally (Artis et al. 1982; Boelaert et al. 1993). Limiting iron availability in blood serum acts as a protective mechanism for the host against normal pathogens and also against Mucorales in particular. Because individuals with DKA are more susceptible to mucormycosis, the normal healthy people, the clinical finding that iron intake performs a function in the pathophysiology of the disease gives weight to this theory. Infusing serum with exogenous iron allowed *R. oryzae* to thrive in abundance under acidic but not alkaline circumstances (pH 7.4). In an acidic environment, the iron-binding capacity decreased, which indicates an acidosis environment lowers transferrin's ability to bind iron by converting ferric iron from transferrin by proton-mediated transfer (Ibrahim et al. 2008). Animal investigations have demonstrated that treating mice with DKA with iron chelators such as deferiprone and deferasirox (Ibrahim et al. 2006, 2007), which are not used by Mucorales as xenosiderophores, protected them from *R. oryzae* infection. On the other hand, not all Mucorales are equally vulnerable to efficient iron chelators (Lewis et al. 2011). Another clinical observation emphasizes the critical role played by the availability of host iron in the predisposition of patients to mucormycosis. Patients undergoing dialysis who are simultaneously receiving treatment with the iron chelator deferoxamine are at an increased risk of contracting a lethal form of mucormycosis (Boelaert et al. 1991) (Boelaert et al. 1991), which is a fungal infection (Fig. 1). Xenosiderophores such as deferoxamine, produced by bacteria, predispose people to *Rhizopus* infection by serving as bacterial siderophores (Boelaert et al. 1991). Deferoxamine connects to the mold via an inducible receptor after degrading ferric iron from transferrin. The iron is transported intracellularly when the ferric form is changed into the more soluble ferrous form by an active reduction of the ferric form into the more soluble ferrous form (De Locht et al. 1994). This happens when ferric iron is transformed to ferrous iron, which is more soluble. This is consistent with prior results that suggest that the administration of deferoxamine affects survival in *Rhizopus* infection, but does not influence survival in *Candida albicans* (Boelaert et al. 1993) (Boelaert et al. 1993). Deferoxamine administration decreases survival in *Rhizopus* infection but does not affect survival in *Candida albicans* infection (Boelaert et al. 1993). Finally, an underlying myelodysplastic syndrome is a significant risk factor for mucormycosis in transplantation, which is thought to predispose individuals to the disease as a result of iron overload caused by recurrent blood transfusions (Maertens et al. 1999). To get iron from the host, fungi can

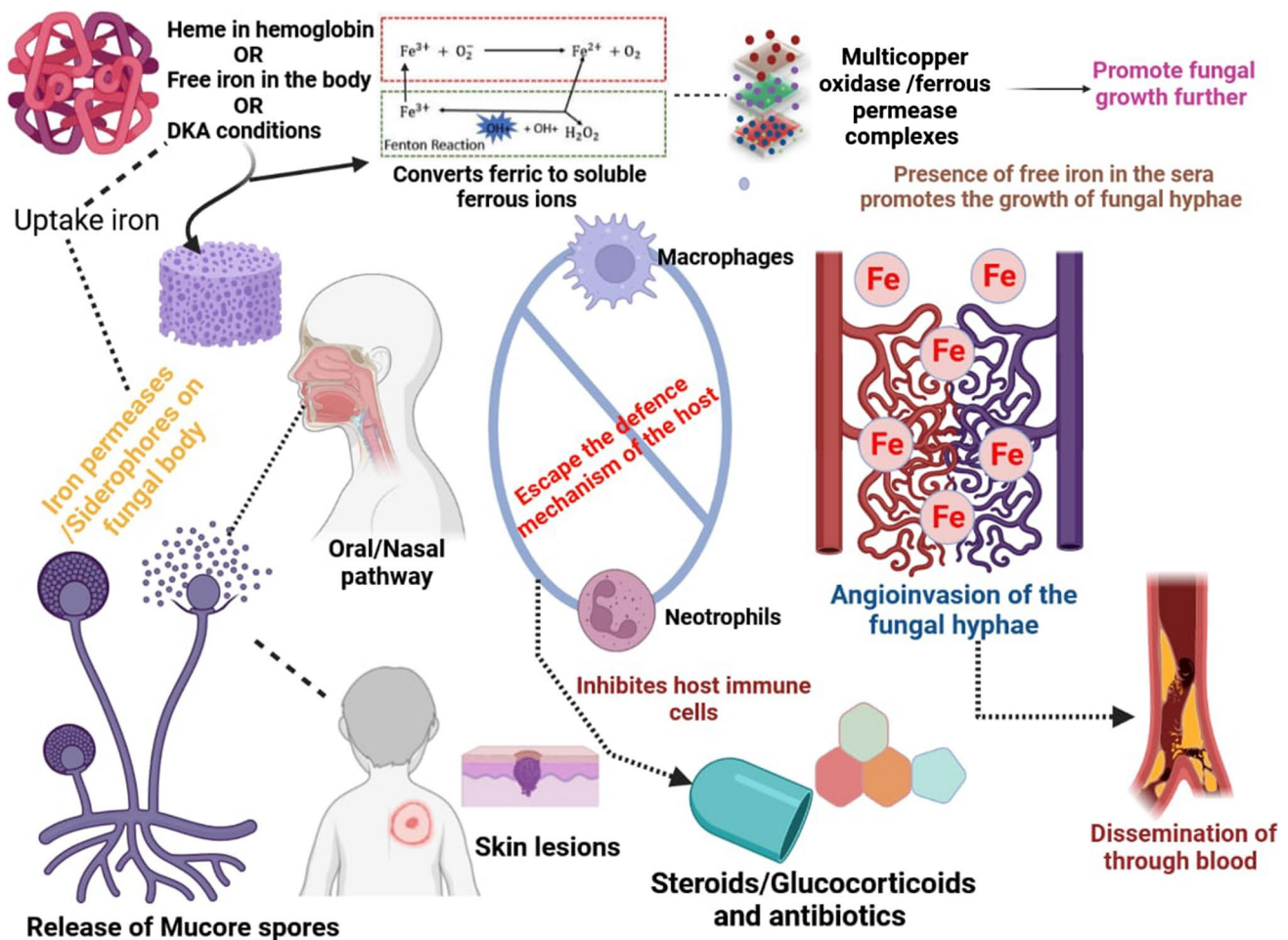


Fig. 1 Mucormycosis is a fungal infection with a typical etiology. The spores of the ubiquitous fungus enter the body through a skin injury or the naso-oral route, and then escape owing to pathological or immunocompromised situations, from the host immune cells. Fun-

gal spores penetrate the cellular barrier and produce hyphae in blood vessels, which disseminate to other organs and cause fungal infection at the entry site. DKA diabetic ketoacidosis

make use of iron permeases with high affinity for iron or iron chelators with low molecular weight (siderophores) (Maertens et al. 1999; Stearman et al. 1996). Fungi have iron permeases with a high affinity for ferric ions as part of a reductive system that also includes redundant surface reductases that convert ferric to the more soluble ferrous form of iron. When the surface reductase generates reduced ferrous iron, ferrous permease captures the reduced ferrous iron and transports it to the ferrous permease complex (Jung et al. 2008; Stearman et al. 1996). *R. oryzae* expresses the gene encoding high-affinity iron permease (FTR1) during mouse infection, and suppressing FTR1 gene expression with RNA-I or lowering the FTR1 copy number using gene disruption decreases the fungus' pathogenicity in experimental animals of mucormycosis, according to a recent study. Passive vaccination with anti-Ftr1p immune serum has been shown to protect DKA mice against *R. oryzae* infection (Jung et al. 2008), which was

significant. As a result, FTR1 is a critical virulence factor for *R. oryzae*, and passive immunotherapy using anti-Ftr1p is a viable method for improving outcomes in the severe mucormycosis disease. In addition to rhizoferrin, which is a siderophore that belongs to the polycarboxylate family (Jung et al. 2008), *Rhizopus* is also known to secrete rhizoferrin. In a receptor-mediated, energy-dependent mechanism (Jung et al. 2008), this siderophore provides iron to *Rhizopus* (Jung et al. 2008). In addition, it has been demonstrated that rhizoferrin is ineffective in collecting iron from serum (De Locht et al. 1994), implying that the contribution of the organism's endogenous siderophores to the organism's pathogenicity in a mammalian host is likely to be low. The host can get iron from a third mechanism by using heme (Ibrahim et al. 2010). Two homologs of heme oxygenase were found in the *Rhizopus* genome project (Ma et al. 2009). These 2 *R. oryzae* counterparts may enable *R. oryzae* to access host hemoglobin iron and explain *R.*

oryzae's angioinvasive nature. Of note, we discovered that the trailing medium development of *R. oryzae*, which has lower FTR1 copy numbers, was likewise supplemented with heme (Ibrahim et al. 2010). In *R. oryzae*, thus, FTR1 can operate as a cytoplasmic membrane permease which enables intracellular heme absorption, followed by the release of ferrous iron by intracellular breakdown with heme oxygenase. Other genes suspected to be involved in *R. oryzae*'s ability to absorb iron include Sree, a transcription regulator reported in *Aspergillus fumigatus*, which is necessary to adapt to the availability of ambient iron [40].

Diagnosis

Early identification of mucormycosis is extremely important because it can improve results. Studies have revealed that survival increases (Chamilos et al. 2008) and surgical resection, disfiguration, and suffering may also be needed or degraded. This disease is considered a rare disease, and the suspicion index is crucial. In diagnosis, we must consider several major points like identification of risk factors, clinical symptoms evaluation, imaging techniques, and finally cultures of the organism.

Direct microscopy

Images are taken directly with a camera using direct microscopy, and for preliminary diagnosis within a short period of time, a KOH wet mount is used. For better visualization of the samples in the laboratory, fluorescent brighteners such as Blankophor and Calcofluor white are used that are conjugated with KOH (Walsh et al. 2012). Direct microscopy of fresh material is a low-cost yet exceptionally effective way for obtaining a tentative diagnosis and defining clean surgical margins for invasive fungal infection during surgery [44]. These approaches, on the other hand, are not capable of distinguishing between fungi at the genus or species level. An additional method, immunohistochemistry using monoclonal antibodies against *R. arrhizus* (which has recently become commercially available), can help diagnose cultures that are negative and shown to be useful in distinguishing aspergillosis from mucormycosis (sensitivity 100%, specificity 100% for mucormycosis) (Jensen et al. 1997) and has received a moderate recommendation of B IIu in the recent ECMM/ESMM consensus statement (Cornely et al. 2019).

Culture

When diagnosing mucormycosis, specimen culture is critical since it enables genus- and species-level identification of the fungus, as well as antifungal susceptibility testing. The most therapeutically important Mucorales are thermotolerant,

meaning they can grow at temperatures as high as 37 °C. They may be grown on almost any carbohydrate substrate, with colonies often emerging in 24–48 h. They are identified based on colonial and microscopic morphology and the temperature of growth (Walsh et al. 2012). Culture of the Mucorales is identified by MALDI-TOP spectroscopy (Cornely et al. 2019). For commercial availability, more enriched databases and validation data are needed. Molecular identification will continue to be the gold standard until that time. If the positive culture is obtained from a sterile site, the diagnosis is confirmed. Suppose the positive culture is obtained from a non-sterile site (Cornely et al. 2019). Mucormycosis culture is not without its drawbacks, the most serious of which is its low sensitivity, resulting in false-negative results in up to 50% of cases. Several factors may be responsible for this, grinding or homogenization of tissue specimens, which can destroy micromycetes' fragile hyphae; the existence of taxa that require particular culture conditions; recent or continuing therapy with antifungals effective on Mucorales; or even a lack of experience are all factors to consider. To acquire the best potential output, adequate specimen sampling and management are required prior to the evaluation. As a result, efficient communication and close coordination between doctors and the microbiology laboratory are essential when a case is suspected to guarantee that all parts of the diagnostic procedure are accomplished appropriately (Walsh et al. 2012).

Predisposing conditions

According to various studies, the most critical mucormycosis-predisposing conditions are:

- With or without stem cell transplantation in malignant hematological illness
- Severe and prolonged neutropenia
- Diabetes mellitus that is poorly managed with diabetic ketoacidosis or not
- Iron overload
- The biggest trauma
- Long corticosteroid usage
- Illegal use of intravenous drugs
- Premature neonatal
- A history of HIV infection

Voriconazole and caspofungin, antifungal drugs that have no efficacy against Zygomycetes, have also been linked to breakthrough zygomycosis development (Hemsley and Kibbler 2008). Aside from these host-related risk factors, many cases have been related to the hospital environment, either entirely or in part. Construction labor, unclean air filters, or a range of healthcare-related

procedures and equipment have all been linked to nosocomial mucormycosis (Petrikkos et al. 2003a), among other things. Several cases of iatrogenic mini-outbreaks have been reported (Skiada et al. 2011a) (Petrikkos et al. 2003b). The present edition contains an in-depth examination of the relevant literature on the subject matter.

HM and hematopoietic stem cell transplantation

Hematopoietic stem cell transplantation (HSCT) is utilized for both hematological malignancies and non-malignant disorders, as well as salvage therapy in patients with no standard chemotherapy response chemotherapy or radiotherapy. The following are some of the general principles of allogeneic HSCT: (1) it allows patients to be rescued after receiving potentially myeloablative doses of chemotherapy and radiation in aggressive diseases, or after developing conventional therapeutic dosage resistance, and (2) it induces a significant graft-versus-malignancy response, which increases the likelihood of eradication of the malignancy and the development of conventional therapeutic dosage resistance. Acute myeloid leukemia (roughly one-third of cases), acute lymphoblastic leukemia (approximately 10–15% of cases), and acute lymphoblastic leukemia (approximately 10–15% of cases) patients and myeloproliferative/myelodysplastic disorders (each about 10–15% of cases) were the most frequently diagnosed. Treatment begins with a conditioning regimen of chemotherapy, immunosuppressive medications, and radiation treatment before the infusion of donor hematopoietic stem cells is carried out in the clinic. To prevent or treat GvHD, immunosuppressive medication is later provided. The conditioning regimen accomplished both eradicating malignant cells and suppressing the recipient's immune reaction. This prevents the recipient's immune response from reacting against the donor hematopoietic cells (Maedler-Kron et al. 2016).

Solid organ malignancies and solid organ transplantation

Specific fungal infections in recipients account for just a tiny proportion of total invasive fungal infections; nonetheless, mucormycosis is associated with a significant mortality rate. Depending on the solid organ transplantation (SOT) type, the predicted incidence ranges from 0.4 to 16.0% (Nampoory et al. 1996; Park et al. 2004). Renal transplant recipients have a range of 0.2 to 1.2%, liver transplant recipients have a range of 0 to 1.6%, heart transplant recipients have a range of 0 to 0.6%, and lung transplant recipients have a range of 0 to 1.5%. When neutropenia was assessed in a retrospective research and literature review, it was shown

that SOT recipients did not have it, nor did they have acidosis with or without hyperglycemia or usage of deferoxamine (DFO) (Singh et al. 2009). On the other hand, all patients were subjected to long-term immunosuppression, which was often accompanied by high doses of systemic corticosteroids. The skin and soft tissues were the most frequently affected, whereas the brain was the least affected. An increased incidence of mucormycosis was seen in a prospective, matched, case-controlled investigation of mucormycosis in SOT recipients who had previously used voriconazole and caspofungin, as well as those who had previously had renal failure or diabetes mellitus (Maurer et al. 1992).

Diabetes mellitus and ketoacidosis

Mucormycosis may be the initial symptom in some individuals with undetected diabetes mellitus (Mok et al. 2003), but it is uncommon in patients with metabolically managed diabetes (Petrikkos et al. 2012) (Kabir et al. 2022) (Karthika et al. 2022a). The epidemiology of mucormycosis in diabetes people is still being studied and is changing. Roden et al. (Park et al. 2004) (Tagde et al. 2021a) discovered that diabetic patients accounted for 36% of 929 reported cases but that the incidence of mucormycosis in diabetics has been decreasing over time (Reed et al. 2008). It has been hypothesized that treatment with statins, which are often used to treat metabolic disorders in the Western world, may have played a part in this reduced frequency because statins are active against some Zygomycetes (Mok et al. 2003; Roden et al. 2005a). Mucormycosis, on the other hand, continues to pose a serious concern to people with diabetes. According to a recent statewide retrospective research conducted in France, mucormycosis incidence among diabetics has increased by 9% every year (Mok et al. 2003). Another retrospective study conducted at two American teaching and tertiary care institutions found that 83% of patients with ROCM were diabetics, with 41% of those patients having no known history of the disease (Chakrabarti et al. 2006a). Fungal infection affecting the lungs is mucormycosis. These findings highlight the link between poor diabetes control and low socioeconomic level in the USA. Because healthcare is mainly out of reach of low-income folks until issues arise, they postpone seeking medical assistance unless complications occur. Another point to consider is that low- and middle-income individuals account for over 80% of all type 2 diabetes-related deaths (Arce-Salinas and Pérez-Silva 2010). Many of these cases of mucormycosis could have been avoided if diabetes control strategies had been implemented (Fig. 2).

Corticosteroid use and rheumatic diseases

Systemic lupus erythematosus in mucormycosis patients is documented in the research article (Arce-Salinas and

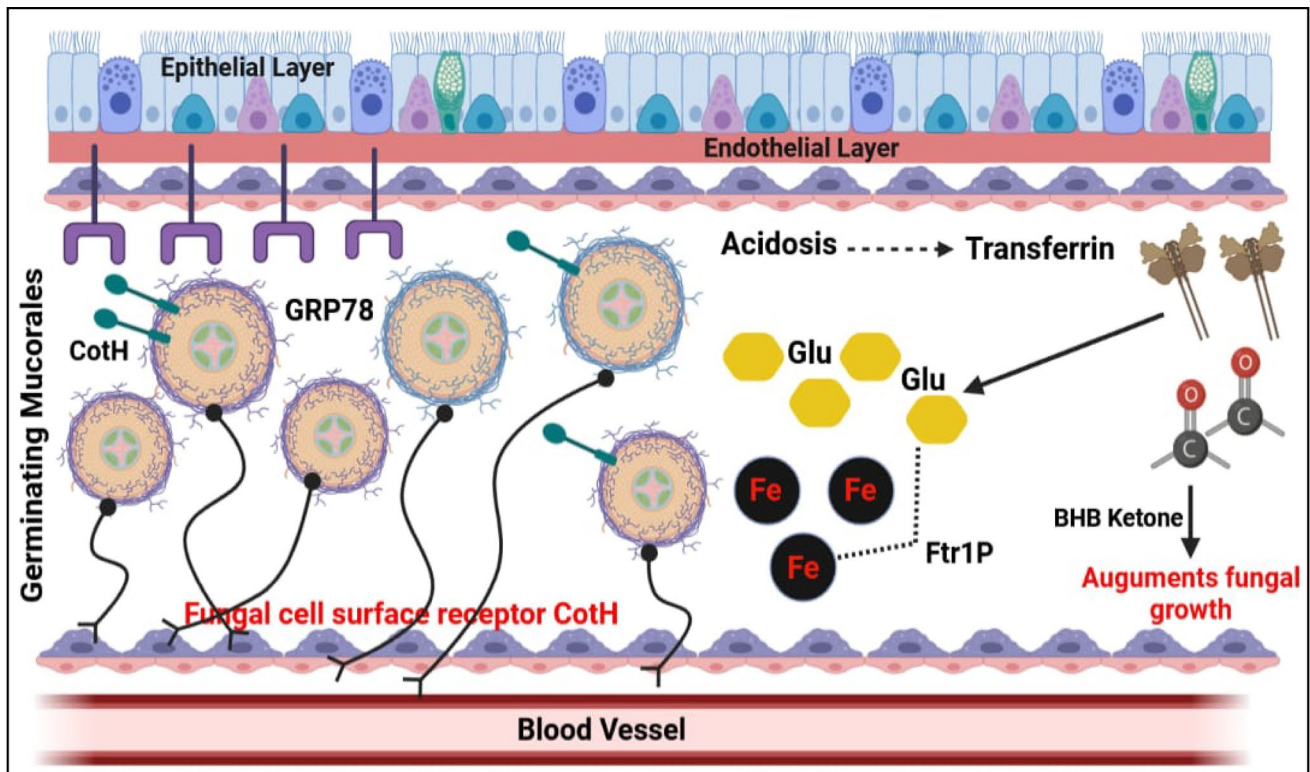


Fig. 2 Complex biochemical connections and immunomodulated interactions in COVID-19-related mucormycosis lead to death in hyperglycemia and ketoacidosis. Hyperglycemia and ketoacidosis develop when the transferrin protein fails to isolate free iron in the blood. Free iron molecules, glucose, and β -hydroxy butyrate (BHB)

ketone bodies influence the immunity that also help to boost up the expression of fungal Coth (coat protein homologs), resulting formation of mucor inside blood vessels. GRP78 glucose regulatory protein-78

Pérez-Silva 2010; Artis et al. 1982). Still, disseminated mucormycosis was prevalent and had a high mortality rate (88%) (Shenoi and Emery 2010). In addition to hypocomplementemia, nephrotic syndrome, uremia, leukopenia, and diabetes mellitus, there are several more risk factors for opportunistic mucormycosis to consider. Opportunistic mucormycosis is a fungal infection that can emerge in persons suffering from various autoimmune disorders. Another significant risk factor for mucormycosis is chronic corticosteroid-based medication, which increases a patient's vulnerability to the infection by inducing abnormalities in macrophages and neutrophils, as well as steroid-induced hyperglycemia (Daly et al. 1989).

Iron overload and chelation therapy with DFO

According to data from an international registry of mycoses, mucormycosis is treated with deferoxamine (DFO) in 78% of dialysis patients (McNab and McKelvie 1997). Mucormycosis is associated with other factors such as DFO and iron overload, which can be produced by transfusion or by dyserythropoiesis (Morrison

and McGlave 1993) (Marty et al. 2004) (Vigouroux et al. 2005). According to the literature, the disseminated form of mucormycosis is the most prevalent presentation in patients receiving DFO (44%), and this presentation is related to a high death rate, which has been reported to approach 80% (McNab and McKelvie 1997; Torres-Narbona et al. 2007).

Prolonged use of voriconazole

Mucormycosis incidence has increased in several institutions around the world because of the *Aspergillus*-active agents used. The findings of recent two randomized studies showed results comparing voriconazole prophylaxes with fluconazole or itraconazole prophylaxes in allogeneic transplant patients were inconclusive (Antinori et al. 2009) (Moraru and Grossman 2000), but they did not rule out the possibility that this was the case.

HIV or AIDS

Antinori et al. (2009) conducted a comprehensive retrospective investigation of 1630 autopsies of patients who died of

AIDS between 1984 and 2002 and found only two cases of mucormycosis. In HIV-infected patients, mucormycosis is uncommon compared to other immunocompromised populations, which explains the low occurrence of the disease in this community. The use of intravenous drugs is connected with the majority of mucormycosis cases in HIV-infected patients (Blatt et al. 1991; Van den Saffele and Boelaert 1996).

Mucormycosis in children

Mucormycosis in children is quite uncommon. Zaoutis and colleagues systematically assessed all accessible English-language reports of pediatric mucormycosis cases published before 2004. One hundred fifty-seven cases (64% of whom were male) with a median age of 5 years were identified by the researchers. Twenty-eight patients (18%) were diagnosed with HMs, and nine patients (6%) had received HSCT. From 2004 through 2008, an additional 30 pediatric cases were reported by the authors (Roilides et al. 2009).

Antifungal therapy challenges in COVID-19-infected patients

Researchers are investigating how common fungal coinfections are in COVID-19 patients and how to detect and treat them. For patient survival, early discovery, therapy initiation, and an understanding of the limitations of the continually updating COVID-19 therapeutic guidelines are crucial (Mekonnen et al. 2021) (Negrut et al. 2021). Acute invasive fungal rhinosinusitis (AIFRS) is a potentially fatal fungal illness (Deutsch et al. 2019) (Behl et al. 2020) (Negru et al. 2022). Immunocompromised patients are more vulnerable, such as those with hematological malignancies, diabetes, or organ transplantation (Hirabayashi et al. 2019) (Bhattacharya et al. 2021) (Mazumdar et al. 2016). COVID-19 infected over 18 million peoples globally, 4 million in the USA, and 2 million in Bangladesh (Dong et al. 2020) (Sindhu et al. 2021a). Acute respiratory distress syndrome (ARDS) caused by a coronavirus can increase the risk of pulmonary fungal infections (Song et al. 2020a). Invasive mold infection is a serious consequence seen in people who have had acute viral pneumonia (Schauwvlieghe et al. 2018). In Europe, China, and the USA, fungal superinfections have been identified (COVID-19). Aspergillosis is the most prevalent cause, with prevalence rates ranging from 7.7 to 27.7% (Hughes et al. 2020; Marr et al. 2021). Based on histology, microbiology, imaging data, and clinical variables, COVID-19-associated invasive pulmonary aspergillosis (CAPA) has been identified (Koehler et al. 2020) (Al-Harrasi et al. 2022a). Hospitals are facing new clinical issues as the global coronavirus pandemic (COVID-19) spreads around the world. The increased chance of coinfections is one of these concerns that pose a significant

risk to patients. Although the number of COVID-19 patients who developed secondary fungal infections resulting in severe complications and even death is still low due to the pandemic's short duration, studies have been published that show a huge number of COVID-19 hospitalized patients who developed secondary fungal infections resulting in severe complications and even death (Segrelles-Calvo et al. 2021) (Tagde et al. 2021c) (Karthika et al. 2021).

Epidemiology of fungal coinfections in COVID-19 patients

COVID-19 is a severe acute respiratory infection that has been spreading over the world (Song et al. 2020b; Fatima et al. 2022; Behl et al. 2022b). In hospitalized COVID-19 patients, fungal coinfections, particularly with *Aspergillus* and *Candida* species, are frequent, impacting patient outcomes and treatment efforts. However, there is currently a paucity of knowledge and expertise about the causative association between fungal coinfections and the severity of COVID-19 disease in patients. If and when such data becomes available, it will help with proper case management (Ezeokoli and Pohl 2020). Fungal infections can make COVID-19 diagnosis, treatment, and development more challenging, whether they occur before or after COVID-19 exposure (Karthika et al. 2022b; Chung et al. 2020; Kim et al. 2020; Ding et al. 2020; Gangneux et al. 2020). Pre-existing fungal infections are uncommon at this period. This is due to the likelihood of previously unknown fungal infections in healthy persons prior to COVID-19 exposure, a lack of accurate clinical symptom descriptions, and a preference for COVID-19 diagnosis over fungal infection detection (Ezeokoli and Pohl 2020). Although COVID-19-related conditions are widespread in ICU patients, they are not the only source of infection (Basseti et al. 2017). Mucormycosis is an example of an opportunistic fungal infection. It was once debatable whether persons who take immunosuppressants such corticosteroids and monoclonal antibodies are more prone to get COVID-19 or whether the immunosuppressive condition makes COVID-19 disease worse. Immunosuppressive drugs are still needed unless the patient is at a higher risk of severe COVID-19 infection or is on excess dose of corticosteroids (Otrisal et al. 2021a). As far as we know, COVID-19 disease causes severe and long-term lymphopenia, which raises the risk of opportunistic infections (Sindhu et al. 2021b).

The global popularity of COVID-19 and the possibility of fungal coinfections

Coronaviruses are transmitted from human to human that infect respiratory tract and also have become a worldwide public health issue (of the International 2020; Zhou et al.

2020). SARS-CoV-2, like SARS-CoV and MERS-CoV, causes respiratory illnesses (Huang et al. 2020) (Chahal et al. 2021). Extremely unwell patients, patients who were admitted in an intensive care unit (ICU), required mechanical ventilation, or had spent more than 50 days in the hospital, were more likely to have fungal coinfections (Raedler and Schaub 2014). At this moment, there are no known treatment drugs for this virus. COVID-19 is being treated with antiviral methods that are currently being explored (Al-Harasi et al. 2022b). Infections in the respiratory system, such as influenza, predispose patients to coinfections, worsening the sickness and increasing the likelihood of death (Mirzaei et al. 2020). The 2019 coronavirus infection caused by coronavirus two and produced severe acute respiratory syndrome has decimated the world (SARS-CoV-2). Based on review data from SARS and influenza, we believe that fungal coinfections linked to COVID-19 may be overlooked or misdiagnosed. Despite the absence of evidence, patients with COVID-19 are more likely to develop invasive mycoses, especially those severely ill or immunocompromised. Risk factors, forms of invasive mycoses, diagnostic strengths and limitations, clinical scenarios, and the need for a measure or individualized treatment are all explored (Tilavberdiev and Madaminov 2021). COVID is related to any infectious disease, and the metabolites generated by microorganisms such as bacteria, fungus, and protozoa can be implicated in necrotizing pneumonia and other necrotizing medical diseases found in COVID-19 (Akter et al. 2021b) (Karthika et al. 2021).

Clinical manifestations

Lyme infection caused by a spirochete that is carried by insects begins with an erythema chronicum migrans rash. Evanescent red blotches or circles, malar or urticarial rash, conjunctivitis, and periorbital edema were seen in nearly half of the 314 Lyme disease patients. Dermatological symptoms, quickly shifting system involvement, and, if required, serologic tests can all be used to diagnosis early Lyme disease (Paley 2021). *Staphylococcus aureus* is a type of bacteria that cause a variety of illnesses in humans. Bacteremia, infective endocarditis, osteoarticular infections, skin and soft tissue infections, pleuropulmonary infections, and infection caused by medical equipment are all examples of joint disorders. This study delves into the epidemiology, etiology, clinical symptoms, and treatment of each of these clinical entities. While reviewing the literature to support management strategies for various clinical presentations, we discovered a paucity of high-quality evidence for several critical clinical concerns (Tong et al. 2015). *Staphylococcus aureus* is both a disease and a commensal bacterium in humans. *S. aureus* has colonized around 30% of the human

population (Wertheim et al. 2005). Hemoglobinopathies are one of the world's most frequent hereditary disorders. Due to immigration, they have grown much more frequent throughout northern and central Europe, particularly in Germany (Kohne 2011). Two hundred forty individuals with common variable immunodeficiency, seven patients with thymoma-associated hypogammaglobulinemia, and 44 patients with X-linked agammaglobulinemia had their records analyzed at this clinic over the last 20 years. Despite significant therapeutic improvements, there is still a long time between diagnosis and treatment and high death and morbidity rates. Hypogammaglobulinemia has been associated with chronic sinopulmonary infection, chronic diarrhea, malignancy, joint sickness, and hepatitis. Mycoplasma infections and enterovirus infections can be resistant to treatment, which is a severe problem. The increased frequency of lymphoma and stomach cancer in people with common variable immunodeficiency is highlighted (Eastwood and Nyhlin 1995).

Pulmonary mucormycosis

Pulmonary mucormycosis is caused by a severe but rare opportunistic fungus that affects persons who are immunocompromised. There is a paucity of research on the subject. To evaluate the clinical aspects of this infection, we examine a recent case and do a literature study. After reviewing the MEDLINE database for publications published in the English-language literature from 1970, we found 87 instances. Diabetes, hematologic malignancies, renal insufficiency, and organ transplantation were all significant risk factors. Several patients looked to have weakened immune systems. The top lobes tended to become entangled. Air crescent signals on chest x-rays indicated pulmonary hemorrhage and hemoptysis mortality. Histopathologic examination was found to be more sensitive than fungal cultures, and fiber-optic bronchoscopy was found to be a proper diagnostic technique. In total, 44% of the victims were rescued. Patients who received a combination of medicinal and surgical treatment fared better than those who did not. As a result, immunocompromised people who do not respond to antibiotics should be suspected of having this infrequent but often fatal infection. To maximize the chances of cure, early detection and active management are critical. Systemic antifungal medicine, surgical excision, and, if possible, repair of the patient's underlying condition are all required for effective treatment (Lee et al. 1999). Mucormycosis is an opportunistic fungal infection that commonly begins in the lungs (Tedder et al. 1994). Mucormycosis has recently been identified as a serious lung infection in hematologic patients and transplant recipients who were given antifungal prophylaxis using antifungals that were efficacious against *Aspergillus* but not Mucorales. Unlike pulmonary aspergillosis, pulmonary mucormycosis has not improved considerably in the

previous decade because of difficulties with early identification and the low efficacy of present antifungal therapies for Mucorales (Hamilos et al. 2011).

Rhinocerebral mucormycosis

The rhinocerebral type of the illness, which accounts for around half of all newly described cases, is most commonly observed in poorly managed diabetics or extremely dehydrated young children. We have dealt with 13 cases since 1963, which are detailed in this report. The chance of long-term survival is around 85%. The rigorous surgical treatment, which included regular debridement and intravenous amphotericin B, is responsible for the remarkable cure rate (Kvijayan and Specialities 2019). Rhinocerebral mucormycosis is caused by an invasive, opportunistic fungus that typically affects people who are immunocompromised, such as those who have diabetes or other immunological problems. The colonization of the nasal mucosa is thought to be the site of entry, allowing the fungus to proceed into the orbit via the paranasal sinuses. Because the orbital apex is implicated in the infection of the brain and cavernous sinus, sphenotomectomy with or without maxillectomy appears to be the most effective therapy. From February 2000 to April 2004, 10 persons with rhinocerebral mucormycosis were assessed in prospective research. Eleven people were diagnosed with rhinocerebral mucormycosis clinically, and ten of them were included in our study following histological confirmation. In nine out of ten instances, the underlying illness was diabetes (Hosseini et al. 2005). Rhinocerebral mucormycosis is a severe and sometimes fatal fungal illness. Nasal mucosa involvement with the invasion of the paranasal sinuses and orbit is the classic presentation. Mucormycosis is most typically associated with diabetic ketoacidosis; however, since the introduction of AIDS and potent immunosuppressive drugs, disease demographics have changed. Aggressive debridement, systemic antifungal medication, and management of underlying comorbid variables are all part of the therapy plan (Peterson et al. 1997). Rhinocerebral mucormycosis is only observed in people with substantial metabolic or immunologic issues, with a few exceptions. Factors that may predispose to mucormycosis development are studied. Ketoacidosis and immunologic insufficiency caused by the underlying disease or treatment for other disorders are examples of these. Understanding these risk factors is crucial to initiate proactive diagnosis and treatment as soon as feasible (McNulty 1982).

Cutaneous mucormycosis

The fungus Zygomycetes, which belong to the Mucorales family, causes mucormycosis. Immunocompromised people are more likely to be impacted by this disease, which

has a severe and rapid course. Mucormycosis can manifest itself in a variety of clinical manifestations and locations. Although obtaining the correct diagnosis can be challenging, it is essential for a patient's survival. Mucormycosis manifests itself in a variety of ways. Cutaneous mucormycosis is less common than other varieties of mucormycosis, but if not treated promptly, it can be fatal. Histology and tissue culture both indicate a fungal infection. As a typical treatment, antifungal medicines are utilized in conjunction with surgical debridement. We present five different cases of cutaneous mucormycosis treated at our clinic, as well as the treatments used in each patient (Arnáiz-García et al. 2009). Cutaneous mucormycosis is the third most common clinical kind of mucormycosis, after pulmonary and rhinocerebral mucormycosis. The most common factors predisposed to this infection are hematological malignancies and diabetes mellitus, but many individuals are immune-competent. Mucormycosis agents can be found worldwide and are transmitted to the skin via direct inoculation due to various injuries. Among these are needlesticks, animal stings and bites, car accidents, natural disasters, and burn injuries. The most common symptom of mucormycosis is necrotic eschar; however, it can sometimes develop with other symptoms. The infection could be limited, penetrating nearby fat, muscle, fascia, and bone, or spreading throughout the body. The vague symptoms of mucormycosis make diagnosis difficult. A biopsy, as well as a culture, is required. Surgical debridement, antifungal medicines (amphotericin B and posaconazole), and, when possible, reversal of underlying risk factors are used to treat mucormycosis. Although fatality rates are lower than in other varieties of the disease, they are nevertheless substantial, ranging from 4 to 10% when the infection is contained [48]. Cutaneous mucormycosis is a novel fungal infection caused by the opportunistic Glomeromycota fungus. It is common in poorly controlled diabetes patients and immunocompromised individuals. Following a traumatic experience, it is typically obtained through direct inoculation. Although an indurated plaque that progresses to necrosis is typical, the clinical picture is not always clear. The etiological agent must be identified to confirm the diagnosis, and new molecular diagnostic techniques have recently been established. It is a life-threatening, invasive disease that necessitates early detection and intensive treatment to improve survival. The therapy of choice is amphotericin B, but novel azoles such as posaconazole and isavuconazole should also be investigated (Gómez-Camarasa et al. 2014).

Gastrointestinal mucormycosis

The gastrointestinal mucormycosis of twenty patients is investigated. Colonization (five patients), infiltration (seven patients), and vascular invasion (four patients) were the histological findings for this potentially fatal opportunistic

fungal infection (eight patients). There were no deaths because of colonization. Mucormycosis exacerbated the peptic ulcer disease in ten patients. An infiltrative or invasive illness developed in seven of the individuals. Five of the seven patients' presentation and operational results resembled cancer, and six received successful surgical surgery. The other patient could only be helped by medical intervention. Patients with post-traumatic peritonitis (4), transmural amoebiasis (2), tuberculosis (1), gastroenteritis (1), stomach cancer (1), and diabetes were among the ten patients who had infections linked with other gastrointestinal illnesses (1). Only one of the eight patients was able to avoid a life-threatening disease. When mucormycosis was related to a peptic ulcer in this study, it took a less aggressive course than when it was linked to other gastrointestinal disorders (Thomson et al. 1991). Mucormycosis is a life-threatening infection caused by fungus in the Mucoromycotina subphylum of the Mucorales order (Hibbett et al. 2007). Diabetes, abnormalities in host phagocytes, corticosteroid use, organ or stem cell transplantation, and high levels of accessible blood iron due to acidosis or deferoxamine treatment are all traditional risk factors for the development of invasive mucormycosis (Goldstein et al. 2009; Spellberg et al. 2005). The illness has been described in an increasing number of patients who do not have usual risk factors in recent years (Roden et al. 2005a). Over the last decade, mucormycosis has become a leading cause of death among people with diabetes and other immunocompromised people. Mucormycosis symptoms include rhinosinusitis, pansinusitis, rhinoorbital, and rhinocerebral symptoms. Primary GI mucormycosis, on the other hand, is an uncommon condition with a high fatality rate. The stomach is the most common location of GI mucormycosis. In the literature, only a few cases of GI mucormycosis in an immunocompetent host have been recorded. A young child developed fungal sepsis due to GI mucormycosis in an immunocompetent person (Benjamin 2009).

Disseminated mucormycosis

Early detection of invasive mucormycosis is critical for effective treatment, higher survival rates, and lower morbidity (Walsh et al. 2012). Disseminated mucormycosis, which first manifested as indurated skin nodules and pneumonia, exacerbated the clinical history with acute granulocytic leukemia. This is the first time cutaneous vasculitis has been characterized as a mucormycosis dermatologic presentation (Meyer et al. 1973). Isavuconazole is only approved to treat invasive aspergillosis and mucormycosis in adults because no pediatric pharmacology studies have been published so far. Isavuconazole has only been used in a few pediatric cases that have been published. Even with the liposomal formulation, amphotericin B is the only antifungal treatment recommended for pediatric

mucormycosis. However, side effects, particularly nephrotoxicity, could be a problem. In this case, other antifungal drugs that are effective against Mucorales are required (Cornu et al. 2018).

Uncommon forms of mucormycosis

Molds other than *Aspergillus* are causing a growing number of people to become ill. The ever-increasing use of solid organ and hematopoietic stem cell transplantation, as well as more stringent myeloablative therapy for malignant tumors and more intense care for critically ill patients, contributes to the spread of these infections. Invasive mold infection fatality rates remain high, despite advances in diagnostic and therapeutic options. This paper summarizes the current state of knowledge about non-*Aspergillus* mold infections of the chest, focusing on risk factors, clinical characteristics, diagnosis, and therapy (Quan and Spellberg 2010). Mucormycosis (Fig. 3), a life-threatening disease caused by a Mucorales fungus, is becoming more common. Direct inoculation causes skin mucormycosis, which commonly occurs after trauma or surgery. Gastrointestinal mucormycosis affects the stomach and colon after consuming infected food or using contaminated equipment. Disseminated illness, the most severe form of the disease, is accompanied by significant immunosuppression. Endocarditis, osteoarthritis, and isolated brain infections are just a few of the unusual symptoms that have been reported. Finally, in preterm newborns and burn units, mucormycosis associated with medical care is a concern. Only the early reversed halo sign is connected to pulmonary mucormycosis, regardless of clinical symptoms or CT scan results. Circulating Mucorales DNA detection is a potential new diagnostic tool that can help diagnose and treat antifungal medication, underlying disease repair, and surgery if necessary (Serris et al. 2019).

Bangladesh reports 1st death by black fungus

Many web databases were used to obtain crucial information regarding these diseases. According to published reports and evaluations, the long-term repercussions of these simultaneous epidemics on global socioeconomic and public health status can be projected based on earlier outbreak experiences, notably the COVID-19 pandemic. Furthermore, continued local government restrictions may lead to food insecurity, global recession, and a significant impact on the mental health of people of all ages, especially in developing countries. Slowed national economic growth, greater political insecurity, and a shortage of essential commodities are

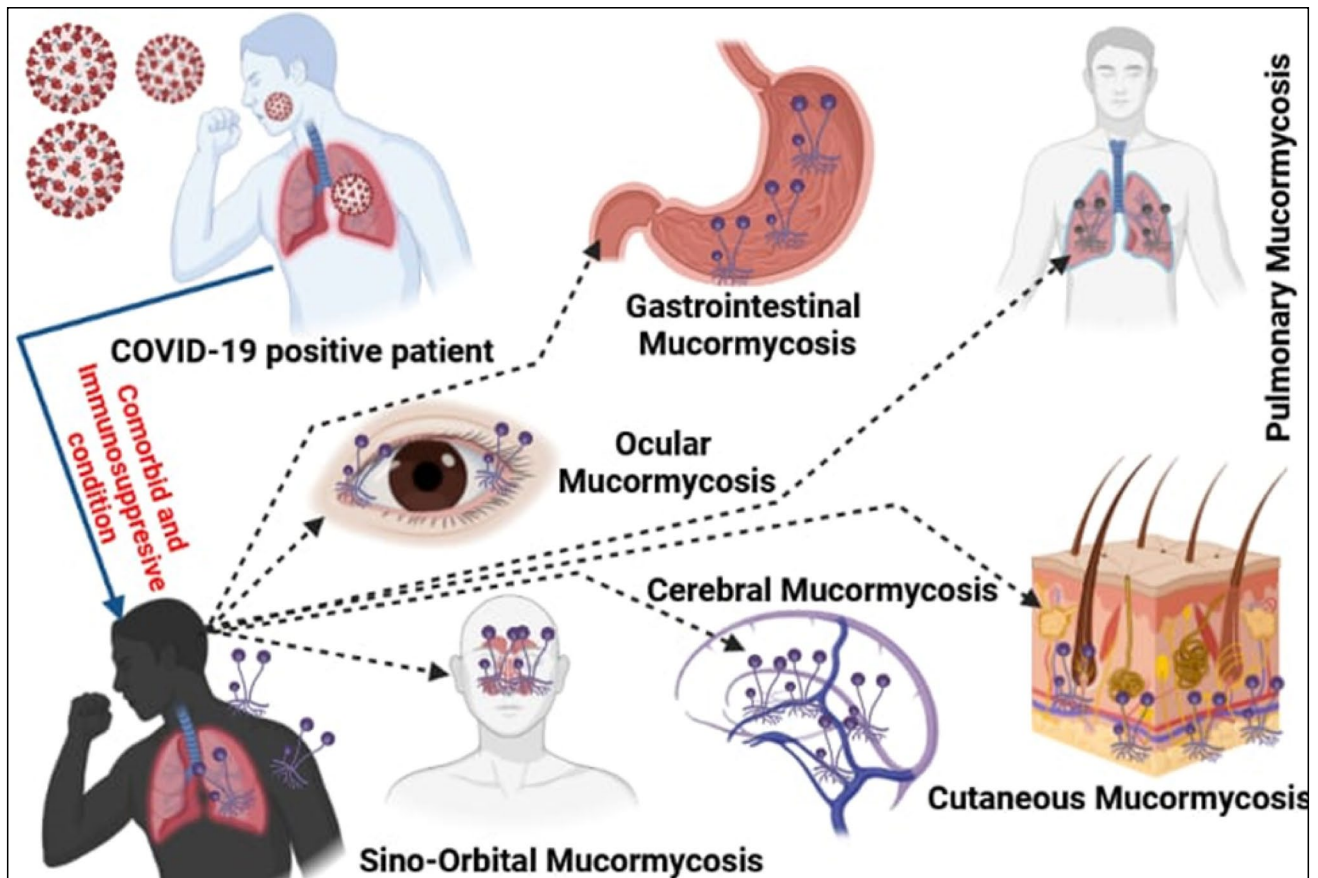


Fig. 3 Based on case reports, a clinical depiction of several kinds of COVID-19-associated mucormycosis (CAM)

just a few of the far-reaching impacts that have already been noticed. Despite several efforts to solve the situation, such as immunization, clinical management, further research, social separation, and lockdown, among others, emerging variations and accompanying genetic changes may make containment more difficult, exacerbating the problem once more. Continuous preparedness and updated clinical care backed by epidemiological studies and novel scientific endeavors are unavoidable in confronting many infectious disease waves simultaneously, given the pathogens' current mutational dynamics and prior experiences (Khan et al. 2021).

Drug treatment for mucormycosis

The diagnostic approach used in clinical practice is insufficiently sensitive and specific. On radiography, pulmonary mucormycosis has been related to many (10) nodules and pleural effusion. The inverted halo sign is another finding on computed tomography (CT) scan that appears to suggest the presence of mucormycosis. The cornerstones of diagnosis are microscopy (direct and on histology) and culture. Micrococetes can be detected or identified via molecular testing,

and they may be recommended as a valuable adjunct to conventional diagnostic processes. An effective mucormycosis treatment plan includes reversing or terminating underlying predisposing factors, early delivery of active antifungal drugs at appropriate doses, full excision of all diseased tissues, and the use of various adjuvant therapies (Hadiyanto et al. 2021). In recent years, significant progress has been made in the treatment of mucormycosis. Maintaining a high index of suspicion and actively biopsying suspicious lesions has become apparent, emphasizing the need for beginning therapy as soon as feasible. According to emerging data, surgical removal of sick and necrosed tissue is suggested whenever possible. Amphotericin B lipid formulations have become the usual therapy for mucormycosis due to their superior safety and efficacy. According to preclinical and limited retrospective clinical evidence, combining amphotericin lipid formulations with an echinocandin enhances mucormycosis survival (Najafi et al. 2019). Polyene should be used as the first antifungal therapy for mucormycosis. Although amphotericin B (AmB) deoxycholate has long been the gold standard for mucormycosis therapy, lipid formulations of AmB are significantly less nephrotoxic. They can be given in bigger dosages for longer periods of time

than AmB. The anti-mucormycosis activity of fluconazole, voriconazole, and itraconazole is inconsistent.

Prophylaxes

Pre- and post-exposure prophylaxes (PrEP and PEP) can help prevent HIV infection. However, the most vulnerable populations in sub-Saharan Africa, such as sex workers, are usually inaccessible and underutilized. Based on in-depth interviews conducted in Mombasa, Kenya, with 21 female and 23 male HIV-negative sex workers, we discovered that despite a solid willingness to utilize both, comprehension and expertise of PrEP and PEP were poor. Despite concerns about side effects, participants believed PrEP would empower them and give additional infection prevention. Even though PEP was widely available, few people were aware of it, and even fewer had used it; those who had, however, stated that they would do so again. Healthcare for sex workers required strict HIV/STI testing, as well as secrecy, anonymity, and a user-friendly website (Restar et al. 2017). Periodontitis can be slowed down using dental prophylaxis, which entails eliminating supragingival calculus and plaque. The impact of dental prophylaxis on T2DM patients' periodontitis was studied in a randomized controlled experiment.

Secondary prophylaxis

While primary prophylaxis for children with severe hemophilia is well-established and recommended, less study on the benefits of secondary prevention began in adolescence or adulthood (Tagliaferri et al. 2008). Prophylaxis is usually recommended to treat severe hemophilia A. Prophylaxis is utilized in less than half of extreme cases in the USA, even though it is widely employed in other countries. One indication is that many people with severe hemophilia are affected. Prophylaxis's potential benefits will only be realized if supplied to a community as secondary prophylaxis. The arthropathy of thirteen children with severe hemophilia was treated with frequent factor VIII or IX replacement infusions in this study. The children, who were 6.9 years old at the time (range 2.0–12.5), had an average of 43 acute hemorrhages (range 8–127) in the year preceding up to prophylaxis, with a mean of 24 (range 5–46) into joints. Five boys were given factor VIII concentrate (20 U/kg) three times each week, while one child was given factor IX concentrate (40 U/kg) twice per week. This dosage regimen was insufficient for three factor VIII-deficient boys and one factor IX secondary child. Two of the three factor VIII-deficient boys reacted to a 30 U/kg increase before the 3-day delay.

Fever-driven treatment

There is no single therapeutic strategy appropriate for all patients; for example, empirical antifungal medication may be advised for individuals at very high risk, while others at moderate risk may benefit from a preventative approach. Two antifungal drugs with different modes of action (echinocandins + azoles or polyenes, for example) could be combined to take advantage of their synergistic and additive effects. Assume there is much pharmacokinetic variability and the dose-concentration effect correlations are not evident. Therapeutic drug monitoring (TDM) of the medications should be examined once therapy has begun (e.g., for itraconazole, voriconazole, and posaconazole) (Candoni et al. 2012). Earlier antifungal therapy was linked to fluconazole non-susceptible strains, whereas previous echinocandin treatment was related to *C. parapsilosis*-related breakthrough candidemia (BrC). These findings must be considered while treating BrC experimentally (Cuervo et al. 2016). Invasive mold sickness is becoming more common among immunocompromised people. It is a hot topic of debate regarding the ideal time to use mold-active antifungal drugs. Current antifungal prophylaxis, early treatment, and proven mold infections in one hematology patient are discussed (Maertens et al. 2011).

Diagnosis-driven treatment

The reasons for comprehensive periodontal treatment, as well as the stages of treatment, are discussed. The phases naturally progress one after the other. Periodontal health, gingivitis, and periodontitis are the three major treatment groups that can be formed. Within the periodontitis group, the main ideas and techniques for treating chronic and aggressive periodontitis patients are entirely different. Gingivitis and chronic periodontitis results are largely predictable, and traditional non-surgical and surgical therapy can reduce inflammation, delay periodontal deterioration, and restore gingival periodontal health. Patients' motivation and upkeep are critical for long-term effects. It is harder to predict late treatment effects and aggressive periodontitis case maintenance. Regenerative surgical treatments, on the other hand, can completely restore the vertical component of bone loss. Because no periodontal regenerative therapy can replace the missing alveolar crest and interdental septa, the horizontal bone loss should be irreversible (Gera 2004). The purpose of this study was to see how successful and safe low-dose amphotericin B (AmB) was in treating using various antifungal techniques (Yang et al. 2017).

First-line antifungal monotherapy

Aspergillosis is an invasive fungal infection (IFI) that can be fatal in persons who have weakened immune systems. A fungus causes it, and it spreads throughout the body. In the 1990s, for example, the development and widespread use of fluconazole prophylaxis resulted in lower mortality from yeast infections. As a result, invasive aspergillosis has become the most prevalent IFI, especially among patients with hematological malignancies, solid organ transplantation, and allogeneic hematopoietic stem cell transplantation. Patients who are at risk of contracting aspergillosis are put on long-term immunosuppressive medicines (e.g., corticosteroids). Earlier reports of antifungal prophylaxis changes in lung transplant (LTx) recipients have been published, but the current therapeutic practice is unfamiliar. This research aimed to see what antifungal prophylactic techniques are currently being employed at LTx centers worldwide. Each active center's designated LTx clinician received an e-mail invitation to engage in a web-based survey between September 2009 and January 2010. A total of 57% of those asked (58/102) responded. Medical directors at LTx facilities in the USA provided most responses (72.4%). Most centers (58.6%) utilized universal prophylaxis within the first 6 months following LTx, with 97.1% targeting *Aspergillus* species. The first-line therapies were voriconazole alone and in combination with inhaled amphotericin B (AmB) (Neoh et al. 2011). A airway infection caused by bacteria and fungus characterizes cystic fibrosis (CF). Conditions with the *Scedosporium/Lomentospora* species are widespread and challenging to treat. Molds from the genus *Scedosporium/Lomentospora* are the most prevalent molds detected in CF patients' respiratory samples, second only to *Aspergillus* spp. This study aimed to explore antimycotic treatment options for *Scedosporium/Lomentospora* lung fungal infections in CF patients (Schwarz et al. 2019). The optimum treatment for mucormycosis is yet to be determined, thanks to the emergence of novel antifungals. In this study, the current management of mucormycosis and its effects were thoroughly examined (Jeong et al. 2019).

First-line antifungal combination therapy

This multicenter observational trial looked into the feasibility, effectiveness, and toxicity of antifungal combination therapy (combo) to treat confirmed or suspected invasive fungal diseases (IFDs) in patients with hematological malignancies (Candoni et al. 2014). Antifungal combination treatment is a novel approach to treating fungal infections in the clinic. The evidence from in vitro, experimental, and clinical trials is examined in this research to provide clinical answers for this exciting new therapy strategy (Fohrer et al. 2006). Invasive fungal infections (candidiasis, aspergillosis,

and cryptococcosis) cause severe morbidity and mortality in immunocompromised people. Except for cryptococcosis, invasive fungal infections are treated with single antifungal medicines based on randomized clinical studies or expert advice. The dismal prognosis of these infections has attracted antifungal associations' attention as a first- or second-line treatment, and a plethora of experimental data has been published on the subject. In humans, mainly HIV-positive persons, the combination therapy of amphotericin B and flucytosine for cryptococcal meningitis has been thoroughly validated. According to a few studies, fluconazole and amphotericin B are not antagonistic in candidiasis, and caspofungin plus polyene or caspofungin plus azole combinations may be helpful in invasive aspergillosis. Randomized investigations are required to verify these findings. Research on the effects of anidulafungin and voriconazole in the treatment of aspergillosis is currently being conducted (Gellen-Dautremer et al. 2009).

Antifungal salvage treatment

Posaconazole was given at a dose of 21 mg/kg (range 4.8–33.3) for 32 days (range 4–262). None of the patients stopped taking their medication because of side effects, which were largely minor and only happened to 11 of them. We feel that posaconazole has a high level of safety and tolerance and that it could be beneficial in treating individual pediatric patients with invasive infections based on the data (Lehrnbecher et al. 2010). There are now a variety of novel therapeutic options for dangerous fungal infections. All three echinocandin medicines now available effectively treat candidemia and invasive candidiasis in randomized, blinded clinical trials. In previously controlled salvage treatment trials in patients who had failed or were intolerant to conventional medication, echinocandins effectively treat invasive aspergillosis. Voriconazole and posaconazole, two new triazole antifungal medicines, provide a broad spectrum of antifungal activity. Invasive aspergillosis has traditionally been treated with voriconazole. Posaconazole appears to be successful in the treatment of zygomycosis based on compassionate treatment evidence. Non-*Aspergillus* mold infections, endemic mycoses, and severe *Candida* infections have been successfully treated with these medications (Kauffman 2006) (Karthika et al. 2022a).

Treatment duration for mucormycosis

Despite the addition of mold-active drugs (posaconazole and isavuconazole) to our armory against mucormycosis, there are still many unanswered concerns about treating this uncommon opportunistic infection. We cover the current state of therapy choices in this mini-review.

Mucormycosis treatment requires a tailored approach that takes into account the host's overall immunosuppression, as well as comorbidities, the certainty of diagnosis, infection site, and antifungal pharmacological properties, due to the disease's diversity (Sipsas et al. 2018). The Zygomycetes class is divided into two orders: Mucorales and Entomophthorales (Prabhu and Patel 2004). The Tunisian infectious disease department conducted research in 2000 and 2013 on four men and one lady, all of whom were in their 60 s. One of the patients had severe leukemia, while the other three had diabetes. Mucormycosis was discovered in rhinocerebral, rhinoorbital, auricular, pulmonary, and cutaneous mucormycosis. Mucorales *Rhizopus arrhizus* and *Lichtheimia* were found in three and two cases, respectively. Amphotericin B was given to all the patients, and two of them additionally had surgical debridement. Two patients died, while the other two were left with peripheral facial paralysis (Bellazreg et al. 2015).

Dexamethasone treatment

Dexamethasone's main anti-inflammatory impact was to stop a pro-inflammatory gene from triggering the acute inflammatory response (Saraya et al. 2012). Low doses of dexamethasone work via the genomic mechanism (Fig. 4) (Mitre-Aguilar et al. 2015), which takes longer and has fewer adverse effects; greater dosages, on the other hand, act quickly via non-genomic channels (Fig. 5) and have more side effects (Lecoq et al. 2009). Corticosteroids were found to be effective in both in vitro and in vivo against COVID-19 and pneumonia infections in clinical trials. Dexamethasone, the most common corticosteroid, was administered to treat the infection. Lower dosages, on the other hand, decreased mortality and were significant in individuals with severe COVID symptoms. However, because of the potential for damage at greater dosages, the therapy should be used with caution (Ahmed and Hassan 2020).

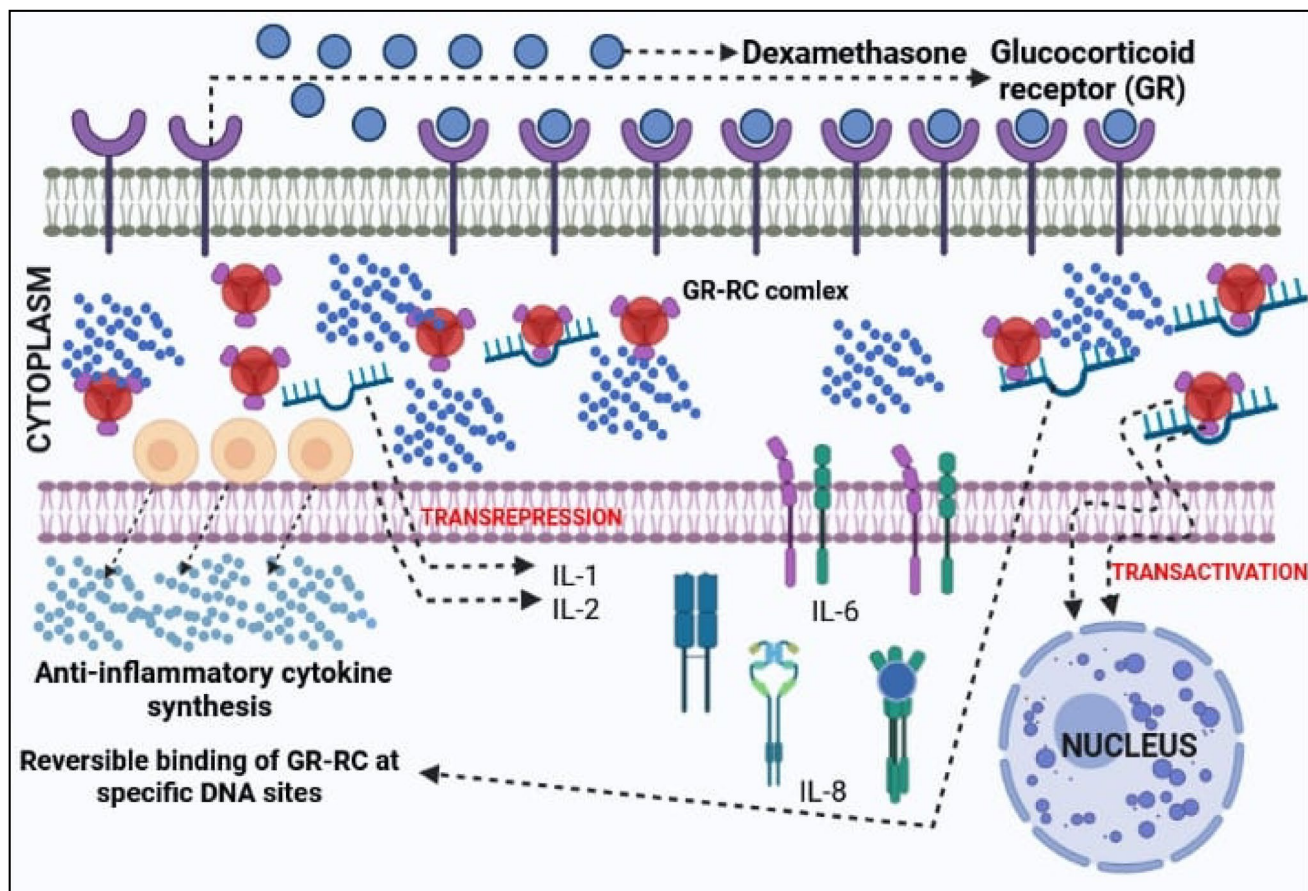


Fig. 4 Dexamethasone's typical genomic mechanism in COVID-19 corticosteroid treatment. Dexamethasone (DM) is a lipophilic substance that quickly diffuses over the cell membrane and into the cytoplasm. The glucocorticoid receptor (GR) on the cell membrane binds to DM, generating the glucocorticoid receptor complex (GR-RC), which allows corticosteroids to enter the cell. The GR-GC binds to

certain DNA (deoxyribonucleic acid) sequences, causing transactivation and transrepression to happen at the same time. TNF (tumor necrosis factor) and IFN (interferon)-gamma, as well as interleukins (IL-1, IL-2, IL-6, and IL-8) are inhibited, but anti-inflammatory cytokine production is increased

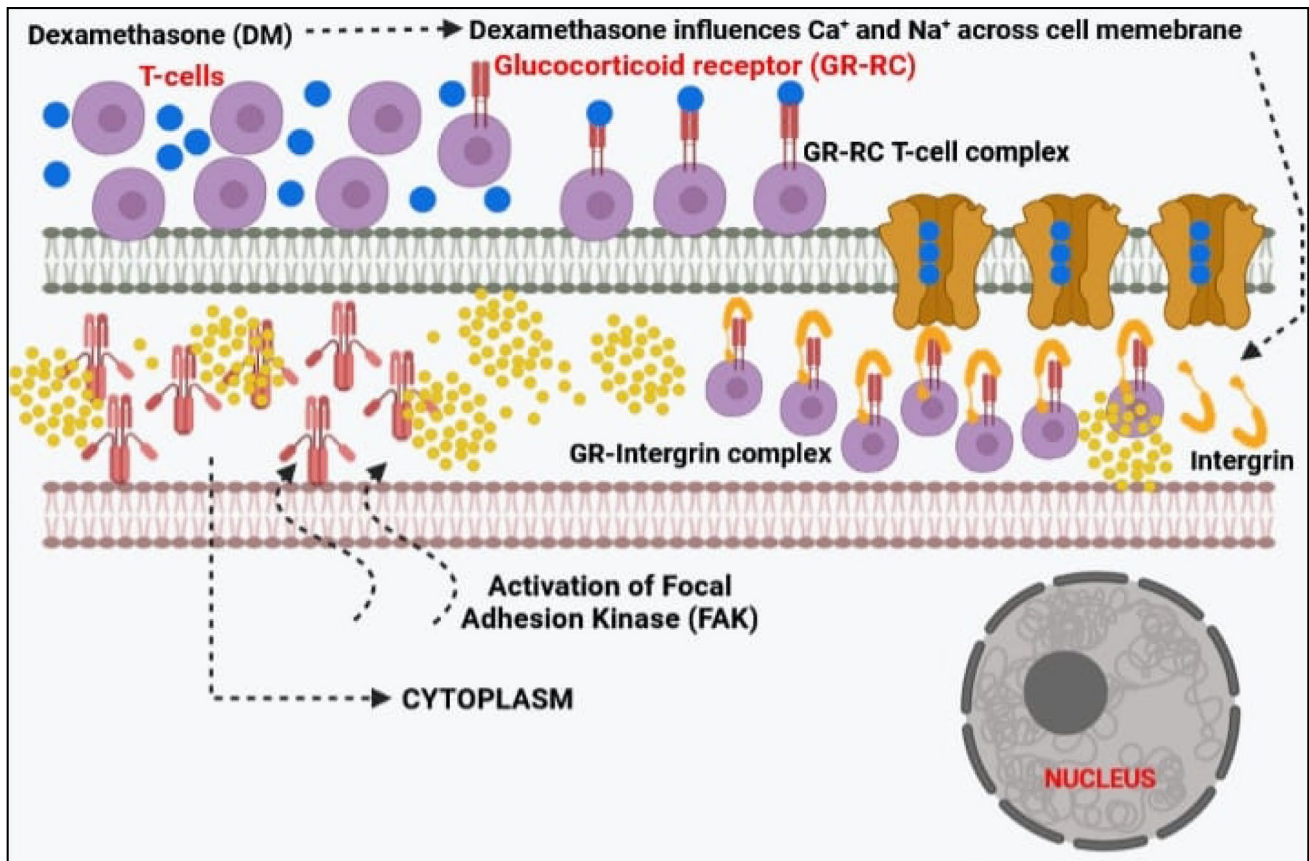


Fig. 5 Dexamethasone's typical non-genomic mechanism in COVID-19 corticosteroid treatment. A large dose of corticosteroids is necessary due to the severity of the illness. Dexamethasone (DM) binds to the membrane-associated glucocorticoid receptor (GR) on T lymphocytes at higher concentrations, lowering the immunological response

these cells generate. An integrin binds to the GR complex in the cytoplasm and activates focal adhesion kinase (FAK). Furthermore, high dosages of DM reduce inflammation via altering calcium and sodium ion active transport

Treatment pathways for mucormycosis

The point of entry is assumed to be the colonization of the nasal mucosa, which allows the fungus to travel into the orbit via the paranasal sinuses. Spheno-ethmoidectomy with or without maxillectomy appears to be the most successful treatment since the orbital apex is involved in the infection of the brain and cavernous sinus. We evaluated ten people with rhinocerebral mucormycosis in a prospective study from February 2000 to April 2004. Eleven individuals had clinically diagnosed rhinocerebral mucormycosis, with ten included in our survey after histological confirmation (Hosseini and Borghei 2005). Mucormycosis is a fungal infection with few therapeutic options that are becoming more common. Blocking EGFR signaling with FDA-approved medicines enhanced survival in mice infected with *R. arrhizus* var. *dilemma*. This research contributes to our knowledge of how the Mucorales fungus infiltrates host cells during lung mucormycosis and shows that FDA-approved EGFR inhibitors can be repurposed (Watkins et al. 2018).

Mortality and fatality case rate

Mucormycosis an uncommon but usually fatal illness. The case fatality rate (CFR) of mucormycosis varies depending on the underlying environments, health, and fungus type. Due to the disease's extreme rarity, it is difficult to determine the precise rates of morbidity and death for mucormycosis. But other earlier investigations revealed conflicting information about the CFR of mucormycosis (Table 1).

Estimated prevalence globally

It is difficult to get a sample from deep tissue, and because diagnostic techniques have a limited sensitivity, the actual incidence or prevalence of mucormycosis may be higher. The burden of major fungal diseases worldwide has been evaluated by the Leading International Fungal Education (LIFE) webpage (Table 2).

Table 1 Mucormycosis mortality or case fatality rate in various case studies throughout the world

Study number	Case fatality rate or mortality rate	References
1	Overall 64% (11/17)	Petrikkos et al. (2003a)
2	Overall 54% (501/929) - 96% (disseminated mucormycosis) - 85% (gastrointestinal mucormycosis) - 76% (pulmonary mucormycosis) - 46% (sinus infection)	Roden et al. (2005b)
3	32% (19/60) - 36% (immunocompromised) - 22% (immunocompetent) - 18% (treated with liposomal amphotericin B)	Pagano et al. (2009)
4	11.5% (61/531) - 47.8% (hematologic malignancies) - 36.4% (bone marrow transplantation)	Bitar et al. (2009)
5	53% (10/19) - 75% (antifungal treatment alone) - 14% (antifungal treatment and surgery)	Ambrosioni et al. (2010)
6	47% (108/230) - 76% (hematopoietic stem cell transplantation) - 58% (disseminated mucormycosis) - 56% (pulmonary mucormycosis) - 52% (hematologic malignancies) - 44% (diabetes)	Skiada et al. (2011b)
7	44% (44/101) - 25% (rhinocerebral mucormycosis) - 79% (disseminated mucormycosis) - 48% (pulmonary mucormycosis) - 22% (cutaneous mucormycosis)	Lanternier et al. (2012)

Conclusion and future perspectives

Rhinocerebral or craniofacial mucormycosis, formerly thought to be exclusive to diabetes, can now be found in immunocompromised patients as well as seemingly healthy people. Patients may not have a typical, unilateral acute sickness with black eschar, but this entity should be considered in the context of long-term, smoldering sinus symptomatology. The correct diagnosis is aided by clinical suspicion, which is supported by radiological investigations. To achieve a good outcome, immunosuppression and other predisposing factors must be controlled quickly, amphotericin B therapy must be started, and meticulous, extensive surgical debridement of the involved tissues and drainage of the focal collections in the orbit and cranial cavity must be performed. In some patients, orbital exenteration may help to improve illness management. Mucormycosis has become more common as a result of

the prolonged survival of debilitated patients, as well as greater therapeutic use of antibiotics and immunosuppressive drugs. Our increased understanding of this life-threatening ailment is the first step toward a better prognosis in this disease. Numerous organisms of the genera *Rhizopus*, *Mucor*, and *Lichtheimia* may cause mucormycosis because of the vast number of immunosuppressed patients. There is a strong correlation between COVID-19-associated mucormycosis (CAM) and pre-existing risk factors for the development of mucormycosis. Patients at risk from CAM include those with concurrent medical conditions like diabetes and those taking immunosuppressive drugs like steroids for treatment. Therefore, while treating COVID-19 patients who have risk factors for CAM, immunosuppressive drugs should be administered with caution and, if possible, avoided. To prevent the condition from worsening, a prompt diagnosis and course of medication should be started in COVID-19 patients if CAM is suspected.

Table 2 Burden of major fungal diseases worldwide as evaluated by LIFE

Country	Total population (in millions)	Total estimated fungal burden	Mucormycosis		Invasive aspergillosis		Reference
			Total burden	Rate/100 K	Total burden	Rate/100 K	
Algeria	40.4	568,942	79	0.2	2865	7.1	Chekiri-Talbi et al. (2017)
Argentina	43.8	881,023	75	0.17	2536	5.8	Sacarlal and Denning (2018)
Australia	23.57	693,708	21	0.06	560	3–29%	Prakash and Chakrabarti (2019)
Belgium	11.1	233,000	31	0.58	675	6.08	Bongomin et al. (2017)
Brazil	194.0	3,800,000	243	0.2	8664	4.47	Giacomazzi et al. (2016); Prakash and Chakrabarti (2019)
Cameroon	24.2	1,126,332	5	0.2	1175	5.3	Sacarlal and Denning (2018)
Canada	35.5	652,932	43	0.12	566	1.59	Dufresne et al. (2017); Prakash and Chakrabarti (2019)
Chile	17.5	325,036	35	0.2	296	1.7	Álvarez Duarte et al. (2017)
Colombia	49.3	760,808	99	0.2	2820	5.7	Alvarez-Moreno et al. (2018)
Czech Republic	10.5	176,073	22	0.2	297	2.8	Chrdle et al. (2015)
Denmark	5.6	894,430	1	0.02	294	5.3	Beardsley et al. (2015)
Dominican Republic	10.9	2,293,681	20	0.2	61	0.8	Gugnani et al. (2016)
France	65.8	968,143	79	0.12	1185	1.8	Gangneux et al. (2016)
Greece	10.8	194,067	7	0.06	1125	10.4	Gamaletsou et al. (2016)
India	1300.0	NA	171,504	14	NA	NA	Chakrabarti and Dhaliwal (2013)
Ireland	6.4	117,384	13	0.2	445	7	Dorgan et al. (2015)
Japan	127.0	2,370,314	254	0.2	1308	1	Prakash and Chakrabarti (2019)
Jordan	6.3	119,153	1	0.02	84	1.34	Wadi and Denning (2018)
Kazakhstan	17.7	300,824	16	0.09	511	2.8	Kemaykin et al. (2018)
Kenya	43.6	3,186,766	80	0.2	239	0.6	Guto et al. (2016)
Korea	48.0	985,079	68	0.14	2150	4.48	Huh et al. (2017)
Malawi	17.7	1,338,523	30	0.2	1186	6.7	Kalua et al. (2018)
Mexico	112.3	2,749,159	134	0.12	4510	4	Bongomin et al. (2017)
Nigeria	155	17,983,517	300	0.2	928	0.6	Bongomin et al. (2017)
Norway	5.2	839,087	7	0.1	278	5.3	Nordøy et al. (2018)
Pakistan	184.5	3,280,554	25,830	14	10,949	5.9	Jabeen et al. (2017)
Philippines	98.4	1,852,137	20	0.02	3085	3	Batac et al. (2017)
Portugal	10.6	1,695,514	10	9.5	240	2.3	Sabino et al. (2017)
Qatar	1.9	33,448	23	1.23	11	0.6	Alfouzan et al. (2020)
Romania	19.7	436,230	7	0.04	1524	7.7	Alvarez-Moreno et al. (2018)
Russia	142.9	3,082,907	232	0.16	3238	2.27	Klimko et al. (2015)
Serbia	7.1	156,825	23	0.33	619	8.8	Arsenijević and Denning (2018)
Spain	47.0	8,144,605	20	0.04	1293	2.75	Alastruey-Izquierdo et al. (2013)
Thailand	65.1	1,254,562	130	0.2	941	1.4	Chayakulkeeree et al. (2017)
Ukraine	45.5	999,152	90	0.1975	1233	2.7067	Bongomin et al. (2017)
UK	63.18	241,525–662,987	57	0.09	2901–2912	4.59–4.61	Pegorie et al. (2017)

Table 2 (continued)

Country	Total population (in millions)	Total estimated fungal burden	Mucormycosis		Invasive aspergillosis		Reference
			Total burden	Rate/100 K	Total burden	Rate/100 K	
USA	NA	NA	36	0.3	301	2.4	Webb et al. (2018)
Republic of Uzbekistan	30.7	536,978	27	0.08	1521	4.8	Tilavberdiev et al. (2017)

Acknowledgements This publication was supported by the Deanship of Scientific Research at Prince Sattam Bin Abdulaziz University, Al-Kharj, Saudi Arabia; the authors are sincerely grateful as well to Egyptian Russian University, Badr, Egypt, for its support.

Author contribution Conceptualization, methodology: Md. Rezaul Islam, Md. Mominur Rahman, Md. Habibur Rahman, Sherouk Hussein Sweilam, Md. Rezaul Islam; writing the original draft and methodology and collecting data, Md. Mominur Rahman, Md. Tanjimul Ahasan, Nadia Sarkar, Shopnil Akash, Fahadul Islam, Most. Nazmin Aktar, Mohd Saeed, Md. Harun-Or-Rashid, Md. Kawser Hosain, Md. Saidur Rahaman, Sadia Afroz, Shabana Bibi, Md. Habibur Rahman. All authors approved submitting the final manuscript.

Data availability Not applicable.

Declarations

Ethical approval Not applicable.

Consent to participate Not applicable.

Consent for publication Not applicable.

Competing interests The authors declare no competing interests.

References

- Afroze SN, Korlepara R, Rao GV, Madala J (2017) Mucormycosis in a diabetic patient: a case report with an insight into its pathophysiology. *Contemp Clin Dent* 8(4):662
- Ahmed MH, Hassan A (2020) Dexamethasone for the treatment of coronavirus disease (COVID-19): a review. *SN Compr Clin Med* 2(12):2637–2646
- Akter R, Rahman M, Bhattacharya T, Kaushik D, Mittal V, Parashar J, Kumar K, Kabir M, Tagde P (2021a) Novel coronavirus pathogen in humans and animals: an overview on its social impact, economic impact, and potential treatments. *Environ Sci Pollut Res*:1–19
- Akter R, Rahman MH, Kaushik D, Mittal V, Uivarosan D, Nechifor AC, Behl T, Karthika C, Stoicescu M, Munteanu MA (2021b) Chemo-preventive action of resveratrol: suppression of p53—a molecular targeting approach. *Molecules* 26(17):5325
- Al-Harrasi A, Behl T, Upadhyay T, Chigurupati S, Bhatt S, Sehgal A, Bhatia S, Singh S, Sharma N, Vijayabalan S (2022a) Targeting natural products against SARS-CoV-2. *Environ Sci Pollut Res* 1–29
- Al-Harrasi A, Behl T, Upadhyay T, Chigurupati S, Bhatt S, Sehgal A, Bungau S (2022) Targeting natural products against SARS-CoV-2. *Environ Sci Pollut Res* 1–29
- Alastruey-Izquierdo A, Mellado E, Peláez T, Pemán J, Zapico S, Alvarez M, FILPOP Study Group (2013) Population-based survey of filamentous fungi and antifungal resistance in Spain (FILPOP Study). *Antimicrob Agents Chemother* 57(7):3380–3387
- Alfouzan W, Al-Wathiqi F, Altawalah H, Asadzadeh M, Khan Z, Denning DW (2020) Human Fungal Infections in Kuwait—Burden and Diagnostic Gaps. *J Fungi* 6(4):306
- Alvarez-Moreno CA, Cortes JA, Denning DW (2018). Burden of fungal infections in Colombia. *4(2):41*
- Álvarez Duarte E, Denning DW (2017) Serious fungal infections in Chile. *Eur J Clin Microbiol Infect Dis* 36(6):983–986
- Ambrosioni J, Bouchuiguir-Wafa K, Garbino J (2010) Emerging invasive zygomycosis in a tertiary care center: epidemiology and associated risk factors. *Int J Infect Dis* 14:e100–e103
- Antinori S, Nebuloni M, Magni C, Fasan M, Adorni F, Viola A, Corbellino M, Galli M, Vago G, Parravicini C (2009) Trends in the postmortem diagnosis of opportunistic invasive fungal infections in patients with AIDS: a retrospective study of 1,630 autopsies performed between 1984 and 2002. *Am J Clin Pathol* 132(2):221–227
- Apicella M, Campopiano MC, Mantuano M, Mazoni L, Coppelli A, Del Prato S (2020) COVID-19 in people with diabetes: understanding the reasons for worse outcomes. *Lancet Diabetes Endocrinol* 8(9):782–792
- Arce-Salinas CA, Pérez-Silva E (2010) Mucormycosis complications in systemic lupus erythematosus. *Lupus* 19(8):985–988
- Arnáiz-García ME, Alonso-Peña D, del Carmen González-Vela M, García-Palomo JD, Sanz-Giménez-Rico JR, Arnáiz-García AM (2009) Cutaneous mucormycosis: report of five cases and review of the literature. *J Plast Reconstr Aesthet Surg* 62(11):e434–e441
- Arsenijević VA, Denning DW (2018) Estimated burden of serious fungal diseases in Serbia. *J Fungi* 4(3):76
- Artis WM, Fountain JA, Delcher HK, Jones HE (1982) A mechanism of susceptibility to mucormycosis in diabetic ketoacidosis transferrin and iron availability. *Diabetes* 31(12):1109–1114
- Auluck A (2007) Maxillary necrosis by mucormycosis: A case report and literature review. *Medicina Oral Patología Oral y Cirugía Bucal (Internet)* 12(5):360–364
- Badiee P, Hashemizadeh Z (2014) Opportunistic invasive fungal infections: diagnosis & clinical management. *Indian J Med Res* 139(2):195
- Bassetti M, Garnacho-Montero J, Calandra T, Kullberg B, Dimopoulos G, Azoulay E, Cornely OA (2017) Intensive care medicine research agenda on invasive fungal infection in critically ill patients. *Intensive Care Med* 43(9):1225–1238
- Batac MCR, Denning D (2017) Serious fungal infections in the Philippines. *Eur J Clin Microbiol Infect Dis* 36(6):937–941
- Beardsley J, Denning DW, Chau NV, Yen NTB, Crump JA, Day JN (2015) Estimating the burden of fungal disease in Vietnam. *Mycoses* 58:101–106
- Behl T, Kaur I, Bungau S, Kumar A, Uddin MS, Kumar C, Pal G, Shrivastava K, Zengin G, Arora S (2020) The dual impact of ACE2 in COVID-19 and ironical actions in geriatrics and pediatrics with possible therapeutic solutions. *Life Sci* 257:118075
- Behl T, Kaur I, Sehgal A, Singh S, Sharma N, Anwer MK, Makeen HA, Albratty M, Alhazmi HA, Bhatia S (2022a) There is

- nothing exempt from the peril of mutation—the Omicron spike. *Biomed Pharmacother* 148:112756
- Behl T, Kaur I, Sehgal A, Singh S, Sharma N, Anwer MK, Makeen HA, Albratty M, Alhazmi HA, Bhatia S (2022b) There is nothing exempt from the peril of mutation—The Omicron spike. 148:112756
- Bellazreg F, Hattab Z, Meksi S, Mansouri S, Hachfi W, Kaabia N, Letaief A (2015) Outcome of mucormycosis after treatment: report of five cases. *New Microbes New Infect* 6:49–52
- Benjamin SPE (2009) Primary gastric mucormycosis: role of preexisting ulcerative and erosive lesions. *J Postgrad Med* 55(1):73–73
- Bhattacharya T, Dutta S, Akter R, Rahman MH, Karthika C, Nagaswarupa HP, Murthy HCA, Fratila O, Brata R, Bungau S (2021) Role of phytonutrients in nutrigenetics and nutrigenomics perspective in curing breast cancer. *Biomolecules* 11(8):1176
- Bitar D, Van Cauteren D, Lanternier F, Dannaoui E, Che D, Dromer F, Desenclos J-C, Lortholary O (2009) Increasing incidence of zygomycosis (mucormycosis), France, 1997–2006. 15(9):1395
- Blatt SP, Lucey DR, DeHoff D, Zellmer RB (1991) Rhinocerebral zygomycosis in a patient with AIDS. *J Infect Dis* 164(1):215–215
- Boelaert JR, de Locht M, Van Cutsem J, Kerrels V, Cantinieaux B, Verdonck A, Van Landuyt HW, Schneider Y-J (1993) Mucormycosis during deferoxamine therapy is a siderophore-mediated infection. In vitro and in vivo animal studies. *J Clin Invest* 91(5):1979–1986
- Boelaert JR, Fenves AZ, Coburn JW (1991) Deferoxamine therapy and mucormycosis in dialysis patients: report of an international registry. *Am J Kidney Dis* 18(6):660–667
- Boiko DI, Skrypnikov AM, Shkodina AD, Hasan MM, Ashraf GM, Rahman M (2022) Circadian rhythm disorder and anxiety as mental health complications in post-COVID-19. *Environ Sci Pollut Res* 29(19):28062–28069
- Bongomin F., Gago, S., Oladele, R. O., & Denning, D. W. (2017). Global and multi-national prevalence of fungal diseases—estimate precision. *J Fungi* 3(4):57
- Candoni A, Caira M, Cesaro S, Busca A, Giacchino M, Fanci R, SEIFEM Group (Sorveglianza Epidemiologica Infezioni Fungine nelle Emopatie Maligne) (2014) Multicentre surveillance study on feasibility, safety and efficacy of antifungal combination therapy for proven or probable invasive fungal diseases in haematological patients: the SEIFEM real-life combo study. *Mycoses* 57(6):342–350
- Candoni A, Pagano L, Scaglione F, Viscoli C (2012) Prophylaxis and treatment of invasive fungal infections in hematological patients. *Rev Health Care* 3(1S):27–40
- Chahal R, Nanda A, Akkol EK, Sobarzo-Sánchez E, Arya A, Kaushik D, Dutt R, Bhardwaj R, Rahman MH, Mittal V (2021) *Ageratum conyzoides* L. and its secondary metabolites in the management of different fungal pathogens. *Molecules* 26(10):2933
- Chakrabarti A, Das A, Mandal J, Shivaprakash MR, George VK, Tarai B, Sakhuja V (2006) The rising trend of invasive zygomycosis in patients with uncontrolled diabetes mellitus. *Sabouraudia* 44(4):335–342
- Chakrabarti A, Dhaliwal M (2013) Epidemiology of mucormycosis in India. *Current Fungal Infection Reports* 7(4):287–292
- Chamilos G, Lewis RE, Kontoyiannis DP (2008) Delaying amphotericin B-based frontline therapy significantly increases mortality among patients with hematologic malignancy who have zygomycosis. *Clin Infect Dis* 47(4):503–509
- Chander J (2017) Textbook of medical mycology. JP Medical Ltd
- Chang J, Chan D, Pada S, Tambyah PA (2020) Coinfection with COVID-19 and coronavirus HKU1—the critical need for repeat testing if clinically indicated. *J Med Virol* 92(10):1785
- Chayakulkeeree M, Denning DW (2017) Serious fungal infections in Thailand. *Eur J Clin Microbiol Infect Dis* 36(6):931–935
- Chekiri-Talbi M, Denning DW (2017) Burden of fungal infections in Algeria. *Eur J Clin Microbiol Infect Dis* 36(6):999–1004
- Chowdhary A, Tarai B, Singh A, Sharma A (2020) Multidrug-resistant *Candida auris* infections in critically ill coronavirus disease patients, India, April–July 2020. 26(11):2694
- Chrdle A, Mallátová NA, Vašáková M, Haber J, Denning DW (2015) Burden of serious fungal infections in the Czech Republic. *Mycoses* 58:6–14
- Cornely OA, Alastruey-Izquierdo A, Arenz D, Chen SC, Dannaoui E, Hochhegger B, Hoenigl M, Jensen HE, Lagrou K, Lewis RE (2019) Global guideline for the diagnosis and management of mucormycosis: an initiative of the European Confederation of Medical Mycology in cooperation with the Mycoses Study Group Education and Research Consortium. *Lancet Infect Dis* 19(12):e405–e421
- Cornu M, Bruno B, Loridant S, Navarin P, François N, Lanternier F, Amzallag-Bellenger E, Dubos F, Mazingue F, Sendid B (2018) Successful outcome of disseminated mucormycosis in a 3-year-old child suffering from acute leukaemia: the role of isavuconazole? A case report. *BMC Pharmacol Toxicol* 19(1):1–5
- Cuervo G, Garcia-Vidal C, Nucci M, Puchades F, Fernández-Ruiz M, Obed M, Manzur A, Gudiol C, Pemán J, Aguado J (2016) Break-through candidaemia in the era of broad-spectrum antifungal therapies. *Clin Microbiol Infect* 22(2):181–188
- Daly AL, Velazquez LA, Bradley SF, Kauffman CA (1989) Mucormycosis: association with deferoxamine therapy. *Am J Med* 87(4):468–471
- De Locht M, Boelaert JR, Schneider Y-J (1994) Iron uptake from ferrioxamine and from ferrirrhizoferrin by germinating spores of *Rhizopus microsporus*. *Biochem Pharmacol* 47(10):1843–1850
- Deutsch PG, Whittaker J, Prasad S (2019) Invasive and non-invasive fungal rhinosinusitis—a review and update of the evidence. *Medicina* 55(7):319
- Ding Q, Lu P, Fan Y, Xia Y, Liu M (2020) The clinical characteristics of pneumonia patients coinfecting with 2019 novel coronavirus and influenza virus in Wuhan China. *J Med Virol* 92(9):1549–1555
- Dong E, Du H, Gardner L (2020) An interactive web-based dashboard to track COVID-19 in real time. *Lancet Infect Dis* 20(5):533–534
- Dorgan E, Denning DW, McMullan R (2015) Burden of fungal disease in Ireland. *J Med Microbiol* 64(4):423–426
- Dufresne SF, Cole DC, Denning DW, Sheppard DC (2017) Serious fungal infections in Canada. *Eur J Clin Microbiol Infect Dis* 36(6):987–992
- Eastwood M, Nyhlin H (1995) Beeturia and colonic oxalic acid. *QJM: an Int J Med* 88(10):711–717
- Ezeokoli O, Pohl C (2020) Opportunistic pathogenic fungal coinfections are prevalent in critically ill COVID-19 patients: are they risk factors for disease severity? *SAMJ: South Afr Med J* 110(11):1081–1085
- Fatima M, Iqbal MK, Iqbal A, Kaur H, Gilani SJ, Rahman M, Ahmadi A, Rizwanullah M (2022) Current insight into the therapeutic potential of phytocompounds and their nanoparticle-based systems for effective management of lung cancer. *Anti-Cancer Agents Med Chem (formerly Current Medicinal Chemistry-Anti-Cancer Agents)* 22(4):668–686
- Federation ID. List of countries and territories in South-East Asia with members. Available via <https://idf.org/our-network/regions-members/south-east-asia/membershtml2020> (Accessed 23 June 2021)
- Fohrer C, Fornecker L, Nivoix Y, Cornila C, Marinescu C, Herbrecht R (2006) Antifungal combination treatment: a future perspective. *Int J Antimicrob Agents* 27:25–30

- Gamaletsou MN, Drogari-Apiranthitou M, Denning DW, Sipsas NV (2016) An estimate of the burden of serious fungal diseases in Greece. *Eur J Clin Microbiol Infect Dis* 35(7):1115–1120
- Gambhir RS, Aggarwal A, Bhardwaj A, Kaur A, Sohi RK, Mehta S (2021) COVID-19 and mucormycosis (black fungus): an epidemic within the pandemic. *Roczniki Państwowego Zakładu Higieny* 72(3)
- Gandhi RT, Lynch JB, Del Rio C (2020) Mild or moderate Covid-19. *New England J Med* 383(18):1757–1766
- Gangneux J-P, Bougnoux M-E, Dannaoui E, Cornet M, Zahar J (2020) Invasive fungal diseases during COVID-19: we should be prepared. *J De Mycol Med* 30(2):100971
- Gangneux JP, Bougnoux ME, Hennequin C, Godet C, Chandennier J, Denning DW, Dupont B (2016) An estimation of burden of serious fungal infections in France. *J Mycol Med* 26(4):385–390
- Garg D, Muthu V, Sehgal IS, Ramachandran R, Kaur H, Bhalla A, Agarwal R (2021) Coronavirus disease (Covid-19) associated mucormycosis (CAM): case report and systematic review of literature. *Mycopathologia* 186(2):289–298
- Gellen-Dautremier J, Lanternier F, Dannaoui E, Lortholary O (2009) Antifungal combination therapy in invasive fungal infections. *La Revue de Med Int* 31(1):72–81
- Georgopoulou S, Kounougeri E, Katsenos C, Rizos M, Michalopoulos A (2003) Rhinocerebral mucormycosis in a patient with cirrhosis and chronic renal failure. *Hepato-gastroenterology* 50(51):843–845
- Gera I (2004) The stages of comprehensive periodontal therapy–diagnosis-driven treatment planning. *Fogorv Sz* 97(3):103–111
- Giacomazzi J, Baethgen L, Carneiro LC, Millington MA, Denning DW, Colombo AL, In Association with the LIFE Program (2016) The burden of serious human fungal infections in Brazil. *Mycoses* 59(3):145–150
- Goldstein EJ, Spellberg B, Walsh TJ, Kontoyiannis DP, Edwards J Jr, Ibrahim AS (2009) Recent advances in the management of mucormycosis: from bench to bedside. *Clin Infect Dis* 48(12):1743–1751
- Gómez-Camarasa C, Rojo-Martín MD, Miranda-Casas C, Alastruey-Izquierdo A, Aliaga-Martínez L, Labrador-Molina JM, Navarro-Marí JM (2014) Disseminated infection due to *Saksenaia vasiformis* secondary to cutaneous mucormycosis. *Mycopathologia* 177(1–2):97–101
- Goyal R, Bala R, Sindhu RK, Zehravi M, Madaan R, Ramproshad S, Mondal B, Dey A, Rahman M, Cavalu S (2022) Bioactive based nanocarriers for the treatment of viral infections and SARS-CoV-2. *Nanomaterials* 12(9):1530
- Gugnani HC, Denning DW (2016) Burden of serious fungal infections in the Dominican Republic. *J Infect Publ Health* 9(1):7–12
- Guto JA, Bii CC, Denning DW (2016) Estimated burden of fungal infections in Kenya. *J Infect Dev Ctries* 10(08):777–784
- Hadiyanto JN, Wilda F, Cahyadi A, Adisuhanto M (2021) The ‘black fungus’ co-infection in COVID-19 patients: a review. *Indonesian J Trop Infect Dis* 9(2):126–136
- Hamilos G, Samonis G, Kontoyiannis DP (2011) Pulmonary mucormycosis. In *Seminars in respiratory and critical care medicine* (Vol. 32, No. 06, pp. 693–702). © Thieme Medical Publishers
- Hemsley C, Kibbler C (2008) Fungal infections. *Hematopoietic Stem Cell Transplantation in Clinical Practice*. Elsevier Health Sciences
- Hibbett DS, Binder M, Bischoff JF, Blackwell M, Cannon PF, Eriksson OE, Zhang N (2007) A higher-level phylogenetic classification of the Fungi. *Mycol Res* 111(5):509–547
- Hirabayashi KE, Idowu OO, Kalin-Hajdu E, Oldenburg CE, Brodie FL, Kersten RC, Vagefi MR (2019) Invasive fungal sinusitis: risk factors for visual acuity outcomes and mortality. *Ophthalmic Plast Reconstr Surg* 35(6):535–542
- Hoenigl M, Seidel D, Carvalho A, Rudramurthy SM, Arastehfar A, Gangneux JP, Chakrabarti A (2022) The emergence of COVID-19 associated mucormycosis: a review of cases from 18 countries. *Lancet Microbe*
- Hoeprich PD (1995) Antifungal chemotherapy. *Progress in Drug Research/Fortschritte der Arzneimittelforschung/Progrès des recherches pharmaceutiques* 87–127
- Hosseini SMS, Borghei P (2005) Rhinocerebral mucormycosis: pathways of spread. *Eur Arch Oto-Rhino-Laryngology Head Neck* 262(11):932–938
- Hosseini SMS, Borghei P (2005) Rhinocerebral mucormycosis: pathways of spread. *Eur Arch Oto-Rhino-Laryngol Head Neck* 262(11):932–938
- Howard DH (1999) Acquisition, transport, and storage of iron by pathogenic fungi. *Clin Microbiol Rev* 12(3):394–404
- Huang C, Wang Y, Li X, Ren L, Zhao J, Hu Y, Zhang L, Fan G, Xu J, Gu X (2020) Clinical features of patients infected with 2019 novel coronavirus in Wuhan, China. *Lancet* 395(10223):497–506
- Hughes S, Troise O, Donaldson H, Mughal N, Moore LS (2020) Bacterial and fungal coinfection among hospitalized patients with COVID-19: a retrospective cohort study in a UK secondary-care setting. *Clin Microbiol Infect* 26(10):1395–1399
- Huh K, Ha YE, Denning DW, Peck KR (2017) Serious fungal infections in Korea. *Eur J Clin Microbiol Infect Dis* 36(6):957–963
- Huq AM, Hossain MG, Islam MS, Sobur MA, Taufiqer AMM, Rahman M, Rahman T (n. d.) Mucormycosis (black fungus) and its impact on the COVID-19 patients: An updated review
- Hurt MA, Weedon D (2012) *Weedon’s skin pathology*. London: Churchill Livingstone Elsevier, 2010. *Dermatol Pract Concept* 2(1):79
- Ibrahim A, Spellberg B, Edwards J Jr (2008) Iron acquisition: a novel prospective on mucormycosis pathogenesis and treatment. *Curr Opin Infect Dis* 21(6):620
- Ibrahim AS, Edwards JE Jr, Fu Y, Spellberg B (2006) Deferiprone iron chelation as a novel therapy for experimental mucormycosis. *J Antimicrob Chemother* 58(5):1070–1073
- Ibrahim AS, Gebermariam T, Fu Y, Lin L, Husseiny MI, French SW, Schwartz J, Skory CD, Edwards JE, Spellberg BJ (2007) The iron chelator deferasirox protects mice from mucormycosis through iron starvation. *J Clin Investig* 117(9):2649–2657
- Ibrahim AS, Gebremariam T, Lin L, Luo G, Husseiny MI, Skory CD, Fu Y, French SW, Edwards J, John E, Spellberg B (2010) The high affinity iron permease is a key virulence factor required for *Rhizopus oryzae* pathogenesis. *Mol Microbiol* 77(3):587–604
- Jabeen K, Farooqi J, Mirza S, Denning D, Zafar A (2017) Serious fungal infections in Pakistan. *Eur J Clin Microbiol Infect Dis* 36(6):949–956
- Jalal K, Khan K, Basharat Z, Abbas MN, Uddin R, Ali F, Khan SA (2022) Reverse vaccinology approach for multi-epitope centered vaccine design against delta variant of the SARS-CoV-2. *Environ Sci Pollut Res* :1–19
- Jensen HE, Salonen J, Ekfors TO (1997) The use of immunohistochemistry to improve sensitivity and specificity in the diagnosis of systemic mycoses in patients with haematological malignancies. *J Pathol: A Journal of the Pathological Society of Great Britain and Ireland* 181(1):100–105
- Jeong W, Keighley C, Wolfe R, Lee WL, Slavin MA, Chen SC, Kong DC (2019) Contemporary management and clinical outcomes of mucormycosis: a systematic review and meta-analysis of case reports. *Int J Antimicrob Agents* 53(5):589–597
- John TM, Jacob CN, Kontoyiannis DP (2021) When uncontrolled diabetes mellitus and severe COVID-19 converge: the perfect storm for mucormycosis. *J Fungi* 7(4):298
- Jung WH, Sham A, Lian T, Singh A, Kosman DJ, Kronstad JW (2008) Iron source preference and regulation of iron uptake in *Cryptococcus neoformans*. *PLoS Pathog* 4(2):e45

- Kabir M, Ferdous Mitu J, Akter R, Akhtar MF, Saleem A, Al-Harrasi A, Bhatia S, Rahman M, Damiri F, Berrada M (2022) Therapeutic potential of dopamine agonists in the treatment of type 2 diabetes mellitus. *Environ Sci Pollut Res* 1–20
- Kalua K, Zimba B, Denning DW (2018) Estimated burden of serious fungal infections in Malawi. *J Fungi* 4(2):61
- Karthika C, Appu AP, Akter R, Rahman M, Tagde P, Ashraf GM, Abdel-Daim MM, Abid A, Bungau S (2022a) Potential innovation against Alzheimer's disorder: a tricomponent combination of natural antioxidants (vitamin E, quercetin, and basil oil) and the development of its intranasal delivery. *Environ Sci Pollut Res* 1–16
- Karthika C, Sureshkumar R, Zehravi M, Akter R, Ali F, Ramproshad S, Mondal B, Kundu MK, Dey A, Rahman M (2022b) Multidrug resistance in cancer cells: focus on a possible strategy plan to address colon carcinoma cells. *Life* 12(6):811
- Karthika C, Swathy Krishna R, Rahman M, Akter R, Kaushik D (2021) COVID-19, the firestone in 21st century: a review on coronavirus disease and its clinical perspectives. *Environ Sci Pollut Res* 28(46):64951–64966
- Kauffman CA (2006) Clinical efficacy of new antifungal agents. *Curr Opin Microbiol* 9(5):483–488
- Kaur I, Behl T, Aleya L, Rahman H, Kumar A, Arora S, Bulbul IJ (2021) Artificial intelligence as a fundamental tool in management of infectious diseases and its current implementation in COVID-19 pandemic. *Environ Sci Pollut Res* 28(30):40515–40532
- Kemaykin VM, Tabinbaev NB, Khudaibergenova MS, Olifirovich AA, Abdrakhmanova LM, Denning DW, Klimko N (2018) An estimate of severe and chronic fungal diseases in the Republic of Kazakhstan. *J Fungi* 4(1):34
- Khan A, Ema NT, Rakhi NN, Saha O, Rahaman MM (2021) Parallel Outbreaks of Deadly Pathogens (SARS-CoV-2, H5N8, EVD, Black fungi) around the World in 2021: Priorities for Achieving Control with Socio-Economic and Public Health Impact
- Kim D, Quinn J, Pinsky B, Shah NH, Brown I (2020) Rates of coinfection between SARS-CoV-2 and other respiratory pathogens. *JAMA* 323(20):2085–2086
- Klimko N, Kozlova Y, Khostelidi S, Shadrivova O, Borzova Y, Burygina E, Denning DW (2015) The burden of serious fungal diseases in Russia. *Mycoses* 58:58–62
- Koehler P, Bassetti M, Chakrabarti A, Chen SC, Colombo AL, Hoenigl M, Klimko N, Lass-Flörl C, Oladele RO, Vinh DC (2020) Defining and managing COVID-19-associated pulmonary aspergillosis: the 2020 ECMAM/ISHAM consensus criteria for research and clinical guidance. *Lancet Infect Dis*
- Kohn R, Hepler R (1985) Management of limited rhino-orbital mucormycosis without exenteration. *Ophthalmology* 92(10):1440–1444
- Kohne E (2011) Hemoglobinopathies: clinical manifestations, diagnosis, and treatment. *Deutsches Ärzteblatt International* 108(31–32):532
- Kumer A, Chakma U, Matin MM, Akash S, Chando A, Howlader D (2021) The computational screening of inhibitor for black fungus and white fungus by D-glucofuranose derivatives using in silico and SAR study. *Organic Commun* 14(4)
- KVIJAYAN AV (2019) RHINO ORBITO CEREBRAL MUCORMYCOSIS (ROCM)-A Retrospective analysis of 31 patients. *University Journal of Surgery and Surgical Specialities* 5(4)
- Lanternier F, Dannaoui E, Morizot G, Elie C, Garcia-Hermoso D, Huerre M, Bitar D, Dromer F, Lortholary O (2012) A global analysis of mucormycosis in France: the RetroZygo Study (2005–2007). *54(suppl_1):S35–S43*
- Lecoq L, Vincent P, Lavoie-Lamoureux A, Lavoie JP (2009) Genomic and non-genomic effects of dexamethasone on equine peripheral blood neutrophils. *Vet Immunol Immunopathol* 128(1–3):126–131
- Lee FY, Mossad SB, Adal KA (1999) Pulmonary mucormycosis: the last 30 years. *Arch Intern Med* 159(12):1301–1309
- Lehrnbecher T, Attarbaschi A, Duerken M, Garbino J, Gruhn B, Kontny U, Groll AH (2010) Posaconazole salvage treatment in paediatric patients: a multicentre survey. *Eur J Clin Microbiol Infect Dis* 29(8):1043–1045
- Lewis RE, Pongas GN, Albert N, Ben-Ami R, Walsh TJ, Kontoyianis DP (2011) Activity of deferasirox in Mucorales: influences of species and exogenous iron. *Antimicrob Agents Chemother* 55(1):411–413
- Lin E, Moua T, Limper AH (2017) Pulmonary mucormycosis: clinical features and outcomes. *Infection* 45(4):443–448
- Ma L-J, Ibrahim AS, Skory C, Grabherr MG, Burger G, Butler M, Elias M, Idrum A, Lang BF, Sone T (2009) Genomic analysis of the basal lineage fungus *Rhizopus oryzae* reveals a whole-genome duplication. *PLoS Genet* 5(7):e1000549
- Maedler-Kron C, Marcus VA, Michel RP (2016) Hematopoietic stem cell transplantation. In *Pathology of transplantation*. Springer, pp. 401–449
- Maertens J, Demuynck H, Verbeken E, Zachee P, Verhoef G, Vandenberghe P, Boogaerts M (1999) Mucormycosis in allogeneic bone marrow transplant recipients: report of five cases and review of the role of iron overload in the pathogenesis. *Bone Marrow Transplant* 24(3):307–312
- Maertens J, Groll AH, Cordonnier C, de la Cámara R, Roilides E, Marchetti O (2011) Treatment and timing in invasive mould disease. *J Antimicrob Chemother* 66(suppl_1):i37–i43
- Maniruzzaman M, Islam M, Ali M, Mukerjee N, Maitra S, Kamal MA, Ghosh A, Castrosanto MA, Alexiou A, Ashraf GM (2022) COVID-19 diagnostic methods in developing countries. *Environ Sci Pollut Res* :1–14
- Marr KA, Platt A, Tornheim JA, Zhang SX, Datta K, Cardozo C, Garcia-Vidal C (2021) Aspergillosis complicating severe coronavirus disease. *Emerg Infect Dis* 27(1):18
- Marty FM, Cosimi LA, Baden LR (2004) Breakthrough zygomycosis after voriconazole treatment in recipients of hematopoietic stem-cell transplants. *N Engl J Med* 350(9):950–952
- Maurer JR, Tullis DE, Grossman RF, Vellend H, Winton TL, Patterson GA (1992) Infectious complications following isolated lung transplantation. *Chest* 101(4):1056–1059
- Mazumdar R, Rahman M, Rahman M, Chowdhury M, Hossain M, Ahmed M, Gupta P (2016) Phytochemical and pharmacological investigation of *Polyalthia suberosa* Roxb. *Int J Innov Pharm Sci Res* 4(7):693–708
- McNab AA, McKelvie P (1997) Iron overload is a risk factor for zygomycosis. *Arch Ophthalmol* 115(7):919–921
- McNulty JS (1982) Rhinocerebral mucormycosis: predisposing factors. *Laryngoscope* 92(10):1140–1143
- Mekonnen ZK, Ashraf DC, Jankowski T, Grob SR, Vagefi MR, Kersten RC, Simko JP, Winn BJ (2021) Acute invasive rhino-orbital mucormycosis in a patient with COVID-19-associated acute respiratory distress syndrome. *Ophthalmic Plast Reconstr Surg* 37(2):e40
- Meyer RD, Kaplan MH, Ong M, Armstrong D (1973) Cutaneous lesions in disseminated mucormycosis. *JAMA* 225(7):737–738
- Mirzaei R, Goodarzi P, Asadi M, Soltani A, Aljanabi HAA, Jeda AS, Dashtbin S, Jalalifar S, Mohammadzadeh R, Teimoori A (2020) Bacterial co-infections with SARS-CoV-2. *IUBMB Life* 72(10):2097–2111
- Mitre-Aguilar IB, Cabrera-Quintero AJ, Zentella-Dehesa A (2015) Genomic and non-genomic effects of glucocorticoids: implications for breast cancer. *8(1):1*
- Mok CC, Que TL, Tsui EYK, Lam WY (2003) Mucormycosis in systemic lupus erythematosus. In *Seminars in arthritis and rheumatism* (Vol. 33, No. 2, pp. 115–124). WB Saunders

- Moraru RA, Grossman ME (2000) Palatal necrosis in an AIDS patient: a case of mucormycosis. *CUTIS-NEW YORK* 66(1):15–21
- Morrison V, McGlave P (1993) Mucormycosis in the BMT population. *Bone Marrow Transplant* 11(5):383–388
- Muma MKI, Chipalo-Mutati G (2010) Deadly orbital mucormycosis, rare yet possible infection. *Med J Zambia* 37(4):268–272
- Najafi N, Kermani F, Ghadi NG, Aghili SR, Seifi Z, Roilides E, Shokohi T (2019) Fatal rhinocerebral mucormycosis in a patient with ulcerative colitis receiving azathioprine and corticosteroid. *Curr Med Mycol* 5(1):37
- Nampoory MRN, Khan ZU, Johnny KV, Constandi JN, Gupta RK, Al-Muzairi I, Chugh TD (1996) Invasive fungal infections in renal transplant recipients. *J Infect* 33(2):95–101
- Negru PA, Radu A-F, Vesa CM, Behl T, Abdel-Daim MM, Nechifor AC, Endres L, Stoicescu M, Pasca B, Tit DM (2022) Therapeutic dilemmas in addressing SARS-CoV-2 infection: favipiravir versus remdesivir. *Biomed Pharmacother* 147:112700
- Negrut N, Codrean A, Hodisan I, Bungau S, Tit DM, Marin R, Behl T, Banica F, Diaconu CC, Nistor-Cseppento DC (2021) Efficiency of antiviral treatment in COVID-19. *Exp Ther Med* 21(6):1–7
- Neoh CF, Snell GI, Kotsimbos T, Levvey B, Morrissey CO, Slavin MA, Kong DCM (2011) Antifungal prophylaxis in lung transplantation—A world-wide survey. *Am J Transplant* 11(2):361–366
- Nordøy I, Hestvedt L, Torp Andersen C, Mylvaganam H, Kols NI, Falch BM, Denning DW (2018) An estimate of the burden of fungal disease in Norway. *J Fungi* 4(1):29
- Nussbaum ES, Hall WA (1994) Rhinocerebral mucormycosis: changing patterns of disease. *Surg Neurol* 41(2):152–156
- Coronaviridae Study Group of the International Committee on Taxonomy of Viruses (2020) The species severe acute respiratory syndrome-related coronavirus: classifying 2019-nCoV and naming it SARS-CoV-2. *Nat Microbiol* 5(4):536
- World Health Organization. (2021). Progress on household drinking water, sanitation and hygiene 2000-2020: five years into the SDGs.
- Otrisal P, Bungau C, Obsel V, Melicharik Z, Tont G (2021a) Selected respiratory protective devices: respirators and significance of some markings. *Sustainability* 13(9):4988
- Otrisal P, Bungau C, Obsel V, Melicharik Z, Tont G (2021) Selected respiratory protective devices: Respirators and significance of some markings. *Sustainability* 13(9):4988
- Pagano L, Valentini C, Posteraro B, Girmenia C, Ossi C, Pan A, Candoni A, Nosari A, Riva M, Cattaneo C (2009) Zygomycosis in Italy: a survey of FIMUA-ECMM (Federazione Italiana di Micopatologia Umana ed Animale and European Confederation of Medical Mycology). *21(3):322–329*
- Paley EL (2021) Towards understanding COVID-19: molecular insights, co-infections, associated disorders, and aging. *J Alzheimer's Dis Rep (Preprint):1–30*
- Park B, Kontoyiannis D, Pappas P, Wannemuehler K, Anaissie E, Fridkin S (2004) Comparison of zygomycosis and fusariosis to invasive aspergillosis among transplant recipients reporting to TRANSNET (abstract M-666). Program and Abstracts 44th Interscience Conference on Antimicrobial Agents and Chemotherapy (Washington), Washington, American Society for Microbiology
- Pegorie M, Denning DW, Welfare W (2017) Estimating the burden of invasive and serious fungal disease in the United Kingdom. *J Infect* 74(1):60–71
- Peterson KL, Wang M, Canalis RF, Abemayor E (1997) Rhinocerebral mucormycosis: evolution of the disease and treatment options. *Laryngoscope* 107(7):855–862
- Petrikkos G, Skiada A, Lortholary O, Roilides E, Walsh TJ, Kontoyiannis DP (2012) Epidemiology and clinical manifestations of mucormycosis. *Clin Infect Dis* 54(suppl_1): S23-S34
- Petrikkos G, Skiada A, Sambatakou H, Toskas A, Vaiopoulos G, Giannopoulou M, Katsilambros N (2003a) Mucormycosis: ten-year experience at a tertiary-care center in Greece. *Eur J Clin Microbiol Infect Dis* 22(12):753–756
- Petrikkos G, Skiada A, Sambatakou H, Toskas A, Vaiopoulos G, Giannopoulou M, Katsilambros N (2003) Mucormycosis: ten-year experience at a tertiary-care center in Greece. *Eur J Clin Microbiol Infect Dis* 22(12):753–756
- Prabhu R, Patel R (2004) Mucormycosis and entomophthoromycosis: a review of the clinical manifestations, diagnosis and treatment. *Clin Microbiol Infect* 10:31–47
- Prakash H, Chakrabarti A (2019) Global epidemiology of mucormycosis. *J Fungi* 5(1):26
- Prakash H, Chakrabarti A (2021). Epidemiology of mucormycosis in India. *Microorganisms*. 9:523
- Purohit D, Jalwal P, Manchanda D, Saini S, Verma R, Kaushik D, Pandey P (2022) Nanocapsules: An Emerging Drug Delivery System. *Recent Pat Nanotechnol*
- Quan C, Spellberg B (2010) Mucormycosis, pseudallescheriasis, and other uncommon mold infections. *Proc Am Thorac Soc* 7(3):210–215
- Raedler D, Schaub B (2014) Immune mechanisms and development of childhood asthma. *Lancet Respir Med* 2(8):647–656
- Rahman MH, Akter R, Behl T, Chowdhury MA, Mohammed M, Bulbul IJ, Elshenawy SE, Kamal MA (2020) COVID-19 outbreak and emerging management through pharmaceutical therapeutic strategy. *Curr Pharm Des* 26(41):5224–5240
- Rahman MH, Akter R, Kamal MA (2021a) Prospective function of different antioxidant containing natural products in the treatment of neurodegenerative diseases. *CNS Neurol Dis-Drug Targets (formerly Current Drug Targets-CNS & Neurological Disorders)* 20(8):694–703
- Rahman MT, Hossain MG, Rahman AT, Huq AM, Farzana S, Nazir KNH (2021) Mucormycosis (black fungus) in COVID-19 patients—Will it be another matter of concern in the midst of the COVID-19 flare-up in Bangladesh? *J Adv Vet Anim Res* 8(3):367
- Raut A, Huy NT (2021) Rising incidence of mucormycosis in patients with COVID-19: another challenge for India amidst the second wave?. *Lancet Respiratory Med* 9(8):e77
- Reed C, Bryant R, Ibrahim AS, Edwards J Jr, Filler SG, Goldberg R, Spellberg B (2008) Combination polyene-caspofungin treatment of rhino-orbital-cerebral mucormycosis. *Clin Infect Dis* 47(3):364–371
- Restar AJ, Tocco JU, Mantell JE, Lafort Y, Gichangi P, Masvawure TB, Chabeda SV, Sandfort TG (2017) Perspectives on HIV pre- and post-exposure prophylaxes (PrEP and PEP) among female and male sex workers in Mombasa, Kenya: implications for integrating biomedical prevention into sexual health services. *AIDS Educ Prev* 29(2):141–153
- Richardson M (2009) The ecology of the Zygomycetes and its impact on environmental exposure. *Clin Microbiol Infect* 15:2–9
- Roden MM, Zaoutis TE, Buchanan WL, Knudsen TA, Sarkisova TA, Schaufele RL, Sein M, Sein T, Chiou CC, Chu JH (2005a) Epidemiology and outcome of zygomycosis: a review of 929 reported cases. *Clin Infect Dis* 41(5):634–653
- Roden MM, Zaoutis TE, Buchanan WL, Knudsen TA, Sarkisova TA, Schaufele RL, Walsh TJ (2005) Epidemiology and outcome of zygomycosis: a review of 929 reported cases. *Clin Infect Dis* 41(5):634–653
- Roilides E, Zaoutis T, Walsh TJ (2009) Invasive zygomycosis in neonates and children. *Clin Microbiol Infect* 15:50–54

- Sabino R, Veríssimo C, Brandão J, Martins C, Alves D, Pais C, Denning DW (2017) Serious fungal infections in Portugal. *Eur J Clin Microbiol Infect Dis* 36(7):1345–1352
- Sacarlal J, Denning DW (2018) Estimated burden of serious fungal infections in Mozambique. *J Fungi* 4(3):75
- Salehi M, Ahmadikia K, Badali H, Khodavaissy S (2020) Opportunistic fungal infections in the epidemic area of COVID-19: a clinical and diagnostic perspective from Iran. *Mycopathologia* 185(4):607–611
- Saraya MA, Amal AEAI (2012) Dexamethasone as adjunctive therapy for treatment of varicella pneumonia. *Egyptian Journal of Chest Diseases and Tuberculosis* 61(3):9–13
- Sarkar S, Gokhale T, Choudhury SS, Deb AK (2021) COVID-19 and orbital mucormycosis. *Indian J Ophthalmol* 69(4):1002
- Schauwvlieghe AF, Rijnders BJ, Philips N, Verwijs R, Vanderbeke L, Van Tienen C, Mycosis Dutch-Belgian, study group, (2018) Invasive aspergillosis in patients admitted to the intensive care unit with severe influenza: a retrospective cohort study. *Lancet Respiratory Med* 6(10):782–792
- Schwarz C, Brandt C, Melichar V, Runge C, Heuer E, Sahly H, Tintelnot K (2019) Combined antifungal therapy is superior to monotherapy in pulmonary scedosporiosis in cystic fibrosis. *J Cyst Fibros* 18(2):227–232
- Segrelles-Calvo G, Araújo GR, Llopis-Pastor E, Carrillo J, Hernández-Hernández M, Rey L, Rodríguez Melean N, Escribano I, Antón E, Zamarro C (2021) Prevalence of opportunistic invasive aspergillosis in COVID-19 patients with severe pneumonia. *Mycoses* 64(2):144–151
- Sen M, Honavar SG, Sharma N, Sachdev MS (2021) COVID-19 and eye: a review of ophthalmic manifestations of COVID-19. *Indian J Ophthalmol* 69(3):488
- Serris A, Danion F, Lanternier F (2019) Disease entities in mucormycosis. *J Fungi* 5(1):23
- Seyedmousavi S, Bosco S, De Hoog S, Ebel F, Elad D, Gomes RR, Jacobsen ID, Jensen HE, Martel A, Mignon B (2018) Fungal infections in animals: a patchwork of different situations. *Med Mycol* 56(suppl_1):S165–S187
- Sharma S, Batra S, Gupta S, Sharma VK, Rahman MH, Kamal MA (2022) Persons with co-existing neurological disorders: risk analysis, considerations and management in COVID-19 pandemic. *CNS Neurol Dis-Drug Targets (formerly Current Drug Targets-CNS & Neurological Disorders)* 21(3):228–234
- Shenoi S, Emery H (2010) Successful treatment of invasive gastric mucormycosis in a child with systemic lupus erythematosus. *Lupus* 19(5):646–649
- Sindhu RK, Najda A, Kaur P, Shah M, Singh H, Kaur P, Cavalu S, Jaroszuk-Sierocińska M, Rahman MH (2021a) Potentiality of nanoenzymes for cancer treatment and other diseases: current status and future challenges. *Materials* 14(20):5965
- Sindhu RK, Verma R, Salgotra T, Rahman MH, Shah M, Akter R, Murad W, Mubin S, Bibi P, Qusti S (2021b) Impacting the remedial potential of nano delivery-based flavonoids for breast cancer treatment. *Molecules* 26(17):5163
- Singh AK, Singh R, Joshi SR, Misra A (2021) Mucormycosis in COVID-19: a systematic review of cases reported worldwide and in India. *15(4):102146*
- Singh N, Aguado JM, Bonatti H, Forrest G, Gupta KL, Safdar N, John GT, Pursell KJ, Muñoz P, Patel R (2009) Zygomycosis in solid organ transplant recipients: a prospective, matched case-control study to assess risks for disease and outcome. *J Infect Dis* 200(6):1002–1011
- Sipsas NV, Gamaletsou MN, Anastasopoulou A, Kontoyiannis DP (2018) Therapy of mucormycosis. *4(3):90*
- Skiada A, Pagano L, Groll A, Zimmerli S, Dupont B, Lagrou K, Lass-Flörl C, Bouza E, Klimko N, Gaustad P (2011a) Zygomycosis in Europe: analysis of 230 cases accrued by the registry of the European Confederation of Medical Mycology (ECMM) Working Group on Zygomycosis between 2005 and 2007. *Clin Microbiol Infect* 17(12):1859–1867
- Skiada A, Pagano L, Groll A, Zimmerli S, Dupont B, Lagrou K, Lass-Flörl C, Bouza E, Klimko N, Gaustad P (2011b) Zygomycosis in Europe: analysis of 230 cases accrued by the registry of the European Confederation of Medical Mycology (ECMM) Working Group on Zygomycosis between 2005 and 2007. *17(12):1859–1867*
- Skiada A, Pavleas I, Drogari-Apiranthitou M (2020) Epidemiology and diagnosis of mucormycosis: an update. *J Fungi* 6(4):265
- Slavin MA, Chakrabarti A (2012) Opportunistic fungal infections in the Asia-Pacific region. *Med Mycol* 50(1):18–25
- Song G, Liang G, Liu W (2020a) Fungal co-infections associated with global COVID-19 pandemic: a clinical and diagnostic perspective from China. *Mycopathologia* :1–8
- Song G, Liang G, Liu W (2020) Fungal co-infections associated with global COVID-19 pandemic: a clinical and diagnostic perspective from China. *Mycopathologia* 185(4):599–606
- Spellberg B, Edwards J Jr, Ibrahim A (2005) Novel perspectives on mucormycosis: pathophysiology, presentation, and management. *Clin Microbiol Rev* 18(3):556–569
- Stearman R, Yuan DS, Yamaguchi-Iwai Y, Klausner RD, Dancis A (1996) A permease-oxidase complex involved in high-affinity iron uptake in yeast. *Science* 271(5255):1552–1557
- Sundermann AJ, Clancy CJ, Pasculle AW, Liu G, Cumbie RB, Driscoll E, Ayres A, Donahue L, Pergam SA, Abbo L (2019) How clean is the linen at my hospital? The Mucorales on unclean linen discovery study of large United States transplant and cancer centers. *Clin Infect Dis* 68(5):850–853
- Tagde P, Najda A, Nagpal K, Kulkarni GT, Shah M, Ullah O, Balant S, Rahman MH (2022) Nanomedicine-based delivery strategies for breast cancer treatment and management. *Int J Mol Sci* 23(5):2856
- Tagde P, Tagde S, Bhattacharya T, Akter R, Rahman M (2021a) Multifaceted effects of intermittent fasting in the treatment and prevention of diabetes, cancer and obesity or other chronic diseases. *Curr Diabetes Rev*
- Tagde P, Tagde S, Bhattacharya T, Tagde P, Chopra H, Akter R, Kaushik D, Rahman M (2021b) Blockchain and artificial intelligence technology in e-Health. *Environ Sci Pollut Res* 28(38):52810–52831
- Tagde P, Tagde S, Tagde P, Bhattacharya T, Monzur SM, Rahman MH, Otrisal P, Behl T, Ul Hassan SS, Abdel-Daim MM (2021c) Nutraceuticals and herbs in reducing the risk and improving the treatment of COVID-19 by targeting SARS-CoV-2. *Biomedicines* 9(9):1266
- Tagliaferri A, Franchini M, Coppola A, Rivolta G, Santoro C, Rossetti G, Feola G, Zanon E, Dragani A, Iannaccaro P (2008) Effects of secondary prophylaxis started in adolescent and adult haemophiliacs. *Haemophilia* 14(5):945–951
- Tedder M, Spratt JA, Anstadt MP, Hegde SS, Tedder SD, Lowe JE (1994) Pulmonary mucormycosis: results of medical and surgical therapy. *Ann Thorac Surg* 57(4):1044–1050
- Thomson S, Bade P, Taams M, Chrystal V (1991) Gastrointestinal mucormycosis. *J Bri Surg* 78(8):952–954
- Tilavberdiev SA, Denning DW, Klimko NN (2017) Serious fungal diseases in the Republic of Uzbekistan. *Eur J Clin Microbiol Infect Dis* 36(6):925–929
- Tilavberdiev SA, Madaminov FA (2021) Associated fungal infections, related to the global Covid-19 pandemic (literature review). *Int J Multicult Multirelig Underst* 8(5):619–627
- Tong SY, Davis JS, Eichenberger E, Holland TL, Fowler VG Jr (2015) *Staphylococcus aureus* infections: epidemiology, pathophysiology, clinical manifestations, and management. *Clin Microbiol Rev* 28(3):603–661

- Torres-Narbona M, Guinea J, Martínez-Alarcón J, Muñoz P, Gadea I, Group, E. B. a. a. r. o. t. M. Z. S. (2007) Impact of zygomycosis on microbiology workload: a survey study in Spain. *J Clin Microbiol* 45(6):2051–2053
- Two black fungus cases detected in Bangladesh (9. Star TD. Two black fungus cases detected in Bangladesh. Available via <https://www.thedailystar.net/bangladesh/news/two-black-fungus-cases-detected-20983092021>. Accessed 23 June 2021.
- Van den Saffele J, Boelaert J (1996) Zygomycosis in HIV-positive patients: a review of the literature: Zygomycosen bei HIV-positiven Patienten: eine Literaturübersicht. *Mycoses* 39(3–4):77–84
- Vigouroux S, Morin O, Moreau P, Méchinaud F, Morineau N, Mahé B, Chevallier P, Guillaume T, Dubruille V, Harousseau J-L (2005) Zygomycosis after prolonged use of voriconazole in immunocompromised patients with hematologic disease: attention required. *Clin Infect Dis* 40(4):e35–e37
- Wadi J, Denning DW (2018) Burden of serious fungal infections in Jordan. *J Fungi* 4(1):15
- Walia V, Kaushik D, Mittal V, Kumar K, Verma R, Parashar J, Akter R, Rahman M, Bhatia S, Al-Harrasi A (2021) Delineation of neuroprotective effects and possible benefits of antioxidant-therapy for the treatment of Alzheimer's diseases by targeting mitochondrial-derived reactive oxygen species: bench to bedside. *Mol Neurobiol* 1–24
- Walsh TJ, Gamaletsou MN, McGinnis MR, Hayden RT, Kontoyiannis DP (2012) Early clinical and laboratory diagnosis of invasive pulmonary, extrapulmonary, and disseminated mucormycosis (zygomycosis). *Clin Infect Dis* 54(suppl_1):S55–S60
- Walther G, Wagner L, Kurzai O (2019) Updates on the taxonomy of Mucorales with an emphasis on clinically important taxa. *Journal of Fungi* 5(4):106
- Wani AA (2021a) Mucormycosis (black fungus) an emerging threat during 2nd wave of COVID-19 pandemic in India: a review. *Haya Saudi J Life Sci* 6(7):143–146
- Wani AAJHSJLS (2021b) Mucormycosis (Black Fungus) an emerging threat during 2nd wave of COVID-19 pandemic in India: A Review 6(7):143–146
- Watkins TN, Gebremariam T, Swidergall M, Shetty AC, Graf KT, Alqarihi A, Bruno VM (2018) Inhibition of EGFR signaling protects from mucormycosis. *MBio* 9(4):e01384–18
- Webb BJ, Ferraro JP, Rea S, Kaufusi S, Goodman BE, Spalding J (2018) Epidemiology and clinical features of invasive fungal infection in a US health care network. *Open Forum Infect Dis*
- Wertheim HF, Melles DC, Vos MC, van Leeuwen W, van Belkum A, Verbrugh HA, Nouwen JL (2005) The role of nasal carriage in *Staphylococcus aureus* infections. *Lancet Infect Dis* 5(12):751–762
- Yang L, Jin X-S, Li J-H, Liu J, Guan W, Gao H-H, Jing Y (2017) Efficacy and safety of low-dose amphotericin B in different antifungal strategies for treatment of invasive fungal disease in patients with hematological malignancies. *Zhongguo Shi Yan Xue Ye Xue Za Zhi* 25(1):221–225
- Yohai RA, Bullock JD, Aziz AA, Markert RJ (1994) Survival factors in rhino-orbital-cerebral mucormycosis. *Surv Ophthalmol* 39(1):3–22
- Zehravi M, Kabir J, Akter R, Malik S, Ashraf GM, Tagde P, Ramproshad S, Mondal B, Rahman M, Mohan AG (2022) A prospective viewpoint on neurological diseases and their biomarkers. *Molecules* 27(11):3516
- Zhou P, Yang X-L, Wang X-G, Hu B, Zhang L, Zhang W, Si H-R, Zhu Y, Li B, Huang C-L (2020) A pneumonia outbreak associated with a new coronavirus of probable bat origin. *Nature* 579(7798):270–273

Publisher's note Springer Nature remains neutral with regard to jurisdictional claims in published maps and institutional affiliations.

Springer Nature or its licensor holds exclusive rights to this article under a publishing agreement with the author(s) or other rightsholder(s); author self-archiving of the accepted manuscript version of this article is solely governed by the terms of such publishing agreement and applicable law.