



## Correction to: Histological liver changes in Swiss mice caused by tannery effluent

Letícia Martins Rabelo<sup>1</sup> · Abraão Tiago Batista Guimarães<sup>2</sup> · Joyce Moreira de Souza<sup>2</sup> · Wellington Alves Mizael da Silva<sup>2</sup> · Bruna de Oliveira Mendes<sup>1</sup> · Raíssa de Oliveira Ferreira<sup>1</sup> · Aline Sueli de Lima Rodrigues<sup>2</sup> · Guilherme Malafaia<sup>2,3</sup>

Published online: 27 March 2018  
© Springer-Verlag GmbH Germany, part of Springer Nature 2018

**Correction to: Environ Sci Pollut Res (2018) 25:1943–1949**  
<https://doi.org/10.1007/s11356-017-0647-1>

There is a problem in the original publication of this paper (Fig. 2 Graphs are in Portuguese).

Shown in this paper is the correct version.

---

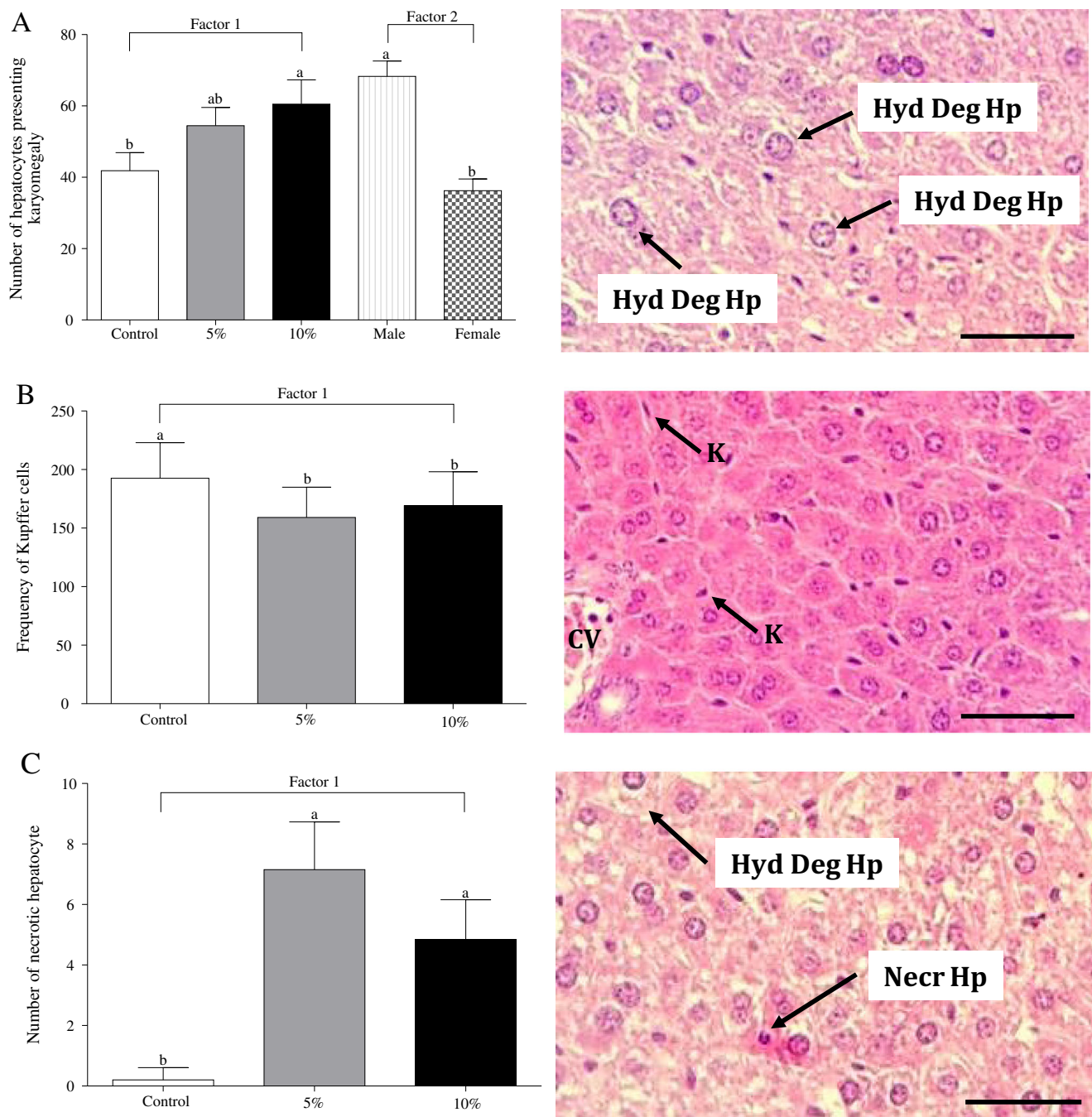
The online version of the original article can be found at <https://doi.org/10.1007/s11356-017-0647-1>

---

✉ Guilherme Malafaia  
guilhermeifgoiano@gmail.com

Aline Sueli de Lima Rodrigues  
alineifgoiano@gmail.com

- <sup>1</sup> Laboratório de Pesquisas Biológicas, Instituto Federal Goiano–Campus Urutaí, Urutaí, GO, Brazil
- <sup>2</sup> Programa de Pós-Graduação em Conservação de Recursos Naturais do Cerrado, Instituto Federal Goiano–Campus Urutaí, Rodovia Geraldo Silva Nascimento, 2,5 km, Zona Rural, Urutaí, GO CEP:75790-000, Brazil
- <sup>3</sup> Programa de Pós-Graduação em Biodiversidade Animal, Universidade Federal de Goiás–Campus Samambaia, Goiânia, GO, Brazil



**Fig. 2** (A) Number of hepatocytes presenting karyomegaly; (B) Frequency of Kupffer cells and (C) number of necrotic hepatocyte in Swiss mice (male and female) exposed, or not, to different tannery effluent concentrations diluted in water, for 150 days. Different letters

indicate statistically significant differences between experimental groups. Hyd Deg Hp: hepatocyte presenting hydropic degeneration; k: Kupffer cell; Necr Hp: Necrosis in hepatocyte; CV: centrilobular vein. Bar=100  $\mu$ m. HE stain.