



# Detection of coronavirus in tear samples of hospitalized patients with COVID-19

Mine Ozturk · Deniz Kumova · Sema Alacam ·  
Hatice Erdogan · Feyza Onder

Received: 6 March 2022 / Accepted: 7 July 2022 / Published online: 20 July 2022  
© The Author(s), under exclusive licence to Springer Nature B.V. 2022

## Abstract

**Purpose** To assess the presence of viral RNA in conjunctival secretions and tears of severe acute respiratory syndrome coronavirus 2 (SARS-CoV-2)-infected patients in terms of a possible ocular transmission route and also to examine whether a difference between the patients with and without ocular surface positivity existed.

**Methods** A prospective cross-sectional study of 70 consecutive patients who were hospitalized in Haseki Training and Research Hospital with SARS-CoV-2 from February 1 to April 1, 2021, was performed. Tears and conjunctival secretions were collected within 24 h of nasopharyngeal sample collection and examined for SARS-CoV-2 using reverse transcription real-time polymerase chain reaction (qPCR). The clinical data, results of blood tests and

nasopharyngeal and conjunctival swabs, and CT findings were evaluated for all patients.

**Results** Seventy patients (37 males, 33 females) were included in this study. Tear–conjunctival samples from eight patients (11.42%) yielded positive PCR results although these eight patients had no eye symptoms or conjunctivitis. In patients with positive conjunctival PCR results, cycle threshold values for conjunctival samples were higher than those for nasopharyngeal samples. All findings (except gender) were similar between patients with either positive or negative conjunctival swab samples. All patients with positive conjunctival swab samples were male; however, the male ratio in patients with negative conjunctival swab samples was only 46.77%.

**Conclusion** In our study, the rate of conjunctival swab PCR positivity was 11.42%. It appears that even in the absence of ocular symptoms, SARS-CoV-2 virus may be present on the ocular surface; therefore, the ocular surface may be a significant viral transmission route.

**Keywords** Conjunctival swab · Nasopharyngeal swab · COVID-19 · SARS-CoV-2 · Tears

---

M. Ozturk (✉) · D. Kumova · F. Onder  
Department of Ophthalmology, Haseki Training  
and Research Hospital, University of Health Sciences,  
Millet Street, 34096 Istanbul, Turkey  
e-mail: dr\_mine@yahoo.com

S. Alacam  
Division of Virology, Department of Medical  
Microbiology, Haseki Training and Research Hospital,  
University of Health Sciences, Istanbul, Turkey

H. Erdogan  
Department of Medical Microbiology, Haseki Training  
and Research Hospital, University of Health Sciences,  
Istanbul, Turkey

## Introduction

The novel coronavirus disease 2019 (COVID-19) was first reported in December 2019 in Wuhan,

China and was declared a pandemic by the World Health Organization (WHO) on March 11, 2020.

Ocular tropism of the respiratory viruses, such as adenovirus, influenza, respiratory syncytial virus, rhinovirus, and coronaviruses has been previously demonstrated. It was also proven that the eye can have a dual role in infection establishment. It serves as a portal of entry and also serves as a primary site of replication [1]. Infected tears can be taken up by the conjunctiva, cornea, epithelium of lacrimal duct, or transmitted to nasopharynx through the nasolacrimal duct. The passage of the infected tears through the nasolacrimal system may provide a pathway for the virus that initially is present on the infected ocular surface to enter the digestive and respiratory tracts [2]. The reverse passage of the virus from the oral and nasal mucosa to the eye seems less likely but cannot be ruled out completely.

The main routes of transmission of the COVID-19 infection are airborne dissemination (respiratory route), direct or indirect contact (face/eye touching), and oral–fecal. Great concern has been expressed about COVID-19 infection acquired through ocular route, but its main mechanism has not yet been definitively clarified [3]. The spike (S) protein of coronaviruses facilitates entry into target cells by binding to specific surface receptors. It was demonstrated that severe acute respiratory syndrome coronavirus 2 (SARS-CoV-2) uses the angiotensin-converting enzyme 2 (ACE2) as a receptor for viral entry into target cells, and the serine protease TMPRSS2 for S protein priming. ACE2 and TMPRSS2 are believed to be the major players in the cell entry [4, 5]. Viral tropism of the ocular surface may be partially explained by the presence of SARS-CoV-2 receptors in the eye. ACE2 and TMPRSS2 receptors have been identified both on the ocular surface (conjunctiva and cornea) and in the deeper intraocular tissues (retina and choroid) [6, 7]. The presence of the TMPRSS2 protein and ACE2 receptors on the corneal limbal stem cells may theoretically allow the virus to cross the ocular surface and spread from the eye to the other areas of the body through the blood and/or nervous system (ophthalmic branch of the trigeminal nerve) [8]. In an experimental animal study, it was shown that SARS-CoV-2 coronavirus can replicate in the conjunctival cells and cause viral pneumonia via the conjunctival route [9].

This study aimed to investigate the presence of the new coronavirus in tears and conjunctival secretions from patients infected with SARS-Cov-2 to contribute to a better understanding of the transmission routes of the disease. Different features in the patients with SARS-CoV-2 detected on the ocular surface were also evaluated.

## Materials and methods

### Study design and participants

A prospective cross-sectional study was designed at the Haseki Training and Research Hospital, Istanbul, Turkey. Between February 1 and April 1, 2021, 70 consecutive patients who were hospitalized with a COVID-19 diagnosis and had a nasopharyngeal reverse-transcriptase polymerase chain reaction (RT-PCR) analysis performed within the last 24 h were included in the study. The diagnostic criteria included nasopharyngeal swab PCR results that were positive for SARS-CoV-2 nucleic acid and/or highly suspicious radiological findings correlating with COVID-19 (unilateral or bilateral multi-lobed infiltration of the lungs, especially the peripheral zones and/or ground glass appearance), which were detected on chest computed tomography (CT) scans and confirmed by a radiologist with supportive laboratory parameters.

### Procedures

The demographic, clinical, and laboratory data of all patients were recorded. Blood test results on the day of admission, including complete blood cell count, peripheral capillary oxygen saturation (SpO<sub>2</sub>), procalcitonin, C-reactive protein (CRP), creatine kinase (CK), lactate dehydrogenase (LDH), troponine T, D-dimer, fibrinogen and activated partial thromboplastin time (APTT), chest CT findings, and RT-PCR results from nasopharyngeal swabs for SARS-CoV-2 were also included in this study. Information about the time of onset of the general symptoms (respiratory, fever, gastrointestinal, tiredness and myalgia) and previous antiviral treatment (if any) were also recorded. Novel coronavirus pneumonia (NCP) was defined as mild–moderate or severe pneumonia. Mild–moderate NCP was defined based on two parameters:

(1) symptoms, such as fever, joint/muscle pain, sore throat, and/or cough, SpO<sub>2</sub> level > 90% in room air and (2) mild/moderate findings on a CT scan. Severe NCP was defined based on two parameters: (1) symptoms, such as fever, joint/muscle pain, sore throat, and/or cough, SpO<sub>2</sub> level ≤ 90% in room air and (2) CT findings of bilateral diffuse pneumonia.

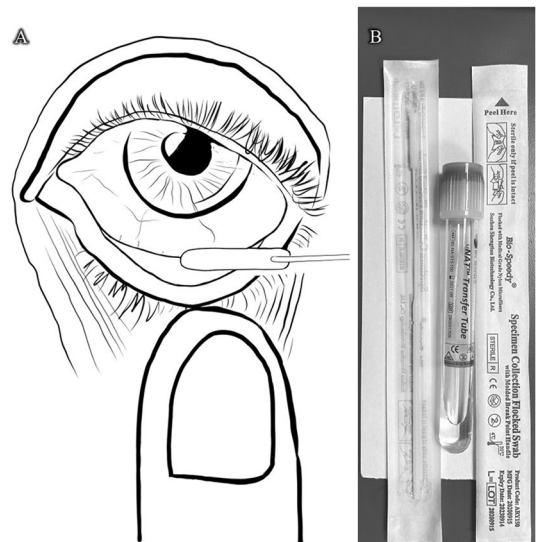
Nasopharynx swabs were taken from all patients by trained healthcare workers within the last 24 h in the COVID-19 outpatient clinics. Conjunctival swabs were taken by two experienced ophthalmologists (MO, DKG) immediately after the patients were hospitalized. Conjunctival swabs were taken within 24 h of nasopharynx swabs to compare the viral load between the nasopharynx and conjunctiva more accurately and prevent the viral load from being affected by treatment. Prior to conjunctival sampling, an ocular surface examination was performed with a penlight.

#### Method of obtaining a conjunctival swab

The conjunctival swab method was used to collect tears and conjunctival samples from the patients. To prevent respiratory contamination, a patient was asked to wear a surgical mask before and during the procedure. The ophthalmologist who took the sample entered the patient's room wearing personal protective equipment and sterile gloves. Each patient's lower eyelid was opened, and the disposable sampling swab was placed in the lower fornix without anesthesia (Fig. 1). The swab was gently turned and held in the lower fornix for at least 10 s. The procedure was applied consecutively with the same swab for both eyes thus increasing the quantity of ocular samples. Samples were put into a sterile viral nucleic acid buffer (vNAT) transfer tube and rapidly transferred to the PCR laboratory.

#### PCR protocol

Samples collected with synthetic fiber swabs were inserted into a sterile vNAT transfer tube containing 2 ml extractive and preservative vNAT (Bio-speedy, Bioeksen, Istanbul, Turkey). The collected samples were stored at 2 to 8 °C and transferred to the virology laboratory of our hospital under the same



**Fig. 1** (A) The conjunctival swab technique; (B) Swab and vNAT transfer tube used in the present study. The figure was illustrated by the corresponding author Mine Ozturk

conditions. The PCR test for the detection of SARS CoV-2 in swab samples was carried out within 24 h. Since the liquid in the vNAT tubes allowed for extraction of SARS COV-2 RNA in 5 min, the PCR step could be started directly without the need for intermediate processing. The diagnosis with the Biospeedy SARS CoV-2 Double Gene RT qPCR Version 4 (Bio-speedy, Bioeksen, Istanbul, Turkey) kit was performed using one-step RT-PCR targeting the SARS CoV-2-specific N gene and Orf1ab gene region. Viral load was determined using cycle threshold (Ct) value.

#### Statistical analysis

Statistical analysis was performed using SPSS software (version 15,0 SPSS (IBM), Chicago, IL, USA). For data evaluation in addition to descriptive statistical methods (mean, standard deviation), the Shapiro–Wilk normality test was used to examine variable distribution. An independent t-test was used for comparing normally distributed variables in binary groups, and the Mann–Whitney U test was used for comparison of variables that did not show normal distribution between binary groups. Chi-square and Fisher's exact tests were used for comparisons of

**Table 1** Demographic, clinical characteristics, and laboratory results of all patients

Parameter	Value	
Age (years, mean $\pm$ SD)	61.50 $\pm$ 13.76 (32–90)	
<i>Gender</i>		
Male	37/70	52.90%
Female	33/70	47.10%
<i>Nasopharyngeal RT-PCR</i>		
Negative	22/70	31.43%
Positive	48/70	68.57%
<i>Conjunctival RT-PCR</i>		
Negative	62/70	88.57%
Positive	8/70	11.43%
<i>Chronic medical illness</i>	41/70	58.57%
Diabetes	18/70	25.71%
Cardiovascular and cerebrovascular diseases	28/70	40.00%
Respiratory system diseases	16/70	22.85%
Malignancy	3/70	4.28%
Ocular symptoms	3/70	4.28%
<i>Sign and symptoms at admission</i>		
Respiratory (cough, shortness of breath)	49/70	70.00%
Fever	18/70	25.71%
Gastrointestinal (nausea, vomiting, diarrhea)	12/70	17.14%
Tiredness, myalgia	39/70	55.71%
Duration of symptoms (days)	8.54 $\pm$ 4.68 (1–21)	
Body temperature ( $^{\circ}$ C)	36.53 $\pm$ 0.48 (35–38)	
Peripheral capillary oxygen saturation (SpO <sub>2</sub> )	93.69 $\pm$ 2.87 (84–99)	
<i>Pneumonia severity</i>		
Mild-moderate	63/70	90.00%
Severe	7/70	10.00%
Neutrophil count, ( $\times 10^3/\mu$ L), mean $\pm$ SD	5.96 $\pm$ 3.20	
Lymphocyte count, ( $\times 10^3/\mu$ L), mean $\pm$ SD	1.45 $\pm$ 0.77	
Monocyte count, ( $\times 10^3/\mu$ L), mean $\pm$ SD	0.50 $\pm$ 0.28	
C-reactive protein, (mg/L), mean $\pm$ SD	75.76 $\pm$ 65.83	
Troponine T, (ng/mL), mean $\pm$ SD	0.014 $\pm$ 0.013	
Procalcitonin, (ng/mL), mean $\pm$ SD	0.50 $\pm$ 2.16	
Lactate dehydrogenase, (U/L), mean $\pm$ SD	327.66 $\pm$ 132.04	
Creatine kinase, (U/L), mean $\pm$ SD	158.81 $\pm$ 168.54	
D-Dimer, mg/L, mean $\pm$ SD	1.42 $\pm$ 2.84	
Fibrinogen, mg/dl, mean $\pm$ SD	598.96 $\pm$ 154.69	
Activated partial thromboplastin time (sec), mean $\pm$ SD	32.16 $\pm$ 4.08	
Number of patients with previous COVID-19 treatment without hospitalization, (no,%)	32/70	45.71%
Duration of previous COVID-19 treatment, (days)	4.68 $\pm$ 2.75 (1–10)	

*SD* standard deviation, *RT-PCR* reverse-transcriptase polymerase chain reaction, *COVID-19* coronavirus 2019

qualitative data. The results were evaluated at a significance level of  $p < 0.05$ .

## Results

Demographic, clinical characteristics and laboratory results of all patients are summarized in Table 1. Seventy COVID-19 patients (33 females and 37 males) were included in this study. The mean age of the patients was  $61.50 \pm 13.76$  years (range 32–90). Forty-one (58.57%) patients had systemic diseases, including diabetes, respiratory system diseases, cardiovascular and cerebrovascular diseases, and malignant tumors. Of the 70 patients, 63 patients (90%) had mild-moderate disease, and seven patients (10%) had severe disease. The nasopharyngeal RT-PCR test performed before hospitalization yielded positive results in 48 patients (68.57%). When the records of the patients with negative nasopharyngeal PCR results were investigated retrospectively, it was found that nine patients had previous nasopharyngeal PCR tests. While two of these patients had negative test results, seven of them presented positive test results. Patients with negative nasopharyngeal PCR results were confirmed as COVID-19 patients based on their radiological and clinical findings. At the time of conjunctival sampling, the average time from the onset of general symptoms was  $8.54 \pm 4.68$  (range 1–21) days. Forty-nine (70%), 18 (25.71%), 12 (17.14%), and 39 (55.71%) patients had respiratory symptoms, fever, gastrointestinal symptoms, and tiredness and/or myalgia, respectively. Three patients (4.28%) had ocular symptoms, such as itching and foreign body sensation, but none of them had positive results for conjunctival SARS-CoV-2. The main body temperature and SpO<sub>2</sub> were  $36.53 \pm 0.48$  and  $93.69 \pm 2.87$ , respectively. Among 70 patients, eight patients (11.43%) had positive conjunctival swab PCR, whereas 62 (88.57%) had negative conjunctival swab PCR. Thirty-two of the 70 patients (45.71%) had undergone previous COVID-19 treatment without hospitalization, and the main duration of the previous treatment was  $4.68 \pm 2.75$  days.

In Table 2, demographic, clinical characteristics and laboratory results of the patients with positive conjunctival swab samples are summarized in detail. The mean CT values for the samples taken from the nasopharynx and conjunctiva were  $25.43 \pm 6.98$  and  $33.51 \pm 3.43$ , respectively.

Demographic, clinical characteristics, and laboratory results of the patients with and without positive conjunctival swab PCR are given together in Table 3 to examine whether a difference between patients with and without a positive swab existed. Age and concomitant systemic diseases were similar among all patients. The most common concomitant systemic diseases were cardiovascular and cerebrovascular diseases. The ratio of male gender was significantly higher ( $p = 0.005$ ) in the patients with positive conjunctival swab PCR (100%) compared to the patients with negative swab PCR (46.77%). While nasopharyngeal PCR tests obtained just before hospitalization were positive in all patients with positive conjunctival swab PCR, the positivity rate was only 64.52% (40/62) for the patients with negative conjunctival swab PCR ( $p = 0.042$ ). The nasopharyngeal RT-PCR Ct values were similar ( $26.77 \pm 4.92$  versus  $25.43 \pm 6.98$ ;  $p = 0.515$ ). None of the patients with positive conjunctival swab PCR presented ocular symptoms. Of the patients with negative conjunctival swab PCR, two had conjunctival hyperemia, and one had foreign body sensation in the eye. Signs and symptoms upon admission were similar. While the most common symptom was respiratory (cough and shortness of breath) in the patients with negative conjunctival swab PCR (72.58%), the most common symptoms in the patients with negative conjunctival swab PCR were respiratory symptoms and tiredness/myalgia (50% for both). None of the patients were admitted to intensive care unit (ICU) because of respiratory failure. When the conjunctival–tear samples were obtained, the mean time from the onset of symptoms was similar ( $8.69 \pm 4.83$  versus  $7.25 \pm 3.69$ ,  $p = 0.448$ ). The values of the body temperature and peripheral capillary oxygen saturation (SpO<sub>2</sub>) showed no difference ( $36.53 \pm 0.46$  versus  $36.55 \pm 0.69$ ;  $p = 0.931$  and  $93.19 \pm 3.7$  versus  $93.12 \pm 2.10$ ;  $p = 0.959$ , respectively). The severity of lung involvement as assessed by CT was similar ( $p = 0.316$ ). Activated partial thromboplastin clotting time (APTT) was observed to be significantly longer in the patients with positive conjunctival swab PCR compared to those with negative swab PCR ( $35.04 \pm 6.04$  versus  $31.8 \pm 3.67$ ;  $p = 0.034$ ), but for all patients, this value was within normal range. All other blood test results showed no significant difference ( $P > 0.05$ ). Thirty of 62 patients with

**Table 2** Demographic, clinical characteristics, and laboratory results of the patients with positive conjunctival swap samples

	Case 1	Case 2	Case 3	case 4	Case 5	case 6	Case 7	Case 8
Age (years, mean $\pm$ SD)	50	64	55	86	84	63	73	63
Gender	M	M	M	M	M	M	M	M
Nasopharyngeal RT-PCR	+	+	+	+	+	+	+	+
Nasopharyngeal RT-PCR cycle of threshold (Ct)	37.99	24.46	23.96	19.57	34.42	22.67	19.01	21.35
Conjunctival RT-PCR cycle of threshold (Ct)	34.90	31.63	34.82	33.55	34.74	37.55	26.06	34.89
Chronic medical illness	Cardiovascular	Respiratory	–	–	Cardiovascular	–	Cardiovascular	Respiratory
Ocular symptoms	–	–	–	–	–	–	–	–
Sign and symptoms at admission	Respiratory	Respiratory	Fever, gastrointestinal, tiredness, myalgia	Respiratory, tiredness, myalgia	Gastrointestinal, tiredness, myalgia	Fever, tiredness, myalgia	Fever	Respiratory
Duration of symptoms (days)	13	9	5	6	6	4	12	3
Body temperature ( $^{\circ}$ C)	36.5	36.5	36.5	36.5	38	36	36.8	35.6
Peripheral capillary oxygen saturation (SpO <sub>2</sub> )	96	91	96	94	91	91	93	93
Pneumonia severity	Mild-moderate	Mild-moderate	Mild-moderate	Mild-moderate	Mild-moderate	Mild-moderate	Mild-moderate	Mild-moderate
Neutrophil count, ( $\times 10^3/\mu$ L),	2.8	7.42	1.78	7.66	2.75	5.05	3.84	2.16
Lymphocyte count, ( $\times 10^3/\mu$ L),	0.94	0.85	1.38	0.8	1.53	1.94	0.88	0.38
Monocyte count, ( $\times 10^3/\mu$ L)	0.75	0.59	0.55	0.27	0.32	0.52	0.58	0.19
C-reactive protein, (mg/L)	119.7	94.6	49.3	142.8	47.4	64.1	41.5	112.6
Troponine T, (ng/mL)	0.006	0.001	0.005	0.02	0.059	0.008	0.072	0.007

**Table 2** (continued)

	Case 1	Case 2	Case 3	case 4	Case 5	case 6	Case 7	Case 8
Procalcitonin, (ng/mL)	0.05	0.35	0.05	0.37	0.08	0.13	2.16	0.15
Lactate dehydrogenase, (U/L)	415	271	213	391	327	298	200	464
Creatine kinase, (U/L)	108	183	68	279	164	105	84	267
D-Dimer, mg/L	0.56	1.35	0.83	0.51	0.35	0.4	4.45	1.01
Fibrinogen, mg/dl	564	693	450	546	402	695	461	521
Activated partial thromboplastin time, (seconds)	23.1	35.6	34.2	38.7	44.8	33.8	34.1	36
Previous COVID-19 treatment without hospitalisation	–	+	–	–	–	+	–	–
Duration of previous COVID-19 treatment, (day)	0	5	0	0	0	4	0	0

negative conjunctival swab PCR and two of eight patients with positive conjunctival swab PCR had been given COVID-19 treatment with Favipiravir and did not require hospitalization. Duration of previous COVID-19 treatment was similar ( $2.27 \pm 3.07$  versus  $1.13 \pm 2.1$ ;  $p = 0.271$ ).

## Discussion

The results of this study showed positive results (11.43% of patients) for SARS-CoV-2 RNA in the conjunctival swabs of the patients with COVID-19. In different studies, the positive rate of SARS-CoV-2 RNA detected in tears and conjunctival secretions was different. Hany et al., Arora et al., and Kaya et al. reported higher rates of 28.57%, 28%, and 16%, respectively, than found in our study [10–12]. In some other studies, a lower positivity rate, ranging from 0.8 to 7, was found [13–18]. This variability could have been due to multiple factors, such as differences in

hygiene practices, race, timing of conjunctival swab, technique of conjunctival swab removal, patient compliance, or different virus subtypes in different geographical regions.

In our study, the mean duration of symptoms at the time of conjunctival sampling was 7.25 days. Previous studies in SARS patients showed that the presence of virus in tears occurs during the early stages of the disease (19). It was shown that high rates of positivity were found in tears or conjunctival samples taken from the fourth to ninth day (median value being fifth) after symptom onset. Arora et al. and Kaya et al. reported high positivity rates of 28% and 16%, respectively [11, 12]. Arora et al. showed that the median duration of symptoms in patients with positive PCR results from tear swabs was five days (range, 4–9 days) [11]. In Kaya et al.'s study, the mean time from onset of symptoms was 6.84 days [12]. On the contrary, Seah et al. performed sequential conjunctival sampling in 17 patients; however, viral RNA was not detected in any of the samples. Fifty-two of

**Table 3** Demographic and clinical characteristics and laboratory results of the patients with and without positive conjunctival swab PCR

	Patients with— n:62	Conjunctival RT-PCR	Patients with + n:8	Conjunctival RT-PCR (+)	P
Age (years, mean ± SD)	60.76 ± 13.8		67.25 ± 12.87		0.212*
<i>Gender</i>					
Male	29/62	46.77%	8/8	100.00%	0.005 +
Female	33/62	53.23%	0/8	0.00%	
<i>Nasopharyngeal RT-PCR</i>					
Negative	22/62	35.48%	0/8	0.00%	0.042 +
Positive	40/62	64.52%	8/8	100.00%	
Nasopharyngeal RT-PCR cycle of threshold (Ct)	26.77 ± 4.92		25.43 ± 6.98		0.515*
<i>Chronic medical illness</i>					
Diabetes	18/62	29.03%	0/8	0.00%	0.077 ‡
Cardiovascular and cerebrovascular diseases	25/62	40.32%	3/8	37.50%	0.878 +
Respiratory system diseases	14/62	22.58%	2/8	25.00%	0.878 +
Malignancy	3/62	4.84%	0/8	0.00%	0.525 ‡
Ocular symptoms	3/62	4.84%	0/8	0.00%	0.525 ‡
<i>Sign and symptoms at admission</i>					
Respiratory (cough, shortness of breath)	45/62	72.58%	4/8	50.00%	0.190 +
Fever	15/62	24.19%	3/8	37.50%	0.418 +
Gastrointestinal (nausea, vomiting, diarrhea)	10/62	16.13%	2/8	25.00%	0.531 +
Tiredness, myalgia	35/62	56.45%	4/8	50.00%	0.730 +
Duration of symptoms (days)	8.69 ± 4.83		7.25 ± 3.69		0.448 ‡
Body temperature (°C)	36.53 ± 0.46		36.55 ± 0.69		0.931*
Peripheral capillary oxygen saturation (SpO2)	93.19 ± 3.70		93.12 ± 2.10		0.959*
<i>Pneumonia severity</i>					
Mild-moderate	55/62	88.71%	8/8	100.00%	0.316 +
Severe	7/62	11.29%	0/8	0.00%	
Neutrophil count, ( $\times 10^3/\mu\text{L}$ ), mean ± SD	6.19 ± 3.24		4.18 ± 2.31		0.095*
Lymphocyte count, ( $\times 10^3/\mu\text{L}$ ), mean ± SD	1.5 ± 0.79		1.09 ± 0.49		0.160*
Monocyte count, ( $\times 10^3/\mu\text{L}$ ), mean ± SD	0.51 ± 0.3		0.47 ± 0.19		0.883 ‡
C-reactive protein, (mg/L), mean ± SD	74.7 ± 68.71		84 ± 38.56		0.319 ‡
Troponin T, (ng/mL), mean ± SD	0.013 ± 0.012		0.023 ± 0.026		0.340 ‡
Procalcitonin, (ng/mL), mean ± SD	0.52 ± 2.29		0.42 ± 0.72		0.176 ‡
Lactate dehydrogenase, (U/L), mean ± SD	328.34 ± 136.66		322.38 ± 95.27		0.905 ‡
Creatine kinase, (U/L), mean ± SD	159.02 ± 177.14		157.25 ± 81.12		0.172 ‡



**Table 3** (continued)

	Patients with—Conjunctival RT-PCR n:62	Patients with + Conjunctival RT-PCR (+) n:8	<i>P</i>
D-Dimer, mg/L, mean ± SD	1.41 ± 2.98	1.18 ± 1.36	0.803‡
Fibrinogen, mg/dl, mean ± SD	606.37 ± 158.86	541.5 ± 108.08	0.267*
Activated partial thromboplastin time (sec), mean ± SD	31.8 ± 3.67	35.04 ± 6.04	0.034*
Number of patients with previous COVID-19 treatment without hospitalization, (no, %)	30/62	2/8	25.00%
Duration of previous COVID-19 treatment, (days)	2.27 ± 3.07	1.13 ± 2.1	0.271‡

\*Independent t-Test; ‡Mann-Whitney U test; †chi-square test; ‡Fisher's Exact Test

64 samples were collected in the second and third week after initial symptom onset in that study [20]. In a study by Zhang et al., only one of 102 COVID-19 patients showed tear positivity, and the mean time of conjunctival sampling was 18.15 days [14]. Only in one study, SARS-CoV-2 RNA was detected in the conjunctival sample up to 27 days after disease onset, suggesting sustained viral replication [18].

We used conjunctival swab removal technique for conjunctival sampling. As in our study, two other studies with high rates of conjunctival PCR positivity used the conjunctival swab technique [10, 12]. Seah et al. obtained tear samples using Schirmer's test strip and reported negative results [20]. The Schirmer test strips can trap a few conjunctival exfoliated cells, and the negative result in that study may have been related to this situation. Arora et al. compared three methods of conjunctival sampling (conjunctival swab and Schirmer's test strips, conjunctival swab alone, and Schirmer's test strips alone). They reported that the samples collected with the Schirmer test had less viral load and the capability of detecting viral RNA was more with the conjunctival swab technique [11]. Unlike other studies, Dutescu et al. took the tear sample using a laboratory capillary and found a positivity rate of 28% [21].

The prevalence and necessity of conjunctivitis and ocular symptoms in patients with positive conjunctival RT-PCR results are controversial. Previous studies have reported that RNA shedding can occur in asymptomatic patients and may be a very important source of infection for other people and ophthalmologists [19]. In our study, none of the patients with positive PCR results in tears had ocular symptoms. Three patients that had ocular symptoms, such as itching and foreign body sensation had negative results for conjunctival SARS-CoV-2. Zhou et al. reported the rate of ocular symptoms as 6% (eight of 121 patients). Ocular symptoms were itching, redness, tearing, discharge, and foreign body sensations. Ocular symptoms were seen in only one of three patients with positive conjunctival RT-PCR results; the remaining two patients were asymptomatic [22]. In Wu et al.'s study, 12 of 38 patients had ocular symptoms, such as conjunctival hyperemia, epiphora, chemosis, and increased secretion, and only two of them had tear positivity [15]. In another study, three of 43 patients had positive tear sample results. Of those three patients, one had foreign body sensation, one

had conjunctivitis, and the third had no symptoms [17]. Güemes-Villahoz et al. reported that COVID-19 patients with and without conjunctivitis showed the same rate of tear sample positivity (5.5%) [23]. Other studies also found that virus could be found in COVID-19 patients without conjunctivitis or ocular symptoms [10–12, 16]. On the contrary, Xia et al. reported that SARS-CoV-2 could only be detected in the tears and conjunctival secretions of COVID-19 patients with conjunctivitis because of the low viral load in the noninflamed tissues [24]. The absence of ocular symptoms in any of the patients with positive conjunctival results in our study and the results of the other studies mentioned above [10–12, 15–17, 22, 23] suggest that ocular inflammation is not a requirement for viral shedding in tears as suggested previously by Xia et al.

Demographic, clinical characteristics and laboratory results of all patients were investigated to assess whether a difference between the patients with and without ocular surface positivity existed and only gender was found different in our study. All patients in the group with ocular surface positivity were male. We think that this difference may be because the male population was outside the home more than females during the pandemic period and paid less attention to hand hygiene outside. No difference between the patients with positive and negative tear-conjunctival PCR tests in terms of blood tests was observed. This finding may be related to the similar disease severity of the patients.

The viral load can be assessed indirectly by the COVID-19 RT-PCR Ct value. The Ct value can be used to compare the viral loads from different body areas. Ziad et al. found significantly higher Middle East respiratory syndrome coronavirus (MERS-CoV) loads in tracheal aspirates compared to sputum and nasopharyngeal swab samples [25]. This finding suggests that the genome fraction and viral concentration are different in different areas of the body. In our study, the mean Ct value for samples taken from the conjunctiva was higher than the mean Ct value for the samples obtained from the nasopharynx of the same patients. This finding indicates a lower viral load in the conjunctiva. Considering that the ocular surface is an open environment and the virus may be rapidly transported through the nasolacrimal duct, the concentration of SARS-CoV-2 at the ocular surface is

likely to be low. Only a few studies in the literature comparing CT values in ocular and nasopharyngeal samples have been published. Ares et al., Karabela et al., and Gijs et al. reported results similar to ours [18, 26, 27].

There are many factors affecting the positivity rate of SARS-CoV-2 RNA detected in tears and conjunctival secretions in our study. First, conjunctival swab samples may trap a few exfoliated cells, which have a low chance of showing the virus. Second, the lack of sensitivity of RT-PCR kits may result in a low positive rate, which is also problematic in detecting of SARS-CoV-2 in nasopharyngeal swap samples. Finally, antiviral treatment received by the patients before sampling may have affected the results. When all these factors are considered, the rate of virus infection on the ocular surface may be much higher than we could detect.

The limitations of this study were the small number of patients, one-time sampling (performed only on the first day of admission), and the lack of biomicroscopic slit-lamp examinations because of the sensitive conditions of the patients and the risk to healthcare professionals. The importance of this study is that it is one of the few studies in the literature in which Ct values from both nasopharyngeal and conjunctival samples of SARS-CoV-2 patients were obtained together and compared.

In conclusion, this study showed positive results (11.43% of patients) for SARS-CoV-2 RNA in the conjunctival swaps of the COVID-19 patients with or without ocular manifestations in the early phase of the disease. SARS-CoV-2 virus may be present on the ocular surface, and the ocular surface may be a potential site of virus replication and more importantly, act as a potential route for the virus transmission from the eye to the respiratory and gastrointestinal tract. Therefore, eye protection (face shield, goggles or protective slit-lamp shield), hand hygiene and other personal protection procedures are recommended to healthcare workers who are in direct contact with patients' eye secretions or ocular surfaces till the end of the COVID-19 pandemic.

**Author's Contribution** Involved in design and conduct of the study (MO, DK, SA, HE, FO); preparation and review of the study (MO, DK, SA, HE, FO); data collection (MO, DK, SA); and statistical analysis (MO).

**Funding** This study was funded by the authors and did not receive any grant from finance agencies in the public or commercial sectors.

#### Declarations

**Competing interests** The authors declare no competing interests.

**Conflict of interest** The authors declare that they have no conflict of interest.

**Ethical approval** The study was approved by the Institutional Review Board of the Samatya Training and Research Hospital Ethics Committee (#2705) and was conducted in accordance with the tenets of the Helsinki Declaration.

**Informed consent** Informed consent was obtained from all individual participants included in the study.

#### References

1. Belser JA, Rota PA, Tumpey TM (2013) Ocular tropism of respiratory viruses. *Microbiol Mol Biol Rev* 77(1):144–156. <https://doi.org/10.1128/MMBR.00058-12>
2. Napoli PE, Nioi M, d'Aloja E, Fossarello M (2020) The ocular surface and the coronavirus disease 2019: Does a dual “Ocular Route” exist? *J Clin Med* 9(5):1269. <https://doi.org/10.3390/jcm9051269>
3. Li JO, Lam DSC, Chen Y, Ting DSW (2020) Novel Coronavirus disease 2019 (COVID-19): the importance of recognising possible early ocular manifestation and using protective eyewear. *Br J Ophthalmol* 104(3):297–298. <https://doi.org/10.1136/bjophthalmol-2020-315994>
4. Hoffmann M, Kleine-Weber H, Schroeder S, Krüger N, Herrler T, Erichsen S, Schiergens TS, Herrler G, Wu NH, Nitsche A, Müller MA, Drosten C, Pöhlmann S (2020) SARS-CoV-2 cell entry depends on ACE2 and TMPRSS2 and is blocked by a clinically proven protease inhibitor. *Cell* 181(2):271–280.e8. <https://doi.org/10.1016/j.cell.2020.02.052>
5. Fodoulian L, Tuberosa J, Rossier D, Boillat M, Kan C, Pauli V, Egervari K, Lobrinus JA, Landis BN, Carleton A, Rodriguez I (2020) SARS-CoV-2 receptors and entry genes are expressed in the human olfactory neuroepithelium and brain. *iScience*. 23(12):101839. Doi: <https://doi.org/10.1016/j.isci.2020.101839>
6. Zhang B, Wang Q, Liu T, Dou SQ, Qi X, Jiang H, Qi BX, Zhang B, Zhou QJ (2020) A special on epidemic prevention and control: analysis on expression of 2019-nCoV related ACE2 and TMPRSS2 in eye tissues. *Chin J Ophthalmol* 56(6):438–446. <https://doi.org/10.3760/cma.j.cn112142-20200310-00170>
7. Senanayake P, Drazba J, Shadrach K, Milsted A, Rungger-Brandle E, Nishiyama K, Miura S, Karnik S, Sears JE, Hollyfield JG (2007) Angiotensin II and its receptor subtypes in the human retina. *Invest Ophthalmol Vis Sci* 48(7):3301–3311. <https://doi.org/10.1167/iovs.06-1024>
8. Li YC, Bai WZ, Hashikawa T (2020) The neuroinvasive potential of SARS-CoV2 may play a role in the respiratory failure of COVID-19 patients. *J Med Virol* 92(6):552–555. <https://doi.org/10.1002/jmv.25728>
9. Deng W, Bao L, Gao H, Xiang Z, Qu Y, Song Z, Gong S, Liu J, Liu J, Yu P, Qi F, Xu Y, Li F, Xiao C, Lv Q, Xue J, Wei Q, Liu M, Wang G, Wang S, Yu H, Chen T, Liu X, Zhao W, Han Y, Qin C (2020) Ocular conjunctival inoculation of SARS-CoV-2 can cause mild COVID-19 in rhesus macaques. *Nat Commun* 11(1):4400. <https://doi.org/10.1038/s41467-020-18149-6>
10. Mahmoud H, Ammar H, El Rashidy A, Ali AH, Hefny HM, Mounir A (2020) Assessment of coronavirus in the conjunctival tears and secretions in patients with SARS-CoV-2 infection in Sohag Province. *Egypt Clin Ophthalmol* 14:2701–2708. <https://doi.org/10.2147/OPHTH.S270006>
11. Arora R, Goel R, Kumar S, Chhabra M, Saxena S, Manchanda V, Pumma P (2021) Evaluation of SARS-CoV-2 in tears of patients with moderate to severe COVID-19. *Ophthalmology* 128(4):494–503. <https://doi.org/10.1016/j.ophtha.2020.08.029>
12. Kaya H, Çalışkan A, Okul M, Sarı T, Akbudak İH (2020) Detection of SARS-CoV-2 in the tears and conjunctival secretions of Coronavirus disease 2019 patients. *J Infect Dev Ctries* 14(9):977–981. <https://doi.org/10.3855/jidc.13224>
13. Guan WJ, Ni ZY, Hu Y, Liang WH, Ou CQ, He JX, Liu L, Shan H, Lei CL, Hui DSC, Du B, Li LJ, Zeng G, Yuen KY, Chen RC, Tang CL, Wang T, Chen PY, Xiang J, Li SY, Wang JL, Liang ZJ, Peng YX, Wei L, Liu Y, Hu YH, Peng P, Wang JM, Liu JY, Chen Z, Li G, Zheng ZJ, Qiu SQ, Luo J, Ye CJ, Zhu SY, Zhong NS; China Medical Treatment Expert Group for Covid-19 (2020) Clinical characteristics of coronavirus disease 2019 in China. *N Engl J Med* 382(18):1708–1720. <https://doi.org/10.1056/NEJMoa2002032>
14. Zhang X, Chen X, Chen L, Deng C, Zou X, Liu W, Yu H, Chen B, Sun X (2020) The evidence of SARS-CoV-2 infection on ocular surface. *Ocul Surf* 18(3):360–362. <https://doi.org/10.1016/j.jtos.2020.03.010>
15. Wu P, Duan F, Luo C, Liu Q, Qu X, Liang L, Wu K (2020) Characteristics of ocular findings of patients with coronavirus disease 2019 (COVID-19) in Hubei Province. *China JAMA Ophthalmol* 138(5):575–578. <https://doi.org/10.1001/jamaophthalmol.2020.1291>
16. Xie HT, Jiang SY, Xu KK, Liu X, Xu B, Wang L, Zhang MC (2020) SARS-CoV-2 in the ocular surface of COVID-19 patients. *Eye Vis (Lond)* 7:23. <https://doi.org/10.1186/s40662-020-00189-0>
17. Karimi S, Arabi A, Shahraki T, Safi S (2020) Detection of severe acute respiratory syndrome Coronavirus-2 in the tears of patients with Coronavirus disease 2019. *Eye (Lond)* 34(7):1220–1223. <https://doi.org/10.1038/s41433-020-0965-2>
18. Rodríguez-Ares T, Lamas-Francis D, Treviño M, Navarro D, Cea M, López-Valladares MJ, Martínez L, Gude F, Touriño R (2021) SARS-CoV-2 in conjunctiva and tears

- and ocular symptoms of patients with COVID-19. *Vision (Basel)* 5(4):51. <https://doi.org/10.3390/vision5040051>
19. Loon SC, Teoh SC, Oon LL, Se-Thoe SY, Ling AE, Leo YS, Leong HN (2004) The severe acute respiratory syndrome coronavirus in tears. *Br J Ophthalmol* 88(7):861–863. <https://doi.org/10.1136/bjoo.2003.035931>
  20. Seah IYJ, Anderson DE, Kang AEZ, Wang L, Rao P, Young BE, Lye DC, Agrawal R (2020) Assessing viral shedding and infectivity of tears in coronavirus disease 2019 (COVID-19) patients. *Ophthalmology* 127(7):977–979. <https://doi.org/10.1016/j.ophtha.2020.03.026>
  21. Dutescu RM, Banasik P, Schildgen O, Schrage N, Uthoff D (2021) Detection of coronavirus in tear samples of hospitalized patients with confirmed SARS-CoV-2 from oropharyngeal swabs. *Cornea* 40(3):348–350. <https://doi.org/10.1097/ICO.0000000000002562>
  22. Zhou Y, Duan C, Zeng Y, Tong Y, Nie Y, Yang Y, Chen Z, Chen C (2020) Ocular findings and proportion with conjunctival SARS-COV-2 in COVID-19 patients. *Ophthalmology* 127(7):982–983. <https://doi.org/10.1016/j.ophtha.2020.04.028>
  23. Güemes-Villahoz N, Burgos-Blasco B, Vidal-Villegas B, Garcia-Feijoo J, Arriola-Villalobos P, Martínez-de-la-Casa JM, Diaz-Valle D, Konstas AG (2020) Novel insights into the transmission of sars-cov-2 through the ocular surface and its detection in tears and conjunctival secretions: a review. *Adv Ther* 37(10):4086–4095. <https://doi.org/10.1007/s12325-020-01442-7>
  24. Xia J, Tong J, Liu M, Shen Y, Guo D (2020) Evaluation of coronavirus in tears and conjunctival secretions of patients with SARS-CoV-2 infection. *J Med Virol* 92(6):589–594. <https://doi.org/10.1002/jmv.25725>
  25. Memish ZA, Al-Tawfiq JA, Makhdoom HQ, Assiri A, Alhakeem RF, Albarrak A, Alsubaie S, Al-Rabeeh AA, Hajomar WH, Hussain R, Kheyami AM, Almutairi A, Azhar EI, Drosten C, Watson SJ, Kellam P, Cotten M, Zumla A (2014) Respiratory tract samples, viral load, and genome fraction yield in patients with Middle East respiratory syndrome. *J Infect Dis* 210(10):1590–1594. <https://doi.org/10.1093/infdis/jiu292>
  26. Karabela Y, Karabela SN, Ozbas M, Kasikci H, Kart Yasar K (2021) Investigation of SARS-CoV-2 in tear and conjunctival secretions of hospitalized patients with clinically-confirmed COVID-19 pneumonia. *BMC Infect Dis* 21(1):918. <https://doi.org/10.1186/s12879-021-06630-6>
  27. Gijs M, Veugen JMJ, Wolffs PFG, Savelkoul PHM, Tas J, van Bussel BCT, de Kruif MD, Henry RMA, Webers CAB, Dickman MM, Nuijts RMMA (2021) In-Depth investigation of conjunctival swabs and tear fluid of symptomatic covid-19 patients, an observational cohort study. *Transl Vis Sci Technol* 10(12):32. <https://doi.org/10.1167/tvst.10.12.32>

**Publisher's Note** Springer Nature remains neutral with regard to jurisdictional claims in published maps and institutional affiliations.