


Correction of hyperopia with astigmatism following radial keratotomy with daily disposable plus spherical contact lens: a case report

Yun-Wen Chen · Jiahn-Shing Lee · Chiun-Ho Hou · Ken-Kuo Lin 

Received: 5 June 2017 / Accepted: 23 August 2017 / Published online: 30 August 2017
© The Author(s) 2017. This article is an open access publication

Abstract

Purpose To report the refractive correction in a case of hyperopia and astigmatism following radial keratotomy.

Methods A case report.

Results A 47-year-old woman, who had undergone refractive surgery for radial keratotomy in both eyes 22 years before the present study, presented to our clinic with blurred vision. Her best corrected visual acuity, with spectacle correction of +3.50 DS/−1.50 DCX130° in the right eye and +3.75 DS/−1.50 DCX80° in the left eye, was 0.2 logMAR and 0.3 logMAR, respectively. Her keratometric readings were 35.75 D/36.75 D at 74° and 35.25 D/36.25 D at 61°, respectively. Prompted by intolerance to glasses, the patient requested for contact lenses. First, we applied a rigid, gas-permeable contact lens. However, we noted poor fitting due to central corneal flattening. Subsequently, we applied a conventional plus spherical soft contact lens (PSSCL), which is thick in the

center and can therefore correct hyperopia and low-grade astigmatism simultaneously. The conventional PSSCL showed slightly inferior decentration, with good movement, and the patient was satisfied with it. After ascertaining the patient's living habits, we decided that a daily disposable soft contact lens would most meet her needs. The final prescription was a daily disposable PSSCL; the patient was satisfied with her corrected visual acuity of 0.0 logMAR in the right eye and 0.0 logMAR in left eye. Her daily disposable PSSCL-corrected visual acuity was stable during the 10-month follow-up.

Conclusion For patients displaying hyperopia with astigmatism following radial keratotomy, the PSSCL may confer better corrected visual acuity and acceptability.

Keywords Radial keratotomy · Hyperopia · Astigmatism

Y.-W. Chen

Department of Ophthalmology, Kaohsiung Chang Gung Memorial Hospital, Chang Gung University College of Medicine, Taoyuan, Taiwan

J.-S. Lee · C.-H. Hou · K.-K. Lin (✉)

Department of Ophthalmology, LinKo Chang Gung Memorial Hospital, Chang Gung University College of Medicine, No.5, Fuxing St., Guishan Dist., Taoyuan City 333, Taiwan
e-mail: d12093@cgmh.org.tw

Introduction

Radial keratotomy (RK) is performed using radial incisions in the corneal stroma, producing a wound that is associated with midperipheral bulging of the cornea, compensatory central corneal flattening, and decreased refractive power. For this reason, progressive hyperopia after RK is not uncommon [1, 2]. In

fact, in the Prospective Evaluation of Radial Keratotomy (PERK) study, hyperopic shift after RK continued in many patients at an average rate of +0.21 diopters (D) per year for the first 6 months to 2 years after the surgery, and at +0.06 D per year between the second and tenth years after surgery [3, 4]. Therefore, patients who have undergone RK may present with hyperopia many years after the procedure; in such patients, this condition may be related to the corneal incisions, lens aging (including cataract formation), or both [5]. With regard to ocular surgical treatment for RK patients presenting with hyperopia, laser-assisted in situ keratomileusis (LASIK) and surface ablation have been effective [6, 7]. In terms of non-surgical correction methods, contact lenses, including rigid gas-permeable contact lenses (RGPCs), orthokeratology-designed RGPCs (OD-RGPCs), hybrid lenses, and soft contact lenses (SCLs) [8, 9], may improve vision. In the present report, we present a case of hyperopia with astigmatism in a woman who had undergone RK 22 years previously; her vision was well refractive corrected using a plus spherical SCL (PSSCL).

Case report

A 47-year-old woman visited our outpatient clinic complaining of progressive blurred vision in both eyes. In 1994, she had undergone refractive surgery for RK in both eyes at the age of 25 years, and her preoperative refractive error values were -6.5 D in the right eye and -8.5 D in the left eye. Her uncorrected visual acuity was 0.4 logMAR in both eyes, and her autorefractometer (Topcon RM6000, Japan) was $+3.75$ DS/ -1.50 DCX129° in the right eye and $+4.00$ DS/ -1.25 DCX82° in the left eye. Her best corrected visual acuity (BCVA) with spectacle correction of $+3.50$ DS/ -1.50 DCX130° in the right eye and $+3.25$ DS/ -1.00 DCX80° in the left eye was 0.2 logMAR in the right eye and 0.3 logMAR in the left eye. Her keratometric readings were 35.75 D/36.75 D at 74° in the right eye and 35.25 D/36.25 D at 61° in the left eye.

Slit lamp examination revealed a clear cornea with eight radial incisional scars in both eyes; both lenses were clear. Her optic zone after the RK procedure measured 2.4–2.5 mm in the right eye and 2.2–2.3 mm in the left eye. A fundus examination was unremarkable. The intraocular pressure was

19 mmHg in both eyes. The corneal topography of both eyes was obtained using the Oculus Pentacam (Oculus Optikgeräte GmbH, Wetzlar, Germany; Figs. 1, 2); corneal central flattening with refractive powers of 27–30 D was noted (Figs. 3, 4). The patient was therefore diagnosed as having hyperopia with astigmatism following RK.

Prompted by an intolerance of glasses, the patient asked for treatment using contact lenses. At first, we applied an RGPC. However, we noted marked decentration and poor fitting due to central corneal flattening, because the lens did not have a sufficiently flat base curve. Next, we applied a conventional PSSCL, which is thick in the center and can therefore correct hyperopia and low-grade astigmatism simultaneously. The conventional PSSCL showed slightly inferior decentration, with good movement, and the patient was satisfied with her corrected visual acuity. Subsequently, after ascertaining the patient's living habits, we decided that a daily disposable contact lens would most meet her needs. The final prescription was a Johnson & Johnson® daily disposable PSSCL ($+3.50$ D/base curve, 8.5 mm/diameter 14.2 mm in the right eye; $+3.75$ D/base curve 8.5 mm/diameter 14.2 mm in the left eye). The patient was satisfied with her corrected visual acuity of 0.0 logMAR in the right eye and 0.0 logMAR in the left eye. The daily disposable PSSCL-corrected visual acuity was stable during the 10-month follow-up period.

Discussion

RK is a refractive surgical method for correcting myopia. The procedure involves radial incisions in the paracentral to peripheral cornea; these induce central corneal flattening and reduce myopia. The complications of RK range from the seriously sight-threatening to less severe problems, including corneal perforations, accidental incisions across the visual axis, a decentered clear zone, limbal incisions, visual fluctuations, corneal edema [10], glare [10, 11], and falsely low IOP values [12]. RK may also confer a greater chance of iatrogenic keratoconus, although this speculation remains a matter of debate [13, 14]. Conversely, one case report suggested that corneal stability following RK may protect against keratoconus [13]. The long-term, unintended refractive outcomes of RK noted in the literature include BCVA

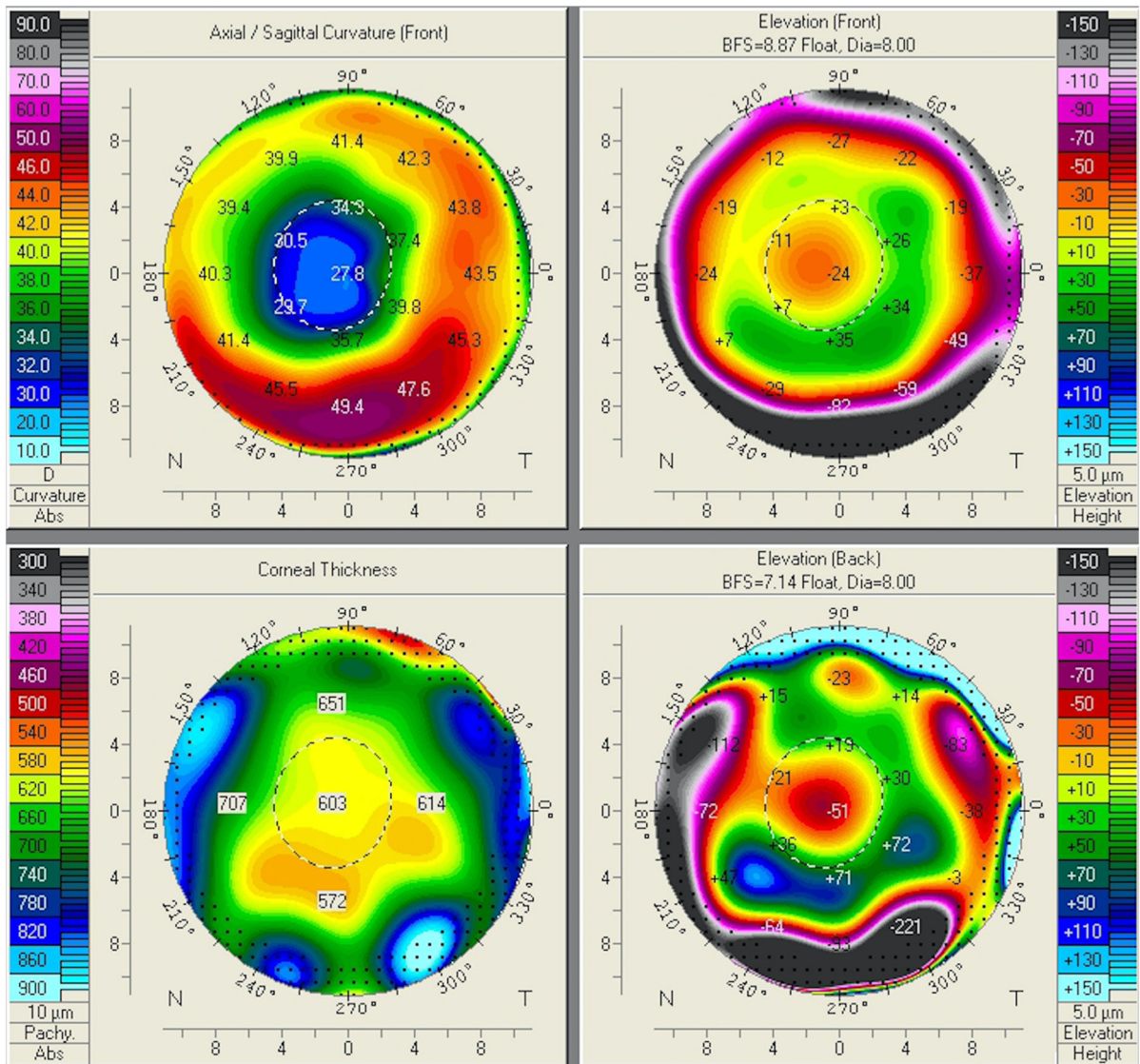


Fig. 2 Oculus Pentacam of the patient's left eye showing corneal curvature map

that they are more expensive and have limited product specifications.

In the present study, after trying RGPCL, we applied a conventional PSSCL, which is thick in the center and which can therefore correct hyperopia and low-grade astigmatism simultaneously. The conventional PSSCL showed slightly inferior decentration, with good movement, and the patient was satisfied with her corrected visual acuity.

The present case suggests that PSSCLs are ideal for refractive correction of hyperopia with astigmatism following RK, because they have a thick center that

may better correct both astigmatism and hyperopia. Furthermore, PSSCLs with a thick center can correct the flat central cornea caused by RK; for this reason, they may possess better centration and stability, as well as confer a more stable tear lens.

PSSCLs are easy to apply and are relatively affordable. After ascertaining the living habits of our patient, we decided that a daily disposable SCL might most meet her needs. Ultimately, we prescribed a daily disposable PSSCL, which has all the advantages of the conventional PSSCL and avoids the need for disposable plus toric SCLs, which are unavailable in Taiwan.

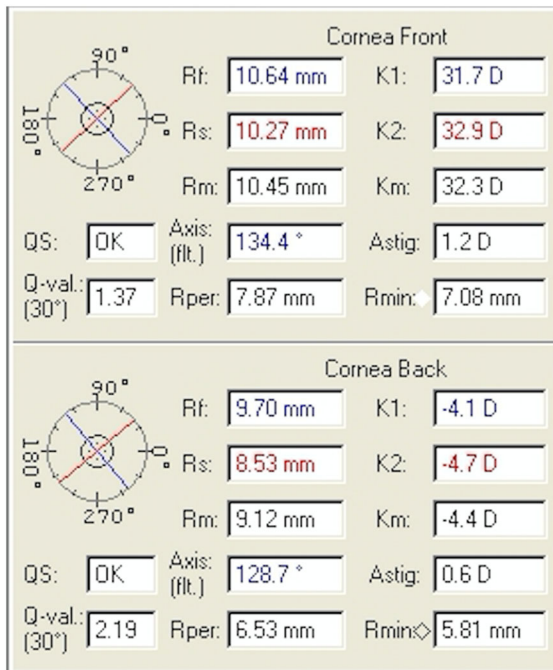


Fig. 3 Oculus Pentacam of the patient's right eye showing corneal parameters

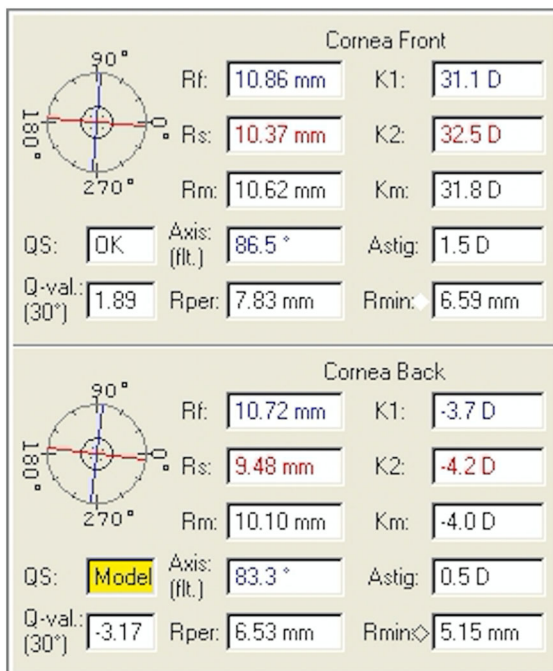


Fig. 4 Oculus Pentacam of the patient's left eye showing corneal parameters

Our patient showed acceptable fitting and reached a satisfactory corrected visual acuity.

This case study followed the Declaration of Helsinki on medical protocol.

Conclusion

Patients diagnosed as having hyperopia with astigmatism following RK may benefit from the PSSCL, as the lens confers better corrected visual acuity and acceptability.

Acknowledgements We would like to acknowledge Wei-Yu Chiang for his helpful suggestions in the treatment plan and Ching-Hsi Hsiao for providing this case.

Open Access This article is distributed under the terms of the Creative Commons Attribution 4.0 International License (<http://creativecommons.org/licenses/by/4.0/>), which permits unrestricted use, distribution, and reproduction in any medium, provided you give appropriate credit to the original author(s) and the source, provide a link to the Creative Commons license, and indicate if changes were made.

References

1. Leccisotti A, Fields SV (2015) Femtosecond-assisted laser in situ keratomileusis for consecutive hyperopia after radial keratotomy. *J Cataract Refract Surg* 41:1594–1601
2. Deitz MR, Sanders DR, Raanan MG (1986) Progressive hyperopia in radial keratotomy. Long-term follow-up of diamond-knife and metal-blade series. *Ophthalmology* 93:1284–1289
3. Forister JF, Sun A, Weissman BA (2007) Progress report on a post-radial keratotomy patient 20 years after surgery. *Eye Contact Lens* 33:334–337
4. Waring GO 3rd, Lynn MJ, McDonnell PJ (1994) Results of the prospective evaluation of radial keratotomy (PERK) study 10 years after surgery. *Arch Ophthalmol* 112:1298–1308
5. Christopher JR, Brian S, Elizabeth AD et al (2012) Incisional corneal surgery. Basic and Clinical Science Course, section 13. San Francisco, CA
6. Linebarger EJ, Hardten DR, Lindstrom RL (2000) Laser-assisted in situ keratomileusis for correction of secondary hyperopia after radial keratotomy. *Int Ophthalmol Clin* 40:125–132
7. Joyal H, Gregoire J, Faucher A (2003) Photorefractive keratectomy to correct hyperopic shift after radial keratotomy. *J Cataract Refract Surg* 29:1502–1506
8. Simunovic MP (1997) Post radial keratotomy RGP fitting—a case study. *Contact Lens Anter Eye* 20:87–90

9. Schlitzer RL (1992) Preservative uptake by soft contact lenses. *Contact Lens Spectr* 7:41–43
10. Bergmanson JP, Farmer EJ (1999) A return to primitive practice? Radial keratotomy revisited. *Contact Lens Anter Eye* 22:2–10
11. Rashid E, Waring GO (1989) Complications of radial and transverse keratotomy. *Surv Ophthalmology* 34:73–106
12. Scheuerle AF, Martin M, Voelcker HE et al (2008) Undetected development of glaucoma after radial keratotomy. *J Refract Surg* 24:51–54
13. Sousa JM, Hirai FE, Sato EH (2013) Keratoconus and corneal stability after radial keratectomy in the fellow eye: case report. *Arq Bras Oftalmol* 76:195–196
14. Kim H, Choi JS, Joo CK (2006) Corneal ectasia after PRK: clinicopathologic case report. *Cornea* 25:845–848
15. Waring GO (1998) Refractive surgery. In: Leibowitz (ed) *Corneal disorders: clinical diagnosis and management*. Saunders Company, Philadelphia, pp 1023–1105
16. Avetisov SE, Antonov AA, Vostrukhin SV (2015) Progressive hyperopic shift after radial keratotomy: possible causes. *Vestn Oftalmol* 131:13–18
17. Liu YM, Xie P (2016) The safety of orthokeratology—a systematic review. *Eye Contact Lens* 42:35–42
18. Koffler BH, Sears JJ (2013) Myopia control in children through refractive therapy gas permeable contact lenses: is it for real? *Am J Ophthalmol* 156:1076.e1–1081.e1
19. Wang B, Naidu RK, Qu X (2017) Factors related to axial length elongation and myopia progression in orthokeratology practice. *Plos One* 12:e0175913
20. Alio JL, Belda JJ, Artola A et al (2002) Contact lens fitting to correct irregular astigmatism after corneal refractive surgery. *J Cataract Refract Surg* 28:1750–1757