



# Myocarditis following COVID-19 vaccination in adolescents and adults: a cumulative experience of 2021

Onyedika J. Ilonze<sup>1</sup> · Maya E. Guglin<sup>1</sup>

Accepted: 14 April 2022 / Published online: 22 April 2022

© The Author(s), under exclusive licence to Springer Science+Business Media, LLC, part of Springer Nature 2022

## Abstract

Clinical course and outcomes of myocarditis after COVID-19 vaccination remain variable. We retrospectively collected data on patients > 12 years old from 01/01/2021 to 12/30/2021 who received COVID-19 messenger RNA (mRNA) vaccination and were diagnosed with myocarditis within 60 days of vaccination. Myocarditis cases were based on case definitions by authors. We report on 238 patients of whom most were male ( $n = 208$ ; 87.1%). The mean age was  $27.4 \pm 16$  (range 12–80) years. Females presented at older ages ( $41.3 \pm 21.5$  years) than men  $25.7 \pm 14$  years ( $p = 0.001$ ). In patients > 20 years of age, the mean duration from vaccination to symptoms was  $4.8 \text{ days} \pm 5.5 \text{ days}$ , but in < 20, it was  $3.0 \pm 3.3 \text{ days}$  ( $p = 0.04$ ). Myocarditis occurred most commonly after the Pfizer-BioNTech mRNA vaccine ( $n = 183$ ; 76.45) and after the second dose ( $n = 182$ ; 80%). Symptoms started  $3.95 \pm 4.5$  days after vaccination. The commonest symptom was chest pain ( $n = 221$ ; 93%). Patients were treated with non-steroidal anti-inflammatory drugs ( $n = 105$ ; 58.3%), colchicine ( $n = 38$ ; 21.1%), or glucocorticoids ( $n = 23$ ; 12.7%). About 30% of the patients had left ventricular ejection fraction but more than half recovered the on repeat imaging. Abnormal cardiac MRIs were common; 168 patients (96% of 175 patients that had MRI) had late gadolinium enhancement, while 120 patients (68.5%) had myocardial edema. Heart failure guideline-directed medical therapy use was common ( $n = 27$ ; 15%). Eleven patients had cardiogenic shock; and 4 patients required mechanical circulatory support. Five patients (1.7%) died; of these, 3 patients had endomyocardial biopsy/autopsy-confirmed myocarditis. Most cases of COVID-19 vaccine myocarditis are mild. Females presented at older ages than men and duration from vaccination to symptoms was longer in patients > 20 years. Cardiogenic shock requiring mechanical circulatory support was seen and mortality was low. Future studies are needed to better evaluate risk factors, and long-term outcomes of COVID-19 mRNA vaccine myocarditis.

**Keywords** Pfizer-BioNTech BNT162b2 vaccine · Moderna mRNA-1273 vaccine · Myocarditis · Mechanical circulatory support · Cardiogenic shock · Mortality

## Background

The Food and Drug Administration (FDA) granted emergency use authorization for the Pfizer-BioNTech and Moderna COVID-19 vaccines in December 2020 and to the Janssen COVID-19 vaccine in February 2021. In May 2021, the FDA also included children 12 years and older. The European Medical Agency (granted approval to two mRNA-based vaccines: BNT162b2 (Comirnaty, BioNTech/Pfizer)

and mRNA1273 (Spikevax, Moderna) and two recombinant vector-based vaccines: adenovirus type 26 vector COVID-19 Vaccine Janssen (Janssen, Johnson & Johnson), and the recombinant chimpanzee adenoviral vector vaccine ChAdOx1 nCoV-19 (Vaxzervria, AstraZeneca).

Cases of myocarditis have been reported following coronavirus disease 2019 (COVID-19) vaccination initially in the US military [1, 2] and Israel [3] but now more commonly in the rest of the world. Myocarditis has been associated with vaccines for illnesses such as small pox [4] and influenza [5] with limited outcome data. Since expanding access of the Pfizer-BioNTech COVID-19 vaccine to those as young as 12 years of age, suspected myocarditis temporally related to the vaccine has also been reported [6–8]. On June 23, 2021, the Centers for Disease Control and Prevention (CDC) Advisory Committee on Immunization Practices reported

✉ Onyedika J. Ilonze  
oilonze@iu.edu

<sup>1</sup> Division of Cardiovascular Medicine, Krannert Cardiovascular Institute, Indiana University School of Medicine, 1801 North Senate Boulevard Suite 2000, Indianapolis, IN 46202, USA

a likely link between mRNA COVID-19 vaccination and myocarditis, in particular, in those  $\leq 39$  years old [9].

Available data points to a benign course from COVID-19 vaccine myocarditis. Most reports of COVID-19 vaccine myocarditis have been limited to adults and adolescents in North America [10], or Israel [11], and such series do not typically report on cases in older patients or females. Although it is difficult to prove causality, cases of myocarditis may coincide with vaccination but be unrelated especially in a time of mass vaccination.

We aim to describe a systematic literature review of myocarditis associated with the COVID-19 vaccine in all patients reported globally.

## Methods

### Study design

We conducted a systematic review of the literature conducted following PRISMA guidelines [12] to retrieve publications containing data regarding clinical presentations and outcomes of patients with COVID-19 vaccination-associated myocarditis. Registration of a review protocol was unnecessary because data contained in published literature was used for this study.

### Eligibility criteria

The publications included were full-length manuscripts retrieved with our search that contained data on one or more patients 12 years old or older, who received a COVID-19 vaccine and had an acute presentation with myocarditis. Myocarditis was diagnosed by one or more of the following characteristics: (1) clinically suspected myocarditis [13], (2) elevated troponin levels and abnormal electrocardiograms (ECGs), and (3) cardiac function on non-invasive imaging, or findings consistent with myocarditis on cardiac magnetic resonance imaging (cMRI), including myocardial edema or late gadolinium enhancement or on endomyocardial biopsy [14]. Publications were excluded if these were written in languages other than English without an English interpretation or had insufficient data on individual patients.

### Search methods

Following PRISMA guidelines [12], a systematic search of the literature was conducted using PubMed. The keywords were “COVID-19 vaccine,” “coronavirus,” and “vaccine” in combination with “myocarditis,” and “myopericarditis.” In relevant papers, the list of references was manually searched as well. The search was limited to the articles published in 2021 (January 1 to December 31). All the identified

publications were screened to exclude duplicates by comparing titles, authors, and digital object identifiers. After removing duplicates, all the remaining publications were screened for exclusion criteria by reading titles and abstracts. After removing publications that met exclusion criteria, the remaining publications were further screened for inclusion and exclusion criteria by reading the full-text publications. The list of references for each relevant publication was manually examined. The search identified 260 publications. After removing duplicates and screening for exclusion and inclusion criteria, 106 publications were included in the analysis (Fig. 1).

### Data extraction process

The included publications were analyzed in a qualitative manner for authors' names, date of publication, country, and the timeline of the events. These publications were used to identify our subjects of interest. Once identified, subjects were labeled and their data extracted.

These data were used to perform quantitative analyses of demographics, type of vaccine administered, clinical presentation, comorbidities, biomarkers, dynamic changes of left ventricular ejection fraction (LVEF), wall motion abnormalities, electrocardiogram (ECG) changes, cardiac MRI (cMRI) data, diagnostic evaluation, treatment modalities, and outcomes (survival to discharge).

## Results

### Patient characteristics

We identified 238 individual patients within the specified period. The mean age of the patients was  $27.4 \pm 16$  (range 12–80) years. Majority of the patients ( $N=208$ ; 87.1%) were male and there was wide geographical spread with most of the patients being from North America (57.1%), Europe (17.6%), and Israel (15.4%). In males, the mean age at presentation was  $25.7 \pm 14$  and in females was  $41.3 \pm 21.5$  years ( $p=0.001$ ). Race and ethnicity data was not reported in most of the patients and was not included in the final table.

### Vaccination data, symptoms, and clinical course

Majority of the patients with myocarditis received the mRNA COVID-19 vaccines — Pfizer-BioNTech ( $n=183$ ; 76.4%) and Moderna (MRNA-1273) vaccines ( $n=46$ ; 19.3%). Four (1.7%) and 3 (1.3%) cases occurred after the AstraZeneca (ChAdOx1 nCoV-19) and Johnson and Johnson (Janssen COVID-19 vaccine) respectively. One (0.4%) case occurred after the Sinovac vaccine while the vaccine was unspecified in another case. Patients presented more frequently after the

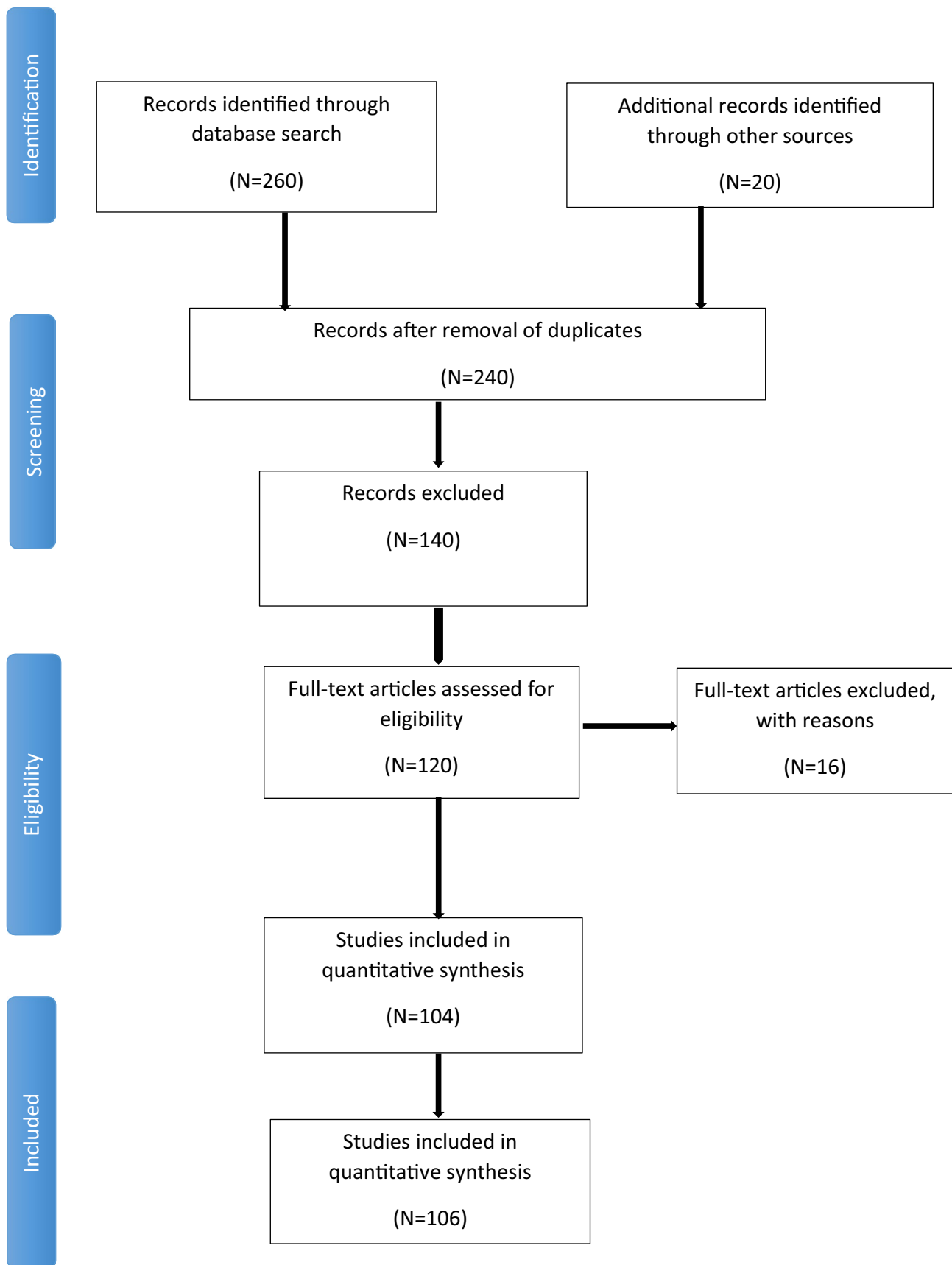


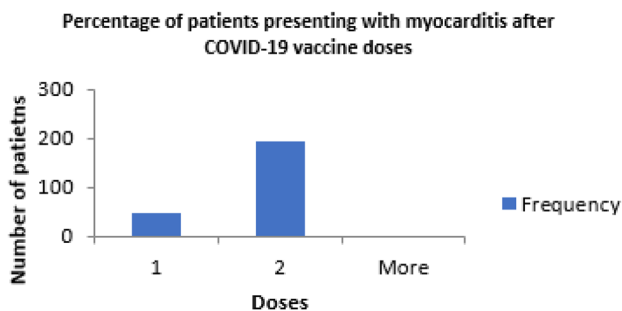
Fig. 1 Study selection flowchart

**Table 1** Demographic variables and history of COVID-19 infection

	<i>N</i> = 238
Age (years)	27.4 ± 16 (range 12–80)
○ ≤ 20 years	110 (47%)
○ ≥ 21 years	122 (53%)
○ Unspecified	6
Sex	
○ Male	208 (87.4%)
○ Female	27 (11.3%)
○ Not reported	3 (1.3%)
Geographic location ( <i>N</i> = 240)	
○ North America (US and Canada)	137 (57.1%)
○ Israel	37 (15.4%)
○ Europe	42 (17.6%)
○ Asia	20 (8.3%)
○ Latin America	2 (0.8%)
○ Australia	1 (0.4%)
○ Africa	1 (0.4%)
Known prior COVID-19 infection (by history or prior positive test)	7 (3%)

second vaccine dose (*n* = 182, 80%) (Table 1, Fig. 2). Onset of symptoms occurred at a mean of 3.95 ± 4.5 days after vaccine administration, with 27 patients (11.3%) presenting with symptoms 7 to 20 days and only 5 patients (2.1%) presenting with symptoms ≥ 21 days after vaccination. Chest pain was the most common symptom, occurring in 221 patients (93%). Fever and shortness of breath each occurred in 33.8% and 16.5% of patients, respectively (Table 1).

The mean duration from the vaccine administration to symptom onset was 3.7 ± 4.2 days in males and in females was 6.5 ± 7.2 days (*p* = 0.08). In male patients, Pfizer-BioNTech vaccine was received by 168 (80.8%) patients, Moderna-1273 35 (16.8%), Astra Zeneca 2 (0.9%), and Johnson and Johnson 2 (0.9%) patients. Female patients had the following vaccine distribution: Pfizer-BioNTech, 12 (44.4%); MRNA-1273, 11 (40.7%); Astra Zeneca, 2 (7.4%); Johnson and Johnson,

**Fig. 2** Percentage of patients presenting with myocarditis after 1st and 2nd COVID-19 vaccine doses

2 (7.4%); and 1 (3.7%) patient unspecified vaccine type. In patients > 20 years of age, the mean duration from vaccination to symptoms was 4.8 days ± 5.5 days and in those aged < 20, it was 3.0 ± 3.3 days (*p* = 0.04). The mean length of stay in patients > 20 years is 6.3 ± 9.9 days and in individuals aged < 20 years 3.3 ± 1.9 days (*p* = 0.23) (Table 2).

The mean hospital length of stay was 12 ± 21 days (range, < 1–129). The mean length of stay for males 3.9 ± 3.2 days and females for 13.6 ± 21.7 days (*p* = 0.02). Most patients (*n* = 105, 58.3%) were treated with non-steroidal anti-inflammatory drugs. Glucocorticoids were used in 23 patients (12.7%) while intravenous immunoglobulin was administered to 13 (7.2%) patients (Table 4). Colchicine was used in 38 patients (21.1%). Eleven patients (6.1%) had complete clinical improvement without any anti-inflammatory therapies. Guideline-directed medical therapy mainly angiotensin converting enzyme inhibitors (ACEI), angiotensin receptor blockers (ARBs), and beta blockers (BB) was used concurrently in 27 (15%) patients.

### Laboratory data

Of the patients who had cardiac troponin recorded (*n* = 212), all patients had elevated troponins; troponin I (mean 13.7 ng/mL; IQR 4.4–14.7; *n* = 112), troponin T (mean, 4.2 ng/mL; IQR, 0.57–3.21 ng/mL; *n* = 17), or high-sensitivity troponin (mean 1835 ng/mL; IQR, 161–1631.5 ng/mL; *n* = 83; Table 3). Mean C-reactive protein levels were elevated (8.5 mg/dL; IQR, 0–99.9 mg/dL; *n* = 145). The mean brain natriuretic peptide level was elevated (1812 pg/mL; IQR, 26.1–100.5 pg/mL; *n* = 32) and median NT-proBNP (N-terminal pro-B-type natriuretic peptide) was also elevated (6637 pg/mL; IQR, 350.5–4181.5) pg/mL; *n* = 19; Table 3).

### Electrocardiograms and arrhythmias

Electrocardiograms (ECGs) were obtained in 210 patients (88.2%); 183 (87.2%) of the ECGs were abnormal. The most common abnormal ECG findings were ST-segment and T-wave abnormalities/elevation (*n* = 168, 80%; Table 3), with low voltages also seen in 2 patients (0.9%). No follow-up data was available for these 2 patients.

Non-sustained ventricular tachycardia occurred in 4 patients (1.9%), on ECG, telemetry. Premature ventricular contractions (*n* = 2; 0.9%), atrial tachycardia (*n* = 2; 0.9%), first-degree atrio-ventricular block (*n* = 1; 0.5%), and junctional rhythm (*n* = 2; 0.9%) were rare.

### Cardiac imaging

Echocardiography was performed on majority of patients (*N* = 231; 97%). Most patients (*n* = 160, 69.2%) had normal

**Table 2** COVID-19 vaccine and clinical data

	<i>N</i> = 238
Brand of COVID-19 vaccine	
○ Pfizer-BioNTech	183 (76.9%)
○ Moderna	46 (19.3%)
○ Johnson and Johnson	3 (1.3%)
○ AstraZeneca (ChAdOx1-S)	4 (1.7%)
○ Sinovac	1 (0.4%)
○ Unspecified	1 (0.4%)
Dose of vaccine prior to symptoms	
○ 1st dose	46 (19.2%)
○ 2nd dose	190 (80%)
○ Unspecified	2 (0.8%)
Days from vaccine administration to symptom onset	3.95 ± 4.5
<b>Symptoms</b>	
○ Chest pain	221 (92.1%)
○ Fever (temperature > 100.4F or tactile)	81 (33.8%)
○ Shortness of breath	40 (16.5%)
○ Gastrointestinal symptoms (nausea, vomiting, diarrhea)	22 (9.2%)
○ General symptoms (fatigue, myalgia, weakness, anosmia)	93 (38.8%)
Intensive care unit stay	14 (5.8%)
Cardiogenic shock	11 (4.5%)
○ Inotrope/vasopressor use	8 (3.3%)
○ Veno-arterial extracorporeal mechanical oxygenation (VA-ECMO) and Impella CP®	4 (1.7%)
Length of stay (days)	12 ± 21 (range < 1–129)
Outpatient treatment	3 (1.2%)
Mortality (2 females and 3 males)	5 (1.7%)

systolic function, whereas 50 (21.6%) had mild, 4 (1.7%) had moderate, and 17 (1.4%) had severe dysfunction (Table 3). Thirty-five patients out of the 71 with LVEF < 55% had recovery of systolic function to normal, while most others had incomplete data reported in the case articles. Forty-three patients (18.6%) had pericardial effusion, but most were small.

Initial cMRI was performed in 178 patients and 175 (99%) had abnormalities. Among patients with abnormal cMRI, late gadolinium enhancement was noted in 168 (96%) and myocardial edema was present in 120 (68.5%) (Table 4). Of those with abnormal cMRI, most 145 (81.4%) occurred in patients with normal left ventricular systolic function on echocardiogram. Sixty-five (27.3%) patients had coronary angiograms as part of the evaluation and all patients had no significant obstructive disease on angiography.

### Mechanical circulatory support (MCS)

Although only 14 patients (5.8%) were managed in the intensive care units (ICU), inotropic or vasoactive support was

used in 11 (4.5%): of these, 11 patients met the criteria for cardiogenic shock but only 4 patients required mechanical circulatory support — 3 patients required veno-arterial extracorporeal membrane oxygenation (VA-ECMO) while one had Impella CP®. Of the 4 patients who required MCS, three out of them survived and one died.

### Mortality and endomyocardial biopsy

A total of 5 patients (1.7%) died — 2 females and 3 males, age ranging 22–70 years. Of the deaths, 2 patients received the Pfizer-BioNTech vaccines and 2 patients received mRNA-1273 vaccine while in one fatal case the received vaccine was Janssen Johnson & Johnson. Two deaths occurred after the 1st dose and 3 deaths after the second vaccine dose. All the patients who died had reduced ejection fraction on the initial admission. In 3 out of the 5 patients who died, endomyocardial biopsy or autopsy was performed and in all three cases myocarditis was confirmed.

Choi et al. reported on a 22-year-old male Korean military recruit had chest pain 5 days after the first dose of Pfizer-BioNTech (BNT162b2) vaccine and was found unresponsive

**Table 3** Laboratory, electrocardiogram, and imaging data

<b>Peak laboratory values</b>	
Troponin ( <i>N</i> =212)	
Troponin I (ng/mL) ( <i>N</i> =112) (Reference normal <0.04)	13.7 (IQR 4.4–14.7)
High-sensitivity troponin ( <i>N</i> =83) (Reference normal <15)	1835 (IQR 161.3–1631.5)
Troponin T (ng/mL) ( <i>N</i> =17) (Reference normal <0.04)	4.2 (IQR 0.57–3.21)
NT-proBNP (pg/mL) ( <i>N</i> =19) (Reference normal <125 pg/mL)	6637 (range 0–35,975, IQR 350.5–4181.5)
BNP (pg/mL) ( <i>N</i> =32) (Reference normal <100 pg/mL)	1812 (range 0–43,131, IQR 26.1–100.5)
C-Reactive protein (mg/dL) ( <i>N</i> =145) (Reference normal <0.3 mg/dL)	8.5 (range 0–99.9, IQR 2–8.9)
<b>Testing/imaging</b>	
Electrocardiogram (ECG) ( <i>N</i> =210)	
○ Abnormal	183 (87.2%)
○ Normal	27 (12.8%)
Abnormal ECG findings or arrhythmias ( <i>N</i> =183)	
○ ST or T wave changes/elevation	168 (80%)
○ Non-sustained VT (ECG or telemetry)	4 (1.9%)
○ Low voltage QRS	2 (0.95%)
○ PVCs (ECG or telemetry)	2 (0.95%)
○ Atrial tachycardia (ECG or telemetry)	2 (0.95%)
○ First degree atrioventricular block	1 (0.48)
○ Junctional rhythm	2 (0.95%)
Echocardiogram ( <i>N</i> =231)	
Left ventricular ejection fraction	
○ Normal	160 (69.2%)
○ Mild dysfunction (45–54%)	50 (21.6%)
○ Moderate dysfunction (35–44%)	4 (1.7%)
○ Severe dysfunction (<35%)	17 (7.3%)
○ Pericardial effusion (any)	43 (18.6%)
Cardiac MRI ( <i>N</i> =178)	
Abnormal findings ( <i>N</i> =175)	
○ Late gadolinium enhancement	168 (96%)
○ Myocardial edema	120 (68.5%)
Coronary angiogram ( <i>N</i> =62)	
○ No coronary artery disease	62 (100%)
Endomyocardial biopsy/autopsy	
○ Normal	3
○ Abnormal (suggestive of myocarditis)	10

*BNP* brain natriuretic peptide, *NT-proBNP* NT-pro brain natriuretic peptide, *PVC* premature ventricular contractions, *MRI* magnetic resonance imaging, *VT* ventricular tachycardia

with ventricular fibrillation and had cardiopulmonary resuscitation for 2 h and died [15]. Endomyocardial biopsy showed atrial myocarditis, with contraction band necrosis in addition to neutrophil and histiocyte infiltrates and patches of necrosis [15].

Abbate et al. reported on a 27-year-old male with trisomy 21 who presented in cardiogenic shock 2 days after his second Pfizer-BioNTech (BNT162b2) vaccine dose.

Echocardiogram showed severe left ventricular systolic dysfunction (LVEF 20%) and a small pericardial effusion. He had hemodynamically unstable ventricular tachycardia refractory to electrical cardioversion followed by pulseless electrical activity. He required VA-ECMO. Despite vasopressors, mechanical ventilation, and renal replacement therapy, multiorgan failure and refractory shock persisted and he died 21 h after presentation. Family declined autopsy [16].

**Table 4** Treatments received ( $N=180$ )

NSAIDs (including aspirin)	105 (58.3%)
Colchicine	38 (21.1%)
Guideline-directed medical therapy (GDMT)	27 (15%)
o BB alone	8
o ACEI/ARB alone	1
o ACEI/ARB and BB	18
Glucocorticoids (IV or oral)	23 (12.7%)
Intravenous immunoglobulin (IVIG)	13 (7.2%)
No anti-inflammatory medications	11 (6.1%)
Anakinra	2 (1.1%)
Unspecified (treatment not described)	60

*NSAIDs* nonsteroidal anti-inflammatory drugs; *IVIG* intravenous immunoglobulin, *GDMT* guideline-directed medical therapy — includes *ACEI* angiotensin converting enzyme inhibitors, *ARB* angiotensin receptor blockers, *BB* beta blockers, mineralocorticoid receptor antagonists

Verma et al. reported on a 42-year-old male who presented with chest pain 2 weeks after the 2nd dose of mRNA-1273 vaccine. Transthoracic echocardiogram showed global biventricular dysfunction (ejection fraction, 15%) and left ventricular hypertrophy. Coronary angiography revealed no coronary artery disease. He developed cardiogenic shock and died 3 days after presentation. Autopsy revealed biventricular myocarditis with inflammatory infiltrate admixed with macrophages, T-cells, eosinophils, and B cells. [17]

Ujueta et al. reported a case of a 62-year-old Uruguayan Caucasian female who presented with weakness 4 days after administration of the Janssen Johnson & Johnson COVID-19 vaccine. She was hypotensive and tachycardic. Laboratory tests revealed elevated troponin, lactic acidosis, NT-Pro-BNP, and leukocytosis. Echocardiogram revealed severe biventricular dysfunction with left ventricular ejection fraction of 29%, and small pericardial effusion. Coronary angiography showed elevated left-sided filling pressures, and no obstructive disease. Despite maximum inotropes and vasopressors, she had cardiac arrest and died. Autopsy revealed scattered positive CD3 immunostaining supporting T cell infiltration and multiple immunohistochemistry staining like CD163 suggesting lymphohistiocytic myocarditis with sparse eosinophils [18].

Nassar et al. reported a case of a 70-year-old Caucasian female who presented with dyspnea 2 days after receiving the Janssen COVID-19 vaccine. She was intubated on arrival. She had elevated troponin and procalcitonin and echocardiogram showed severely decreased left ventricular ejection fraction (10%), diffuse left ventricular hypokinesis. She was hypotensive and receiving vasopressors and antibiotic therapy and had renal failure requiring renal replacement therapy. The patient declined cardiac

catheterization and remained on medical therapy until her death on the eighth day of admission [19]. No autopsy was done.

## Discussion

The exact epidemiology of “traditional” (non-vaccine associated) myocarditis is difficult to ascertain. A Swedish study of 12,747 unselected routine autopsies over a 10-year period showed a frequency of histopathological myocarditis fulfilling the Dallas criteria of 1.06% [20]. A Finnish registry showed that myocarditis caused 0.19% (95% CI 0.18 to 0.19%) of all medical admissions, and 0.48% (95% CI 0.46 to 0.49%) of all cardiovascular admissions [21]. In the pre-COVID-19 era, vaccine-related myopericarditis among 620,195 reports filed at the Vaccine Adverse Event Reporting System (VAERS) between 1990 and 2018 was 0.1% [22]. As of June 5, CDC data showed 12 cases of myopericarditis in males (male rates of 16.9 (11.0–24.8) per million doses (95% CI)) and 6 cases in females (female rates of 3.2 (1.2–6.9) per million doses (95% CI)) after 2 doses of COVID-19 mRNA vaccine [23]. However, as of November 2021, VAERS had received ~989 reports of myocarditis or myopericarditis after COVID-19 vaccination mainly males between 12 and 29 years [23]. Montgomery et al. reported 23 male military personnel diagnosed with myocarditis after 2.8 million doses of COVID-19 vaccinations administered in the Military Health System, mostly after the second dose of mRNA COVID-19 vaccination, reflecting higher than expected numbers of myocarditis cases [2]. The Israeli Ministry of Health reported 148 myocarditis cases among 10.4 million vaccinated individuals occurring within 30 days of vaccination [24]. The prevalence of myocarditis in Israel was 1/20,000 for the 16- to 30-year group compared with 1/100,000 in the general population receiving the same vaccine [24].

This systematic review represents the largest up-to date international cohort of myocarditis that occurred within 60 days following COVID-19 vaccine. The initial clinical presentation of COVID-19 vaccine-associated myocarditis was similar to that of traditional myocarditis. Clinical symptoms such as chest pain, fever, and shortness of breath are common. Few patients 7 (3%) patients had a known prior COVID-19 infection.

In our series, females who presented with myocarditis post-vaccination were older than men ( $41.3 \pm 21.5$  vs  $25.7 \pm 14$  years,  $p=0.001$ ), were hospitalized for a longer duration ( $13.6 \pm 21.7$  days vs  $3.9 \pm 3.2$  days,  $p=0.02$ ), and had a trend towards longer time between the vaccination and onset of symptoms ( $6.5 \pm 7.2$  days vs  $3.7 \pm 4.2$  days in males,  $p=0.08$ ). Older patients also had a longer duration between the last dose of the vaccine and symptoms onset ( $4.8$  days  $\pm 5.5$  days vs  $3.0 \pm 3.3$  days,  $p=0.04$ ).

Abnormal ECGs, and elevated troponins were seen in almost all the patients. Low LVEF was seen in 71 patients (30.7%) but most patients had recovered ejection fraction on repeat imaging. Pericardial effusion was present in almost 1 in 5 patients in our series which suggests that myopericarditis may have been present in more cases than diagnosed. All the coronary angiograms showed no obstructive coronary artery disease suggesting low yield in suspected COVID-19 vaccine-associated myocarditis. Guideline-directed medical therapy use was present in almost 15% of the cohort suggesting the degree of LV dysfunction present in our cohort. Autopsy/endomyocardial biopsy was done in 13 patients and 10 out of these cases had biopsy- or autopsy-confirmed myocarditis.

Mortality was low at 1.7%, and the distribution of the fatal cases did not reveal any preference for age sex, or vaccine type. In all cases where pathology was available, myocarditis was confirmed. Cardiogenic shock was uncommon, but 4 patients still required temporary mechanical circulatory support.

### Previous studies

Currently, two types of papers on post-COVID-vaccine myocarditis are represented in the literature. The first type usually presents the analysis of very large datasets with good epidemiology data but limited clinical information [25–27]. In a highly vaccinated Israeli population (almost exclusively with Pfizer-BioNTech vaccine), myocarditis cases were judged to be mild in 95%, but one fulminant case was fatal. The overall risk was higher after the second dose [3]. The analysis of the Vaccine Adverse Event Reporting System (VAERS) also indicated that post-vaccination myocarditis rate was highest in young boys aged 12–15 following the second dose of the mRNA vaccine [26]. The analysis of the Kaiser Permanente Southern California database yielded cases of myocarditis exclusively in males, and usually after the second dose [28].

The second type of articles reviews published cases with good clinical data. Among these papers, our review represents the largest collection of post-COVID-vaccine myocarditis in the literature. There were several previously published reviews. They either had age limitation, or covered smaller time interval, or both [10, 29–33]. Case series from a single institution usually contain very few cases [34]. Although of value, they have limited data which may not be representative of an overall picture. In the military, all 20 reported patients had symptom onset following the second dose of the vaccine, all had significantly elevated cardiac troponin levels, and all recovered. Eight patients who underwent cMRI imaging within the acute phase of illness had findings consistent with the clinical diagnosis of myocarditis [2].

It is important to contrast our findings with large case series of COVID-19 vaccine-induced myocarditis in 2021. Merovach et al. [35] reported a retrospective review of national vaccine surveillance data in Israel (after 5.1 million people were fully vaccinated) which identified 136 cases of definite/probable myocarditis after the Pfizer-BioNTech (BNT162b2) vaccine. Their myocarditis data was reported earlier on with the vaccine experience February/March 2021. The findings were similar to those seen in our case series. Most cases were seen in males, aged between 16 and 39, after the second vaccine dose and with most cases being seen 3 days after the second vaccine dose. There was only one fatality in a patient with fulminant myocarditis [35]. Unlike in our series, the patient who died did not have endomyocardial biopsy/autopsy performed and only 2 patients had endomyocardial biopsy which showed foci of endointerstitial edema and neutrophils, along with mononuclear-cell infiltrates.

Witberg et al. [36] (Israel) performed a retrospective review of members of a large health care organization in Israel for myocarditis diagnosed after at least a dose of the Pfizer-BioNTech (BNT162b2) vaccine using the Centers for Disease Control and Prevention case definition. Of the >2.5 million members at least 16 years of age or older, 54 cases met the criteria for myocarditis. The findings were again similar to those seen in our series and the highest incidence of myocarditis (10.69 cases per 100,000 persons; 95% CI, 6.93 to 14.46) was reported in male patients between the ages of 16 and 29 years. After a median follow-up of 83 days after the onset of myocarditis, 1 patient had been readmitted to the hospital and 1 had died of an unknown cause after discharge. One case was associated with cardiogenic shock leading to need for VA-ECMO.

### Mechanisms of mRNA vaccine-induced myocarditis

The causal relation between myocarditis and COVID-19 vaccination and mechanism responsible are unproven. However, the time concordance is indicative of an association. Post-vaccine myocarditis commonly occurs after the second dose of mRNA vaccine, which causes greater lymphocyte activation, and is more likely to be immune mediated.

SARS-CoV-2 mRNA vaccines contain nucleoside-modified mRNA, encoding the viral spike glycoprotein of SARS-CoV-2 (but no live virus or DNA). Vaccine mRNA causes the cells to build the spike protein which stimulates an adaptive immune response to identify and destroy a virus expressing spike protein. The immune system may detect vaccine mRNA as an antigen, resulting in activation of proinflammatory cascades that may lead to myocarditis as part of a systemic reaction [37]. The encoded viral surface spike protein of the mRNA vaccine, which triggers the immune response, may interact with angiotensin converting enzyme 2 receptors in the host, increasing the likelihood of cardiac sensitivity or inflammatory



reactions [38]. Another potential mechanism for myocarditis is molecular mimicry between the spike protein of SARS-CoV-2 and self-antigens [39]. Antibodies against SARS-CoV-2 spike glycoproteins have been experimentally shown to cross-react with structurally similar human peptide protein sequences, including  $\alpha$ -myosin [39]. Polyethylene glycol contained in some vaccines may also stimulate a hypersensitivity reaction [40].

## Pathology

In the report of post-mortem examination of 18 patients who were recently vaccinated from COVID-19, only one was found to have myocarditis, but he also had severe coronary sclerosis, massive cardiac hypertrophy, and myocardial infarction scars. The vaccination took place 11 h prior to death [41]. In a review of 38 published cases of autopsy performed in people who died soon after vaccination for COVID-19 [42], the predominant cause of death was thrombosis and/or hemorrhage, but in two cases myocarditis was diagnosed [42]. The histology was consistent with neutrophil and histiocyte infiltration with occasional areas of myocyte necrosis, located in the atria around sinus and atrioventricular node in one case Pfizer-BioNTech [15] and infiltrates consisting of macrophages, T- and B- lymphocytes, and eosinophils in another case mRNA-1273 [17]. Meanwhile, morphological findings in these additional patients were all consistent with lymphocytic myocarditis [43–48]. Also, more cases of fulminant myocarditis have emerged [43–45, 47, 48]. Cardiac arrest as an initial presentation of post-COVID-19 vaccine myocarditis has also been reported [49]. Additionally, there was one report of myocarditis following the booster dose [50].

## Limitations

The retrospective and descriptive nature of our study was a limitation. Because we censored our literature search by 2021, several cases published in 2022 were not included in the analysis. Definition of myocarditis was also based on local clinical expertise and diagnostic modalities. The criteria for cardiogenic were limited to any inotrope/vasopressor use or use of temporary MCS and we may have overestimated the incidence of cardiogenic shock. Due to inadequate data in some patients, some may have had concomitant pericarditis (myopericarditis) which may have a variable presentation from frank myocarditis. Some patients included in this series may have an alternative diagnosis, although the high numbers of clinically suspected myocarditis presenting within a week of vaccination in a 3-month period would be unusual. Image acquisition of cMRI was not standardized and relied on local protocols.

Echocardiograms were mainly done in the ER setting with only EF assessment and no diastolic function parameters were measured. Cardiac MRIs were not interpreted in core laboratories and cMRIs were not obtained in all cases in our series; we may be over- or underestimating the frequency of abnormal cMRI findings.

## Conclusion

In this largest collection of cases of myocarditis likely related to COVID-19 vaccination (occurring within 60 days of the vaccination), we summarize an international experience with this condition accumulated in 2021, the first year of vaccine availability and mass vaccination. We demonstrated that although the disease typically runs a benign course characterized by mild illness with rapid resolution, it may present with cardiogenic shock and cardiac arrest, may require mechanical circulatory support, and results in death of 1.7% of patients. Histopathologically, lymphocytic myocarditis is present in the majority of cases. Patients are predominantly males of young age, but all ages and both sexes, as well as all types of vaccines, are represented. Women develop post-vaccine myocarditis at an older age and have longer hospital stay. The duration between vaccination and symptoms is longer in older patients. Because fatal cases occur at any age, no case should be dismissed as just having “benign myocarditis,” especially if left ventricular ejection fraction is compromised and if it occurs in older female patients. Further research is needed to fully elucidate the mechanisms, evaluate risk factors, and understand the long-term outcomes of COVID-19 vaccine myocarditis.

**Supplementary information** The online version contains supplementary material available at <https://doi.org/10.1007/s10741-022-10243-9>.

**Author contribution** All authors contributed to the study conception and design. Material preparation, data collection and analysis were performed by Onyedika J. Ilonze and Maya Guglin. The first draft of the manuscript was written by Onyedika J. Ilonze, and all authors commented on previous versions of the manuscript. All authors read and approved the final manuscript.

## Declarations

**Conflict of interest** The authors declare no competing interests.

## References

1. Larson KF, Ammirati E, Adler ED, Cooper LT Jr, Hong KN, Saponara G et al (2021) Myocarditis after BNT162b2 and mRNA-1273 vaccination. *Circulation* 144(6):506–508
2. Montgomery J, Ryan M, Engler R, Hoffman D, McClenathan B, Collins L et al (2021) Myocarditis following immunization with mRNA COVID-19 vaccines in members of the US military. *JAMA Cardiol* 6(10):1202–1206

3. Mevorach D, Anis E, Cedar N, Bromberg M, Haas EJ, Nadir E et al (2021) Myocarditis after BNT162b2 mRNA vaccine against Covid-19 in Israel. *N Engl J Med* 385(23):2140–2149
4. Halsell JS, Riddle JR, Atwood JE, Gardner P, Shope R, Poland GA et al (2003) Myopericarditis following smallpox vaccination among vaccinia-naïve US military personnel. *JAMA* 289(24):3283–3289
5. Kim YJ, Bae JI, Ryoo SM, Kim WY (2019) Acute fulminant myocarditis following influenza vaccination requiring extracorporeal membrane oxygenation. *Acute Crit Care* 34(2):165–169
6. McLean K, Johnson TJ (2021) Myopericarditis in a previously healthy adolescent male following COVID-19 vaccination: a case report. *Acad Emerg Med Off J Soc Acad Emerg Med* 28(8):918–921
7. Abu Mouch S, Roguin A, Hellou E, Ishai A, Shoshan U, Mahamid L et al (2021) Myocarditis following COVID-19 mRNA vaccination. *Vaccine* 39(29):3790–3793
8. Marshall M, Ferguson ID, Lewis P, Jaggi P, Gagliardo C, Collins JS et al (2021) Symptomatic acute myocarditis in 7 adolescents after Pfizer-BioNTech COVID-19 vaccination. *Pediatrics* 148(3)
9. Gargano JWW, Hadler SC, Langley G, Su JR, Oster ME, Broder KR, Gee J, Weintraub E, Shimabukuro T et al (2021) Use of mRNA COVID-19 vaccine after reports of myocarditis among vaccine recipients: update from the advisory committee on immunization practices - United States. *MMWR Morb Mortal Wkly Rep* 70:977–982
10. Truong DT, Dionne A, Muniz JC, McHugh KE, Portman MA, Lambert LM et al (2021) Clinically suspected myocarditis temporally related to COVID-19 vaccination in adolescents and young adults. *Circulation*
11. Shiyovich A, Witberg G, Aviv Y, Eisen A, Orvin K, Wiessman M et al (2021) Myocarditis following COVID-19 vaccination: magnetic resonance imaging study. *Eur Heart J Cardiovasc Imaging*
12. Moher D, Liberati A, Tetzlaff J, Altman DG, Group P (2009) Preferred reporting items for systematic reviews and meta-analyses: the PRISMA statement. *PLoS Med* 6(7):e1000097
13. Bozkurt B, Colvin M, Cook J, Cooper LT, Deswal A, Fonarow GC et al (2016) Current diagnostic and treatment strategies for specific dilated cardiomyopathies: a scientific statement from the American heart association. *Circulation* 134(23):e579–e646
14. Ferreira VM, Schulz-Menger J, Holmvang G, Kramer CM, Carbone I, Sechtem U et al (2018) Cardiovascular magnetic resonance in nonischemic myocardial inflammation: expert recommendations. *J Am Coll Cardiol* 72(24):3158–3176
15. Choi S, Lee S, Seo JW, Kim MJ, Jeon YH, Park JH et al (2021) Myocarditis-induced sudden death after BNT162b2 mRNA COVID-19 vaccination in Korea: case report focusing on histopathological findings. *J Korean Med Sci* 36(40):e286
16. Abbate A, Gavin J, Madanchi N, Kim C, Shah PR, Klein K et al (2021) Fulminant myocarditis and systemic hyperinflammation temporally associated with BNT162b2 mRNA COVID-19 vaccination in two patients. *Int J Cardiol* 340:119–121
17. Verma AK, Lavine KJ, Lin CY (2021) Myocarditis after Covid-19 mRNA vaccination. *N Engl J Med* 385(14):1332–1334
18. Ujueta F, Azimi R, Lozier MR, Poppiti R, Ciment A (2021) Lymphohistocytic myocarditis after Ad26.COV2.S viral vector COVID-19 vaccination. *IJC Heart Vasc* 36:100869
19. Nassar M, Nso N, Gonzalez C, Lakhdar S, Alshamam M, Elshafey M et al (2021) COVID-19 vaccine-induced myocarditis: case report with literature review. *Diabetol Metab Syndr* 15(5):102205
20. Gravanis MB, Sternby NH (1991) Incidence of myocarditis. A 10-year autopsy study from Malmo, Sweden. *Arch Pathol Lab Med* 155(4):390–2
21. Kyto V, Sipila J, Rautava P (2013) The effects of gender and age on occurrence of clinically suspected myocarditis in adulthood. *Heart (British Cardiac Society)* 99(22):1681–1684
22. Su JR, McNeil MM, Welsh KJ, Marquez PL, Ng C, Yan M et al (2021) Myopericarditis after vaccination, vaccine adverse event reporting system (VAERS), 1990–2018. *Vaccine* 39(5):839–845
23. Prevention CfDca (2022) Advisory committee on immunization practices (ACIP). Coronavirus disease 2019 (COVID-19) vaccines.: CDC. [cited 2022 17th March]. Available from: <https://www.cdc.gov/vaccines/acip/meetings/downloads/slides-2022-02-04/04-COVID-Kracalic-508.pdf>. Accessed 17 Mar 2022
24. Health IMo (2021) Surveillance of myocarditis (inflammation of the heart muscle) cases between December 2020 and May 2021 (including). [cited 2022 March 17]. Available from: <https://www.gov.il/en/departments/news/01062021-03>. Accessed 17 Mar 2022
25. Ho JS, Sia CH, Ngiam JN, Loh PH, Chew NW, Kong WK, Poh KK (2021) A review of COVID-19 vaccination and the reported cardiac manifestations. *Singapore Med J*. 19 Nov 2021. <https://doi.org/10.11622/smedj.2021210>. Epub ahead of print. PMID: 34808708
26. Høeg TB, Krug A, Stevenson J, Mandrola J (2021) SARS-CoV-2 mRNA Vaccination-Associated Myocarditis in Children Ages 12-17: A Stratified National Database Analysis. medRxiv : the preprint server for health sciences. <https://doi.org/10.1101/2021.08.30.21262866>
27. Diaz GA, Parsons GT, Gering SK, Meier AR, Hutchinson IV, Robicsek A (2021) Myocarditis and pericarditis after vaccination for COVID-19. *JAMA* 326(12):1210–1212
28. Simone A, Herald J, Chen A, Gulati N, Shen AY, Lewin B et al (2021) Acute myocarditis following COVID-19 mRNA vaccination in adults aged 18 years or older. *JAMA Intern Med* 181(12):1668–1670
29. Woo W, Kim AY, Yon DK, Lee SW, Hwang J, Jacob L et al (2021) Clinical characteristics and prognostic factors of myocarditis associated with the mRNA COVID-19 vaccine. *J Med Virol*
30. Grome HN, Threlkeld M, Threlkeld S, Newman C, Martines RB, Reagan-Steiner S et al (2021) Fatal multisystem inflammatory syndrome in adult after SARS-CoV-2 natural infection and COVID-19 vaccination. *Emerg Infect Dis* 27(11):2914–2918
31. Diaz-Arocutipa C, Saucedo-Chinchay J, Imazio M (2021) Pericarditis in patients with COVID-19: a systematic review. *J Cardiovasc Med (Hagerstown)* 22(9):693–700
32. Hajra A, Gupta M, Ghosh B, Ashish K, Patel N, Manek G et al (2021) Proposed pathogenesis, characteristics, and management of COVID-19 mRNA vaccine-related myopericarditis. *Am J Cardiovasc Drugs* 1–18
33. Sulemankhil I, Abdelrahman M, Negi SI (2021) Temporal association between the COVID-19 Ad26.COV2.S vaccine and acute myocarditis: a case report and literature review. *Cardiovasc Revasc Med*
34. Dionne A, Sperotto F, Chamberlain S, Baker AL, Powell AJ, Prakash A et al (2021) Association of myocarditis with BNT162b2 messenger RNA COVID-19 vaccine in a case series of children. *JAMA Cardiol*
35. Mevorach D, Anis E, Cedar N, Bromberg M, Haas EJ, Nadir E et al (2021) Myocarditis after BNT162b2 mRNA vaccine against Covid-19 in Israel. *N Engl J Med*
36. Witberg G, Barda N, Hoss S, Richter I, Wiessman M, Aviv Y et al (2021) Myocarditis after Covid-19 vaccination in a large health care organization. *N Engl J Med*
37. Bozkurt B, Kamat I, Hotez PJ (2021) Myocarditis with COVID-19 mRNA vaccines. *Circulation* 144(6):471–484
38. Switzer C, Loeb M (2021) Evaluating the relationship between myocarditis and mRNA vaccination. *Expert Rev Vaccines* 1–7
39. Vojdani A, Kharrazian D (2020) Potential antigenic cross-reactivity between SARS-CoV-2 and human tissue with a possible link to an increase in autoimmune diseases. *Clin Immunol* 217:108480
40. Kounis NG, Koniari I, Mplani V, Velissaris D, Tsigkas G (2021) The pathogenesis of potential myocarditis induced by COVID-19 vaccine. *Am J Emerg Med*

41. Schneider J, Sottmann L, Greinacher A, Hagen M, Kasper HU, Kuhnen C et al (2021) Postmortem investigation of fatalities following vaccination with COVID-19 vaccines. *Int J Legal Med* 135(6):2335–2345
  42. Sessa F, Salerno M, Esposito M, Di Nunno N, Zamboni P, Pomara C (2021) Autopsy findings and causality relationship between death and COVID-19 vaccination: a systematic review. *J Clin Med* 10(24)
  43. Agdamag ACC, Gonzalez D, Carlson K, Konety S, McDonald WC, Martin CM et al (2022) Fulminant myocarditis following coronavirus disease 2019 vaccination: a case report. *Eur Heart J Case Rep* 6(1):ytac007
  44. Cui G, Li R, Zho C, Wang DW (2021) Case report: COVID-19 vaccination associated fulminant myocarditis. *Front Cardiovasc Med* 8:769616
  45. Kazama S, Okumura T, Kimura Y, Ito R, Araki T, Mizutani T et al (2022) Biopsy-proven fulminant myocarditis requiring mechanical circulatory support following COVID-19 mRNA vaccination. *CJC Open*
  46. Kiblboeck D, Klingel K, Genger M, Traxler S, Braunsteiner N, Steinwender C et al (2022) Myocarditis following mRNA COVID-19 vaccination: call for endomyocardial biopsy. *ESC Heart Fail*
  47. Koiwaya H, Nishihira K, Tomozoe K, Shibata Y (2022) Serial histopathologic assessment of fulminant myocarditis after the first mRNA COVID-19 vaccine dose. *Eur Heart J*
  48. Oka A, Sudo Y, Miyoshi T, Ozaki M, Kimura Y, Takagi W et al (2022) Fulminant myocarditis after the second dose of COVID-19 mRNA vaccination. *Clin Case Rep* 10(2):e05378
  49. Sadiq W, Waleed MS, Suen P, Chalhoub MN (2022) Cardiopulmonary arrest after COVID-19 vaccination: a case report. *Cureus* 14(1):e21141
  50. Aviram G, Viskin D, Topilsky Y, Sadon S, Shalmon T, Taieb P et al (2022) Myocarditis associated with COVID-19 booster vaccination. *Circ Cardiovasc Imaging* 15(2):e013771
- Publisher's Note** Springer Nature remains neutral with regard to jurisdictional claims in published maps and institutional affiliations.