



## Myocardial work and takotsubo syndrome: stress affects work

Antonio Vitarelli<sup>1,2</sup>

Received: 20 May 2022 / Accepted: 21 May 2022 / Published online: 28 June 2022  
© The Author(s), under exclusive licence to Springer Nature B.V. 2022

Takotsubo syndrome (TTS), also known as stress cardiomyopathy, apical ballooning syndrome or broken heart syndrome, is a neurocardiac condition triggered by emotional or physical stress and characterized by acute reversible heart failure. TTS was first described [1] in a postmenopausal Asian woman with chest pain, dyspnea, ECG ST changes consistent with acute myocardial infarction, normal coronary arteries, and left ventricular (LV) apical dyskinetic ballooning giving the appearance of a traditional Japanese octopus trapping pot called “takotsubo”. These signs resolved spontaneously and apparently normal left ventricular function resumed. Similar cases have subsequently been reported in western countries [2–4] and found in adults of all ages and also in children. Etiology and pathophysiology are still not fully understood and, although initially thought to be a relatively benign condition, this syndrome is now known to be associated with considerable short-term morbidity and small but important long-term mortality risk [5]. In the fourth universal definition of myocardial infarction TTS is classified as myocardial injury but not infarction [6]. Endogenous adrenergic surge is the most established theory for the pathogenesis of takotsubo syndrome. Increased responsiveness of the left ventricular apex to catecholamines could explain the characteristic apical ballooning. However, because patients with TTS are frequently neither tachycardic nor hypertensive at onset, contrary to other conditions known to have high catecholamine surges, TTS might affect the autonomic nervous system in a more complex way than a simple catecholamine spike. Neurocardiogenic stunning, coronary vasospasm, microvascular reactivity, sympathetic hyperexcitability, LV basal hypercontractility with outflow tract obstruction, inflammatory mechanisms and genetic predisposition have been involved in its pathogenesis. In the setting

of the COVID-19 pandemic, TTS was also described [7] as complication of the acute infection or indirect outcome of quarantine-induced stress (stress-induced cardiomyopathy).

Diagnosis of TTS can be challenging because the clinical presentation is often similar to acute coronary syndromes and prompt cardiac imaging is required due to rapid normalization of LV ejection fraction. The Mayo Clinic diagnostic criteria [5] originally described in 2004 and modified in 2008 are the most used in clinical practice and research. The International Takotsubo Registry (Inter-TAK) diagnostic score [8] was designed to help clinicians differentiate takotsubo syndrome from acute coronary syndrome. The most significant changes from the preceding modified Mayo Clinic criteria were that significant coronary artery disease can also coexist and pheochromocytoma may be present and act as a trigger. TTS diagnosis is often made when normal or non-obstructive coronary artery disease is documented. Coexisting coronary artery disease is present in about 15% of patients with TTS and a careful correlative analysis of angiography and wall motion abnormalities is advisable. Left ventriculography usually confirms the diagnosis due to characteristic LV ballooning. In most cases (50–80%), there is a typical pattern of apical and mid-ventricular dyskinesia or hypo-akinesia with basal sparing. Intravascular ultrasound may aid to rule out plaque rupture, which is not a feature of takotsubo syndrome. Echocardiography can also help to support the diagnosis (severity and extent of wall motion abnormalities) and detect potential complications [5]. Typically, the wall motion abnormality is not limited to one arterial territory differentiating it from acute myocardial infarction. Characteristic echocardiographic findings are LV basal hypercontractility and apical ballooning, but other less common forms (median and reverse types) have been reported. Echocardiographic features associated with a higher risk are low LV ejection fraction and right ventricular involvement. Approximately 15% of patients show left ventricular outflow tract (LVOT) obstruction that can be associated with mitral regurgitation secondary to mitral valve leaflet tethering and systolic anterior motion. LVOT obstruction can exacerbate

✉ Antonio Vitarelli  
vitar@tiscali.it; cardiagnostica@gmail.com

<sup>1</sup> Cardiagnostica CS, Via Lima 35, 00198 Rome, Italy

<sup>2</sup> Department of Medicine and Cardiology, Sapienza University, Rome, Italy

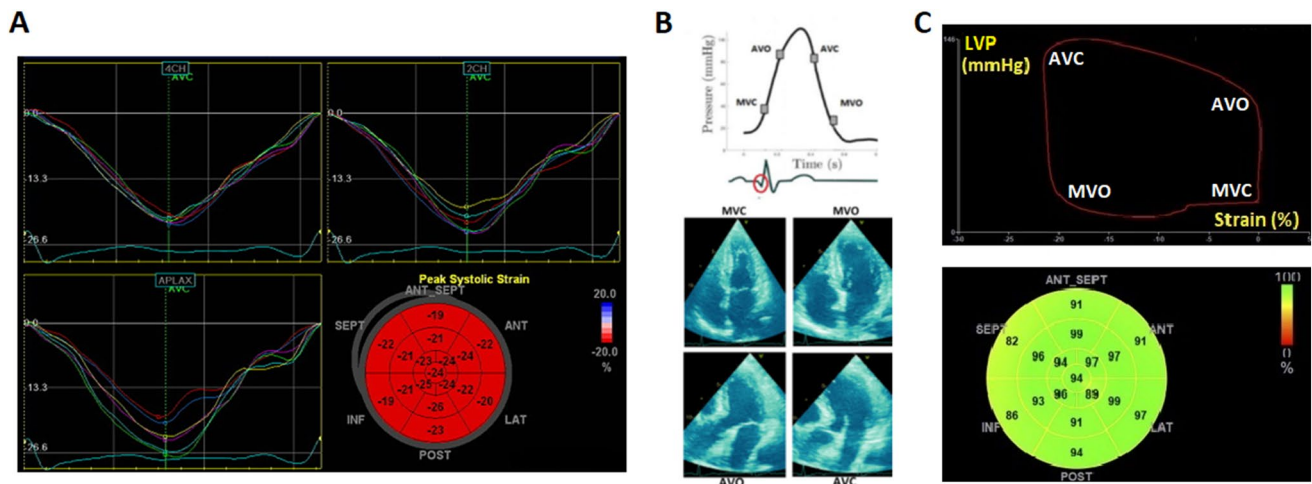
LV apical ballooning and dysfunction by exposing the apex to greater wall stress than the basal myocardium.

Advanced echocardiographic techniques such as speckle-tracking echocardiography (STE) can provide accurate identification of cardiac abnormalities during the acute and recovery phase of TTS. STE assessment of LV global longitudinal strain and left atrial strain have been associated with a higher rate of in-hospital complications [9]. The added value of STE findings is also seen after the acute event since LVEF usually normalizes but functional LV abnormalities may persist. Within the first few months after TTS hospitalization, LV strain and twist mechanics can be impaired despite normalization of LVEF [10]. Reduced LV longitudinal strain, apical circumferential strain and LV twist were also detected over 1 year after the acute event, casting doubt on the common perception of TTS as a transient condition [11].

However, speckle-tracking strain assessment is sensitive to afterload, and its accuracy is limited when afterload is not taken into account in the analysis. A noninvasive technique for estimating myocardial work (MW) based on the combined assessment of LV pressure and LV strain by STE has been described [12]. This method has renewed a previous concept according to which ventricular work is influenced by the relationship between myocardial contraction and intracardiac pressure recorded during cardiac catheterization and thus evaluated by an invasively-derived pressure–volume loop [13]. The noninvasive estimated pressure curve component is created by integrating the peripheral systolic blood pressure with the timing of cardiac events derived from echocardiographic valvular events. This noninvasive method

showed a strong correlation with invasive techniques, oxygen consumption and regional myocardial glucose metabolism obtained by positron emission tomography [12].

MW measures the extent of work performed by the LV during isovolumetric contraction and relaxation phases and mechanical systole, and is defined as force times distance. Since it is not easy to calculate myocardial force, pressure is used as a surrogate. MW is obtained noninvasively from the estimated LV systolic pressure measurement via brachial artery cuff pressure and measurement of strain. The area of LV work is highlighted by the pressure-strain loop (PSL) proceeding in a counterclockwise rotation, as shown in Fig. 1. The area inside the curve is described as systolic stroke work. *Myocardial work index (MWI)* is the total LV work performed during mechanical systole (which starts at mitral valve closure and ends at mitral valve opening) plus isovolumetric contraction and relaxation. It is expressed in units of mmHg%. Since work is by definition force by length, the use of pressure and strain indicates a MW index rather than a direct measure of work. *Myocardial constructive work (MCW)* is LV systolic work that is productive, including muscle shortening during systole and muscle lengthening during isovolumic relaxation. *Myocardial wasted work (MWW)* is LV systolic work that is not productive, including muscle lengthening during systole and muscle shortening during isovolumic relaxation. *Myocardial work efficiency (MWE)* represents the efficiency of the energy consumed during the cardiac cycle and is determined as the PSL-derived ratio between constructive work and the sum of constructive and wasted work. It is expressed as a percentage ranging from 0 to 100% (close to 100 in the



**Fig. 1** Construction of myocardial work bull's-eye plot. **A.** Peak global longitudinal strain is derived from high-quality myocardial apical views. **B.** Noninvasive systolic blood pressure is used as a surrogate for systemic left ventricular pressure. Valve events are assessed by echocardiography. **C.** Myocardial work based on blood pressure

and global longitudinal strain is calculated from a complex algorithm within ultrasound machine software (GE Healthcare, Chicago, IL). A pressure-strain loop is generated. The area under the curve represents total myocardial work. AVC, aortic valve closure; AVO, aortic valve opening; MVC, mitral valve closure, MVO, mitral valve opening

presence of synchronous contraction and relaxation of all LV segments). Values are calculated globally and segmentally using the same bull's-eye plot as for strain analysis. Normal reference ranges for MWI and MWE have been described both in adults [14] and children [15].

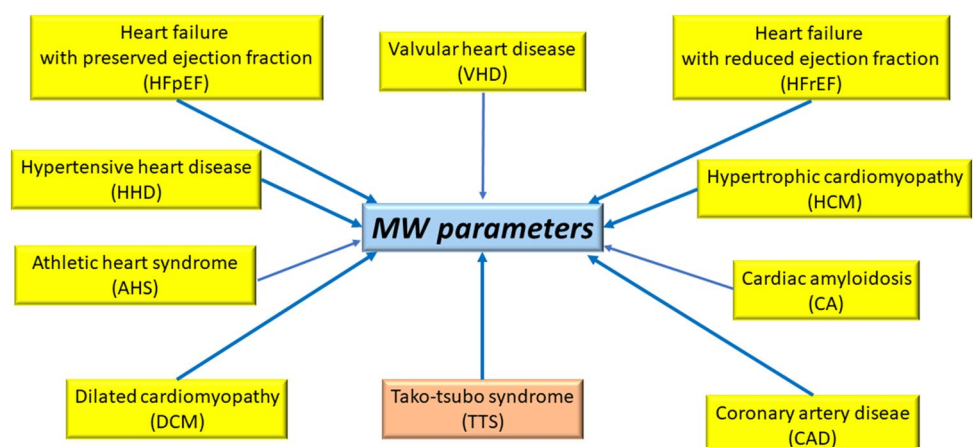
Experimental and clinical studies [12, 16–21] have shown that myocardial work parameters strongly correlate with invasive measurements and changes of these indices are found across a broad spectrum of heart disease such as ischemic heart disease, cardiomyopathies, and valvular heart disease (Fig. 2). The role of MW in coronary artery disease has been studied [18, 19] and it has been shown that regional MW index and MW efficiency in the culprit vessel territory were significantly lower in comparison with the non-culprit vessel territory, MW index in the culprit vessel territory was independently related to early LV remodelling, and MW index in the culprit vessel territory was superior to LV global longitudinal strain and LV ejection fraction in predicting early adverse LV remodelling [19]. LV remodelling with different loading conditions has been assessed in systemic hypertension and non-ischemic dilated cardiomyopathy [20]. Hypertensive patients had higher MW index to compensate for the preservation of LV contractility against the increased afterload whereas MW efficiency was unchanged because there was a proportional increase in both constructive and wasted work. In nonobstructive hypertrophic cardiomyopathy [21] myocardial constructive work showed correlations with maximum LV wall thickness, diastolic function, and QRS duration and was significantly associated with adverse outcomes. Differences in constructive work were observed in different phenotypes of hypertrophic cardiomyopathy (apical vs septal).

In the present issue of the International Journal of Cardiovascular Imaging [22], authors have investigated the serial change in myocardial work compared to traditional echo parameters during the acute phase of takotsubo cardiomyopathy. Fifty patients with the apical variant of TTS underwent transthoracic echocardiography within 24 h of

admission and a median of 36 days at follow-up. Constructive work, wasted work, MW index and efficiency were assessed. Hospital complications were defined as heart failure, LV apical thrombus, and ventricular arrhythmias. 24 matched-subjects were used as controls. MW indices were significantly impaired in patients with TTS and hospital complications. At follow-up, MW was significantly reduced compared to controls, although hemodynamics, LV ejection fraction, and 2D strain were similar. The results suggest that MW decreases during TTS but does not fully recover at 1 month of follow-up, while all other parameters have fully recovered. This implies that MW is sensitive enough to detect residual subclinical myocardial dysfunction in a ventricular chamber that exhibits total recovery of wall motion abnormalities.

The authors are to be congratulated for presenting these interesting results. This study is the first to assess myocardial work in patients with TTS. An experimental study performed in rats receiving intraperitoneal administration of different catecholamines [23] has demonstrated that in TTS cardiac dysfunction is afterload-dependent. These authors showed that isoprenaline, dopamine, and epinephrine may all induce TTS-like cardiac dysfunction in rats and that different morphological patterns are associated with different manipulation of the blood pressure. They proposed that strong vasopressor or vasodilator stimuli may generate overriding of reflexes aimed at maintaining ventriculo-arterial coupling and cause uncoupling of the LV and the arterial system. Clinically, LV systolic dysfunction in the acute TTS phase is characterized by profound myocardial stunning with reduced contractility and deformation as well as passive lengthening of several affected segments during the systolic phase [24]. A regional increase in wall stress due to the ballooning often observed in TTS could promote passive longitudinal lengthening instead of shortening for severely stunned cardiomyocytes. Post-systolic shortening of weakened segments often occurs in this setting, affecting negatively the subsequent diastolic phase of the cardiac cycle,

**Fig. 2** Various heart diseases influencing myocardial work (MW) parameters



and these wall deformation abnormalities can be influenced by a high afterload. Therefore MW, which allows assessment of both systolic and relaxation phase and quantification of positive and negative LV work, seems more appropriate to assess cardiac performance in TTS rather than GLS alone.

Authors suggest these findings, despite some technical limitations, have clinical implications. Although only patients with image quality that was adequate to undergo speckle-tracking echocardiographic analysis were included, MW offers complementary information versus 2D strain alone since it takes into account afterload. This seems particularly interesting in TTS where the phenotype of cardiac dysfunction is influenced by afterload and several affected segments exhibit systolic lengthening and post-systolic shortening (wasted work) in the acute phase. Although MW was significantly impaired in patients with in-hospital complications, the long term prognostic implications of these results need further evaluation in a larger sample. However, after more than one month of follow-up, myocardial performance still appeared slightly reduced compared to control subjects with similar blood pressure (e.g., wasted work), suggesting that subtle myocardial dysfunction persisted despite full LVEF and strain recovery.

Some issues warrant further comment. Authors have considered the apical variant of TTS and these results cannot be generalized to other TTS phenotypes. Patients with LV outflow tract obstruction (peak LVOT gradient  $\geq 30$  mmHg at rest) were disregarded. This highlights one of the major limitations of noninvasive myocardial work assessment. Determination of myocardial work from LV pressure-strain loop assumes that peripheral brachial cuff systolic blood pressure is nearly equivalent to LV intracardiac systolic pressure. In the presence of significant LVOT obstruction or conditions such as aortic valve stenosis, LV pressure is higher than peripheral brachial cuff blood pressure and consequently the calculation of myocardial work becomes inaccurate. In these cases myocardial work could be evaluated on the basis of invasively-derived left ventricular pressure but this would take away the advantage of having a harmless non-invasive technique available. Doppler-derived LVOT gradient could be otherwise added to systemic blood pressure to estimate non-invasively LV pressure. A recent study on pre- and post-TAVR (transcatheter aortic valve replacement) aortic valve stenosis has proposed a “corrected” method for determining the extent of myocardial work in conditions where LV systolic pressure does not equal peripheral systolic blood pressure [25]. It has been shown that corrected myocardial work was significantly higher than uncorrected myocardial work in pre-TAVR severe aortic stenosis and significantly improved after post-TAVR resolution of increased afterload. Thus the use of the sum of cuff blood pressure and mean aortic gradient allowed a more accurate analysis of myocardial consumption due to the increase in afterload.

Another limitation of MW is that it does not consider wall stress, wall thickness, and wall curvature. The force acting on the left ventricle is more accurately represented by wall stress rather than LV pressure alone. According to Laplace’s law LV afterload is directly related to LV pressure and geometric changes in ventricular dimensions but inversely related to wall thickness. In enlarged ventricles wall stress will be high and MW may be underestimated. Conversely, in ventricles with greater wall thickness, wall stress will be decreased. In patients with heart failure and ventricular conduction delay candidates for cardiac resynchronization therapy a modification of previous published pressure-strain loop area for LV work analysis was introduced [26, 27] and wall stress was successfully enclosed in the calculation of work by examining the stress-to-strain relationship. Segmental strain curves were imported from speckle-tracking software, LV midwall contour was also imported from the speckle tracking software to calculate the local curvature, segmental wall stress was measured in two-dimensional images, segmental stress-strain loops were constructed and the loop area was used as measure of regional work load. Incorporation of wall stress in myocardial work analysis in patients with cardiac hypertrophy can allow to compare more accurately ventricles of different wall thickness. In cardiac diseases where LV wall thickness is increased with eccentric curvature it would be particularly appropriate to include wall stress in MW analysis. This could be potentially achieved by integrating three-dimensional echocardiographic software, assessing myocardial curvature in multiple image planes and measuring wall stress with the inclusion of wall thickness, LV geometry, and local radius of curvature.

In conclusion, in patients with TTS MW is sensitive enough to detect residual subclinical myocardial dysfunction in a ventricle that is believed to have fully recovered based on wall motion criteria. Future studies using corrected MW parameters and/or three-dimensional speckle tracking echocardiography will help to better define myocardial work in heart disease and, specifically, in takotsubo syndrome.

**Author contributions** This is a manuscript of only one author. No other contributors.

**Funding** The authors have not disclosed any funding.

## Declarations

**Conflict of interest** The author has no conflict of interests to disclose.

**Ethical approval** This editorial comment is compliant with ethical standards.



## References

- Sato H, Tateishi H, Dote KMI, Uchida T, Ishihara M (1990) Tako-Tsubo-like left ventricular dysfunction due to multivessel coronary spasm. In: Kodama K, Haze K, Hori M (eds) Clinical aspect of myocardial injury: from ischemia to heart failure (in Japanese). Kagakuhyoronsha Publishing Co, Tokyo, pp 56–64
- Maron BJ, Towbin JA, Thiene G, Antzelevitch C, Corrado D, Arnett D, Moss AJ, Seidman CE, Young JB (2006) Contemporary definitions and classification of the cardiomyopathies: an American Heart Association Scientific Statement from the council on clinical cardiology, heart failure and transplantation committee; quality of care and outcomes research and functional genomics and translational biology interdisciplinary working groups; and council on epidemiology and prevention. *Circulation* 113(14):1807–1816. <https://doi.org/10.1161/CIRCULATIONAHA.106.174287>
- Lyon AR, Bossone E, Schneider B, Sechtem U, Citro R, Underwood SR, Sheppard MN, Figtree GA, Parodi G, Akashi YJ, Ruschitzka F, Filippatos G, Mebazaa A, Omerovic E (2016) Current state of knowledge on Takotsubo syndrome: a position statement from the taskforce on Takotsubo Syndrome of the Heart Failure Association of the European Society of Cardiology. *Eur J Heart Fail* 18(1):8–27. <https://doi.org/10.1002/ehf.424>
- Ghadri JR, Wittstein IS, Prasad A, Sharkey S, Dote K, Akashi YJ, Cammann VL, Crea F, Galiuto L, Desmet W, Yoshida T, Manfredini R, Eitel I, Kosuge M, Nef HM, Deshmukh A, Lerman A, Bossone E, Citro R, Ueyama T, Corrado D, Kurisu S, Ruschitzka F, Winchester D, Lyon AR, Omerovic E, Bax JJ, Meimoun P, Tarantini G, Rihal C, Y-Hassan S, Migliore F, Horowitz JD, Shimokawa H, Lüscher TF, Templin C (2018) International expert consensus document on takotsubo syndrome (part I): clinical characteristics, diagnostic criteria, and pathophysiology. *Eur Heart J* 39(22):2032–2046. <https://doi.org/10.1093/eurheartj/ehy076>
- Singh T, Khan H, Gamble DT, Scally C, Newby DE, Dawson D (2022) Takotsubo syndrome: pathophysiology, emerging concepts, and clinical implications. *Circulation* 145(13):1002–1019. <https://doi.org/10.1161/CIRCULATIONAHA.121.055854>
- Thygesen K, Alpert JS, Jaffe AS, Chaitman BR, Bax JJ, Morrow DA, White HD (2018) ESC Scientific Document Group. Fourth universal definition of myocardial infarction. *Eur Heart J* 40(3):237–269. <https://doi.org/10.1093/eurheartj/ehy462>
- Kanelidis AJ, Miller PJ, Singh A, Addetia K, Lang RM (2022) Takotsubo syndrome from COVID-19 infection. *J Am Soc Echocardiogr* S0894-7317(22)00229-2. <https://doi.org/10.1016/j.echo.2022.04.011>
- Ghadri JR, Cammann VL, Jurisic S, Seifert B, Napp LC, Diekmann J, Bataiosu DR, D'Ascenzo F, Ding KJ, Sarcon A, Kazemian E, Birri T, Ruschitzka F, Lüscher TF, Templin C, InterTAK co-investigators (2017) A novel clinical score (InterTAK diagnostic score) to differentiate takotsubo syndrome from acute coronary syndrome: results from the International Takotsubo Registry. *Eur J Heart Fail* 19(8):1036–1042. <https://doi.org/10.1002/ehf.683>
- Meimoun P, Stracchi V, Boulanger J, Martis S, Botoro T, Zemir H, Clerc J (2020) The left atrial function is transiently impaired in Tako-tsubo cardiomyopathy and associated to in-hospital complications: a prospective study using two-dimensional strain. *Int J Cardiovasc Imaging* 36(2):299–307. <https://doi.org/10.1007/s10554-019-01722-6>
- Schwarz K, Ahearn T, Srinivasan J, Neil CJ, Scally C, Rudd A, Jagpal B, Frenneaux MP, Pislaru C, Horowitz JD, Dawson DK (2017) Alterations in cardiac deformation, timing of contraction and relaxation, and early myocardial fibrosis accompany the apparent recovery of acute stress-induced (takotsubo) cardiomyopathy: an end to the concept of transience. *J Am Soc Echocardiogr* 30(8):745–755. <https://doi.org/10.1016/j.echo.2017.03.016>
- Scally C, Rudd A, Mezincescu A, Wilson H, Srinivasan J, Horgan G, Broadhurst P, Newby DE, Henning A, Dawson DK (2018) Persistent long-term structural, functional, and metabolic changes after stress-induced (takotsubo) cardiomyopathy. *Circulation* 137(10):1039–1048. <https://doi.org/10.1161/CIRCULATIONAHA.117.031841>
- Russell K, Eriksen M, Aaberge L, Wilhelmsen N, Skulstad H, Remme EW, Haugaa KH, Opdahl A, Fjeld JG, Gjesdal O, Edvardsen T, Smiseth OA (2012) A novel clinical method for quantification of regional left ventricular pressure-strain loop area: a non-invasive index of myocardial work. *Eur Heart J* 33(6):724–733. <https://doi.org/10.1093/eurheartj/ehs016>
- Suga H (1979) Total mechanical energy of a ventricle model and cardiac oxygen consumption. *Am J Physiol* 236(3):H498–505. <https://doi.org/10.1152/ajpheart.1979.236.3.H498>
- Truong VT, Vo HQ, Ngo TNM, Mazur J, Nguyen TTH, Pham TTM, Le TK, Phan H, Palmer C, Nagueh SF, Chung ES (2022) Normal ranges of global left ventricular myocardial work indices in adults: a meta-analysis. *J Am Soc Echocardiogr* 35(4):369–377. <https://doi.org/10.1016/j.echo.2021.11.010>
- Pham TTM, Truong VT, Vu PN, Tran TX, Nguyen NNH, Nguyen LPT, Tu HNT, Palmer C, Tretter JT, Levy P, Mazur W, Pham VN (2022) Echocardiographic reference ranges of non-invasive myocardial work indices in children. *Pediatr Cardiol* 43(1):82–91. <https://doi.org/10.1007/s00246-021-02695-x>
- Hubert A, Le Rolle V, Leclercq C, Galli E, Samset E, Casset C, Mabo P, Hernandez A, Donal E (2018) Estimation of myocardial work from pressure-strain loops analysis: an experimental evaluation. *Eur Heart J Cardiovasc Imaging* 19(12):1372–1379. <https://doi.org/10.1093/ehjci/jeu024>
- Roemer S, Jaglan A, Santos D, Umland M, Jain R, Tajik AJ, Khandheria BK (2021) The utility of myocardial work in clinical practice. *J Am Soc Echocardiogr* 34(8):807–818. <https://doi.org/10.1016/j.echo.2021.04.013>
- Lustosa RP, Fortuni F, van der Bijl P, Goedemans L, El Mahdiui M, Montero-Cabezas JM, Kostyukevich MV, Ajmone Marsan N, Bax JJ, Delgado V, Knuuti J (2021) Left ventricular myocardial work in the culprit vessel territory and impact on left ventricular remodelling in patients with ST-segment elevation myocardial infarction after primary percutaneous coronary intervention. *Eur Heart J Cardiovasc Imaging* 22(3):339–347. <https://doi.org/10.1093/ehjci/jeaa175>
- Lin J, Wu W, Gao L, He J, Zhu Z, Pang K, Wang J, Liu M, Wang H (2022) Global myocardial work combined with treadmill exercise stress to detect significant coronary artery disease. *J Am Soc Echocardiogr* 35(3):247–257. <https://doi.org/10.1016/j.echo.2021.10.009>
- Chan J, Edwards NFA, Khandheria BK, Shiino K, Sabapathy S, Anderson B, Chamberlain R, Scalia GM (2019) A new approach to assess myocardial work by non-invasive left ventricular pressure-strain relations in hypertension and dilated cardiomyopathy. *Eur Heart J Cardiovasc Imaging* 20(1):31–39. <https://doi.org/10.1093/ehjci/jeu131>
- Hiemstra YL, van der Bijl P, El Mahdiui M, Bax JJ, Delgado V, Marsan NA (2020) Myocardial work in nonobstructive hypertrophic cardiomyopathy: Implications for outcome. *J Am Soc Echocardiogr* 33(10):1201–1208. <https://doi.org/10.1016/j.echo.2020.05.010>
- Meimoun P, Vernier A, Lachambre P, Stracchi V, Clerc J (2022) Evolution of non-invasive myocardial work in tako-tsubo cardiomyopathy. *Int J Cardiovasc Imaging* (in press).

23. Redfors B, Ali A, Shao Y, Lundgren J, Gan LM, Omerovic E (2014) Different catecholamines induce different patterns of takotsubo-like cardiac dysfunction in an apparently afterload dependent manner. *Int J Cardiol* 174(2):330–336. <https://doi.org/10.1016/j.ijcard.2014.04.103>
24. Meimoun P, Abouth S, Boulanger J, Luycx-Bore A, Martis S, Clerc J (2014) Relationship between acute strain pattern and recovery in tako-tsubo cardiomyopathy and acute anterior myocardial infarction: a comparative study using two-dimensional longitudinal strain. *Int J Cardiovasc Imaging* 30(8):1491–1500. <https://doi.org/10.1007/s10554-014-0494-9>
25. Jain R, Bajwa T, Roemer S, Huisheer H, Allaqaband SQ, Kroboth S, Perez Moreno AC, Tajik AJ, Khandheria BK (2021) Myocardial work assessment in severe aortic stenosis undergoing transcatheter aortic valve replacement. *Eur Heart J Cardiovasc Imaging* 22(6):715–721. <https://doi.org/10.1093/ehjci/jeaa257>
26. Cvijic M, Duchenne J, Ünlü S, Michalski B, Aaronson M, Winter S, Aakhus S, Fehske W, Stankovic I, Voigt JU (2018) Timing of myocardial shortening determines left ventricular regional myocardial work and regional remodelling in hearts with conduction delays. *Eur Heart J Cardiovasc Imaging* 19(8):941–949. <https://doi.org/10.1093/ehjci/jex325>
27. Duchenne J, Aalen JM, Cvijic M, Larsen CK, Galli E, Bézy S, Beela AS, Ünlü S, Pagourelas ED, Winter S, Hopp E, Kongsgård E, Donal E, Fehske W, Smiseth OA, Voigt JU (2020) Acute redistribution of regional left ventricular work by cardiac resynchronization therapy determines long-term remodelling. *Eur Heart J Cardiovasc Imaging* 21(6):619–628. <https://doi.org/10.1093/ehjci/jeaa003>

**Publisher's Note** Springer Nature remains neutral with regard to jurisdictional claims in published maps and institutional affiliations.