




Original Article

Infrared Thermographic Imaging of Chest Wall Perfusion in Patients Undergoing Coronary Artery Bypass Grafting

STEFAN RASCHE,¹ CHRISTIAN KLEINER,² JENS MÜLLER,³ ANTJE ROST,⁴
TAMER GHAZY,⁵ KATRIN PLÖTZE,⁶ RONALD TETZLAFF,⁴ KLAUS MATSCHKE,⁶
and OLIMPIU BOTA⁷ 

¹Surgical Intensive Care Unit, Faculty of Medicine Carl Gustav Carus, TU Dresden, Fetscherstraße 74, 01307 Dresden, Germany; ²Institute of Acoustics and Speech Communication, TU Dresden, Dresden, Germany; ³Faculty of Electrical and Computer Engineering, Institute of Circuits and Systems, TU Dresden, 01067 Dresden, Germany; ⁴Department of Anesthesiology and Intensive Care Medicine, Faculty of Medicine Carl Gustav Carus, TU Dresden, Fetscherstraße 74, 01307 Dresden, Germany; ⁵Department of Cardiac Surgery, Marburg University Hospital, Marburg, Germany; ⁶Department of Cardiac Surgery, University Heart Center Dresden, TU Dresden, Fetscherstrasse 76, 01307 Dresden, Germany; and ⁷University Center for Orthopedics, Trauma and Plastic Surgery, Faculty of Medicine Carl Gustav Carus, TU Dresden, Fetscherstraße 74, 01307 Dresden, Germany

(Received 17 February 2022; accepted 22 June 2022; published online 30 June 2022)

Associate Editor Stefan M. Duma oversaw the review of this article.

Abstract—Coronary artery disease represents a leading cause of death worldwide, to which the coronary artery bypass graft (CABG) is the main method of treatment in advanced multiple vessel disease. The use of the internal mammary artery (IMA) as a graft insures an improved long-term survival, but impairment of chest wall perfusion often leads to surgical site infection and increased morbidity and mortality. Infrared thermography (IRT) has established itself in the past decades as a non-invasive diagnostic technique. The applications vary from veterinary to human medicine and from head to toe. In this study we used IRT in 42 patients receiving CABG to determine the changes in skin surface temperature preoperatively, two hours, 24 h and 6 days after surgery. The results showed a significant and independent drop of surface temperature 2 h after surgery on the whole surface of the chest wall, as well as a further reduction on the left side after harvesting the IMA. The temperature returned to normal after 24 h and remained so after 6 days. The study has shown that IRT is sufficiently sensitive to demonstrate the known, subtle reduction in chest wall perfusion associated with IMA harvesting.

Keywords—Infrared thermography, Tissue perfusion, Coronary artery bypass, Internal mammary artery, Chest wall perfusion.

ABBREVIATIONS

| | |
|------------------|--|
| BIMA | Bilateral internal mammary artery |
| BL | Before surgery |
| CABG | Coronary artery bypass graft |
| CCS | Canadian Cardiovascular Society grading of angina pectoris |
| CHD | Coronary heart disease |
| CVP | Cutaneous blood volume pulse |
| D6 | 6 Days after surgery |
| DSWI | Deep sternal wound infection |
| H2 | Two hours after surgery |
| H24 | 24 Hours after surgery |
| IMA | Internal mammary artery |
| LIMA | Left internal mammary artery |
| LR | Likelihood ratio |
| LVEF | Ejection fraction |
| NUC | Non-uniformity correction |
| NYHA | New York heart Association functional class |
| ped | Pedicled mammaia graft |
| PPGI | Photoplethysmographic imaging |
| ROI | Regions of interest |
| scel | Skeletonized mammaia graft |
| Ts | Chest wall surface temperature |
| T _{S,L} | Left chest wall surface temperature |
| T _{S,R} | Right chest wall surface temperature |

Address correspondence to Olimpiu Bota, University Center for Orthopedics, Trauma and Plastic Surgery, Faculty of Medicine Carl Gustav Carus, TU Dresden, Fetscherstraße 74, 01307 Dresden, Germany. Electronic mail: olimpiu.bota@uniklinikum-dresden.de

INTRODUCTION

Coronary artery disease (CHD) represents a leading cause of death worldwide, to which the coronary artery bypass graft (CABG) is the main method of treatment in advanced multiple vessel disease. The procedure implies the completion of a median sternotomy and bypassing the diseased coronary artery segments with autologous vessels. The use of the internal mammary artery (IMA) as a graft insures an improved long-term survival.¹² Nevertheless, the combination of median sternotomy with the harvest of the sternal blood supply, the internal mammary arteries, leads to a decrease in the regional blood perfusion, which predisposes to postoperative wound healing disorders and deep sternal wound infections (DSWI).¹ To minimize the occurrence of these complications, the harvest of only the left internal mammary artery (LIMA) is currently favored in most heart surgery centers,¹⁵ while harvesting both internal mammary arteries (BIMA) is used only in chosen cases.⁴ An alternative is the harvesting of a skeletonized IMA, leaving the collateral circulation around the artery intact and therefore preserving some of the sternal perfusion.⁶

Patient comorbidities like obesity, diabetes mellitus, heart failure or a history of smoking may favor the hypoperfusion of the anterior chest area postoperatively.¹⁹ Therefore, the perioperative diagnosis of perfusion impairment around the chest wall is of great importance, especially in patients at risk for developing wound complications. Nevertheless, standard measures to estimate chest wall perfusion have not been yet defined.

The measurement of thermal radiation has been proven so far to have useful applications in different domains like monitoring the heart rate and respiratory rates in experimental pigs,² brain mapping,^{7,10,16} tumor detection,²² identifying the perforator vessels for flap surgery^{26,9} as well as for determining the skin perfusion postoperatively after flap harvest.²⁰ Infrared thermography (IRT) implies a non-invasive, accessible and label-free technique. In patients undergoing CABG surgery, high resolution thermography of the chest wall may be valuable for identifying changes in perfusion, especially in patients at risk.

In our study we aimed at estimating changes in tissue perfusion by means of IRT after the harvest of the LIMA for bypass surgery. Patient-related risk factors, surgical technique, vital parameters and cutaneous blood volume pulse (CBVP) were investigated for additional effects on IRT.

MATERIALS AND METHODS

Study Setting

Patients who underwent CABG were studied at our university center for cardiac surgery, after written informed consent was obtained. The study was conducted in accordance with the principles of the Declaration of Helsinki, fifth revision, and was approved by the Institutional Review Board of our institution (IRB00001473, EK168052013). This was a combined study to evaluate both high resolution thermographic imaging as well as contact-free photoplethysmographic imaging (PPGI)¹¹ for monitoring purposes in major/cardiac surgery.

Thermography Setup

The chest wall surface temperature T_s was measured by the high resolution IRT system VarioCAM[®] (InfraTec GmbH, Dresden, Germany). VarioCAM[®] uses an uncooled microbolometric plane array with a resolution of 480×640 pixels. Its thermal resolution is 30 mK at 30 °C in a spectral range from 7.5 to 14 μm . Its spatial resolution reaches 0.25 mm with an object distance of 300 mm. Images are recorded with 30 frames per second.

Measurements and Image Processing

Measurements were performed the day before surgery (BL) as well as two hours (H2), 24 h (H24) and 6 days (D6) after surgery. Measurements were taken in supine position. Patients were in stable circulatory condition and weaned from mechanical ventilation during the measurements after surgery.

Before each measurement, an internal camera one-point non-uniformity correction (NUC) was performed for each microbolometer of the uncooled focal plane array to avoid a recalibration during data collection. A sequence of thermographic images of one minute duration was taken at each measurement. Data were processed offline after all measurements were completed. Consistent rectangular regions of interest (ROI) were defined for each side of the chest in the four videos, leaving out wound dressings and drains (Fig. 1). The temperatures within the ROI were averaged over time and space, leading to the two temperature values $T_{S,L}$ and $T_{S,R}$ for the left and right side of the anterior chest wall for each measurement. Blood pressure and heart rate, body (core) temperature and room temperature were taken for reference at each measurement. Surrogates of cutaneous perfusion were derived from the CBVP, which was estimated in non-

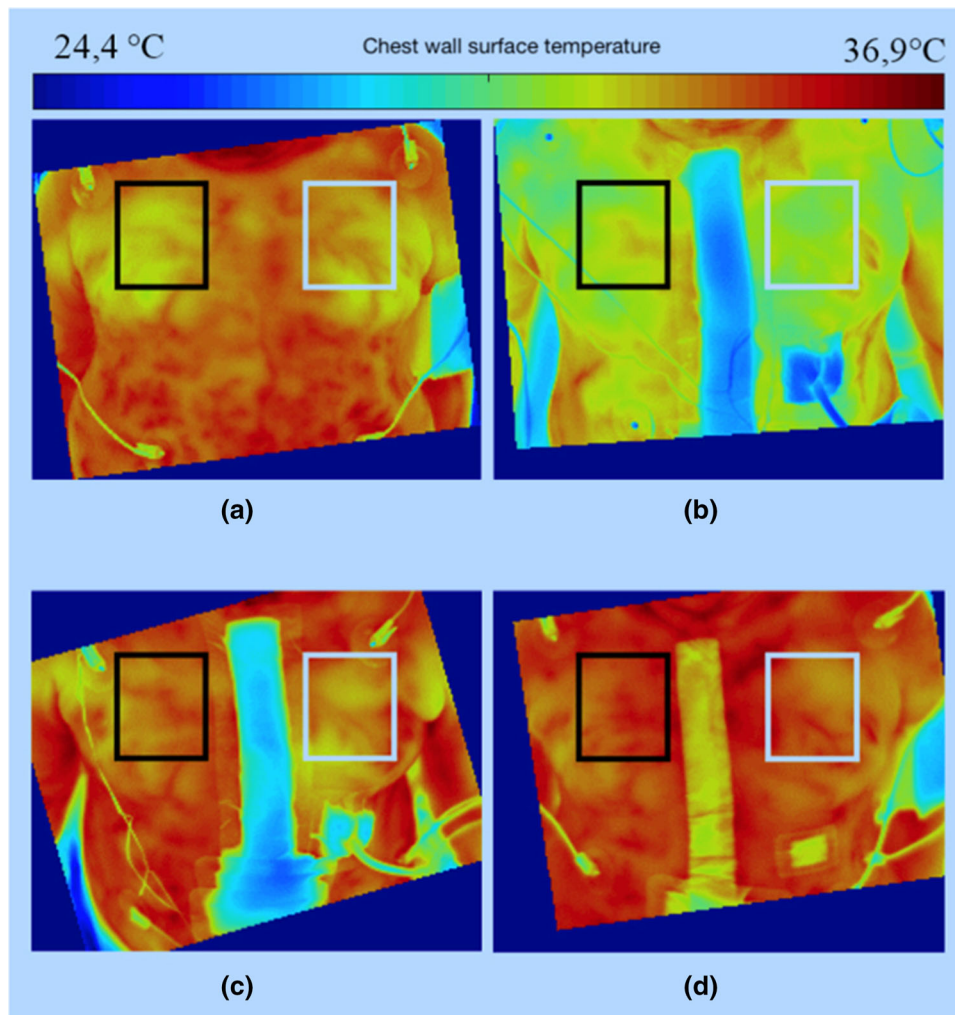


FIGURE 1. Thermal images of the chest wall with left (white) and right (black) ROI. (a) before surgery, (b) 2 h after surgery, (c) 24 h after surgery, (d) 6 days after surgery. All temperature values were averaged over 18,000 frames, corresponding to a duration of 60 s.

contact photoplethysmograms of the accompanying study at the same time points.¹¹

Statistical Analysis

Effects of surgery and surgical techniques, vital parameters, and cofactors on T_s were investigated in random-intercept covariance models. Random effects were defined by patients. Fixed effects were defined by measurement time, chest wall side, vital signs, surgical factors and comorbidity. Maximal models containing covariates of any interest were constructed, pared down on the basis of stepwise deletion and compared by Likelihood ratio (LR) tests. Core temperature and room temperature variables were scaled to their grand mean. Heart rate was scaled to deviations of 10bpm from 80 bpm. Measurement time was defined as an ordinal variable in relation to surgery. Significance of

fixed effects was t-tested after Satterthwaite's approximation to degrees of freedom.¹³ The explanatory power of room and core temperature on T_s was taken as the reduction of the residual variance of T_s from the minimal adequate model through stepwise deletion of both predictors.

RESULTS

Fortytwo patients undergoing CABG surgery were investigated. Patient characteristics and graft preparation are given in Table 1.

Impact of Room and Core Temperature

T_s varied between 28.8 and 35.8 °C and was on average 3.2 °C lower than core temperature ($p < 0.001$, U Test). T_s significantly increased with

room temperature or core temperature in univariable and multivariable analyses. A varying impact of both parameters on T_s during the study was not evident after adjustment for cofactors. Independently from

surgery and physiological parameters, room temperature explained 8.3% of the variance of T_s , whereas body temperature explained 1.2% ($p = 0.04$) and both together explained 11.5% ($p < 0.001$).

TABLE 1. Demographic and baseline data.

| | |
|---------------------------------------|-------------|
| Patients (<i>m:w</i>) | 39:3 |
| Age (years) | 71.1 ± 7.5 |
| Weight (kg) | 87.3 ± 13.9 |
| Height (cm) | 174 ± 7.2 |
| Arterial hypertension (<i>n</i>) | 37 |
| Graft preparation (<i>ped:scel</i>) | 27:15 |
| NYHA (<i>n</i>) | |
| 1 | 2 |
| 2 | 18 |
| 3 | 22 |
| LVEF | |
| Normal | 26 |
| Borderline | 4 |
| Impaired | 8 |
| Severely impaired | 4 |
| Diabetes (<i>n</i>) | 18 |
| Hyperlipidemia (<i>n</i>) | 39 |
| Angina pectoris (<i>n</i>) | 18 |
| CCS 1 | 5 |
| CCS 2 | 6 |
| CCS 3 | 4 |
| CCS 4 | 3 |

Ped pedicled mammaia graft, *scel* skeletonized mammaia graft, *NYHA* New York heart Association functional class, *LVEF* preoperative left ventricular ejection fraction, *CCS* Canadian Cardiovascular Society grading of angina pectoris.

Surgery, Vital Parameters and Comorbidity

T_s significantly decreased immediately after surgery (H2) by 1.7 K (from -2.0 to -1.4 K, $p < 0.001$) at the left side and by 1.3 K from (-1.6 K to -0.9 K, $p < 0.001$) at the right side. It recovered the day after surgery (H24) and slightly exceeded the preoperative level on day 6. A difference in T_s of 404 mK ($p = 0.015$) between the left and right side was seen at H2, but neither before surgery nor at H24 or D6 (Fig. 2, Table 2). Core temperature also decreased after surgery (-0.77 °C, $p < 0.001$). The measurement point *per se* remained significant after multivariable adjustment of related cofactors including core and room temperature.

Table 3 shows the multivariable estimation of concurrent effects of vital parameters, surgery and comorbidity on T_s . A significant impact of surgery on global T_s remains evident until the first postoperative day (H24). Heart rate affected T_s at BL, H24 and D6, but not at H2. At heart rates higher than 80 bpm, T_s increased by 0.3 °C (BL), 0.4 °C (H24) and 0.3 °C (D6) per 10 bpm increase of heart rate. A higher respiratory rate was associated with a slight decrease of T_s . Sensitivity of T_s to blood pressure was only seen in the subgroup of patients with documented angina

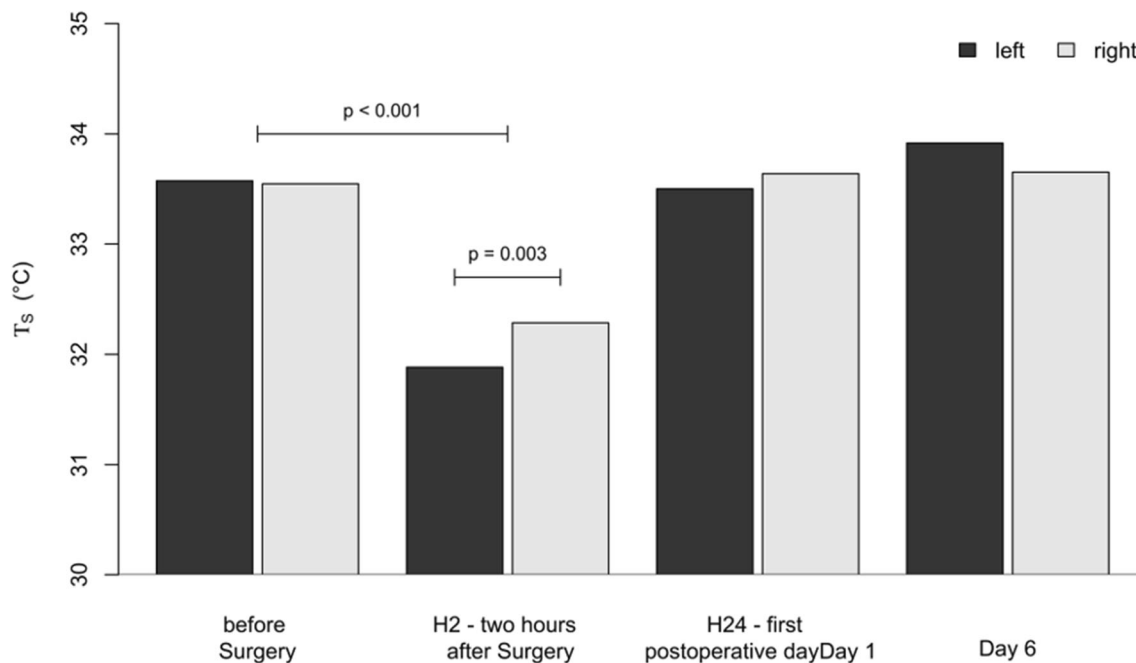


FIGURE 2. Surface Temperature T_s of the left and right side of the anterior chest wall during the study.

TABLE 2. T_s of both sides of the chest during the study.

| | T_s left (°C) | SD | T_s right (°C) | SD | p_1 | p_2 |
|----------|-----------------|-----|------------------|-----|---------|-------|
| Baseline | 33.6 | 0.9 | 33.5 | 0.8 | – | 0.869 |
| H2 | 31.9 | 1.1 | 32.3 | 1.0 | < 0.001 | 0.015 |
| H24 | 33.5 | 1.1 | 33.6 | 1.1 | 0.675 | 0.422 |
| Day6 | 33.9 | 0.9 | 33.7 | 0.9 | 0.045 | 0.119 |

SD standard deviation. p_1 changes over time, p_2 left side vs. right side of the chest wall.

TABLE 3. Multivariable estimation of the effects of surgery vital parameters and comorbidity on T_s .

| | Estimate | CI low | CI high | p |
|--|----------|--------|---------|---------|
| Effect of surgery | | | | |
| H2 | – 2.2 | – 2.9 | – 1.5 | <0.001 |
| H24 | – 0.7 | – 1.3 | – 0.2 | 0.015 |
| D6 | 0.1 | – 0.3 | 0.6 | 0.612 |
| Side effect | | | | |
| BL | 0.0 | – 0.3 | 0.3 | 1 |
| H2 | 0.5 | 0.2 | 0.9 | 0.004 |
| H24 | 0.3 | – 0.1 | 0.6 | 0.208 |
| D6 | – 0.2 | – 0.6 | 0.1 | 0.219 |
| Heart rate ($10 \times \text{min}^{-1}$) | | | | |
| BL | 0.3 | 0.07 | 0.45 | 0.013 |
| H2 | 0.1 | – 0.2 | 0.42 | 0.515 |
| H24 | 0.4 | 0.07 | 0.67 | 0.023 |
| D6 | 0.2 | 0.01 | 0.43 | 0.049 |
| Respiratory rate (min^{-1}) | – 0.04 | – 0.07 | 0.00 | 0.037 |
| Core temperature (°C) | 0.2 | 0.0 | 0.3 | 0.047 |
| Room temperature (°C) | 0.2 | 0.1 | 0.4 | < 0.001 |

CI/95% confidence interval. Side effect denotes the difference of T_s between the right and left side of the chest wall.

pectoris before surgery. Among those, patients with angina of Canadian Cardiovascular Society (CCS) class 4 had a significant delay in postoperative recovery of T_s , compared to lower classes (Table 4). Preoperative systolic cardiac function (ejection fraction) and heart failure according to the New York Heart Association (NYHA) classification had no influence on T_s . Likewise, arterial hypertension, diabetes mellitus or lipid disorders did not exert a significant effect on T_s . Surgical techniques (pedicled vs. skeletonized grafting) and ancillary measures like the use of stapler and gelspore or intracutaneous suture were not systematically associated with T_s .

Relation Between Chest Wall Temperature and Cutaneous Blood Volume Pulse

T_s significantly increased with higher CBVP estimated by non-contact photoplethysmography, albeit the association was moderate (Fig. 3). 25.8% of the variability of T_s was explained by changes of CBVP. Taking into account vital signs and measurement time,

the independent effect of CBVP consistently remained. It was not dependent on measurement time ($p = 0.98$ for the interaction).

DISCUSSION

The present study measured the chest wall surface temperature (T_s) using high resolution thermographic imaging in 42 heart surgery patients. Although expectedly T_s was correlated to core temperature and room temperature, multivariable analysis confirmed that both temperatures only explained a minor part of T_s variance and that an independent residual effect of surgery on its own was present. Two hours after surgery, T_s significantly decreased compared to the preoperative measurement. The expected drop in T_s on the left compared to the right side, where the main blood supply to the chest wall was removed, was also statistically significant at this point. At the next measurement, 24 h after surgery, the difference between T_s and core temperature as well as between the chest wall sides had disappeared. While the surgical trauma and the operating room temperature had probably an effect on the core temperature, the further drop in T_s may be attributed on the one hand to the postoperative peripheral vasoconstriction²¹ and on the other hand to the surgical interruption of the local skin and soft tissue perfusion, which is emphasized on the less perfused left side. Until the next measurement, 24 h after surgery, compensatory mechanisms had gradually reversed these changes, including the difference between sides. Here might come into role the redistribution of circulation with opening of choke vessels, which connect different vascular zones.^{3,5} The fact that T_s was independent of the heart rate only at H2 sustains the idea, that the local perfusion impairment due to surgery was responsible for the T_s drop all together and on the left side. After reestablishment of local perfusion, the heart rate could influence again T_s .

The physiological parameters had a minimal impact on T_s . While the respiratory rate was slightly and inversely associated with T_s , blood pressure had an impact on T_s only in patients with preoperative angina pectoris. The delayed recovery in Class 4 CCS patients may be attributed to a pronounced general vascular injury and successively reduced flow-mediated dilation in these patients, which could delay the opening of choke vessels and the reorganization of circulation.¹⁴ The absent effects of preoperative ejection fraction and NYHA stage on T_s are in accordance with the compensated resting hemodynamics of all patients. Although an improvement in ejection fraction is expected within 30 days after CABG⁸ and therefore an improvement in peripheral tissue perfusion, the mea-

TABLE 4. T_S in patients with documented angina pectoris.

| | Estimate | CI low | CI high | <i>p</i> |
|--|----------|--------|---------|----------|
| CCS 1–3 | | | | |
| H2 | – 1.8 | – 2.3 | – 1.2 | < 0.001 |
| H24 | – 0.2 | – 0.7 | 0.4 | 0.587 |
| D6 | 0,0 | – 0.4 | 0.44 | 0.946 |
| CCS 4 vs. CCS 1–3 | | | | |
| H2 | – 1.3 | – 2.1 | – 0.54 | 0.002 |
| H24 | – 1.6 | – 2.44 | – 0.68 | < 0.001 |
| D6 | – 1.8 | – 2.53 | – 0.98 | < 0.001 |
| Heart rate | 0.3 | 0.14 | 0.39 | < 0.001 |
| Systolic blood pressure ($10 \times \text{mmHg}^{-1}$) | 0.1 | 0.03 | 0.2 | 0.01 |

For patients with CCS1-3, T_S was compared to baseline. For patients with CCS4, T_S deviation from patients with CCS1–3 is shown (CCS 4 vs. CCS 1–3).

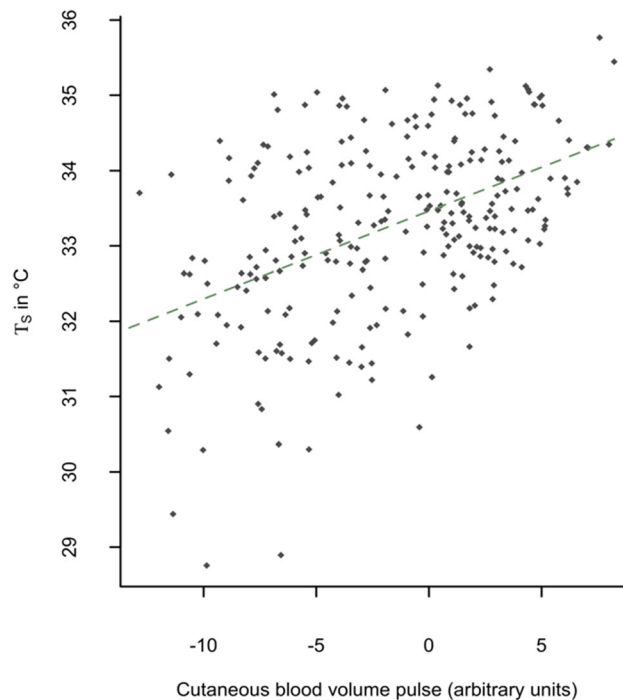


FIGURE 3. Association between cutaneous blood volume pulse (CVP) and chest wall surface temperature (T_S). The dotted line shows the linear fit of T_S to CBVP.

surement interval in our study was possibly too short for these changes to take place. Out of the surgical factors, while the use of stapler, gelspone or intracutaneous sutures were not expected to have a direct impact on tissue perfusion and T_S , the skeletonization of the IMA also didn't systematically show an impact on T_S . While on the long-term this technique has shown to improve the chest wall perfusion,⁶ the surgical preparation with vessel spasm probably impede the rapid reestablishment of tissue perfusion immediately postoperative. Diabetes mellitus, hypertension and lipid disorders had no influence on T_S , showing

that these factors do not affect the rapid circulation changes described above.

The systematic link between T_S and CBVP proves that the perfusion of superficial skin vessels partly determines T_S . Owing to the limited propagation of light into the skin, CBVP is mainly determined by blood volume changes in the outer skin layers. However, there is only a weak relation between both measures (explanatory power 25.8%). These data support the notion that high resolution thermal imaging depends to some extent on peripheral perfusion, as expected, but also on thermal effects of deeper regions of the chest wall, that

are more affected by IMA severance and are critical for wound healing.

The results of this study show, that perfusion alterations after cardiac surgery and even local effects of IMA harvesting can be early detected by means of high resolution IRT. The limited explanatory value of core or room temperature for T_S emphasizes the specific physiologic significance of IRT monitoring in the context of peripheral perfusion. If the method allows to discriminate between expected and pathological changes in chest wall blood flow, i.e., if it could serve as an early indicator of complications associated to malperfusion, remains to be seen in further studies.

IRT has established itself in the past decades as a non-invasive diagnostic technique. The applications vary from veterinary to human medicine and head to toe.²⁴ Around the chestwall, IRT can be used as an adjunctive to mammography to detect breast cancer. The higher tumoral metabolism rate enables the detection within breast thermal maps.²² Zhang *et al.*²⁷ showed that the temperature difference between the two anterior chest wall sides can reliably predict the success of the regional anaesthetic block. The blockade of small unmyelinated fibers in this case causes a vasodilation and interferes with the physiological thermoregulation, compared to the control side. This sustains the findings of our study, that local changes in blood perfusion have a thermographic effect.

IRT is furthermore used in the mapping of skin perforators in flap surgery. According to the angiosome principle, a perforator vessel supplies blood flow to a vascular territory and has anastomoses to other neighbouring vascular territories.²⁵ Currently, dynamic IRT is being used preoperatively in identifying the appropriate perforator vessel to be transplanted as well as in flap monitoring after free flap transplantation, where changes in arterial or venous perfusion influence the skin temperature.^{17,23,28} The sensitivities lie between 89.6 and 99.6% and specificities between 96 and 99.9%.²⁰

After supplying blood to the chest wall, IMA continues to the abdomen wall as the superior epigastric artery, where it anastomoses itself to the inferior epigastric artery to supply the perfusion to the abdominal wall. In breast reconstruction using abdominal flaps, the inferior epigastric artery is elevated together with the fasciocutaneous tissues and the vessel anastomosis is usually performed to the IMA and vein. Nergård *et al.*¹⁸ investigated the abdominal wall perfusion using dynamic IRT in 17 female patients after receiving a breast reconstruction as described before. They recorded a loss of hot spots corresponding to the perforator vessels not only in the undermined median regions, but also in the submammary region on the side where the internal mammary vessels were severed at the level of the third or fourth rib. This sustains the results of the present study,

that the harvest of the IMA results in a decline in skin perfusion immediately postoperative. According to Dhar *et al.*,⁵ after a 3 h period of vasoconstriction, the choke vessels connecting different angiosomes start progressively dilating to reach a normal diameter within 24 h and a maximal dilation at 48–72 h. This was confirmed in the study of Nergård *et al.*,¹⁸ where the hot spots reappeared within the first postoperative days, as well as in our study, where the chest wall temperature equalized within 24 h of surgery.

The present study was performed in a rather limited amount of patients and did not investigate the impact of harvesting BIMA on the chest wall perfusion. The investigation resumed to a quantitative measurement of the temperature, without identifying the individual perforators. The planning of future studies could include a dynamic investigation with the identification of hot spots. This could show more accurately the impact of thoracotomy and the harvesting of the IMA, as direct perforators could be either closed or show less flow.

In the present study, we showed that the high resolution thermography is suitable to detect early perfusion changes of the chest wall and even local effects of IMA harvesting after CABG. We also showed, that the harvest of LIMA has an additive impact on the hemithoracic blood supply in the first day after surgery. Further studies should aim at establishing a quantitative threshold, in order to predict the wound healing disorders according to the measurement of local blood supply.

FUNDING

Open Access funding enabled and organized by Projekt DEAL.

OPEN ACCESS

This article is licensed under a Creative Commons Attribution 4.0 International License, which permits use, sharing, adaptation, distribution and reproduction in any medium or format, as long as you give appropriate credit to the original author(s) and the source, provide a link to the Creative Commons licence, and indicate if changes were made. The images or other third party material in this article are included in the article's Creative Commons licence, unless indicated otherwise in a credit line to the material. If material is not included in the article's Creative Commons licence and your intended use is not permitted by statutory regulation or exceeds the permitted use, you will need to obtain permission directly from the copyright holder. To view a copy of this licence, visit <http://creativecommons.org/licenses/by/4.0/>.

REFERENCES

- ¹Andreas, M., M. Zeitlinger, M. Hoferl, W. Jaeger, D. Zimpfer, J.-M. Hiesmayr, G. Laufer, and D. Hutschala. Internal mammary artery harvesting influences antibiotic penetration into presternal tissue. *Ann Thorac Surg* 95(4):1323–9; Discussion 1329–30, 2013. <https://doi.org/10.1016/j.athoracsur.2012.10.088>.
- ²Barbosa Pereira, C., H. Dohmeier, J. Kunczik, N. Hochhausen, R. Tolba, and M. Czaplik. Contactless monitoring of heart and respiratory rate in anesthetized pigs using infrared thermography. *PLoS ONE* 14(11):e0224747, 2019. <https://doi.org/10.1371/journal.pone.0224747>.
- ³Bota, O., C. Josten, M. A. Borger, N. Spindler, and S. Langer. Standardized musculocutaneous flap for the coverage of deep sternal wounds after cardiac surgery. *Ann. Thorac. Surg.* 107(3):802–808, 2019. <https://doi.org/10.1016/j.athoracsur.2018.09.017>.
- ⁴Buttar, S. N., T. D. Yan, D. P. Taggart, and D. H. Tian. Long-term and short-term outcomes of using bilateral internal mammary artery grafting versus left internal mammary artery grafting: a meta-analysis. *Heart (British Cardiac Society)*. 103(18):1419–1426, 2017. <https://doi.org/10.1136/heartjnl-2016-310864>.
- ⁵Dhar, S. C., and G. I. Taylor. The delay phenomenon: the story unfolds. *Plast. Reconstr. Surg.* 104(7):2079–2091, 1999. <https://doi.org/10.1097/00006534-199912000-00021>.
- ⁶Ejiofor, J. I., T. Kaneko, and S. F. Aranki. Current readings: single vs bilateral internal mammary artery in coronary artery bypass grafting. *Sem Thorac Cardiovasc Surg.* 30(4):398–405, 2018. <https://doi.org/10.1053/j.semtcvs.2018.05.004>.
- ⁷Font-Réaulx, E. de, J. T. Lluch, R. L. López, P. S. Bialik, M. Á. C. Corona, L. G. D. López, E. A. Tirado, E. R. Navarrete, and A. G. Astiazarán. Thermography mapping patterns in temporal lobe epilepsy surgery. *Surg Neurol Int* 11:30, 2020. https://doi.org/10.25259/SNI_549_2019.
- ⁸Haxhibeqiri-Karabdic, I., A. Hasanovic, E. Kabil, and S. Straus. Improvement of ejection fraction after coronary artery bypass grafting surgery in patients with impaired left ventricular function. *Med. Arch. (Sarajevo, Bosnia and Herzegovina)*. 68(5):332–334, 2014. <https://doi.org/10.5455/medarh.2014.68.332-334>.
- ⁹Hennessy, O., and S. M. Potter. Use of infrared thermography for the assessment of free flap perforators in autologous breast reconstruction: a systematic review. *JPRAS Open.* 23:60–70, 2020. <https://doi.org/10.1016/j.jpra.2019.11.006>.
- ¹⁰Hoffmann, N., E. Koch, U. Petersohn, M. Kirsch, and G. Steiner. Cerebral cortex classification by conditional random fields applied to intraoperative thermal imaging. *Curr Direct Biomed Eng.* 2(1):475–478, 2016. <https://doi.org/10.1515/cdbme-2016-0105>.
- ¹¹Kukel, I., A. Trumpp, K. Plötze, A. Rost, S. Zaunseder, K. Matschke, and S. Rasche. Contact-free optical assessment of changes in the chest wall perfusion after coronary artery bypass grafting by imaging photoplethysmography. *Appl. Sci.* 10(18):6537, 2020. <https://doi.org/10.3390/ap10186537>.
- ¹²Kusu-Orkar, T.-E., M. Kermali, N. Oguamanam, C. Bithas, and A. Harky. Coronary artery bypass grafting: Factors affecting outcomes. *J Cardiac Surg.* 35(12):3503–3511, 2020. <https://doi.org/10.1111/jocs.15013>.
- ¹³Kuznetsova, A., P. B. Brockhoff, R. H. B. Christensen. lmerTest package: tests in linear mixed effects models. *J. Stat. Soft.* 2017. <https://doi.org/10.18637/jss.v082.i13>.
- ¹⁴Lekakis, J. P., C. M. Papamichael, C. N. Vemmos, A. A. Voutsas, S. F. Stamatelopoulos, and S. D. Mouloupoulos. Peripheral vascular endothelial dysfunction in patients with angina pectoris and normal coronary arteriograms. *J. Am. Coll. Cardiol.* 31(3):541–546, 1998. [https://doi.org/10.1016/s0735-1097\(97\)00542-1](https://doi.org/10.1016/s0735-1097(97)00542-1).
- ¹⁵McNichols, B., J. R. Spratt, J. George, S. Rizzi, E. W. Manning, and K. Park. Coronary artery bypass: review of surgical techniques and impact on long-term revascularization outcomes. *Cardiol Therap.* 10(1):89–109, 2021. <https://doi.org/10.1007/s40119-021-00211-z>.
- ¹⁶Muller, J., J. Muller, F. Chen, R. Tetzlaff, J. Muller, E. Bohl, M. Kirsch, and C. Schnabel. Registration and fusion of thermographic and visual-light images in neurosurgery. *IEEE Trans Biomed Circ Syst.* 12(6):1313–1321, 2018. <https://doi.org/10.1109/TBCAS.2018.2856407>.
- ¹⁷Muntean, M. V., S. Strilciuc, F. Ardelean, C. Pesteian, R. Lacatus, A. F. Badea, and A. Georgescu. Using dynamic infrared thermography to optimize color Doppler ultrasound mapping of cutaneous perforators. *Med. Ultrasonograph.* 17(4):503–508, 2015.
- ¹⁸Nergård, S., J. B. Mercer, and L. de Weerd. Internal mammary vessels' impact on abdominal skin perfusion in free abdominal flap breast reconstruction. *Plast Reconstr. Surg.* 5(12):e1601, 2017. <https://doi.org/10.1097/GOX.00000000001601>.
- ¹⁹Phoon, P. H. Y., and N. C. Hwang. Deep sternal wound infection: diagnosis, treatment and prevention. *J Cardiothorac Vasc Anesth.* 34(6):1602–1613, 2020. <https://doi.org/10.1053/j.jvca.2019.09.019>.
- ²⁰Raheman, F. J., D. M. Rojoa, and N. G. Patel. Performance of infrared thermography and thermal stress test in perforator mapping and flap monitoring: a meta-analysis of diagnostic accuracy. *J. Plast. Reconstruct. Aesthet. Surg.* 74(9):2013–2025, 2021. <https://doi.org/10.1016/j.bjps.2021.03.088>.
- ²¹Sessler, D. I. Perioperative thermoregulation and heat balance. *Lancet (London, England)*. 387(10038):2655–2664, 2016. [https://doi.org/10.1016/S0140-6736\(15\)00981-2](https://doi.org/10.1016/S0140-6736(15)00981-2).
- ²²Singh, D., and A. K. Singh. Role of image thermography in early breast cancer detection- Past, present and future. *Comput. Methods Programs Biomed.* 183:105074, 2020. <https://doi.org/10.1016/j.cmpb.2019.105074>.
- ²³Sjöberg, T., J. B. Mercer, S. Weum, and L. de Weerd. The value of dynamic infrared thermography in pedicled thoracodorsal artery perforator flap surgery. *Plast. Reconstr. Surg.* 8(7):e2799, 2020. <https://doi.org/10.1097/GOX.00000000002799>.
- ²⁴Tattersall, G. J. Infrared thermography: a non-invasive window into thermal physiology. *Compar. Biochem. Physiol. A.* 202:78–98, 2016. <https://doi.org/10.1016/j.cbpa.2016.02.022>.
- ²⁵Taylor, G. I., D. P. Chubb, and M. W. Ashton. True and 'choke' anastomoses between perforator angiosomes: part I. anatomical location. *Plast. Reconstr. Surg.* 132(6):1447–1456, 2013. <https://doi.org/10.1097/PRS.0b013e3182a80638>.
- ²⁶Thiessen, F. E. F., T. Tondu, B. Cloostermans, Y. A. L. Dirx, D. Auman, S. Cox, V. Verhoeven, G. Hubens, G. Steenackers, and W. A. A. Tjalma. Dynamic infrared thermography (DIRT) in DIEP-flap breast reconstruction: a review of the literature. *Eur. J. Obstetr. Gynecol. Reprod.*

- Biol.* 242:47–55, 2019. <https://doi.org/10.1016/j.ejogrb.2019.08.008>.
- ²⁷Zhang, S., Y. Liu, X. Liu, T. Liu, P. Li, and W. Mei. Infrared thermography for assessment of thoracic paravertebral block: a prospective observational study. *BMC Anesthesiol.* 21(1):168, 2021. <https://doi.org/10.1186/s12871-021-01389-4>.
- ²⁸Zhang, Y., W. Xiao, S. Ng, H. Zhou, P. Min, W. Xi, J. Masia, P. Blondeel, and S. Feng. Infrared thermography-guided designing and harvesting of pre-expanded pedicled flap for head and neck reconstruction. *J. Plast. Reconstr. Aesthet. Surg.* 74(9):2068–2075, 2021. <https://doi.org/10.1016/j.bjps.2020.12.102>.

Publisher's Note Springer Nature remains neutral with regard to jurisdictional claims in published maps and institutional affiliations.