

Giant ovarian cystadenoma weighing 59 kg

Didier Fobe · Tom Vandervurst · Laetitia Vanhoutte

Received: 8 April 2010 / Accepted: 11 May 2010 / Published online: 26 May 2010
© Springer-Verlag 2010

Keywords Ovarian cysts · Cancer

Explanation image

In October 2009, a 24-year-old woman was admitted to our emergency services for massive abdominal distension causing dyspnoea and inability to walk. She had noticed weight gain and progressive abdominal distension for 10 months. She delayed seeking medical advice because of social isolation resulting from family problems. The patient weighed 122 kg for a height of 165 cm and showed signs of hirsutism. Her medical history was unremarkable except for congenital bilateral clubfoot, and she was nulligravida. The CA-125 levels were increased (405.5 U/ml n:0-35). A computerised tomography scan showed a large fluid density mass filling the entire abdominal cavity, with some papillary projections (Fig. 1).

A peridural was performed, and a general anaesthesia was induced before the transfer to the surgical table. The patient was installed supine position, with the table slightly tilted to the left to avoid caval vein compression syndrome. A midline laparotomy was performed (Fig. 2). We found a large cystic mass arising from the right adnexa. The left adnexum was normal. A right salpingo-oophorectomy was performed, and a smooth-walled cystic mass measuring 50×40 cm was removed without disruption of the capsule.

During the surgery after the mass had been removed, a decreased cardiac frequency and an increased ejection fraction were observed. Throughout surgery and postoperatively, respiratory and hemodynamic parameters remained stable, and the patient made an uneventful recovery. She is recovering well and is receiving psychological support. An abdominoplasty will probably be necessary in the future.

Pathology diagnosed a giant mucosal-serosal cystadenoma weighing 59 kg with borderline potential in one of the papillary projections (Figs. 3 and 4). Void of its clear

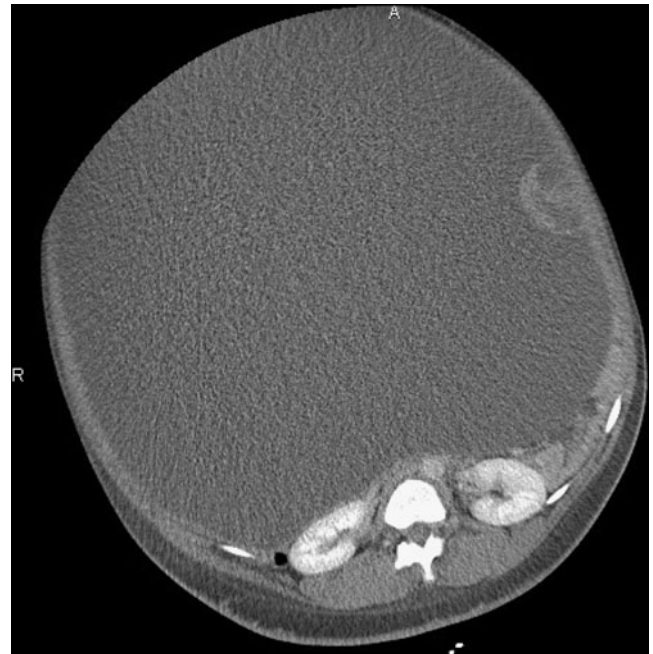


Fig. 1 Computed tomography scan showing a large fluid density mass with a papillary projection

D. Fobe (✉) · T. Vandervurst · L. Vanhoutte
Centre Hospitalier Régional de Namur,
185 Avenue Albert 1er,
5000 Namur, Belgium
e-mail: didier.fobe@skynet.be

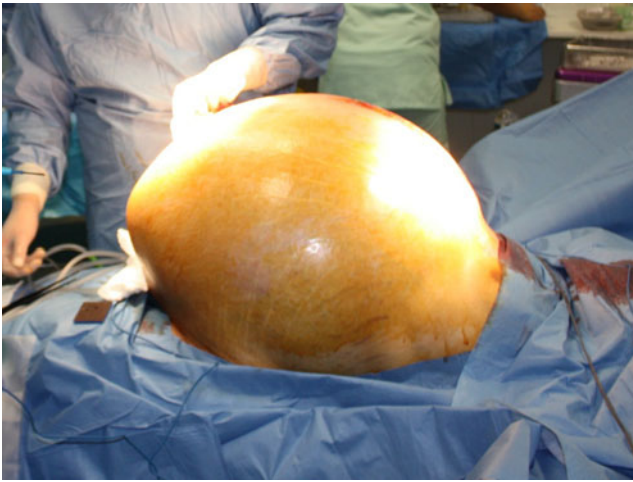


Fig. 2 Preoperative appearance of the patient's abdomen

fluid contents, the cyst weighed 1.3 kg. This is the largest ovarian cyst seen in our institution and one of the largest among those reported in the literature [1–4] (Fig. 5).

Discussion

Ovarian cysts are common particularly in females of child-bearing age. They fall into two main categories: functional cysts that arise from follicular cells and the organic cysts that arise from epithelial cells, germ cells and sex cord-stromal cells. Cancer can arise from non-functional cysts [5]. Among organic cysts, those derived from epithelial cells are by far the most common. Cystic teratomas and serous cystadenomas are the most common benign ovarian neoplasms [4].

These neoplasms are usually diagnosed earlier. A patient may complain of abdominal pain/mass or simply an

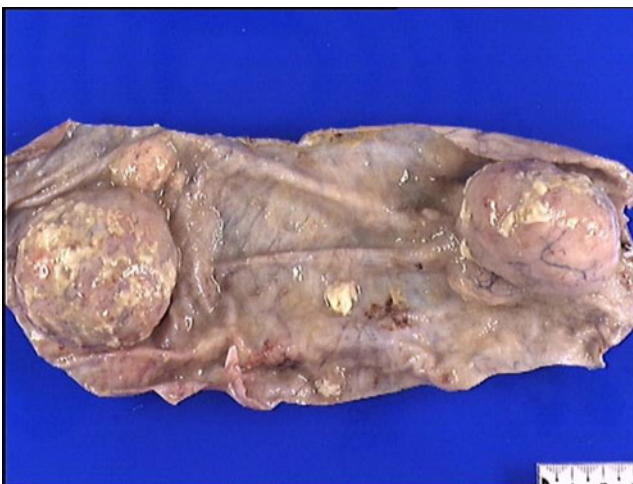

Fig. 3 Cyst lining showing two papillary masses

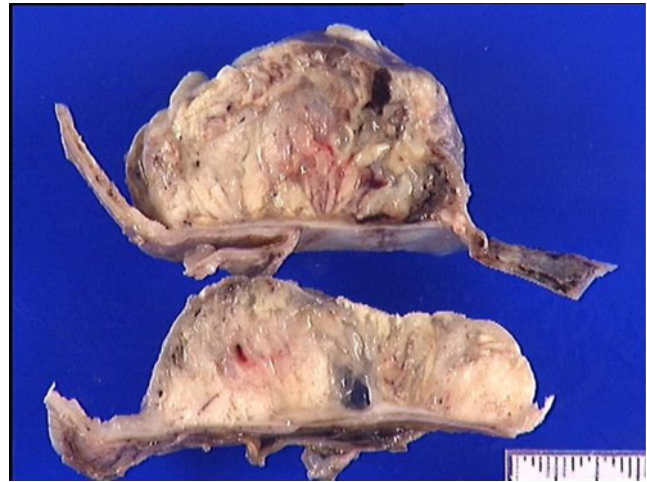

Fig. 4 Macroscopic aspect of the cyst wall after slicing showing variable thickness with solid papillary masses

increase in abdominal girth revealed by clothing too tight to be worn. Cysts are also detected incidentally on imaging studies or during routine gynaecological examination. The diagnosis can be overlooked because of pronounced obesity or negligence in patients who present at a late stage with giant ovarian cysts [1–4]. In 1922, Spohn reported successful treatment in a patient with a huge ovarian cyst weighing 148.6 kg [6]. In 2007, Yanazume et al. reported a cyst estimated at 100 kg. Unfortunately, the patient died of massive abdominal bleeding caused by disseminated intravascular coagulation 10 h postoperatively. Generally speaking, the majority of giant ovarian tumours are benign, borderline or of low malignant potential because when invasive cancer is present, clinical symptoms occur before the mass reaches a significant volume [7].

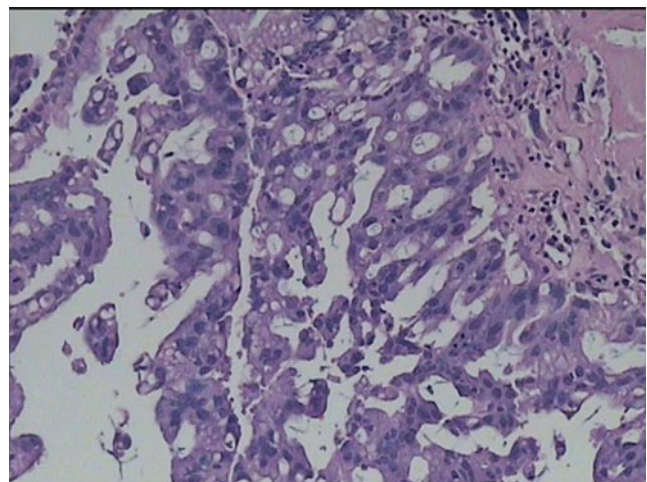


Fig. 5 Microscopic appearance of the cyst wall. Cellular and nuclear atypias are visible which remain confined to the epithelium without transgression of the basal membrane

These huge neglected cysts can mimic other medical conditions on physical examination, like pregnancy, massive ascites, colonic volvulus and idiopathic megacolon [5], and they can give rise to various clinical complications resulting from local compression such as abdominal pain, hydronephrosis and aortocaval compression. This last condition is a well-known complication of supine positioning in pregnant women beyond 16–20 weeks of gestation but is often underestimated in subjects with intra-abdominal pathology. It has to be considered because of its anaesthetic implications (essentially resulting in positioning the patient in a left lateral tilt position in order to avoid hypotension) [8].

The surgical resection of these masses can be delicate. The cyst capsule should be respected to avoid potential tumoural dissemination. Hemodynamic instability induced by fluid depletion and aortocaval decompression during removal of the cyst is also a concern. Some advocate progressive preoperative drainage to avoid the development of severe clinical hypotension [7, 9]. Five potential problems have been associated with the resection of massive ovarian tumours: respiratory failure, intraoperative fluids shifts, adequate exposure, orthostatic hypotension and adynamic intestine. The patient reported by Yanazome et al. indicates that there may be a risk of significant bleeding from redundant parietal peritoneum, and the authors recommend that sufficient amounts of blood be prepared should transfusion be necessary.

When indicated, abdominoplasty is performed at a later stage when the patient has fully recovered.

Conflicts of interest The authors report no conflicts of interest. The authors alone are responsible for the content and writing of the paper.

References

1. Ton-Ho Y, Heng-Sheng L (2008) Giant ovarian cyst. *NEJM* 15 (20):358
2. Mulayim B, Gurakan H, Dagli V, Mulayim S, Aydin O, Akkaya H (2006) Unaware of a giant serous cyst adenoma: a case report. *Arch Gynecol Obstet* 273:381–383
3. Bernal Martinez S, Luna Benitez I, Olivares Valencia CV et al (2001) Giant cyst of the ovary. Report of a case. *Ginecol Obstet Méx* 69:259–261
4. Sujatha VV, Babu SC (2009) Giant ovarian serous cystadenoma in a postmenopausal woman: a case report. *Cases J* 2:7875
5. Myers ER, Bastian LA, Havrilesky LJ, Kulasingam SL, Terplan MS, Cline KE, Gray RN, McCrory DC (2006) Management of adnexal mass. *Evid Rep Technol Assess* 130:1–145
6. Spohn AE (1905–1906) Multicystic ovarian tumor weighing 328 lb. *Tex Med J* 1:273–274
7. Yanazume Y, Yoshinaga M, Yanazume S, Kamikihara T, Tokunaga M, Kamio M, Douchi T (2007) Giant ovarian cancer weighing 100 kg with poor prognosis. *J Obstet Gynaecol Res* 33(1):91–94
8. Kuczkowski KM, Strock D (2004) Large ovarian cyst as a cause of aortocaval compression. *Aesthesia* 59(11):1148
9. Menahem S, Shvartzman P (1994) Giant ovarian cyst mimicking ascites. *J Fam Pract* 39(5):479–481