

Douglas B. Yackel · George A. Vilos

Thermablate EAS: a new endometrial ablation system

Published online: 3 March 2004
© Springer-Verlag Berlin / Heidelberg 2004

Abstract *Objective:* To report on Thermablate EAS, the newest endometrial thermal balloon ablation system now available. *Design:* Thermablate EAS consists of a light-weight reusable hand-held treatment control unit (TCU) with a single use disposable catheter–balloon–cartridge system. Treatment time is <2.5 min. A 6.0-mm diameter catheter allows it to be used in an office or outpatient setting utilizing minimal anesthesia/analgesia. *Results:* Six-month follow-up data obtained under a Special Access Program for Health Canada in a series of 54 patients showed amenorrhea 20%, spotting 20%, hypomenorrhea 37%, eumenorrhea 16%, and persisting menorrhagia 6%. *Conclusion:* Thermablate EAS is the smallest, most portable, and simplest endometrial ablation presently available. High rates of clinical success and patient satisfaction combined with enthusiastic acceptance by clinicians of this compact device makes it a very attractive endometrial ablation system.

Keywords Endometrial ablation · Thermal balloon · Menorrhagia · Thermablate · EAS

Introduction

Menorrhagia affects about 20% of all pre-menopausal women and is the leading cause of iron-deficiency anemia [1]. Failure of this problem to respond to conventional medical therapy has often led to hysterectomy with many

structurally normal uteri being removed for dysfunctional uterine bleeding [2].

In the 1980s hysteroscopic endometrial ablation was introduced as a minimally invasive alternative to hysterectomy. In the past decade, a second generation of endometrial ablation systems evolved utilizing different energy sources such as hot liquid systems, microwave, electro-surgical, radiofrequency, laser, or cryotherapy [3]. Balloon systems include ThermaChoice (Ethicon, Somerville, N.J.), Cavaterm (Walsten Medical, Morges, Switzerland), and MenoTreat (Atos Medical AB, Hörby, Sweden). On 21 May 2003 Thermablate EAS (MDMI Technologies, Richmond, BC, Canada) was approved for sale in Canada with prior approval by the State Drug Administration in China. Approval for sale in Europe with Conformity European (CE) marking is imminent.

Device description

The Thermablate EAS consists of a light weight (approximately 700 g) reusable hand-held treatment control unit (TCU) with a single use disposable catheter–balloon–cartridge system (Fig. 1).

The single use cartridge is pre-filled with a proprietary biocompatible liquid that can safely be heated to temperatures in excess of 170°C. The disposable cartridge has a bayonet connector that forms an airtight seal to the TCU. An insulated 6-mm-diameter catheter connects the liquid reservoir to the soft, flexible tipped preformed silicone balloon which makes full contact with the endometrial cavity transferring the thermal energy to the endometrial lining and underlying myometrium (Fig. 2).

The TCU has treatment temperature, time, and pressure automatically controlled by a microprocessor which operates the electro-mechanical heating and pumping–draining systems. A liquid crystal display (LCD) provides pertinent information and instructions to the user. When turned on it takes approximately 8 min for the system to reach its operating temperature of 173°C during which time patient preparation including a paracervical block

D.B. Yackel is coinventor of Thermablate EAS and is a shareholder of MDMI Technologies, Inc.

D. B. Yackel (✉)
MDMI Technologies Inc.,
Suite 110-12051 Horseshoe Way, Richmond, BC,
V7A 4V4, Canada
e-mail: dyackel@mdmicanada.com

G. A. Vilos
St. Joseph's Health Care,
University of Western Ontario,
London, Ontario, N6A 4V2, Canada



Fig. 1 Thermablate EAS with cartridge partially exposed

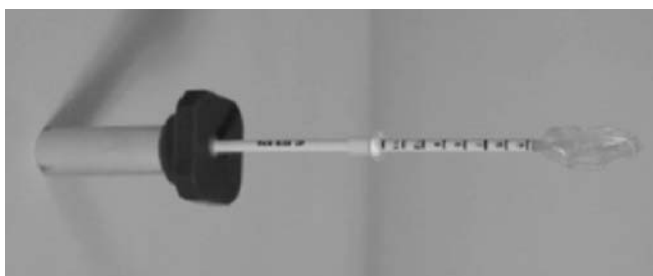

Fig. 2 Single-use catheter–balloon cartridge

can be administered. The device can remain in the treatment-ready state for 35 min before it automatically shuts down (Fig. 3).

When the heat up phase is completed a “Ready for Treatment” prompt is clearly displayed on the LCD along with a green light and an audible beep, indicating that the treatment can be initiated. Following insertion of the pre-lubricated balloon into the endometrial cavity, the treatment trigger is depressed for 5 s ending with an audible beep indicating that the system has been activated and the treatment cycle initiated. A 15-s balloon leak check is automatically carried out following which the hot liquid is pumped through the catheter into the balloon.

During treatment the TCU performs a series of pressurization and depressurization cycles to homogenize the temperature of the liquid in the balloon ensuring uniformity of energy and treatment at the balloon surface. Automatic adjustment of the pressure to 180 mm Hg is done every 10 s with the total treatment time being 128 s (2 min 8 s). Tissue necrosis to a uniform depth of 4–5 mm into the myometrium has been demonstrated in pre-hysterectomy studies. Balloon design provides lesser penetration of approximately 2 mm depth in both the cornual and internal cervical os areas. At the conclusion of treatment, the liquid is automatically withdrawn from the balloon into the canister which is then removed from the endometrial cavity and disposed. The higher temper-

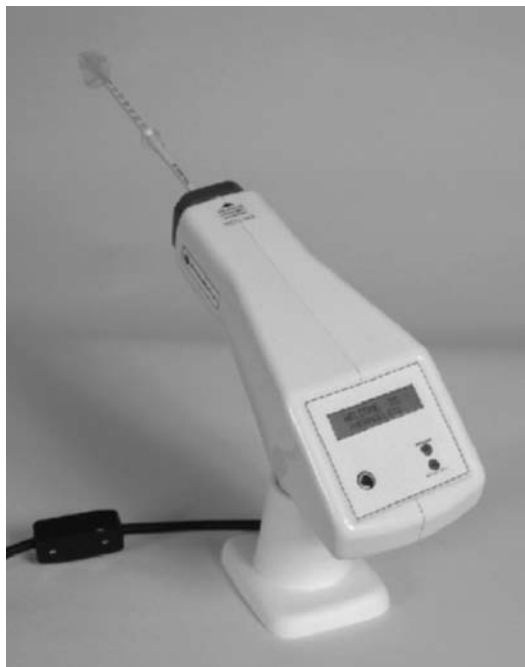

Fig. 3 Assembled Thermablate EAS with view of LCD

ature employed in the Thermablate EAS results in significantly shorter treatment time than is required with other existing balloon technologies.

Clinical trials evaluation

Pre-hysterectomy studies

Phase-I safety trial studies to establish time, temperature, and pressure profiles were carried out on seven patients each at Delta Hospital, Vancouver, BC, and University Hospital, Monterrey, Mexico. Histologic examination of the extirpated uteri confirmed that the most satisfactory results were obtained with a starting liquid temperature of 173°C and a treatment time of 128 s (2 min 8 s). Initial pressurization at 200 mm Hg then automatically adjusts to 180 mm Hg. The pressure is regulated every 10 s throughout the procedure by altering the required volume of liquid pumped into the balloon. Using these parameters tissue necrosis to a uniform depth of 4–5 mm into the myometrium was obtained and was confirmed with vital staining using nitroblue tetrazolium (Fig. 4)

Study in Bombay, India

A phase-II pilot study was carried out in Bombay, India, and has previously been reported. Sixteen women ranging in age from 34–48 years (mean age 41 years) were treated. At 6 months, follow-up showed 8 of 16 women reported amenorrhea (50%), 6 of 16 (38%) had hypomenorrhea or spotting, 1 had normal periods, and 1 failed

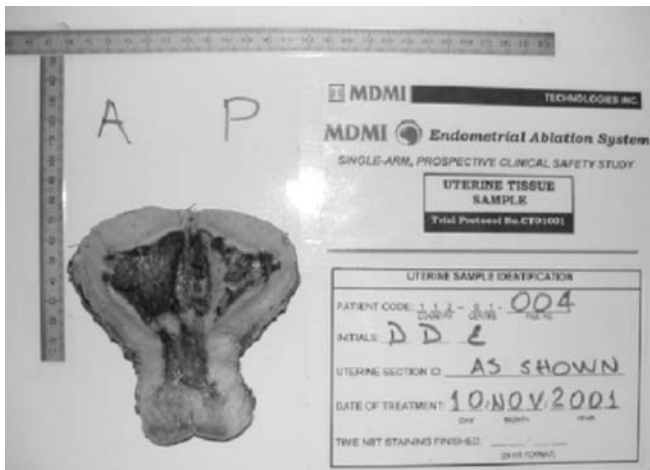


Fig. 4 Pre-treated hysterectomy specimen showing extent of tissue necrosis. (Courtesy of J. Garza-Leal, University Hospital, Monterrey, Mexico)

treatment; the latter had cystic endometrial hyperplasia which was documented on endometrial biopsy 2 weeks before therapy and was confirmed by hysteroscopy at the time of therapy. These results have remained unchanged at 1 and 2 years (pers. commun.).

These women had also experienced dysmenorrhea; mild=8, moderate=2, and severe=6. Following Thermablate treatment only one woman reported persistent mild dysmenorrhea. The overall satisfaction rate was 94% (15 of 16 women) with 11 women being very satisfied and 5 women satisfied [4].

Canadian studies

Prior to Canadian approval to market the Thermablate system in May 2003, a series of patients were treated under the Special Access Program of the Device Evaluation Division of the Therapeutic Products Directorate for Health Canada. From 26 September 2002 through 28 April 2003, 54 patients were approved for use of the device. Treatment was carried out by ten gynecologists in six university-affiliated and community hospitals.

Patient profiles were similar to those of other ablation studies. The mean age was 41.5 years (range 33–54 years). Four patients were nulliparous and two had four children, with seven not recorded. The remainder each had one to three children. Two patients each had one, two, and three cesarean deliveries, respectively, for a total of 12 cesarean births in the 6 patients.

No pretreatment using GnRH analogs, other medications, or timing in the cycle was carried out. Various medical conditions included morbid obesity (BMI >40 kg/m²), sleep apnea, previous history of arterial and venous thrombosis, hypertension with paroxysmal atrial tachycardia, and unsuitability or refusal for general anesthesia or other ablation techniques.

Anesthesia included the following:

General anesthesia	21 of 54	(39%)
Intravenous sedation (IVS)	14 of 54	(26%)
Paracervical block (PCB)	17 of 54	(31%)
IVS and PCB	2 of 54	(4%)

Sixteen patients (30%) were treated in an office or outpatient setting with no anesthesiologist present. There were no intra- or post-operative complications reported.

Patients were discharged within 4–6 h after ablation and required minimal postoperative analgesia. No readmissions to hospital occurred.

Follow-up results in 49 patients at 6 months (5 patients lost to follow-up) were as follows:

Amenorrhea	10 of 49	(20%)
Spotting	10 of 49	(20%)
Hypomenorrhea	18 of 49	(37%)
Eumenorrhea	8 of 49	(16%)
Menorrhagia	3 of 49	(6%)

In the 3 patients with unsatisfactory results, one had a vaginal hysterectomy which showed a 134-g uterus with the cavity showing fibrosis and hyalinization and only scant focal residual atrophic endometrium; two others are awaiting hysterectomy.

These preliminary results were presented at the 32nd Annual Meeting of the American Association of Gynecological Laparoscopists [5].

Discussion

Hysteroscopic ablation has resulted in high success rates of 75–100% (mean 85%) [6, 7, 8, 9, 10, 11]. These methods are skill dependent, require intensive training and expertise, and are not free of complications such as perforation, hemorrhage, visceral injury, and excessive fluid overload absorption.

Thermal balloon ablation requires minimal training and is easy to perform. Low rates (2–4%) of minor problems, such as post-operative infection or hematometra formation, were initially reported [12, 13]. Recently, more serious complications, such as bowel and other thermal injuries, have also been reported in second-generation endometrial ablation systems [14].

Correct patient selection has been stressed to ensure good results [15]. A large uterus, active pelvic infection, evidence of malignant or pre-malignant changes, and the desire to maintain fertility are absolute contraindications. The presence of myomas, especially submucous and intramural >3 cm, or the suspicion of adenomyosis, are likely to reduce success [16]. Rates of success with thermal balloon ablation have paralleled other ablation techniques with 80–90% patient satisfaction expected [17, 18]. Long-term follow-up studies on balloon ablation continue to show highly satisfactory outcomes [19, 20].

Conclusion

Thermablate EAS is the smallest, most portable, and simplest endometrial ablation presently available. A short treatment time of <2.5 min and small (6-mm) diameter catheter allows it to be used in an office or outpatient setting using minimal anesthesia.

The Thermablate EAS is safe and effective in treating menorrhagia especially when other therapies are contraindicated or difficult to perform.

High rates of amenorrhea, spotting, hypomenorrhea, and patient satisfaction have been achieved, and enthusiastic acceptance by clinicians of this compact device makes it a very attractive endometrial ablation system.

Acknowledgements The authors gratefully acknowledge the participation of the following gynecologists in the Canadian trials: S. Tregoning, B.K. Pirani (MSA Hospital, Abbotsford, BC); Y. Kalyanpur, H. Mackoff, H. Robson (Richmond Hospital, Richmond, BC); S. Kaye, E. Hoyer (Lions Gate Hospital, Vancouver, BC); A. Ternamian, N. Leyland (St. Joseph's Health Centre, Toronto, Ontario)

References

1. Snowden R, Christian B (1983) Patterns and perceptions of menstruation: a World Health Organization International Study. London, Croon Helm
2. Garry R (1995) Endometrial laser ablation. *Baillieres Clin Obstet Gynecol* 9:319–328
3. Vilos GA (2000) Global endometrial ablation. *J Obstet Gynaecol Can* 22:668–675
4. Mangeshkar PS, Kapur A, Yackel DB (2003) Endometrial ablation with a new thermal balloon system. *J Am Assoc Gynecol Laparosc* 10:27–32
5. Vilos GA (2003) Endometrial ablation with a new balloon system (Thermablate EAS) to treat menorrhagia in high-risk surgical candidates. *J Am Assoc Gynecol Laparosc* 10:536
6. deWit A (1993) Hysteroscopy: an evolving case of minimally invasive therapy in gynecology. *Health Policy* 23:113–124
7. Baggish MS, Sze EH (1996) Endometrial ablation: a series of 568 patients treated over an 11-year period. *Am J Obstet Gynecol* 174:908–913
8. Garry R (1995) Endometrial laser ablation. *Baillieres Clin Obstet Gynecol* 9:319–328
9. Erian J (1994) Endometrial ablation in the treatment of menorrhagia. *Br J Obstet Gynaecol* 101 (Suppl 11):19–22
10. Vilos GA, Vilos EC, King JH (1996) Experience with 800 hysteroscopic endometrial ablations. *J Am Assoc Gynecol Laparosc* 4:33–38
11. O'Connor H, Magos A (1996) Endometrial resection for the treatment of menorrhagia. *N Engl J Med* 335:151–156
12. Meyer WR, Walsh BW, Grainger DA et al. (1998) Thermal balloon and rollerball ablation to treat menorrhagia: a multi-center comparison. *Obstet Gynecol* 92:98–103
13. Vilos GA, Fortin CA, Sanders B et al. (1997) Clinical trial of the uterine balloon for treatment of menorrhagia. *J Am Assoc Gynecol Laparosc* 4:559–565
14. Gurtcheff SE, Sharp HT (2003) Complications associated with global endometrial ablation: the utility of the MAUDE Database. *Obstet Gynecol* 102:1278–1282
15. Garry R (1995) Good practice with endometrial ablation. *Obstet Gynecol* 86:144–151
16. Yackel DB (1999) Menorrhagia treated by thermal balloon endometrial ablation. *J Obstet Gynaecol Can* 21:1076–1080
17. O'Connor H, Magos AL (1996) Long-term results of endometrial resection. *J Am Assoc Gynecol Laparosc* 3:S535
18. Roy KH, Mattox JH (2002) Advances in endometrial ablation. *CME Review Article. Obstet Gynecol Surv* 57:789–802
19. Amso NN, Fernandez H, Vilos GA, Fortin C, McFaul P, Schaeffer M et al. (2003) Uterine endometrial thermal balloon therapy for the treatment of menorrhagia: long-term multicentre follow-up study. *Hum Reprod* 18:1082–1087
20. Loffer FD, Grainger D (2002) Five-year follow-up of patients participating in a randomized trial of uterine balloon therapy versus rollerball ablation for treatment of menorrhagia. *J Am Assoc Gynecol Laparosc* 9:429–435