

Erratum to: Benign chondroid syringoma (mixed tumor of skin) on the flank with satellites: case report and literature review

U. Wollina · U. Sturm · J. Schönlebe

Published online: 24 October 2014
© Springer-Verlag Wien 2014

Erratum to: Wien Med Wochenschr (2014) 164:377–380
DOI 10.1007/s10354-014-0302-0

Unfortunately, figure legend of Fig. 2 is incorrect. Please find the correct one below.

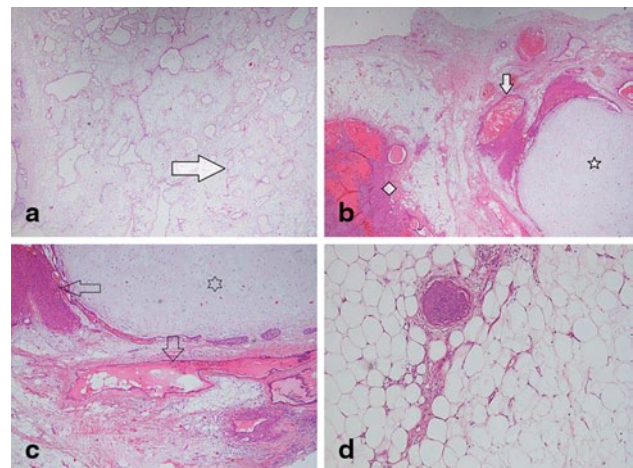


Fig. 2 Mixed tumor of skin. Histopathology (hematoxylin-eosin). **a** Overview ($\times 2$) demonstrating syringoma-like spaces (*arrow*) embedded in a sclerotic stroma. **b** Overview ($\times 2$) demonstrating a mixture of solid basaloid areas (*square*), chondroid areas (*star*), and keratin cysts (*arrow*). **c** Detail ($\times 4$) presenting solid areas (*horizontal arrow*), clear cells areas (*vertical arrow*), and chondroid cells within a chondroid stroma (*star*). **d** Detail ($\times 10$) demonstrating a small basaloid island in the adipose tissue stroma

The online version of the original article can be found under doi:<http://dx.doi.org/10.1007/s10354-014-0302-0>

Prof. Dr. med. U. Wollina, MD (✉)
Department of Dermatology and Allergology,
Academic Teaching Hospital Dresden-Friedrichstadt,
Friedrichstrasse 41,
01067 Dresden, Germany
e-mail: wollina-uw@khdf.de

U. Sturm, MD
Practice for Pathology,
Steubener Str. 12,
01279 Dresden, Germany

J. Schönlebe, MD
Institute of Pathology,
Academic Teaching Hospital Dresden-Friedrichstadt,
Friedrichstrasse 41,
01067 Dresden, Germany