



# Radiographic pelvimetry in free-ranging Eurasian lynx (*Lynx lynx carpathicus*) from Switzerland

Fanny Morend<sup>1</sup> · Johann Lang<sup>2</sup> · Beatriz Vidondo<sup>3</sup> · Marie-Pierre Ryser-Degiorgis<sup>1</sup>

Received: 24 September 2021 / Revised: 20 May 2022 / Accepted: 13 June 2022 / Published online: 6 July 2022  
© The Author(s) 2022

## Abstract

The observation of pelvic anomalies in two Eurasian lynx (subspecies *Lynx lynx carpathicus*) from a population reintroduced to Switzerland raised the question of the frequency of such anomalies, but no anatomical reference values were available for comparison. This study aimed at providing baseline data on the pelvic morphology of Carpathian lynx from Switzerland, and at detecting potential pelvic anomalies. Measurements of 10 pelvic parameters were performed on the radiographs of 56 lynx taken from 1997–2015. Two ratios (vertical diameter/acetabula; sagittal diameter/transversal diameter) and two areas (pelvic outlet and inlet) were calculated to describe pelvic shape. The results showed that the Eurasian lynx has a mesatipellic pelvis, with a pelvic length corresponding to approximately 20% of the body length. We found growth-related pelvis size differences among age classes and evidence of sexual dimorphism in adults: two parameters reflecting pelvic width were larger in females, likely to meet the physiological requirements of parturition. By contrast, pelvis length, conjugata vera, diagonal conjugata, sagittal diameter, and tendentially also vertical diameter, were larger in males, in agreement with their larger body size. Outliers were found in five individuals but apparently without clinical significance. Extreme values were likely due to inter-individual differences and the limited sample size rather than to possible congenital or developmental pathological morphology of the pelvic cavity. We present baseline data of the pelvic morphology, including growth and sexual dimorphism, which may be useful for health monitoring and for determination of age and sex in skeletal remains of Carpathian lynx.

**Keywords** Anatomy · Felid · Health · Malformation · Pelvis · Skeleton

## Introduction

The Eurasian lynx (*Lynx lynx*) is a medium-sized felid species belonging to the subfamily of large felids (Pantherinae). It is widely distributed in both Europe and Asia, and according to the International Union for Conservation of Nature (IUCN) Red List, it is a species of least concern on a global scale. However, in Europe its range has strongly shrunken

until the end of the nineteenth century due to habitat loss and persecution (Schmidt et al. 2011). Currently, the occurrence of *L. lynx* in continental Europe is highly fragmented, and of the 11 existing populations, only five are native while the other six have been reintroduced (Chapron et al. 2014). The Carpathian lynx (*L. lynx carpathicus*) is one of the nine currently proposed subspecies of the Eurasian lynx, which present varying phenotype characteristics including anatomical differences (Breitenmoser and Breitenmoser-Würsten 2008; Gomerčić et al. 2010; Schmidt et al. 2011; Kubala et al. 2019). Nowadays the Carpathian lynx only occurs in small, isolated and genetically impoverished populations in continental Europe (Breitenmoser-Würsten and Obexer-Ruf 2003; Schmidt et al. 2011; Krojerová-Prokešová et al. 2019).

Like in other European countries, in Switzerland the Eurasian lynx vanished at the end of the nineteenth century. Following habitat improvements and prey recovery, reintroductions took place in the 1970s, using Carpathian lynx imported from Slovakia. Two small, geographically

✉ Marie-Pierre Ryser-Degiorgis  
marie-pierre.ryser@vetsuisse.unibe.ch

<sup>1</sup> Institute for Fish and Wildlife Health (FIWI), Department of Infectious Diseases and Pathobiology, Vetsuisse Faculty, University of Bern, Bern, Switzerland

<sup>2</sup> Clinical Radiology, Department of Clinical Veterinary Medicine, Vetsuisse Faculty, University of Bern, Bern, Switzerland

<sup>3</sup> Institute for Veterinary Public Health, Vetsuisse Faculty, University of Bern, Bern, Switzerland

and genetically distinct lynx populations resulted from these releases: one in the Swiss Alps, extending slightly into France and Italy, and another in the Jura Mountains, across the border with France. Less than 250 independent lynx were estimated to occur on the Swiss territory in 2018, including approximately 60 in the Jura and 170 in the Alps ([www.kora.ch](http://www.kora.ch)). Genetic variability is low and associated with a high inbreeding coefficient (Breitenmoser-Würsten and Obexer-Ruf 2003). In Switzerland, free-ranging lynx can reach 18 years of age (Marti and Ryser-Degiorgis 2018a). Adult females weigh 15–21 kg, with a body length (in physiological position) varying between 92–105 cm, while adult males weigh 19–27 kg and are 87–109 cm long (Marti and Ryser-Degiorgis 2018b).

A lynx health monitoring program has been conducted at the Centre for Fish and Wildlife Health (FIWI) in Switzerland for several decades, including necropsies of carcasses, clinical examinations of live lynx and systematic collection of a range of samples in both dead and live lynx (Schmidt-Posthaus et al. 2002; Ryser-Degiorgis and Segner 2015; Ryser-Degiorgis et al. 2021). From 2004 onwards, there has been increasing concern about inbreeding depression, in particular in the Alpine population (Breitenmoser-Würsten and Obexer-Ruf 2003; Ryser-Degiorgis et al. 2013). Among others (Ryser-Degiorgis et al. 2004, 2020), pelvic anomalies were detected in two orphaned lynx from the Swiss Alps, BETHLI in 2006 and an older case found in the FIWI archives (online resource 1). This raised questions regarding the frequency of pelvic malformations in lynx in Switzerland. From then until the present study was carried out, pelvic radiographs have been systematically taken of dead lynx submitted to necropsy and of live lynx to be translocated for reintroduction programs in neighbouring countries.

Narrowing of the pelvis or its deformation may occur due to malunion of a previously fractured pelvis, metabolic disorders or congenital pelvic malformations, and it may result in complications such as obstipation and dystocia (Schrader 1992; Celimli et al. 2008; Batista-Arteaga et al. 2011). Currently there are no studies proving the heritability of pelvic characteristics in felids. Nevertheless, it has been demonstrated in Boston terrier dogs that 26 per cent of the offspring's pelvic shape could be explained by the pelvic shape of the parents (Linde-Forsberg 2002; Celimli et al. 2008; Monteiro et al. 2013). Thus, there were concerns that, if pelvic shape were also inherited in lynx, pelvic malformation and narrowing may occur at an increased frequency in the inbred lynx population in Switzerland. This may have an impact on population dynamics in the long-term due to fatalities linked to chronic obstipation and dystocia.

Radiographic examination followed by pelvic measurements is a valuable method to assess pelvic narrowing or malformation. Pelvimetry consists of measuring distances and angles between pelvic structures, either with

radiographic measurements or by palpation. However, radiographs obviously deliver more accurate data than palpation. Furthermore, the use of radiographs allows carrying measurements after the patient is gone. Thus, radiographic pelvimetry is often used to calculate the pelvic size in humans, and has also been employed in domestic animals such as cats (Celimli et al. 2008; Monteiro et al. 2013), dogs (Eneroth et al. 1999; Ocal et al. 2003), cattle (Van Donkersgoed 1992), sheep (Cloete and Haughey 1990) and Indian buffaloes (Malik et al. 1990). Post-release or post-mortem radiographic pelvimetry obviously represent an interesting approach also for wildlife studies. More recently, pelvimetry has been performed using computer tomography in rabbits (Özkadif et al. 2014) and cats (Yilmaz et al. 2020; Yilmaz and Demircioğlu 2020); however, as stated by the authors, this method has significant limitations as only a few institutions are equipped for computed tomography, costs are high and expert staff is required.

The Swiss lynx populations serve as sources for reintroductions in other European countries (Ryser-Degiorgis et al. 2021) and it is therefore essential to thoroughly assess their health status. The objectives of the present study were: (i) to deliver baseline data on the pelvic morphology of Eurasian lynx from the reintroduced populations in Switzerland; (ii) to assess potential differences in pelvic conformation between the two main populations, among age classes and between sexes; and (iii) to detect pelvic abnormalities that may have been missed by routine evaluation of radiographs.

## Material and methods

### Animals

We used a convenience sample consisting of all available radiographs of free-ranging lynx ( $n = 100$ ) taken from 1997 to 2015 at the Vetsuisse Faculty of the University of Bern. Of these lynx, 86 were found dead and necropsied at the FIWI, and 14 were captured in the field and taken to a quarantine station before translocation or rehabilitation under veterinary supervision of FIWI staff. Live lynx were trapped and anesthetized following established protocols and with all permits required by the Swiss legislation. Anesthesia was performed by intramuscular injection of medetomidine and ketamine hydrochloride (2.8 mg medetomidine and 80 mg ketamine per adult or subadult lynx, i.e., approx. 0.13–0.17 mg/kg medetomidine and 3.6–5.0 mg/kg ketamine depending on the weight measured during manipulations), and atipamezole (five times the medetomidine dosage) was used for reversal as previously described (Ryser-Degiorgis et al. 2021).

Age was determined based on field data (animals identified as kittens) or tooth cementum analysis (Matson's Laboratory, Manhattan, USA), or estimated using morphological criteria

such as body size and weight, growth plates, tooth replacement and tooth wear (Marti and Ryser-Degiorgis 2018a, b; Ryser-Degiorgis et al. 2021). Age classes were defined as previously described (Marti and Ryser-Degiorgis 2018a): juveniles included lynx in their first year of life; subadults ranged from 12–24 months for females and from 12–36 months for males; and adults corresponded to females > 24 months and males > 36 months (post-growth period). Definitions of the subadult and adult age categories differ between females and males because they base on reproductive biology, social behavior and body growth (Breitenmoser and Breitenmoser-Würsten 2008; Marti and Ryser-Degiorgis 2018b).

Body length was measured at necropsy and corresponded to a projection of the stretched lynx body from the tip of the nose to the sacrococcygeal joint (so-called stretched body length) (Marti and Ryser-Degiorgis 2018b). It was available for 45 individuals.

## Radiology

All dead animals were radiographed at the small animal hospital of the University of Bern. Fourteen live lynx were also radiographed but for most of them it was done with a portable unit at the quarantine station. The x-ray units used to obtain the radiographs included a General Electrics Prestige SI (65 kW), a Swissray Gen-X-80 kW unit, a Siemens Polydoros LX Lite Power Up 100 kW, and a portable Gierrth HF 300 (Riesa, Germany) for radiographs taken at the quarantine station. The imaging systems included a Fuji FCR AC-3 and Fuji FCR Profect one reader. The imaging plates were FCR ST-V general purpose plates, standard dual side imaging plates (ST-BD) and dual sided mammographic HR-BD plates. For the mobile system, film-focus distance was 100 cm, for the stationary system 20 cm, the exposure 63 kV/5 mAs for the mobile system and varied between 54 kVp/20 mAs to 70 kVp/25 mAs for the stationary systems used. Ventrodorsal and left or right lateral views of the pelvis were obtained.

## Pelvimetry

Pelvimetry was only possible in 62/100 lynx, as 38/100 had only one projection available, inadequate positioning, incompletely imaged pelvis, or recent pelvic fractures that did not allow exact measurements. We also conducted pelvimetry on radiographs of the juvenile female with obviously abnormal pelvis (BEHTLI; Fig. 1, online resource 1).

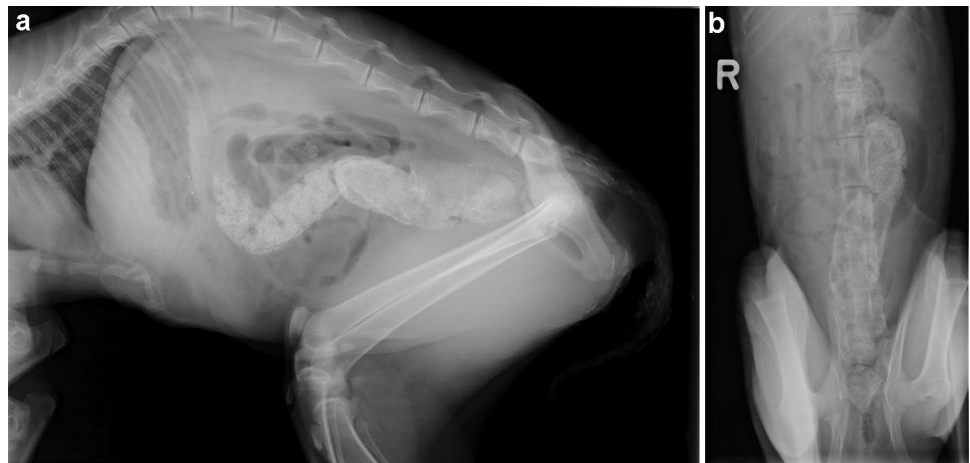
We performed all pelvic measurements directly on the radiographs with the radiology information system IMPAX EE (Agfa Health care, Bonn Germany), using a measurement tool with 0.01 cm accuracy. Each measurement was taken three times by the first author (FM) and the average of the three values was retained. To correct for differences resulting from varying film-focus distance (muscle mass) between the mobile (100 cm) and stationary radiographic systems (120 cm), 15% was subtracted from the values obtained with the portable system.

Similarly to previous studies in domestic cats (Celimli et al. 2008; Monteiro et al. 2013), data collection comprised five measurements in the left–right or right–left lateral projection and five in the ventro–dorsal projection. In addition, we calculated two ratios between the height and width of the pelvis and estimated two pelvic areas. Measurements and abbreviations are explained in Table 1 and shown in Fig. 3.

## Data analysis and statistics

We stored all data in a MS Excel<sup>®</sup> spreadsheet and imported them into the statistical software NCSS (NCSS 2015). Inclusion criteria for statistical analysis were 1) availability of full pelvimetric records, age and sex, 2) pelvic length larger than 10 cm. The threshold of 10 cm is arbitrary and was given by data scarcity below this value and the particularly rapid growth in small juveniles. These criteria led to the exclusion of one adult from the Jura population of unknown sex and five kittens < 4 month-old The 56

**Fig. 1** Abnormal pelvis, Eurasian lynx (*Lynx lynx carpathicus*): **a** Latero-lateral and **b** ventrodorsal projection of the pelvis of a juvenile female, north-eastern Swiss Alps (specimen W06/1532, BEHTLI), asymmetric pelvis and abnormally narrow pelvic canal with accumulation of fecal material in the descending colon and rectum



**Table 1** Pelvic measurements taken on radiographs of Eurasian lynx from Switzerland (*Lynx lynx carpathicus*)

<i>Linear distances (cm)</i>		
<i>PL</i>	Pelvis length	Distance between the most distant Ilium bone extremities (iliac crest and ischial tuberosity)
<i>CV</i>	Conjugata vera	Distance between the promontory and cranial pubic symphysis
<i>DC</i>	Diagonal conjugata	Distance between the promontory and caudal pubic symphysis
<i>VD</i>	Vertical diameter	Vertical distance between the cranial portion of the pubic symphysis and the mid sacrum, i.e. pelvis height
<i>SGD</i>	Sagittal diameter	Distance between caudal sacral and caudal symphysis
<i>FO</i>	Foramen obturatum	Inner length of the foramen obturatum
<i>CT</i>	Coxal tuberosities	horizontal distance between the iliac crests
<i>TD</i>	Transversal diameter	horizontal distance between ilial shafts
<i>AC</i>	Acetabula	horizontal distance between acetabula, i.e. pelvis width
<i>LIT</i>	Lateral ischial tuberosities	horizontal distance between the lateral ischial tuberosities
<b>Areas (cm<sup>2</sup>)</b>		
<i>PIA</i>	Pelvis inlet area	Planar surface corresponding to the boundary between the pelvic and the abdominal cavity $PIA = (CV/2 + TD/2)^2 \times \pi$
<i>POA</i>	Pelvic outlet area	Lower circumference of the lesser pelvis $POA = (VD/2 + AC/2)^2 \times \pi$
<b>Ratios (height/width)</b>		
<i>SGD/TD</i>		
<i>VD/AC</i>		

remaining lynx included 32 animals from the Alps, 22 from the Jura, and two from a recently reintroduced population nucleus in north-eastern Switzerland. There were 26 males and 30 females; and 24 juveniles (4–12 months old), 11 subadults and 21 adults.

For each group of population, age and sex, we visually examined data distribution using quantile plots, histograms and box-plots to check for errors and outliers. In the box-plots the whiskers were drawn as the box edge  $\pm 1.5$  times the interquartile range and the severe outlier boundary was set at box edge  $\pm 3$  times the interquartile range. Due to the large body size variation inherent in the juvenile age class (Marti and Ryser-Degiorgis 2018b) and the poor sample size of subadults, differences between sexes were tested for adult individuals only. We performed univariate analyses to assess for differences between the two main populations (Alps and Jura), and between sexes for all pelvic measurements, using non-parametric tests such as the Mann–Whitney–Wilcoxon (for population and sex) or Kruskal–Wallis (for age) For these analyses, the two lynx from the north-eastern population were also excluded. The level of significance was set to 0.05.

BETHLI was not included in the statistical analyses. Instead, the data of this animal were compared to the measurements of six other lynx of the same age and with similar pelvic length (“controls”, including three females and three males, as sexual dimorphism appears only after one year of age; Marti and Ryser-Degiorgis 2018b).

Were prepared the figures using Microsoft Power Point (Microsoft Corporation 2018, <https://office.microsoft.com>) and the free software GIMP (GIMP 2019).

## Results

Descriptive statistics of the radiographic pelvic parameters per age class and sex are shown in Table 2 and Fig. 3. We found a total of 15 outliers for five linear pelvis parameters (VD, CT, TD, LIT, PL) and body length, concerning five lynx of both sexes, either juvenile or adult, with 1–4 concerned values per lynx (Fig. 2). Among juveniles, a male from the Alps (W09/1096) estimated to 10–11 months old had higher values for CT (pelvis width parameter), pelvis length and body length, and a juvenile female from the Alps (W13/5753) estimated to 8 months old had a much longer body length compared to other juvenile females. Furthermore, a male from the Jura (W15/4039) estimated to 6–7 months old had a slightly higher LIT value (pelvis width parameter). Among adults, two females (ALMA from the Jura and FREIA from the Alps) and a male from the Jura (JURO) showed lower values for a few linear width and height parameters, ALMA also for the pelvis length, despite a body length within the range of other adults of the same sex. Although other parameters did not stand out in the statistical analysis, ALMA and FREIA also had the lowest values of all adult females for the pelvis length, VD, SGD, CT, TD, AC,

**Table 2** Mean, standard deviation and range (minimum–maximum) of the pelvis parameters of 30 free-ranging female and 26 male Eurasian lynx (*Lynx lynx*) from Switzerland, 1997–2015. Sample size (n) is indicated for each sex/age group

Pelvic measurements	Males			Females		
	Juveniles (n = 11)	Subadults (n = 6)	Adults (n = 9)	Juveniles (n = 13)	Subadults (n = 5)	Adults (n = 12)
<b>Linear distances (cm)</b>						
PL	12.13 ± 0.99 (10.80–14.47)	14.91 ± 1.34 (12.78–16.77)	17.03 ± 1.26 (13.97–17.97)	11.79 ± 0.80 (10.60–13.37)	14.05 ± 2.17 (11.36–16.50)	15.62 ± 1.64 (11.96–17.47)
CV	5.00 ± 0.43 (4.25–5.84)	5.38 ± 0.51 (4.63–5.89)	5.80 ± 0.53 (4.72–6.42)	4.79 ± 0.20 (4.52–5.09)	5.04 ± 0.65 (4.34–5.99)	5.43 ± 0.52 (4.33–5.92)
DC	8.68 ± 0.62 (7.40–10.33)	10.30 ± 1.12 (8.96–11.7)	11.50 ± 1.00 (9.35–12.43)	8.43 ± 0.48 (7.89–9.39)	9.64 ± 1.30 (8.29–11.13)	10.73 ± 1.14 (8.29–11.7)
VD	4.59 ± 0.33 (4.10–5.33)	5.15 ± 0.55 (4.23–5.62)	5.56 ± 0.49 (4.69–6.03)	4.33 ± 0.19 (4.07–4.58)	4.52 ± 0.58 (3.81–5.52)	5.28 ± 0.52 (4.19–5.85)
SGD	5.93 ± 0.52 (5.08–7.03)	7.02 ± 0.82 (5.97–8.15)	7.92 ± 0.76 (6.31–8.50)	5.69 ± 0.33 (5.17–6.32)	6.25 ± 1.07 (4.66–7.29)	7.33 ± 0.82 (5.74–8.04)
FO	3.28 ± 0.33 (2.78–3.85)	3.91 ± 0.50 (3.11–4.43)	4.36 ± 0.46 (3.44–4.88)	3.12 ± 0.27 (2.80–3.58)	3.75 ± 0.63 (3.21–4.46)	4.18 ± 0.49 (3.16–4.89)
CT	6.37 ± 0.53 (5.57–7.59)	7.19 ± 0.90 (5.79–8.03)	8.05 ± 0.87 (6.37–9.08)	6.09 ± 0.53 (5.23–6.93)	6.94 ± 1.12 (5.74–8.40)	7.74 ± 0.94 (5.71–8.92)
TD	3.02 ± 0.18 (2.81–3.51)	3.62 ± 0.45 (3.02–4.08)	3.98 ± 0.34 (3.27–4.43)	2.89 ± 0.19 (2.57–3.24)	3.42 ± 0.49 (2.93–3.93)	4.11 ± 0.52 (3.07–4.64)
AC	2.62 ± 0.17 (2.35–2.87)	3.34 ± 0.66 (2.69–4.06)	3.94 ± 0.33 (3.46–4.39)	2.55 ± 0.24 (2.22–3.06)	3.14 ± 0.54 (2.50–3.73)	3.95 ± 0.53 (2.86–4.49)
LIT	6.03 ± 0.70 (4.89–7.30)	7.60 ± 1.05 (6.15–8.86)	8.85 ± 0.72 (7.77–9.94)	5.77 ± 0.44 (5.23–6.50)	7.02 ± 1.12 (5.88–8.48)	8.53 ± 0.95 (6.43–9.26)
<b>Areas (cm<sup>2</sup>)</b>						
PIA	50.74 ± 7.38 (41.40–68.71)	64.12 ± 12.47 (45.92–73.90)	75.60 ± 12.14 (50.14–87.20)	46.52 ± 4.56 (39.44–54.15)	56.94 ± 15.04 (41.47–77.18)	72.23 ± 14.13 (43.05–84.84)
POA	40.97 ± 4.94 (34.70–52.72)	57.50 ± 15.11 (38.15–73.59)	71.72 ± 11.59 (52.21–83.81)	37.31 ± 4.46 (31.04–44.65)	46.72 ± 13.13 (31.30–64.80)	67.59 ± 13.32 (39.04–79.17)
<b>Ratios (height/width)</b>						
SGD/TD	1.96 ± 0.11 (1.76–2.13)	1.94 ± 0.07 (1.84–2.01)	1.99 ± 0.08 (1.88–2.13)	1.97 ± 0.08 (1.85–2.18)	1.83 ± 0.14 (1.59–1.97)	1.79 ± 0.11 (1.58–1.93)
VD/AC	1.76 ± 0.14 (1.58–1.96)	1.57 ± 0.22 (1.38–1.89)	1.40 ± 0.06 (1.34–1.49)	1.70 ± 0.11 (1.46–1.85)	1.45 ± 0.11 (1.28–1.56)	1.35 ± 0.11 (1.19–1.53)

LIT and the two areas PIA and POA. Similarly, JURO had the lowest values for all linear parameters (except LIT: no data) and the two areas. Information on body length was not available for these three individuals. By contrast, an adult male from the Jura (W11/4290) with pelvis measurements within the range of other adult males had a much shorter body length.

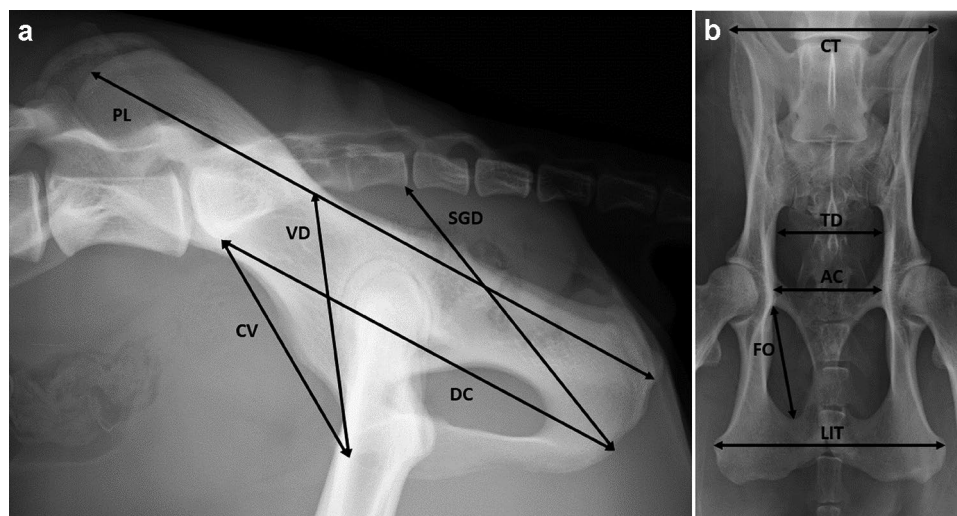
## Population

The mean values of all parameters were very close for the two populations, with either the Alpine or the Jura value being slightly higher. Mean values were nearly identical for PL (Alps 141.3, Jura 141.5) and only slightly higher in

the Alps for CV (Alps 52.7, Jura 51.7) and CT (Alps 70.9, Jura 69.4). Given these minor differences, we could pool the two populations for other analyses.

## Age

All linear radiographic pelvic measurements increased significantly with age (Table 2, Fig. 3,  $p = 0.000$  for all parameters). Regarding the pelvic height/width relationships, we found evidence of a decrease with age for both the VD/AC ( $p = 0.000$ ) and the SGD/TD ratio (this last parameter with smaller differences and a p-value close to the significance level; Table 2,  $p = 0.037$ ).



**Fig. 2** Measurements taken for pelvimetry: Pelvis, Eurasian lynx (*Lynx lynx carpathicus*), subadult male; **a** Left–right latero-lateral radiograph showing pelvis length (PL); conjugata vera (CV); diagonal conjugata (DC); vertical diameter (VD); and sagittal diameter

(SGD); **b** Ventro-dorsal radiograph showing the inner length of the foramen obturatum (FO); coxal tuberosities (CT); transversal diameter (TD); acetabula (AC); and lateral ischial tuberosities (LIT)

## Sex

Adult individuals showed evidence of sex-specific differences for PL ( $p=0.011$ ), CV ( $p=0.035$ ), DC (0.032), SGD=0.040) and SGD/TD ( $p=0.000$ ), while VD was close to the significance level ( $p=0.069$ ).

## Relationship between pelvic length and body length

The body length of the lynx included in this study and the ratio between the mean pelvis length and the mean body length are presented for all age/sex categories in Table 3. Although mean body length was slightly higher in males than females among subadults and adults, the available data did not allow robust testing of differences. The pelvic length was consistently around 19–20% that of the body length for all sex/age groups (no evidence of differences among groups).

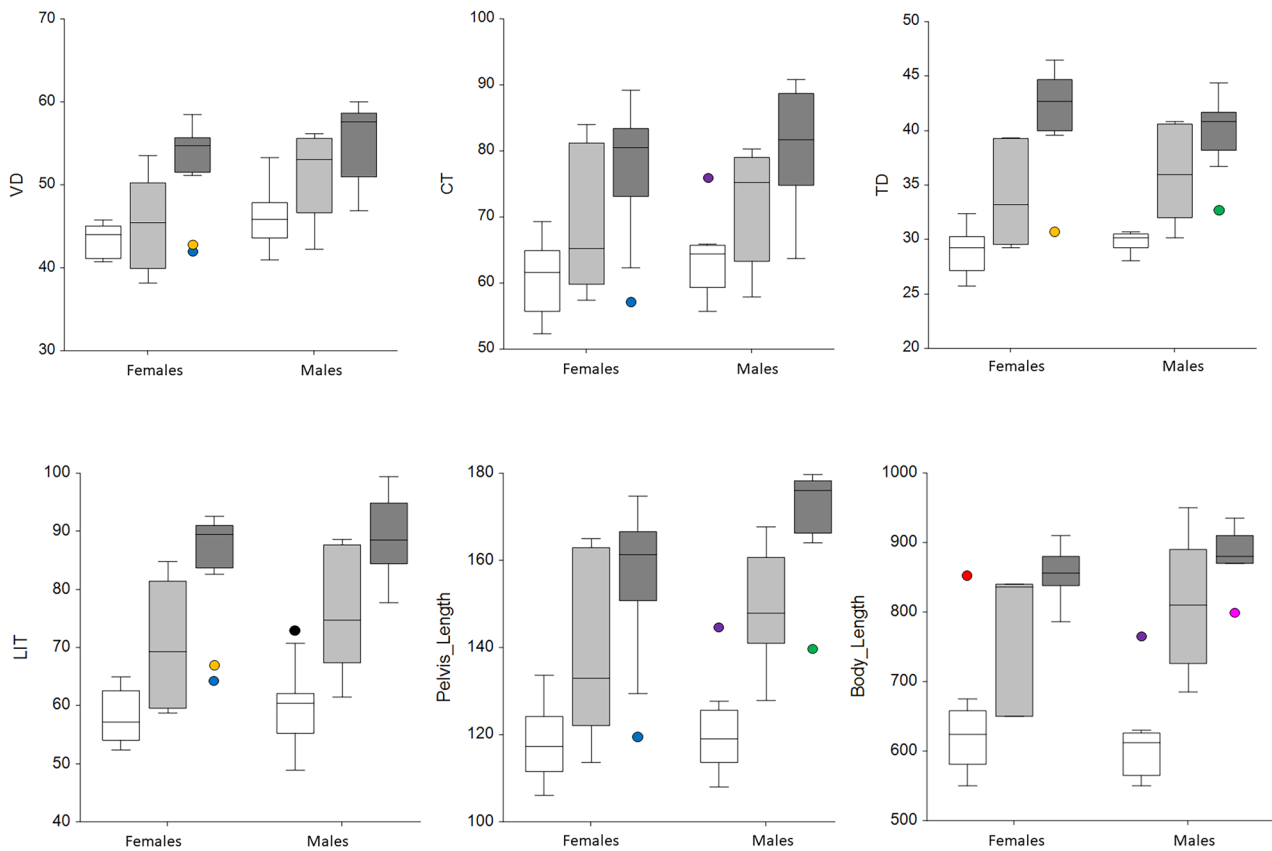
## Abnormal juvenile pelvis

Nine out of 13 measures of BEHTLI's pelvis (Table 4) were smaller than the minimum of the control specimens, including five longitudinal parameters (CV, VD, SGD, CT and AC), the pelvic ratio (SGD/TD), PIA and POA. Thus, although the small sample size of control animals does not allow excluding individual variation of pelvic parameters, measurements were congruent with the anomalies visible

on the prepared pelvis bone: The low CV and SGD values revealed a significant reduction of the pelvic height; the abnormal SGD/TD ratio indicated a modification of the pelvis proportions; and the abnormally low CT value reflected the rotation of the left hemipelvis towards the inside (online resource 1).

## Discussion

Our study is the first to provide pelvimetric measurements for the Eurasian lynx. Pelvimetry studies have been performed in a range of animal species but not in this wild felid. A comparison with data on Canada lynx (*L. canadensis*) and Iberian lynx *L. pardinus*; (García-Perea 1990; Gálvez Prada et al. 2013) was hampered by a range of factors: species measurements for these studies were taken on prepared bones and not on radiographs, these two lynx species are smaller in size than the Eurasian lynx (Breitenmoser and Breitenmoser-Würsten 2008), part of the parameters differed among studies, and data on *L. pardinus* were taken only on a single adult specimen of unknown sex (García-Perea 1990). Future studies in lynx may consider comparing radiological data with direct bone measurements. The latter can be performed post-mortem only but can be done on museum specimens, does not require radiographic equipment and is associated with lower costs, which may permit access to larger sample



**Fig. 3** Box plots of selected pelvic parameters and body length of free-ranging Eurasian lynx from Switzerland (*Lynx lynx carpathicus*): Longitudinal parameters (n=56) and body length (n=45) are indicated in millimeters. Age classes are shown in white for juveniles, light grey for subadults and dark grey for adults. The whiskers were drawn as the box edge ± 1.5 times the interquartile range, and the severe outlier boundary was set at box edge ± 3 times the interquartile range. Outliers were found for one height parameter (VD: verti-

cal diameter) and three width parameters (CT: horizontal distance between the coxal tuberosities; TD: the transversal diameter, LIT: horizontal distance between the lateral ischial tuberosities). The outliers are indicated as colored dots, each color referring to a specific individual, such as the adult females FREIA (orange) and ALMA (blue), the adult male JURO (green) and the juvenile male W09/1096 (purple)

sizes in more lynx populations. Unfortunately, this comparison was not possible in the framework of our study.

We compared our data with those from studies in domestic cats (Celimli et al. 2008; Monteiro et al. 2013)

and dogs (Eneroth et al. 1999; Ocal et al. 2003) since the applied methods were the same. Data on pelvimetry remain scarce even in domestic animals and especially in males, because studies mostly focus on the contribution of female

**Table 3** Mean pelvis length (PL), mean stretched body length (BL) and mean pelvis length/body length ratio (PL/BL), standard deviation and range (in parentheses) of 45 free-ranging Eurasian lynx (*Lynx lynx*) from Switzerland (1997–2015) for which both parameters were avail-

able. Differences between sexes were only tested among adults. A significant difference was found only for PL (Mann–Whitney–Wilcoxon test, p=0.011)

Parameter	Juveniles		Subadults		Adults	
	Male (n=9)	Female (n=12)	Male (n=6)	Female (n=3)	Male (n=7)	Female (n=8)
<b>PL (cm)</b>	12.13 ± 0.99 (10.80–14.47)	11.79 ± 0.80 (10.60–13.37)	14.91 ± 1.34 (12.78–16.77)	14.05 ± 2.17 (11.36–16.50)	17.03 ± 1.26 (13.97–17.97)	15.62 ± 1.64 (11.96–17.47)
<b>BL (cm)</b>	61.24 ± 6.45 (55.00–76.50)	63.29 ± 7.93 (55.00–85.20)	81.08 ± 9.69 (68.50–95.00)	77.53 ± 10.86 (65.00–84.00)	88.14 ± 4.25 (80.00–93.50)	85.56 ± 3.71 (78.60–93.00)
<b>PL/BL</b>	0.20 ± 0.01 (0.18–0.21)	0.19 ± 0.02 (0.15–0.22)	0.19 ± 0.02 (0.15–0.21)	0.19 ± 0.01 (0.19–0.20)	0.20 ± 0.01 (0.19–0.21)	0.19 ± 0.01 (0.17–0.20)

**Table 4** Measurements of an abnormal pelvis (juvenile female lynx BEHTLI, found in the Swiss Alps in 2006) and ranges (min.-max.) of the same parameters obtained for juveniles of comparable size with similar pelvic length (used as controls). The horizontal distance between the lateral ischial tuberosities (LIT) was not measurable on BEHTLI because the pelvis was incomplete on the available ventrodorsal radiographic projection

Pelvic measurements	BEHTLI	Range in controls (n = 8)
Linear distances (cm)		
PL	13.00	12.57 – 13.37
CV	4.14	4.52 – 5.31
DC	8.37	8.51 – 9.39
VD	4.32	4.17 – 4.83
SGD	3.76	5.74 – 6.32
FO	3.56	3.11 – 3.72
CT	5.37	5.74 – 6.93
TD	3.35	2.94 – 3.32
AC	2.30	2.58 – 3.20
Areas (cm <sup>2</sup> )		
PIA	44.06	45.28 – 54.63
POA	34.42	36.89 – 49.02
Ratios (height/width)		
SGD/TD	1.12	1.87 – 2.13
VD/AC	1.88	1.42 – 1.87

pelvic size to rearing performance (Cloete and Haughey 1990; Van Donkersgoed 1992; Eneroth et al. 1999). More recent studies were conducted on Turkish Van cats using three-dimensional computer tomography (Yilmaz et al. 2020; Yilmaz and Demircioğlu 2020). However, although measurements obtained by radiography should correspond to those obtained by computer tomography (Solayar et al. 2017) and the measured parameters were partly the same, sample size was low (n = 16 each) and species were different, preventing meaningful comparisons. Nevertheless, depending on their pelvis shape, animal species can be classified as dolico pelvic (long, vertically elongated pelvis with the anteroposterior diameter greater than the transverse diameter), platypellic (pelvis shortened in the anteroposterior aspect, with a flattened transverse, oval shape) or mesatipellic (round pelvis). In Eurasian lynx, the values of the pelvic height/width ratios (SGD/TD and VD/AC) were all above one and mostly close to two, pointing at an oval pelvis shape (dolico pelvic) for both sexes. This indicates that the lynx pelvis shape differs from that of domestic cats, which have a mesatipellic pelvis (Monteiro et al. 2013).

We did not find differences between the Alpine and Jura population in agreement with a former study that did not detect body size differences between these two populations (Marti and Ryser-Degiorgis 2018b).

Both pelvic areas and almost all linear pelvic measurements significantly increased with age, as expected from animals in growth and documented for other body measurements in Eurasian lynx (Marti and Ryser-Degiorgis 2018b). By contrast, the height/width ratios apparently decreased with age in females and only partly in males (Table 3), possibly because the pelvis of females increases more markedly in width than in length during the growth period. Similar observations were reported for domestic cats (Celimli et al. 2008).

Descriptive statistics (Table 3) did not suggest differences between sexes but this was not tested for juvenile lynx. Comparisons among lynx < 1 year would indeed be subject to errors due to rapid body growth and the resulting wide range of pelvic measurements in this age class. This dataset (11 males, 13 females) is expected to be particularly influenced by the sample size and possible uneven age distribution for each sex. Similarly, we decided not to test for sex differences for subadults due to low sample size (6 males, 5 females). Nevertheless, statistical differences between sexes in lynx during the growth period were unlikely as body size measurements do not differ between sexes before 9 months of age, and differences concern all body measurements only in lynx ≥ 1 year old (Marti and Ryser-Degiorgis 2018b).

In adult lynx, the pelvis length, CV, DC and SGD values were significantly larger in males, in agreement with observations in adult domestic cats (Celimli et al. 2008; Yilmaz and Demircioğlu 2020). Male lynx also had apparently larger mean PIA and POA but this was not supported by the statistical tests. Nevertheless, considering the generally larger body size of males, PIA and POA may be proportionally larger in female lynx. Mesaticephalic female domestic cats have significantly larger PIAs and POAs than males, and PIA and POA represent important parameters to describe the pelvic space for foetus passage in cat reproduction (Celimli et al. 2008; Monteiro et al. 2013). Sex-related body size difference is likely less marked in domestic cats than in Eurasian lynx, potentially explaining the lack of significant difference between pelvis parameters of male and female lynx. Similarly, two parameters reflecting the pelvic width (TD and AC) showed higher mean values in female than male lynx but without statistical differences. Considering that, independently of the body size, a female pelvis is smaller than the pelvis of males, the larger values in females are likely relevant. The significantly larger SGD/TD ratio in males confirmed that adult lynx females have a different pelvic shape than adult males, obviously to fulfil the physiological requirements of parturition. Thus, all these values need to be considered in case of rectal obstipation or dystocia in lynx.

Sexual dimorphism of the pelvic bone has been described in humans, non-human primates (Leutenegger and Larson 1985), retriever dogs (Nganvongpanit et al. 2017), rabbits



(Özkadif et al. 2014) and domestic cats (Monteiro et al. 2013; Yilmaz et al. 2020; Yilmaz and Demircioğlu 2020), whereas it is not present in the German shepherd dog (Ocal et al. 2003). This dimorphism can be characterized by a difference in pelvic size and/or pelvic conformation, and if these differences are marked, they can contribute to the sex determination of an individual (Gonzalez et al. 2009; Nganvongpanit et al. 2017). In Eurasian lynx, Canada lynx and domestic cat (García-Perea 1990; Celimli et al. 2008; Monteiro et al. 2013), sexual dimorphism of the pelvis is characterized by a larger pelvic size in males, in agreement with their larger body size (García-Perea 1990; Pontier et al. 1998; Yom-Tov et al. 2010), and by a different pelvic conformation, the pelvis of females being wider.

Outliers which may hint at abnormal morphological features were detected in five individuals. Within the juvenile age class, a 10–11 months old male had the largest values for two pelvic linear measurements (one width parameter and pelvic length) and for body length. These measurements were within the value range of subadults. The exact birth date of this lynx was unknown, but considering that lynx are born in May–June (Breitenmoser and Breitenmoser-Würsten 2008) and that this individual with only 12 kg body weight was found dead on March 20<sup>th</sup>, a wrong classification as a juvenile is very unlikely (Marti and Ryser-Degiorgis 2018a, b). Therefore, this lynx probably did not have an abnormal pelvis but rather already showed morphological characteristics of a subadult specimen, which is not surprising as he would have been classified as a subadult 1–2 months later. Similarly, a juvenile female had a larger body size compared to the other individuals of this study and a juvenile male had a slightly larger LIT value. These findings may reflect inter-individual variations in growth rates, as already discussed for other body measurements in this species (Marti and Ryser-Degiorgis 2018b). Juvenile lynx grow rapidly (Marti and Ryser-Degiorgis 2018b) and since our juvenile class included animals from 4 to 11 months old, it was particularly heterogenous. The box plot height in subadults illustrated even better the large variation in the datasets of young lynx, certainly due not only to growth-related data heterogeneity but also to limited sample size. Among adults, i.e. lynx in the post-growth period (Marti and Ryser-Degiorgis 2018b), apparently abnormal values may reflect morphological anomalies of the pelvis or be related to individual variations. Male Eurasian lynx > 1 year old are expected to be larger in size than females (Yom-Tov et al. 2010; Marti and Ryser-Degiorgis 2018b). For the three lynx with extreme body length values, we also need to consider the possibility of occasional measurement errors. Indeed, while pelvis measurements were taken within a short time period by the same person (first author) and repeated twice, body length was measured only once, at necropsy, by multiple collaborators over many years. Although all involved people

were instructed and trained to work according to the same standardized protocols (Marti and Ryser-Degiorgis 2018b; Ryser-Degiorgis et al. 2021), occasional errors cannot be excluded. Overall, the data suggest that two adult females (ALMA and FREIA) and an adult male (JURO) may have had a pelvis with abnormal morphological features. Since all linear parameters and the surface areas were small in JURO but the ratios were within the range of other adult males, JURO may simply have had a smaller pelvis. No body size data were available for this lynx and it may just have been a small individual. The extremely low values for VD (height), CT, LIT and TD (width) in the females suggest an abnormal pelvis morphology, which may have impacted parturition. However, ALMA and FREIA also had the lowest values of all adult females for the pelvic length, VD, SGD, AC, LIT and the two areas PIA and POA, suggesting that similarly to JURO, they may have been rather small individuals. Nevertheless, with 19 kg FREIA had a body weight above the mean for adult females (Marti and Ryser-Degiorgis 2018b). Since she had a particularly low TD value and this parameter corresponds to the narrowest part of the pelvis (Fig. 2), she may have encountered problems when giving birth. However, we know from field data that these two radio-marked females reproduced after the radiological examination was performed. Thus, the clinical relevance of the documented values in these adult lynx is questionable.

BEHTLI's data indicated a pathological reduction of the pelvic canal. This supports the hypothesis that this malformation may have predisposed to tenesmus and finally rectal perforation due to a foreign body in the faeces. Besides the two orphans in a rehabilitation centre, we may have identified an additional lynx from the Alps with an abnormal pelvis (FREIA) but without impact on her health or reproductive performance. In our study, these animals represent exceptions but given the relatively high proportion of specimens which could not be measured (38% missing data), the occurrence of more lynx with malformations cannot be excluded. Furthermore, lynx with a malformed pelvis are more likely to die of obstipation, peritonitis or dystocia early in life and may not be found. Carcasses of lynx which are not fitted with a radio-collar and die of non-anthropogenic causes are indeed less likely to be discovered (Schmidt-Posthaus et al. 2002).

A major weakness of this study was the limited sample size, which was suboptimal to assess age, sex and population differences together, despite collecting material over a period of 11 years. Yet, sample size was higher or equivalent to other published studies in wild and domestic carnivores (García-Perea 1990; Celimli et al. 2008; Monteiro et al. 2013; Yilmaz et al. 2020; Yilmaz and Demircioğlu 2020). Limited sample size is a typical problem of studies conducted on small populations of protected wildlife (Ryser-Degiorgis 2013). When considering the current lynx

population size in Switzerland at the time of the study (less than 200 animals  $\geq 1$  year old in 2015), 56 lynx including 32 individuals  $\geq 1$  year old corresponds to approximately 16% of the population, which is considerable. Radiographic material was originally obtained from 100 lynx but unfortunately a significant proportion of images from carcasses could not be used as they were traffic-killed animals with bone fractures. Traffic accidents are a common cause of death in Eurasian lynx (Schmidt-Posthaus et al. 2002; Ryser-Degiorgis 2009) and this problem is unavoidable. Other exclusion criteria concerned only a few individuals.

From a technical point of view, a minimum of two orthogonal projections, including a latero-lateral and a ventro-dorsal projection, are required for pelvimetric analyses. Considering the infrastructure, costs and efforts necessary for radiology and pelvimetry, long-term routine examinations may not be feasible in practice but these investigations should be considered at least for animals with a health disorder possibly related to pelvis conformation to compare their measurements with the data presented here, as exemplified by the case of BEHTLI. Furthermore, these data could be useful for estimating age and sex in skeletal remains. Nevertheless, caution is warranted as concerns comparison. Indeed, since phenotype characteristics vary among Eurasian lynx subspecies (Breitenmoser and Breitenmoser-Würsten 2008; Gomerčić et al. 2010; Schmidt et al. 2011; Kubala et al. 2019), the values presented in this article may only be pertinent to Carpathian lynx. Furthermore, the limited sample size likely underestimated the data range of the three age classes and two sexes.

In conclusion, this study delivered baseline morphology data revealing that the Eurasian lynx is a dolicoepellic species with sexual dimorphism of the adult pelvis bone, and that pelvis malformations are apparently uncommon among free-ranging lynx in Switzerland. In the juvenile lynx with a pelvis malformation detected at post-mortem examination, pelvimetry represented an objective tool that allowed to quantify the anomaly. Thus, radiographic examinations of the pelvis have proven to be a useful component of the long-term health monitoring of lynx.

**Supplementary Information** The online version contains supplementary material available at <https://doi.org/10.1007/s10344-022-01595-6>.

**Acknowledgements** Many thanks go to the hunting authorities, game wardens and biologists of the KORA who organized capture attempts, contributed to data collection in live lynx, submitted lynx carcasses for post-mortem examination and provided information on reproduction success of adult females. The collaborators of the FIWI and of the Department of Clinical Radiology from the Small Animal Clinic are also acknowledged for their contributions to lynx pathological and radiographic examinations, respectively.

**Authors contributions** MPRD and JL designed and supervised the study; FM collected and analysed the pelvimetry data; BV supervised

and carried out the statistical analyses; MPRD and BV prepared the figures; FM, MPRD and BV drafted the manuscript. All authors contributed to and approved the final manuscript.

**Funding** Open access funding provided by University of Bern. No specific funding was available for this study. Lynx were collected and analysed post-mortem in the framework of the national wildlife health surveillance programme carried out at the University of Bern on mandate and with financial support of the Federal Office of Environment and Federal Food Safety and Veterinary Office. The pelvimetry study was part of FM's master thesis.

## Declarations

**Ethics approval** None of the animals concerned by this study was killed for research purposes. All of the samples originated either from free-ranging wildlife found dead in the field or from live animals captured within the framework of conservation actions. Collection and sampling of all animals respected Switzerland's legislation (922.0 hunting law; and 455 animal protection law, including legislation on animal experimentation; [www.admin.ch](http://www.admin.ch)). Anesthesia, handling and examination of live lynx were carried out by experienced veterinarians after obtaining all required permits for capturing and handling lynx (for details see Vogt et al. 2014; Ryser-Degiorgis et al. 2021).

**Conflicts of interest** The authors declare that they have no conflicts of interest.

**Open Access** This article is licensed under a Creative Commons Attribution 4.0 International License, which permits use, sharing, adaptation, distribution and reproduction in any medium or format, as long as you give appropriate credit to the original author(s) and the source, provide a link to the Creative Commons licence, and indicate if changes were made. The images or other third party material in this article are included in the article's Creative Commons licence, unless indicated otherwise in a credit line to the material. If material is not included in the article's Creative Commons licence and your intended use is not permitted by statutory regulation or exceeds the permitted use, you will need to obtain permission directly from the copyright holder. To view a copy of this licence, visit <http://creativecommons.org/licenses/by/4.0/>.

## References

- Batista-Arteaga M, Santana M, Lozano O et al (2011) Medical and surgical management of a dystocia because of foetopelvic disproportion in an African lioness (*Panthera leo*). *Reprod Domest Anim Zuchthyg* 46:362–365. <https://doi.org/10.1111/j.1439-0531.2010.01630.x>
- Breitenmoser U, Breitenmoser-Würsten C (2008) Der Luchs - ein Grossraubtier in der Kulturlandschaft. Salm Verlag, Wohlen/Bern, Switzerland
- Breitenmoser-Würsten C, Obexer-Ruf G (2003) Population and conservation genetics of two reintroduced lynx (*Lynx lynx*) populations in Switzerland – a molecular evaluation 30 years after translocation. *Environ Encount* 58:51–55
- Celimli N, Seyrek Intas D, Yilmazbas G et al (2008) Radiographic pelvimetry and evaluation of radiographic findings of the pelvis in cats with dystocia. *Tierärztl Prax Kleintiere* 4:277–284
- Chapron G, Kaczensky P, Linnell JDC et al (2014) Recovery of large carnivores in Europe's modern human-dominated landscapes. *Science* 346:1517–1519. <https://doi.org/10.1126/science.1257553>

- Cloete SW, Haughey KG (1990) Radiographic pelvimetry for the estimation of pelvic dimensions in Merino, Dormer and S A mutton Merino ewes. *J S Afr Vet Assoc* 61:55–58
- Eneroth A, Linde-Forsberg C, Uhlhorn M, Hall M (1999) Radiographic pelvimetry for assessment of dystocia in bitches: a clinical study in two terrier breeds. *J Small Anim Pract* 40:257–264
- Gálvez Prada F, Serrano León JP, Sañudo Franquelo B, Beltrán Gala JF (2013) Digital atlas of the skeleton of *Lynx pardinus*. *BioScripts & Universidad de Sevilla*, Sevilla, Spain
- García-Perea R (1990) Variabilidad morfológica del género *Lynx* Kerr, 1792 (Carnivora: Felidae). *Universidad Complutense de Madrid*
- GIMP (2019) The GIMP Development Team, 2019, <https://www.gimp.org>
- Gomerčić T, Sindičić M, Đuras Gomerčić M et al (2010) Cranial morphology of the Eurasian lynx (*Lynx lynx* L.) from Croatia. *Vet Arh* 80:393–410
- Gonzalez PN, Bernal V, Perez SI (2009) Geometric morphometric approach to sex estimation of human pelvis. *Forensic Sci Int* 189:68–74. <https://doi.org/10.1016/j.forsciint.2009.04.012>
- Krojerová-Prokešová J, Turbaková B, Jelenčič M et al (2019) Genetic constraints of population expansion of the Carpathian lynx at the western edge of its native distribution range in Central Europe. *Heredity* 122:785–799. <https://doi.org/10.1038/s41437-018-0167-x>
- Kubala J, Gregorová E, Smolko P et al (2019) The coat pattern in the Carpathian population of Eurasian lynx has changed: a sign of demographic bottleneck and limited connectivity. *Eur J Wildl Res* 66:2. <https://doi.org/10.1007/s10344-019-1338-7>
- Leutenegger W, Larson S (1985) Sexual dimorphism in the postcranial skeleton of New World primates. *Folia Primatol Int J Primatol* 44:82–95
- Linde-Forsberg C (2002) Pelvimetry to diagnose dystocia in the bitch. In: *Proceedings of the 27th World Small Animal Veterinary Association World Congress*. Granada, Spain, p 591
- Malik MR, Crao K, Taluja JS, Shrivastava AM (1990) Length and girth as an index to surface pelvimetry in buffalo. *Indian J Anim Sci* 60:1200–1202
- Marti I, Ryser-Degiorgis M-P (2018a) A tooth wear scoring scheme for age estimation of the Eurasian lynx (*Lynx lynx*) under field conditions. *Eur J Wildl Res* 64:37. <https://doi.org/10.1007/s10344-018-1198-6>
- Marti I, Ryser-Degiorgis M-P (2018b) Morphometric characteristics of free-ranging Eurasian lynx *Lynx lynx* in Switzerland and their suitability for age estimation. *Wildl Biol* 2018b:wlb.00432. <https://doi.org/10.2981/wlb.00432>
- Monteiro CLB, Campos AIM, Madeira VLH et al (2013) Pelvic differences between brachycephalic and mesaticephalic cats and indirect pelvimetry assessment. *Vet Rec* 172:16. <https://doi.org/10.1136/vr.100859>
- NCSS (2015) NCSS 10 Statistical Software, 2015; NCSS, LLC; Kay-ville, Utah, USA, <https://www.ncss.com/software/ncss>
- Nganvongpanit K, Pitakarnnop T, Buddhachat K, Phatsara M (2017) Gender-related differences in pelvic morphometrics of the Retriever dog breed. *Anat Histol Embryol* 46:51–57. <https://doi.org/10.1111/ah.12232>
- Ocal MK, Dabanoglu I, Kara ME, Turan E (2003) Computed tomographic pelvimetry in German shepherd dogs. *DTW Dtsch Tierarztl Wochenschr* 110:17–20
- Özkadif S, Eken E, Kalaycı I (2014) A three-dimensional reconstructive study of pelvic cavity in the New Zealand rabbit (*Oryctolagus cuniculus*). *ScientificWorldJournal* 2014:489854. <https://doi.org/10.1155/2014/489854>
- Pontier D, Fromont E, Courchamp F et al (1998) Retroviruses and sexual size dimorphism in domestic cats (*Felis catus* L.). *Proc Biol Sci* 265:167–173. <https://doi.org/10.1098/rspb.1998.0278>
- Ryser-Degiorgis M-P (2013) Wildlife health investigations: needs, challenges and recommendations. *BMC Vet Res* 9:223. <https://doi.org/10.1186/1746-6148-9-223>
- Ryser-Degiorgis M-P (2009) Causes of mortality and diseases of Eurasian lynx (*Lynx lynx*). In: *Iberian lynx ex situ conservation: an interdisciplinary approach*. Vargas A., Breitenmoser C., Breitenmoser B. (eds). *Fundación Biodiversidad / IUCN Cat Specialist Group*, pp 488–497
- Ryser-Degiorgis M-P, Breitenmoser-Würsten C, Meli M, Breitenmoser U (2013) Health surveillance as an important tool in wildlife conservation: experiences with the Eurasian lynx. In: *Proceedings of the 62th International Conference of the Wildlife Disease Association*. Knoxville, Tennessee, USA, p Abstract 46
- Ryser-Degiorgis M-P, Meli ML, Breitenmoser C et al (2021) Health surveillance as an important tool in wild felid conservation: experiences with the Eurasian lynx in Switzerland. *Cat News Special Issue* 14:64–75
- Ryser-Degiorgis M-P, Robert N, Meier RK et al (2020) Cardiomyopathy associated with coronary arteriosclerosis in free-ranging Eurasian lynx (*Lynx lynx* carpathicus). *Front Vet Sci*. <https://doi.org/10.3389/fvets.2020.594952>
- Ryser-Degiorgis M-P, Ryser A, Obexer-Ruff G et al (2004) Emergence of congenital malformations in free-ranging Lynx from Switzerland: first evidence of inbreeding depression. In: *Proceedings of the scientific meeting of the European Association of Zoo- and Wildlife Veterinarians (EAZWV)*, Ebeltoft, Denmark, 2004, May 19–23. Eds: A.H.M. Erken, G.M. Dorrestein, p. 19–23
- Ryser-Degiorgis M-P, Segner H (2015) National competence center for wildlife diseases in Switzerland: Mandate, development and current strategies. *Schweiz Arch Tierheilkd* 157:255–266. <https://doi.org/10.17236/sat00019>
- Schmidt K, Ratkiewicz M, Konopiński MK (2011) The importance of genetic variability and population differentiation in the Eurasian lynx *Lynx lynx* for conservation, in the context of habitat and climate change. *Mammal Rev* 41:112–124. <https://doi.org/10.1111/j.1365-2907.2010.00180.x>
- Schmidt-Posthaus H, Breitenmoser-Würsten C, Posthaus H et al (2002) Causes of mortality in reintroduced Eurasian lynx in Switzerland. *J Wildl Dis* 38:84–92. <https://doi.org/10.7589/0090-3558-38.1.84>
- Schrader SC (1992) Pelvic osteotomy as a treatment for obstipation in cats with acquired stenosis of the pelvic canal: six cases (1978–1989). *J Am Vet Med Assoc* 200:208–213
- Solayar GN, Chinappa J, Harris IA et al (2017) A comparison of plain radiography with computer tomography in determining coronal and sagittal alignments following total knee arthroplasty. *Malays Orthop J* 11:45–52. <https://doi.org/10.5704/MOJ.1707.006>
- Van Donkersgoed J (1992) A critical analysis of pelvic measurements and dystocia in beef heifers. *Compend Contin Educ Pract Vet* 14:405–407
- Vogt K, Zimmermann F, Kölliker M, Breitenmoser U (2014) Scent-marking behaviour and social dynamics in a wild population of Eurasian lynx *Lynx lynx*. *Behav Processes* 106:98–106. <https://doi.org/10.1016/j.beproc.2014.04.017>
- Yilmaz O, Demircioğlu İ (2020) Computed tomography-based morphometric analysis of the hip bones (Ossa coxae) in Turkish Van Cats. *Kafkas Üniversitesi Vet Fakültesi Derg.* <https://doi.org/10.9775/kvfd.2020.24449>
- Yilmaz O, Soyguder Z, Yavuz A, Dundar I (2020) Three-dimensional computed tomographic examination of pelvic cavity in Van Cats and its morphometric investigation. *Anat Histol Embryol* 49:60–66. <https://doi.org/10.1111/ah.12484>
- Yom-Tov Y, Kjellander P, Yom-Tov S et al (2010) Body size in the Eurasian lynx in Sweden: dependence on prey availability. *Polar Biol* 33:505–513. <https://doi.org/10.1007/s00300-009-0728-9>