

Central neuromuscular dysfunction of the deltoid muscle in patients with chronic rotator cuff tears

Alexander Berth · Géza Pap · Wolfram Neuman ·
Friedemann Awiszus

Received: 18 June 2009 / Accepted: 15 July 2009 / Published online: 19 August 2009
© Springer-Verlag 2009

Abstract

Background Previous surface electromyogram (EMG) studies have shown that chronic rotator cuff tears (RCT) may be associated with an altered activation of adjacent shoulder muscles. The effect of RCT on central neuromuscular control mechanisms of the shoulder girdle muscles such as the deltoideus muscle (DM), a key muscle of shoulder function, has as not yet been studied in detail.

Materials and methods This study investigated the corticospinal excitability of the DM to assess the effects of RCT on the central neuromuscular function of proximal upper limb muscles. The motor-evoked potentials (MEP) in response to transcranial magnetic stimulation of DM on both sides were obtained from patients with unilateral RCT and compared with healthy control subjects.

Results In patients, stimulus response curves of DM demonstrated a bilateral hyperexcitability at rest and a hypoexcitability during voluntary activation ($F = 3.82$, $P = 0.007$).

Conclusions The DM hyperexcitability may be related to alterations in the sensory output from the shoulder. The insufficient facilitation of the DM points toward a bilateral central activation deficit. These findings seem to be

assigned to adaptive changes in the motor cortex as a consequence of chronic RCT, and the neuromuscular alteration of the DM should be considered when treating patients with RCT.

Keywords Shoulder · Rotator cuff tear · Deltoideus muscle · Transcranial magnetic stimulation

Introduction

The rotator cuff plays an important role in stabilization and control of the complex course of motion of the glenohumeral joint (GHJ) [1]. Lesions of the rotator cuff are a common source of pain, impairment, and disability of the shoulder, especially in people aged 60 years and older [2, 3]. The prognosis and therapy of a full-thickness rotator cuff tear (RCT) depends on the location, size, and genesis of the lesion [4–6]. However, many patients with RCT have no discomfort due to the lesion [7]. The influence of the superficial shoulder-muscle activity, especially of the deltoid muscle (DM), on the kinematic of the GHJ and the presence or absence of symptoms remains unclear. Previous electromyography (EMG) studies have shown that the shoulder-muscle activity is altered in patients with RCT [8, 9]. This points toward impaired neuromuscular control mechanisms of the surrounding shoulder muscles. However, the definitive origin of these neuromuscular deficits remains to be investigated. In particular, the central changes of neuromuscular control mechanisms contributing to the functional alteration associated with chronic RCT has as yet not been studied in detail.

Transcranial magnetic stimulation (TMS) is a noninvasive technique to investigate the human motor cortex. It has been used to assess excitability, representation, and

A. Berth · W. Neuman · F. Awiszus
Department of Orthopaedics, Otto-von-Guericke-University,
39120 Magdeburg, Germany

G. Pap
Centre of Orthopaedics and Traumatology, Park-Hospital
Leipzig, 04289 Leipzig, Germany

A. Berth (✉)
Orthopädische Universitätsklinik, Universitätsklinikum A. ö. R.,
Leipziger Street 44, 39120 Magdeburg, Germany
e-mail: alexander.berth@med.ovgu.de

function of the motor system [10]. Therefore, the purpose of this study was to investigate with TMS the neuromuscular alterations of DM in patients with a unilateral chronic RCT and in subjects without any shoulder pathologies in order to provide a better understanding of adaptive changes in the motor cortex after chronic RCT.

Materials and methods

Patients

Ten right-handed men with chronic, symptomatic, full-thickness RCT (six on the right side, four on the left side) were selected for this study. Full RCT was diagnosed preoperatively with magnetic resonance imaging. None of these patients reported discomfort in the shoulder on the contralateral side. The nonaffected shoulder was examined clinically and showed no signs of an RCT. Additionally, the investigation by ultrasound showed moderate signs of tendon degeneration but no full-thickness RCT. Radiographs in the anteroposterior, axial, and scapular views on the affected side were performed to exclude considerable osteoarthritis of the shoulder. All patients had symptoms for more than 6 months before surgery and underwent a course of conservative treatment, including anti-inflammatory medication and home-based physical therapy. At time of surgery, subjects ranged in age from 55 to 71 years [mean 64.9 years; standard deviation (SD) \pm 4.6 years]. No other significant neuromuscular or skeletal pathologies were present. All patients underwent an open rotator cuff repair after an antecedent diagnostic arthroscopy. On the basis of the arthroscopic findings, the tear configuration was analyzed and other shoulder pathologies were excluded. During the open rotator cuff repair, the tear size was measured in both the anteroposterior and the mediolateral dimension.

Control group

Thirteen healthy volunteers (ten men, three women) ranging in age from 20 to 48 (mean 27.2; SD \pm 8.1) years served as the control group. These subjects had no shoulder pain, previous shoulder injuries, or neurologic deficits. Both shoulders were examined clinically and radiologically by ultrasound, which showed no signs of considerable tendon degeneration or other pathologies (e.g., bursitis subacromialis).

Clinical assessment

Subjects were assessed using the Constant score [11], nonadjusted with respect to age, and the Disabilities of the

Arm, Shoulder, and Hand (DASH) score [12]. In addition, the Waterloo Handedness Questionnaire (WHQ) [13] was used to quantify handedness. The WHQ comprises 36 questions, which ask individuals to indicate their preferred hand for a variety of unimanual tasks. A total composite score was calculated for the subject by summing all items. Right-handers would be expected to have positive scores on the questionnaire, whereas left-handers were expected to have negative scores.

Transcranial magnetic stimulation

TMS is a noninvasive technique to investigate the human motor cortex. The first successful TMS study was performed in 1985 by Barker et al. [14] and based on Faraday's principles of electromagnetic induction. For magnetic stimulation of the human brain, a brief, high-current pulse is produced with a magnetic coil, which is placed above the scalp. A pulse of current flowing through the magnetic coil generates a magnetic field passing nearly unattenuated through the scalp, which in turn induces an electrical field within cortical tissue. Stimulation-induced neuronal activity subsequently generates a response in the target muscle corresponding to the activated motor cortex areal. These motor- (or magnetic)-evoked potentials (MEP) can be recorded by surface electrodes applied over the target muscle.

In this study, a high-power Magstim 200 stimulator and a Magstim figure-of-eight coil (PN 9925, Magstim Co., Whitland, Wales, UK) was used to apply monophasic TMS. The coil was oriented so that the induced current had a posterior–anterior direction (the handle pointing backward). The coil was held tangentially to the skull and positioned at 45° in relation to the nasion-inion line. According to the study of Tyc et al. [15], the junction of the coil was placed over the maximal peak location of the elicited MEP (the so-called “hot spot”) of the DM, which is located about 2 cm in front and 3 cm left (right) of the vertex. Coil movement during the recording sessions was minimized by drawing a line on the skull that marked the optimal position of the coil. The stimulator had a remote-control interface, allowing control of the stimulus timing and strength by a laboratory computer (Fig. 1).

Experimental protocol

Subjects lay in the supine position and were instructed to maintain a constant active relaxation as complete as possible. TMS trials that were contaminated by voluntary activation in either muscle were excluded from further analysis (except stimulus–response experiments during low-level muscular activity of the DM). The order of

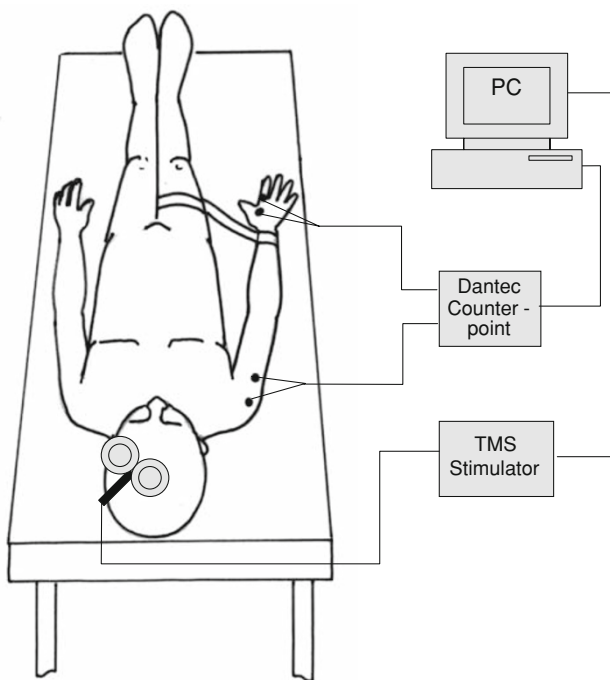


Fig. 1 Experimental setup of the study (investigation of the right side). The motor-evoked potentials (MEP) of the deltoid muscle (DM) and first dorsal interosseus muscle (FDI) were recorded after transcranial magnetic stimulation (TMS) over the scalp during rest and slight voluntary activation of the DM. Voluntary effort of the DM was exerted with a constant abduction of the arm against resistance (strap) at an angle of 40°

investigation of the affected and nonaffected side of the patients and of the left or right side in the control group was randomized and counterbalanced between subjects. The experimental procedure was started by estimating the resting motor threshold (RMT) of the first dorsal interosseus muscle (FDI) by using the maximum likelihood procedure with 15 stimuli [16]. The RMT is the basic unit of TMS dosing and provides a noninvasive global index of cortical excitability of a target muscle. Determining the correct RMT is important for determining the proper TMS dose for each subject and is also important with respect to safety. The RMT is then defined as the TMS stimulus strength at which the response (the elicited MEP) probability equals 0.5. The RMT determination of FDI was used for a proper modulation of stimulus intensities in the following stimulus–response experiments of the DM, because the muscle responses to corticospinal inputs generated by TMS in proximal muscles are generally more difficult to elicit than in distal muscles [17]. Furthermore, FDI and DM have overlapping central muscle representations, suggesting coordination in control of these muscles [18]. After threshold determination, the stimulus–response experiment was conducted to evaluate the MEP of the medial division of the DM of the affected and the

nonaffected side of the patients and both sides in control subjects after TMS of the motor cortex on both hemispheres.

The relationship between the increased magnetic stimulus intensity and rise in the evoked MEP can be distinguished in stimulus response curves, or input–output (I/O) curves. The progression of the I/O curves offers information about the corticospinal excitability of a given motor representation [19–21]. These I/O curves can be estimated under resting condition as well as under a well-defined voluntary activation of the target muscle (the so-called “facilitation”). This facilitation leads under physiological conditions to an increased neuronal (corticospinal) excitability and thus to a clear increase of the MEP amplitude and shortening of the MEP latency by a central stimulation [22].

The subjects and patients received five single stimuli at five different stimulus levels. The magnetic stimulus intensity at each stimulus level [expressed in percentage of the maximum stimulator output (% MSO)] increased from the threshold value in 5% steps up to 20% above the estimated threshold value. The order of application of these 25 stimuli and the interstimulus interval (distributed between 9 and 11 s) was randomized by the laboratory computer. The median of the five MEPs at each of the five different stimulus levels, which were measured from peak to peak, were calculated and stored for analysis. The stimulus–response experiments for DM were done during rest and low-level muscular activity of the DM (about 5–10% of the maximal voluntary contraction) in slight voluntary abduction of the shoulder against resistance. The patients were examined 1 day prior to surgery.

All subjects gave their written informed consent to the TMS investigation. The study was performed in accordance with the ethical standards of the 1964 Declaration of Helsinki and was approved by the ethical committee of our institution. The experimental setup was identical for patients and control subjects.

EMG recordings

Conventional silver/silver chloride electrodes (3 M Red Dot) were used to record the surface EMG activity of DM and FDI. For both muscles, the recording electrode was mounted on the muscle belly, whereas the reference electrode was placed on a bony landmark close to target muscle (deltoid tuberosity of the humerus for DM, proximal phalanx of index finger for FDI). The surface EMG signal was amplified by a conventional EMG (Counterpoint, Dantec, Skovlunde, Denmark) with a bandpass filter (20 Hz–5 kHz). The amplified signal was digitized by a laboratory computer with an analog–digital (AD) conversion card at a sampling rate of 25 kHz per channel.

Statistical analysis

Analysis of variance for repeated measures was performed to compare the excitability of DM on the affected and nonaffected side of the patients and on both sides in control subjects. The intersubject factors were stimulus strength (five levels), task (rest, activity of DM), and side (affected, nonaffected, or left, right, respectively). The intersubject factor was status (patients, control subjects). A significance level <0.05 was assumed. We used SPSS statistical software, version 12.0, for Windows, for all calculations. Unless specified otherwise, results are given as mean \pm SD.

Results

Clinical assessment

Patients

Before surgery, patient Constant score ranged from 18 to 50 (mean 32.8, SD \pm 11.5) points, the WHQ score from 22 to 69 (mean 47.2, SD \pm 17.2) points, and the DASH score from 19.1 to 50.8 (mean 39.4, SD \pm 12.6) points. The intraoperative evaluation of location and size of the RCT showed that in all subjects the RCTs were located in the supraspinatus and/or infraspinatus tendon, and the size of the defect ranged from 4 to 9 cm² (mean 6.3 cm²; SD \pm 2.7 cm²).

Table 1 Mean motor-evoked potential (MEP) amplitudes of the deltoid muscle (DM) of the affected and nonaffected sides of patients and the right and left sides in healthy controls during rest (Session 1) and low-level muscular activity of the DM in slight voluntary

Control subjects

The Constant score of normal subjects ranged from 86 to 100 (mean 94, SD \pm 4.3) points, the WHQ score from 32 to 60 (mean 49.3, SD \pm 9.4) points, and the DASH score was 0 points in all subjects.

Stimulus-response experiments

The results of measurement of stimulus-response experiments of the DM on both sides in patients and controls are summarized in Table 1.

With regard to the stimulus-response experiments for the DM, we could not detect a main effect of side in control subjects or in the patient group ($F = 0.086$, $p = 0.773$). A significant three-way interaction was found between TMS stimulus intensity, task, and status for MEP of the DM ($F = 3.829$, $p = 0.007$), which indicated that the patients' DM had a different behavior than the DM in controls. Figure 2a shows the I/O curves of the DM in patients (filled circles) and control subjects (open circles) at rest. The MEP of the DM in both groups were averaged due to the nonsignificant side by status interaction. The I/O curves demonstrated an increased corticospinal excitability of the DM in the patient group when compared with the normal subjects at rest. In contrast, the MEP of DM in patients and control subjects during slightly voluntary activation of the DM has an opposite behavior (see Fig. 2b). The observed stimulus-response curve shows a decreased corticospinal excitability of the DM in patients when compared with

abduction of the shoulder against resistance (Session 2) after transcranial magnetic stimulation (TMS) at four different stimuli levels [resting motor threshold (RMT), RMT + increasing magnetic stimulus intensities given in percentage of stimulator output

	DM controls		DM patients	
	Affected (μ V)	Nonaffected (μ V)	Left (μ V)	Right (μ V)
Session 1				
RMT	10.2 \pm 1.6	11.3 \pm 2.9	22.4 \pm 21.4	32.5 \pm 35.5
RMT + 5%	10.1 \pm 2.2	11.7 \pm 3.1	24.8 \pm 24.6	43.0 \pm 35.5
RMT + 10%	25.7 \pm 34.0	23.3 \pm 22.7	40.6 \pm 45.9	79.7 \pm 62.9
RMT + 15%	54.0 \pm 83.9	49.6 \pm 67.1	68.7 \pm 59.7	116.0 \pm 97.7
RMT + 20%	89.8 \pm 124.8	78.9 \pm 113.2	87.9 \pm 79.4	143.0 \pm 85.9
Session 2				
RMT	355.7 \pm 303.1	308.7 \pm 220.2	212.6 \pm 98.8	341.3 \pm 171.8
RMT + 5%	562.9 \pm 553.1	557.2 \pm 783.6	256.9 \pm 132.8	416.4 \pm 290.0
RMT + 10%	632.6 \pm 517.6	728.7 \pm 702.4	286.7 \pm 168.6	554.5 \pm 375.5
RMT + 15%	910.6 \pm 715.0	1,166.4 \pm 1,109.1	468.2 \pm 334.4	709.9 \pm 501.1
RMT + 20%	1,089.2 \pm 747.0	1,356.5 \pm 1,174.9	704.9 \pm 747.6	779.8 \pm 534.5

Data are given as mean \pm standard deviation

μ V microvolt

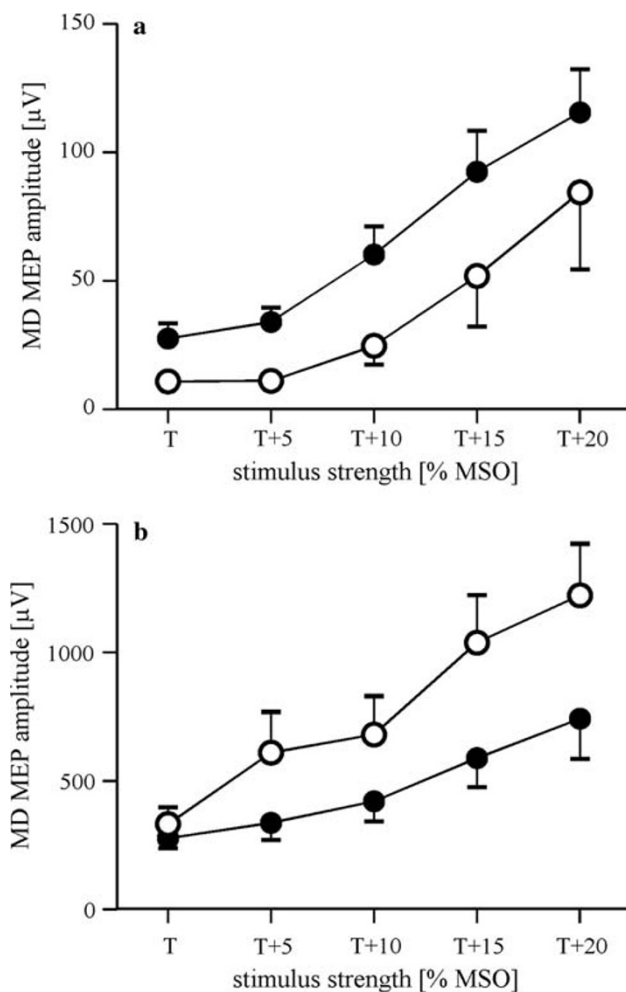


Fig. 2 Motor-evoked potential (MEP) recruitment curves of the deltoideus muscle (DM), both sides averaged, at rest (**a**) and low-level muscular activity of the DM in slight voluntary abduction of the shoulder against resistance (**b**) in patients (*filled circles*) and control subjects (*open circles*) after transcranial magnetic stimulation (TMS) at five different stimulus levels. *T* individual resting motor threshold for first dorsal interosseus muscle (FDI); *T*+ increasing stimulus intensities given in percentage of the magnetic stimulator output (MSO)

control subjects, which indicates that there was insufficient bilateral facilitation of the elicited MEP of the DM in patients.

Discussion

This study investigated the effects of chronic RCT on the neuromuscular function of the DM with TMS to provide a better understanding of adaptive changes in the motor cortex after chronic RCT. Measurements were performed with TMS, an established technique for the evaluation of human motor cortex [23]. TMS is a noninvasive method and allows researchers to investigate adaptive changes in

the central human motoneuron system [24, 25]. The relationship between MEP amplitude and stimulus intensity reflects the excitability of motor cortex and subcortical structures.

Currently, to our knowledge, no study has investigated the adaptive changes of the central part of the neuromuscular system in shoulder-muscle function on the basis of a chronic RCT. On the basis of EMG investigations, there is some evidence that different shoulder pathologies lead to an atypical pattern of shoulder-muscle activity [9, 26]. However, how the motor cortex contributes to this atypical activation pattern remains unclear.

We could demonstrate that the cortical excitability of the DM on the affected and nonaffected side in patients with unilateral chronic RCT is different compared with normal control subjects. The I/O properties of the DM in patients with chronic RCT demonstrated an enhanced excitability at rest. Our results are in line with several other studies, showing an increased MEP recruitment after lower- or upper-limb disuse [27, 28]. Zanette et al. [27] could demonstrate a hyperexcitability of hand muscles after limb immobilization for unilateral wrist fractures on the affected side when compared with the nonaffected side and normal control subjects. The discrepancy of a bilaterally increased corticospinal excitability at rest of DM observed in our study may be related to different periods of limb disuse. The duration of temporary immobilization of the forearm in Zanette's study was about 37 days, whereas the patients in our investigation suffered from unilateral RCT for at least 6 months. There exists some evidence that changes in cortical excitability depend on the duration of limb disuse. For instance, resting motor threshold was reduced after amputation [29] but not after ischemic nerve block [30]. Our results suggest that bilateral changes may occur after long-term sensomotor restriction. The contralateral inhibition would be an index of this limb involvement in motor-task adjustment and may be regarded as a tool to maintain a balance of motor output. However, the time course of cortical changes as a function of limb disuse is not well understood in detail.

An explanation for our finding was that DM hyperexcitability may be related to alterations in the sensory output from the shoulder. We hypothesize that the motor hyperexcitability may be a compensating mechanism for the reduced firing rate of motor units after RCT, with the aim of achieving a better optimal force reaction. Another major finding of our study demonstrates insufficient facilitation of the MEP of DM during voluntary activation in the patient group. We assume that the reduced MEP of DM during voluntary activation of the DM is related to adaptive changes in the motor cortex as a consequence of the RCT. We suggest that these findings are attributable to the altered afferent input from the GHJ, which causes a central

reprogramming of the cortical excitability and representation of the DM. We hypothesize that this kind of deafferentation of the shoulder can probably attribute to a nonspecific central reaction, functioning as a mechanism to prevent further joint or soft tissue damage.

A limitation of our study is that our investigation focused solely on the central changes of the DM, and it remains unclear whether the cortical excitability of several additional shoulder muscles—especially the depressors of the humeral head such as the latissimus dorsi, pectoralis major, or teres major an minor muscle—are influenced as well. Otherwise, it can be assumed that the overlapping motor cortex representations of upper extremity muscle representations leads to similar modifications in the corticomotoneuronal excitability, as shown for the DM [18, 31].

Furthermore, the two investigation groups differed significantly in age. A recent study of Oliviero et al. [32] could demonstrate that MEP were significantly smaller in older than in younger controls. The results of our study exhibited the opposite finding at rest. Furthermore, Wassermann [33] examined the variation in response to TMS in the general population in a sample of 151 individuals with an age range of 18–76 years. He showed a large variability in MEP to TMS and concluded that age was not directly related to cortical excitability. Therefore, it is assumed that the significant difference in age did not contribute to the findings of our study of a hyperexcitability of the DM at rest.

Our study may serve as a baseline investigation of motor-cortex alterations in several shoulder pathologies. Our results might also have some implication for treatment and rehabilitation of patients with chronic RCT. The insufficient facilitation of the DM indicates that rehabilitation programs based on voluntary activation of the shoulder muscles are less sufficient. It is unclear whether surgical procedures such as rotator cuff repair can reduce the disuse of the shoulder and subsequently improve the facilitation of the DM. Furthermore, it can be speculated whether other therapy modalities have a positive effect on neuromuscular dysfunction of the DM alone or in combination with surgical interventions.

In conclusion, from this study, it seems that chronic RCT leads to a bilateral corticospinal excitability alterations of the DM. Although speculative, our data suggest an involvement of central mechanisms and seem to precede severe changes of the shoulder joint, such as RCT arthropathy. Further studies will be required in order to prove this hypothesis, and the influence of surgical procedures on central motor alterations in patients with RCT or other shoulder pathologies should be investigated.

Acknowledgements This research was supported by Deutsche Arthrose Hilfe e.V.

Conflict of interest statement The authors declare that they have no conflict of interest related to the publication of this manuscript.

References

- Gohlke F (2000) Biomechanics of the shoulder. *Orthopade* 29:834–844
- Norwood LA, Barrack R, Jacobson KE (1989) Clinical presentation of complete tears of the rotator cuff. *J Bone Joint Surg Am* 71:499–505
- Murrell GA, Walton JR (2001) Diagnosis of rotator cuff tears. *Lancet* 357:769–770
- Habermeyer P, Lehmann L, Lichtenberg S (2000) Rotator cuff tears: diagnosis and therapy. *Orthopade* 29:196–208
- Dietz SO, Habermeyer P, Magosch P (2002) Current concepts in treatment of rotator cuff tears. *Zentralbl Chir* 127:194–202
- Loew M (2000) Traumatic development of rotator cuff lesion. Scientific principles and consequences for expert assessment. *Orthopade* 29:881–887
- Milgrom C, Schaffler M, Gilbert S, van Holsbeeck M (1995) Rotator-cuff changes in asymptomatic adults. The effect of age, hand dominance and gender. *J Bone Joint Surg Br* 77:296–298
- Steenbrink F, de Groot JH, Veeger HE et al (2006) Pathological muscle activation patterns in patients with massive rotator cuff tears, with and without subacromial anaesthetics. *Man Ther* 11:231–237
- Kelly BT, Williams RJ, Cordasco FA et al (2005) Differential patterns of muscle activation in patients with symptomatic and asymptomatic rotator cuff tears. *J Shoulder Elbow Surg* 14:165–171
- Malcolm MP, Triggs WJ, Light KE et al (2006) Reliability of motor cortex transcranial magnetic stimulation in four muscle representations. *Clin Neurophysiol* 117:1037–1046
- Constant CR, Murley AH (1987) A clinical method of functional assessment of the shoulder. *Clin Orthop Relat Res* 214:160–164
- Hudak PL, Amadio PC, Bombardier C (1996) Development of an upper extremity outcome measure: the DASH (disabilities of the arm, shoulder and hand) [corrected]. The Upper Extremity Collaborative Group (UECG). *Am J Ind Med* 29:602–608
- Bryden MP (1977) Measuring handedness with questionnaires. *Neuropsychologia* 15:617–624
- Barker AT, Jalinous R, Freeston IL (1985) Non-invasive magnetic stimulation of human motor cortex. *Lancet* 1:1106–1107
- Tyc F, Boyadjian A, Devanne H (2005) Motor cortex plasticity induced by extensive training revealed by transcranial magnetic stimulation in human. *Eur J Neurosci* 21:259–266
- Awiszus F (2003) TMS and threshold hunting. *Suppl Clin Neurophysiol* 56:13–23
- Rothwell JC, Thompson PD, Day BL et al (1991) Stimulation of the human motor cortex through the scalp. *Exp Physiol* 76:159–200
- Devanne H, Cassim F, Ethier C et al (2006) The comparable size and overlapping nature of upper limb distal and proximal muscle representations in the human motor cortex. *Eur J Neurosci* 23:2467–2476
- Devanne H, Lavoie BA, Capaday C (1997) Input–output properties and gain changes in the human corticospinal pathway. *Exp Brain Res* 114:329–338
- Ridding MC, Rothwell JC (1997) Stimulus/response curves as a method of measuring motor cortical excitability in man. *Electroencephalogr Clin Neurophysiol* 105:340–344
- Rothwell JC (1997) Techniques and mechanisms of action of transcranial stimulation of the human motor cortex. *J Neurosci Methods* 74:113–122

22. Hess CW, Mills KR, Murray NM (1987) Responses in small hand muscles from magnetic stimulation of the human brain. *J Physiol* 388:397–419
23. Hallett M (2000) Transcranial magnetic stimulation and the human brain. *Nature* 406:147–150
24. Abbruzzese G, Trompetto C (2002) Clinical and research methods for evaluating cortical excitability. *J Clin Neurophysiol* 19:307–321
25. Awiszus F (2005) Quantification of motoneuron pool responses to transcranial magnetic stimulation with surface electromyography. *Biocybern Biomed Eng* 25:3–10
26. Barden JM, Balyk R, Raso VJ et al (2005) Atypical shoulder muscle activation in multidirectional instability. *Clin Neurophysiol* 116:1846–1857
27. Zanette G, Manganotti P, Fiaschi A, Tamburin S (2004) Modulation of motor cortex excitability after upper limb immobilization. *Clin Neurophysiol* 115:1264–1275
28. Roberts DR, Ricci R, Funke FW et al (2007) Lower limb immobilization is associated with increased corticospinal excitability. *Exp Brain Res* 181(2):213–220
29. Chen R, Corwell B, Yaseen Z et al (1998) Mechanisms of cortical reorganization in lower-limb amputees. *J Neurosci* 18:3443–3450
30. Ziemann U, Corwell B, Cohen LG (1998) Modulation of plasticity in human motor cortex after forearm ischemic nerve block. *J Neurosci* 18:1115–1123
31. Marconi B, Pecchioli C, Koch G, Caltagirone C (2007) Functional overlap between hand and forearm motor cortical representations during motor cognitive tasks. *Clin Neurophysiol* 118:1767–1775
32. Oliviero A, Profice P, Tonali PA et al (2006) Effects of aging on motor cortex excitability. *Neurosci Res* 55:74–77
33. Wassermann EM (2002) Variation in the response to transcranial magnetic brain stimulation in the general population. *Clin Neurophysiol* 113:1165–1171