

Erratum to: CT of inferior vena cava filters: normal presentations and potential complications

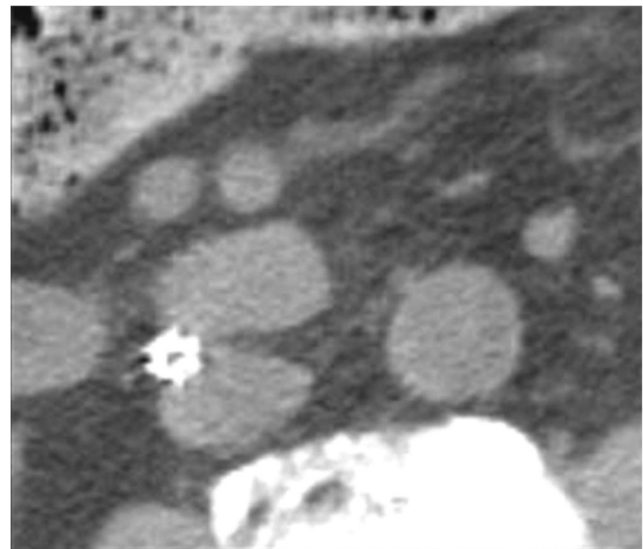
Nicholas A. Georgiou¹ · Douglas S. Katz¹ · George Ganson² · Kaitlin Eng³ · Man Hon¹

Published online: 20 August 2015
© American Society of Emergency Radiology 2015

Erratum to: Emerg Radiol
DOI 10.1007/s10140-015-1333-6

The original version of this article, unfortunately, contained an error.

The image of Figure 4b was incorrect. The correct image is given in this article.



The online version of the original article can be found at <http://dx.doi.org/10.1007/s10140-015-1333-6>.

✉ Nicholas A. Georgiou
Georgiou.Nicholas@Gmail.com

- ¹ Department of Radiology, Winthrop-University Hospital, 259 First Street, Mineola, NY 11501, USA
- ² Department of Radiology, Point Pleasant Radiology Group, Ocean Medical Center, 425 Jack Martin Boulevard, Brick, NJ 08724, USA
- ³ Department of Radiology, Yale-New Haven Medical Center, 20 York Street, New Haven, CT 06510, USA