



## *Review article*

# Imaging in assessing lymph node status in gastric cancer

ROBERT MICHAEL KWEE<sup>1</sup> and THOMAS CHRISTIAN KWEE<sup>2</sup>

<sup>1</sup>Department of Radiology, Maastricht University Medical Center, P. Debyelaan 25, 6202 AZ, Maastricht, The Netherlands

<sup>2</sup>Department of Radiology, University Medical Center Utrecht, Utrecht, The Netherlands

### Abstract

**Background.** Accurate assessment of lymph node status is of crucial importance for appropriate treatment planning and determining prognosis in patients with gastric cancer. The aim of this study was to systematically review the current role of imaging in assessing lymph node (LN) status in gastric cancer.

**Methods.** A systematic literature search was performed in the PubMed/MEDLINE and Embase databases. The methodological quality and diagnostic performance of the included studies was assessed.

**Results.** Six abdominal ultrasonography (AUS) studies, 30 endoscopic ultrasonography (EUS) studies, 10 multidetector-row computed tomography (MDCT) studies, 3 conventional magnetic resonance imaging (MRI) studies, 4 <sup>18</sup>F-fluoro-2-deoxyglucose positron emission tomography (FDG-PET) studies, and 1 FDG-PET/CT fusion study were included. In general, the included studies had moderate methodological quality. The sensitivity and specificity of AUS varied between 12.2% and 80.0% (median, 39.9%) and 56.3% and 100% (median, 81.8%). The sensitivity and specificity of EUS varied between 16.7% and 95.3% (median, 70.8%) and 48.4% and 100% (median, 84.6%). The sensitivity and specificity of MDCT varied between 62.5% and 91.9% (median, 80.0%) and 50.0% and 87.9% (median, 77.8%). The sensitivity and specificity of MRI varied between 54.6% and 85.3% (median, 68.8%) and 50.0% and 100% (median, 75.0%). The sensitivity and specificity of FDG-PET varied between 33.3% and 64.6% (median, 34.3%) and 85.7% and 97.0% (median, 93.2%). The sensitivity and specificity of the FDG-PET/CT fusion study were 54.7% and 92.2%. For all the imaging modalities, there were no significant differences between the mean sensitivities and specificities of high- and low-quality studies.

**Conclusion.** AUS, EUS, MDCT, conventional MRI, and FDG-PET cannot reliably be used to confirm or exclude the presence of LN metastasis. The performance of high-resolution PET/CT fusion and functional MRI techniques still has to be determined.

**Key words** Gastric cancer · Lymph node metastasis · Imaging · Staging · Systematic review

### Introduction

Gastric cancer is the fourth most common cancer and the second leading cause of cancer-related death worldwide. In 2002, about 934 000 people were diagnosed with gastric cancer, and approximately 700 000 died of the disease [1].

Lymph node (LN) status is an important prognostic factor regarding long-term survival [2, 3]; in patients with N0 gastric cancer, the 5-year survival rate (after surgical treatment) is 86.1%, whereas in patients with N1, N2, and N3 gastric cancer, survival rates dramatically decrease to 58.1%, 23.3%, and 5.9% [3]. Patients with T1 tumors have a low risk of LN metastasis: 2.2% in T1a (mucosal) and 17.9% in T1b (submucosal) cancer [4]. In patients with T2 and those with T3 tumors, LN metastases rise to 44% and 64% [5]. The extent to which LN dissection should be performed is still a topic of debate [5–7]. Because extended lymphadenectomy is associated with high morbidity and mortality, patients without LN metastasis should be spared from undergoing such an aggressive procedure. Pretreatment knowledge of LN status would thus be extremely helpful for determining prognosis and planning the optimal extent of lymphadenectomy. In addition, pretreatment knowledge of LN status may help in selecting patients who might benefit most from neoadjuvant chemotherapy [8].

As imaging technology continues to evolve [9], the purpose of this study was to systematically review the current role of imaging in assessing LN status in gastric cancer. This study reviews the role of imaging in discriminating node-negative from node-positive patients, rather than its role in assessing nodal stage according to

Offprint requests to: R.M. Kwee

Received: September 27, 2008 / Accepted: November 10, 2008

the TNM or Japanese Gastric Cancer Association (JGCA) classifications.

## Methods

### *Search strategy*

A computer-aided search of the PubMed/MEDLINE and Embase databases was conducted to find relevant publications on the diagnostic performance of abdominal ultrasonography (AUS), endoscopic ultrasonography (EUS), multidetector-row computed tomography (MDCT), magnetic resonance imaging (MRI),  $^{18}\text{F}$ -fluoro-2-deoxyglucose positron emission tomography (FDG-PET), and FDG-PET/CT fusion, in assessing LN status in gastric cancer. The following search terms were used: (“gastric cancer” or “stomach cancer” or “gastric carcinoma” or “stomach carcinoma”) and (“node metastasis” or “node metastases” or “nodal metastasis” or “nodal metastases” or “node involvement” or “nodal involvement” or “metastatic nodes” or “metastatic lymph nodes” or “lymphatic metastasis” or “lymphatic metastases” or “lymphatic involvement” or “lymph node involvement” or “lymph node metastatic disease” or “lymph node status” or “lymph node staging” or “N staging” or “TNM”) and (“ultrasound” or “sonography” or “ultrasonography” or “endoscopic ultrasound” or “endoscopic ultrasonography” or “EUS” or “computed tomography” or “CT” or “CAT” or “magnetic resonance” or “MR imaging” or “MRI” or “magnetic resonance tomography” or “nuclear magnetic resonance” or “NMR” or “fluorodeoxyglucose” or “2-fluoro-2-deoxy-D-glucose” or “FDG” or “positron emission tomography” or “positron-emission tomography” or “PET”). No beginning date limit was used. The search was updated until July 7, 2008. To expand our search, bibliographies of articles which finally remained after the selection process were screened for potentially suitable references.

### *Study selection*

Studies investigating the diagnostic performance of AUS, EUS, MDCT (defined as CT with four or more detectors), MRI, FDG-PET, and/or FDG-PET/CT fusion in assessing LN status in patients with newly diagnosed, histologically proven gastric cancer were eligible for inclusion. Only studies dealing with adenocarcinoma were included, because this is overwhelmingly the most important and most common malignant tumor that occurs in the stomach (range, 90% to 95%) [10]. Review articles, metaanalyses, abstracts, editorials or letters, case reports, studies involving ten or fewer patients with gastric cancer, tutorials, guidelines for

management, and non-English-language articles were excluded. Studies performed in animals and ex vivo studies were also excluded. Studies in which patients were presurgically treated with radiotherapy or chemotherapy, which may cause downstaging, were excluded. Studies which investigated only patients with gastric cancer confined to a certain part of the stomach (e.g., the gastroesophageal junction) were excluded. Studies which provided insufficient data to construct a  $2 \times 2$  contingency table to calculate sensitivity and specificity for detecting LN metastasis on a per-patient basis were excluded. When data were presented in more than one article, the article with the largest number of patients was chosen.

Two researchers (R.M.K., T.C.K.) independently reviewed the titles and abstracts of the retrieved articles, applying the inclusion and exclusion criteria mentioned above. Articles were rejected if they were clearly ineligible. The same two researchers then independently reviewed the full-text version of the remaining articles to determine their eligibility for inclusion. Disagreements were resolved in a consensus meeting.

### *Data analysis*

For each included study, information was collected concerning year of publication, country of origin, number of patients, technical details of the imaging modality under investigation, criteria for positivity, interpreter(s), and applied reference standard.

The methodological quality of the included studies was assessed in terms of the potential for bias (internal validity) and lack of generalizability (external validity). For this purpose, a checklist adapted from Kelly et al. [11] and Whiting et al. [12, 13] was used. The complete criteria list is presented in Table 1. Internal validity criteria and external validity scores were scored as positive (adequate methods) or negative (inadequate methods, potential bias). If insufficient information was provided on a specific item, a negative score was given. Two reviewers (R. M. K., T. C. K.) independently assigned the scores. Disagreements between the two researchers were discussed and resolved by consensus. Subtotals were calculated for internal (maximum eight) and external (maximum five) validity separately. Total quality scores were expressed as a percentage of the maximum score. Studies which had a percentage of the maximum score of 60 or greater were considered to be of high methodological quality. Studies which had a percentage of the maximum score of less than 60 were considered to be of low methodological quality.

Sensitivities and specificities for the detection of LN metastasis (with corresponding 95% confidence intervals [CIs]) were calculated from the original numbers given in the included studies, for each imaging modality.

**Table 1.** Criteria list used to assess the methodological quality of the studies

	Criteria of validity	Positive score
Internal validity	1. Prospective study	Mentioned in publication
	2. Adequate reference test	D2 or more extensive lymphadenectomy and histopathological analysis of resected lymph nodes performed in all patients
	3. Avoidance of disease progression bias	Time interval between index test and reference test <16 days in all patients
	4. Avoidance of withdrawal bias	<10% of patients who were examined by the index test did not undergo the reference test
	5. Avoidance of study examination bias	<10% of indeterminate or uninterpretable results
	6. Avoidance of diagnostic review bias	Blind interpretation of index test without knowledge of reference test
	7. Avoidance of test review bias	Blind interpretation of reference test without knowledge of index test
	8. Avoidance of comparator review bias	Blinding index test to the other imaging modality, if more than one imaging modality was investigated
External validity	1. Avoidance of spectrum bias	Only patients with newly diagnosed, histologically proven gastric cancer were included or a separate analysis was provided for these patients
	2. Demographic information	Study location (country), age and sex of patients reported
	3. Avoidance of selection bias	Consecutive series of patients or random selection of patients
	4. Standard execution of index test	Application of the same hardware and imaging protocol in all patients
	5. Avoidance of observer variability bias	Interpreter(s) of index test described

Forest plots for sensitivities and specificities were constructed. The means of sensitivities and specificities between studies of high and low methodological quality were compared by using a paired samples *t*-test. The level of statistical significance was set at 0.05. Statistical analyses were executed using Statistical Package for the Social Sciences version 12.0 software (SPSS, Chicago, IL, USA).

## Results

### Literature search

The computer-aided search revealed 1035 articles from PubMed/MEDLINE and 889 articles from Embase. Reviewing titles and abstracts from PubMed/MEDLINE revealed 87 studies potentially eligible for inclusion. Reviewing titles and abstracts from Embase revealed 66 articles potentially eligible for inclusion, of which 62 were already identified by the PubMed/MEDLINE search. Thus, 91 articles remained for possible inclusion and were retrieved in full-text version. Screening references of these articles did not result in other potentially relevant articles. After reviewing the full article, 37 articles were excluded, the majority ( $n = 21$ ) because they provided insufficient data to construct a  $2 \times 2$  contingency table to calculate sensitivity and specificity for the detection of LN metastasis. Other reasons for exclusion were: same data were used in a later study ( $n = 7$ ),

patients examined with a single-slice CT scanner instead of with an MDCT scanner ( $n = 2$ ), diagnostic performance for detecting LN metastasis was not investigated ( $n = 4$ ), patients with esophageal and gastric cancer mixed ( $n = 1$ ), patients with lymphomas and gastric cancer mixed ( $n = 1$ ), and fewer than 10 patients with gastric cancer included ( $n = 1$ ). Eventually, 6 AUS studies, 30 EUS studies, 10 MDCT studies, 3 (conventional) MRI studies, 4 FDG-PET studies, and 1 FDG-PET/CT fusion study [14–65] were included in this systematic review. The characteristics of the included studies are presented in Tables 2 to 7. The AUS studies were published between 1996 and 2006, the EUS studies between 1990 and 2008, the MDCT studies between 2003 and 2008, the MRI studies between 2000 and 2006, and the FDG-PET studies between 1998 and 2006. The included FDG-PET/CT fusion study was published in 2008. The number of patients in the AUS, EUS, MDCT, MRI, and FDG-PET studies varied from 22 to 198, 21 to 254, 27 to 124, 21 to 46, and 13 to 81, respectively. The included FDG-PET/CT fusion study comprised 78 patients.

### Methodological quality assessment

For each of the included studies, 13 methodological quality items were assessed (Table 8).

- For the AUS studies, the total score for combined internal and external validity, expressed as a fraction

**Table 2.** Characteristics of the six included abdominal ultrasonography studies

Study	Year, country	No. of patients	Transducer frequency (MHz)	Criteria for positivity	Interpreter(s)	Reference standard
Ozmen et al. [23]	2006, Turkey	50	NR	NR	NR	Histopathological examination after $\geq$ D2 lymphadenectomy
Liao et al. [33]	2004, China	198	3.5 to 6.0	LNs with a length $\geq$ 5 mm	NR	Intraoperative findings or histopathological examination after surgical resection
Lee et al. [42]	2001, South Korea	43	3.5	LNs with the longest diameter $>$ 8 mm	One expert radiologist	Histopathological examination after surgery
Düx et al. [53]	1997, Germany	22	3.75	Visible LNs	Ultrasonographer	Histopathological examination after surgery
Kim et al. [54]	1997, South Korea	95	3.5 or 5.0	LNs with the longest diameter $>$ 1 cm	Two radiologists	Histopathological examination after surgery
Stell et al. [57]	1996, Scotland	103	3.5	NR	Experienced personnel	Histopathological examination after surgery

LNs, lymph nodes; NR, not reported

of the maximum score, ranged from 31% to 69% (median, 58%). Three AUS studies [23, 42, 53] were of high methodological quality (percentage of the maximum score of 60 or greater).

- For the EUS studies, the total methodological quality score ranged from 38% to 77% (median, 54%). Ten EUS studies [19, 29, 34, 37, 41, 43, 44, 48, 50, 61] were of high methodological quality.
- For the MDCT studies, the total methodological quality score ranged from 38% to 85% (median, 70%). Eight MDCT studies [14, 18, 21, 22, 31, 32, 35, 39] were of high methodological quality.
- For the MRI studies, the total methodological quality score ranged from 46% to 77% (median, 62%). Two MRI studies [45, 47] were of high methodological quality.
- For the FDG-PET studies, the total methodological quality score ranged from 46% to 62% (median, 58%). Two FDG-PET studies [28, 30] were of high methodological quality.
- For the FDG-PET/CT fusion study, the total methodological quality score was 54%.

### Staging performance

The sensitivities and specificities of the included studies are displayed in Table 9 and Fig. 1.

- The sensitivity and specificity of AUS for the detection of LN metastasis varied between 12.2% and

80.0% (median, 39.9%) and 56.3% and 100% (median, 81.8%). There was no significant difference between the mean sensitivity of AUS studies with high and low methodological quality (53.2% vs 36.6%;  $P = 0.697$ ). There also was no significant difference between the mean specificity of studies with high and low methodological quality (73.3% vs 86.4%;  $P = 0.166$ ).

- The sensitivity and specificity of EUS varied between 16.7% and 96.8% (median, 70.8%) and 48.4% and 100% (median, 84.6%). There was no significant difference between the mean sensitivity of EUS studies with high and low methodological quality (69.1% vs 64.1%;  $P = 0.551$ ). There also was no significant difference between the mean specificity of studies with high and low methodological quality (81.8% vs 82.8%;  $P = 0.827$ ).
- The sensitivity and specificity of MDCT varied between 62.5% and 91.9% (median, 80.0%) and 50.0% and 87.9% (median, 77.8%). There was no significant difference between the mean sensitivity of MDCT studies with high and low methodological quality (80.1% vs 75.0%;  $P = 0.331$ ). There also was no significant difference between the mean specificity of studies with high and low methodological quality (82.0% vs 75.5%;  $P = 0.473$ ).
- The sensitivity and specificity of MRI varied between 54.6% and 85.3% (median, 68.8%) and 50.0% and 100% (median, 75.0%). The mean sensitivity and specificity of the MRI studies with high

**Table 3.** Characteristics of the 30 included endoscopic ultrasonography studies

Study	Year, country	No. of patients	Type of echoendoscope	Transducer frequency (MHz)	Criteria for positivity	Interpreter(s)	Reference standard
Lok et al. [17]	2008, Hong Kong	123	Radial array	12 or 7.5, or 5 to 20, or 12 and 20	Hypoechoic LNs, sharply demarcated, rounded contour, and size >10 mm	One of four experienced endoscopists with a special interest in EUS	Histopathological examination after surgery
Bentrem et al. [19]	2007, United States	225	NR	7.5 or 12	Hypoechoic, round, and well-demarcated LNs	A gastroenterologist	Histopathological examination after R0 resection
Tan et al. [20]	2007, China	63	Radial array	7.5 or 20	NR	NR	Histopathological examination after surgery
Arocena et al. [24]	2006, Spain	21	Linear array	12.5	LNs >5 mm, round, hypoechoic, well-demarcated, and homogeneous	Experienced endoscopist	Histopathological examination after surgery (average of 15 resected LNs)
Ganpathi et al. [25]	2006, Singapore	126	Radial array	7.5 to 20	Echo-poor, roundish, well-demarcated LNs and LNs >1 cm	One of three experienced operators	Intraoperative findings or histopathological examination after surgery
Tsendsuren et al. [26]	2006, China	41	Linear array	5.0 or 7.5	LNs with round border and hypoechoic structures	NR	Histopathological examination after surgery
Ang et al. [27]	2006, Singapore	77	Radial array	7.5	LNs >1 cm	NR	Histopathological examination after surgery
Potrc et al. [29]	2006, Slovenia	82	Radial array	7.5 or 12	NR	Two gastroenterologists	Histopathological examination after D2 lymphadenectomy
Polkowski et al. [34]	2004, Poland	88	Radial array	7.5 or 12	LNs ≥8 mm	One experienced investigator	Histopathological examination after lymphadenectomy (≥15 resected LNs)
Bhandari et al. [35]	2004, South Korea	63	Radial array	7.5 or 20	NR	Endoscopist with at least 5 years of experience	Histopathological examination after surgery
Javaid et al. [36]	2004, India	112	Radial array	7.5	Echo-poor, roundish, and well-demarcated LNs	NR	Histopathological examination after surgery
Habermann et al. [37]	2004, Germany	51	Radial array	7.5 or 12	LNs ≥8 mm in short-axis diameter	Endoscopist	Histopathological examination after ≥D1 lymphadenectomy
Xi et al. [40]	2003, China	35	Radial array	7.5, 12, or 20	NR	NR	Histopathological examination after surgery

Chen et al. [41]	2002, Taiwan	57	Radial array	7.5 or 12	LN's with either a round shape with well-defined boundary and hypoechogenicity, an elliptical shape that had a more hypoechoic pattern than the surrounding gastric tissue, or size >10 mm	NR	Histopathological examination after surgery
Willis et al. [43]	2000, Germany	130	Radial array	7.5 or 12	Echo-poor, round, well-demarcated LN's	NR	Histopathological examination after surgery
Tseng et al. [44]	2000, Taiwan	74	Radial array	7.5 or 12	LN's >1 cm in diameter or in direct contact with the primary tumor	Gastroenterologist	Histopathological examination after surgery
Mancino et al. [46]	2000, Italy	79	Radial array	7.5 or 12	Round hypoechoic LN's with sharp borders	NR	Histopathological examination after surgery
Akahoshi et al. [48]	1998, Japan	78	Radial array	15	Well-defined, round, or elliptical structures adjacent to the gastric wall which were more hypoechoic than the surrounding tissues	NR	Histopathological examination after surgery
Hunerbein et al. [49]	1998, Germany	30	Radial array	12.5	LN's with low echogenicity, clearly defined boundaries, and a round shape	Endoscopist	Histopathological examination after surgery (median of 34 resected LN's)
Wang et al. [50]	1998, Taiwan	119	Radial array	7.5 or 12	LN's >1 cm in size	NR	Histopathological examination after surgery
Hamada et al. [52]	1997, Japan	149	Radial array	7.5 or 12	Well-defined round or elliptical structure adjacent to the gastric wall, with a more hypoechoic pattern than the surrounding tissues	NR	Histopathological examination after surgery
Hunerbein et al. [55]	1996, Germany	74	Linear array	5.0 or 7.5	LN's with low echogenicity, clearly defined boundaries, and a round shape	NR	Histopathological examination after surgery
François et al. [56]	1996, France	35	Radial array	7.5 or 12	Well-circumscribed LN's with a largest/smallest diameter ratio <2	NR	Histopathological examination after surgery

Table 3. *Continue*

Study	Year, country	No. of patients	Type of echoendoscope	Transducer frequency (MHz)	Criteria for positivity	Interpreter(s)	Reference standard
Perng et al. [58]	1996, Taiwan	69	Radial array	7.5 or 12	LN's >1 cm in diameter	NR	Histopathological examination after surgery (mean of 25 and 45 resected LN's in subtotal and total gastrectomy)
Smith et al. [60]	1993, United States	50	Radial array	7.5 or 12	NR	Gastroenterologist and radiologist	Histopathological examination after D1 or D2 lymphadenectomy
Ziegler et al. [61]	1993, Germany	108	Radial array	7.5 or 12	LN's of all sizes with a sharp margin and a hypoechoic pattern	NR	Histopathological examination after surgery
Grimm et al. [62]	1993, Germany	203	Radial array	7.5	LN's with a hypoechoic pattern and sharply delineated boundaries	NR	Histopathological examination after surgery
Dittler and Stewert [63]	1993, Germany	254	Radial array	7.5 or 12	Echo-poor, roundish, and well-demarcated LN's	NR	Histopathological examination after surgery (mean of 30 and 55 resected LN's in subtotal and total gastrectomy)
Botet et al. [64]	1991, United States	50	Radial array	7.5 or 12	LN's that appear round and hypoechoic or round with a hypoechoic pattern similar to that of the primary tumor	NR	Histopathological examination after surgery (18-22 and 8-12 resected LN's in subtotal and total gastrectomy)
Tio et al. [65]	1990, The Netherlands	84	Radial array	7.5 or 12	LN's with a hypoechoic pattern and clearly delineated boundaries or direct extension of the primary tumor into adjacent LN's	NR	Histopathological examination after surgery

EUS, endoscopic ultrasonography; LN's, lymph nodes; NR, not reported

**Table 4.** Characteristics of the ten included multidetector-row computed tomography studies

Study	Year, country	No. of patients	Detector rows × collimation (mm)	Use of intravenous contrast (dose)	Imaging plane	Section thickness (mm), gap (mm)	Criteria for positivity	Interpreter(s)	Reference standard
Kim et al. [14]	2008, South Korea	123	40 × 0.625	Iodinated contrast agent (2 mg/kg)	Axial and MPR	5, 5 and 3, 3	LN's >6 mm in short-axis diameter (LN's in the left gastric space >8 mm). Additional criteria: nearly round (longitudinal-transverse diameter ratio <1.5), central necrotic, marked or heterogeneous enhancing (>85 HU in the enhanced scan), and clustered LN's regardless of size	Three gastrointestinal radiologists with 8, 5, and 5 years of experience in gastrointestinal radiology	Histopathological examination and surgical results after subtotal or total gastrectomy
Chamadol et al. [15]	2008, Thailand	28	4 × 2.5	Iodinated contrast agent (100 ml)	Axial	8, 0	LN's >8 mm in short-axis diameter and/or depending on the shape and pattern of enhancement	An experienced radiologist	Histopathological examination after D1 ( <i>n</i> = 4) or D2-lymphadenectomy ( <i>n</i> = 21), or explorative surgery ( <i>n</i> = 3)
Yang et al. [16]	2008, Japan	68	NR	NR	NR	NR	NR	NR	Histopathological examination after D1 + β (for early gastric cancer) or D2 lymphadenectomy (for advanced gastric cancer)
Chen et al. [18]	2007, Taiwan	64	16 × 1.25	Iodinated contrast agent (100 ml)	Axial and MPR	1.2, 2.5	LN's with no fat content and size (short-axis) >1 cm, or a cluster of 3 or more LN's	Two radiologists	Histopathological examination after surgery
Chen et al. [21]	2007, Taiwan	55	16 × 1.25	Iodinated contrast agent (100 ml)	Axial and MPR	5, NR, and 1.25, 0.9	Solitary or separate LN's ≥8 mm in long-axis diameter with marked enhancement (attenuation >80 HU)	Two abdominal radiologists	Histopathological examination after D1 or D2 lymphadenectomy
Yang et al. [22]	2007, South Korea	44	64 × 0.6	Iodinated contrast agent (100 ml)	Axial, coronal and oblique coronal	5, 5 and 1, 1, and 3-5, 3-5	LN's >8 mm	Two experienced radiologists	Histopathological examination after surgery
Kim et al. [31]	2005, South Korea	124	4 × 2.5	Iodinated contrast agent (150 ml)	Axial and MPR	5, 2.5	LN's >8 mm in short-axis diameter and oval	Two experienced gastrointestinal radiologists	Histopathological examination after surgery
Shimohara et al. [32]	2005, Japan	112	4 × 2.5	Iodinated contrast agent (100 ml)	Axial	2.5, 2.5	LN's >8 mm in diameter and round or with high enhancement (attenuation >100 HU)	Two readers	Histopathological examination after ≤ regional LN dissection
Bhandari et al. [35]	2004, South Korea	63	4 × 2.5	Iodinated contrast agent (120 ml)	Axial and MPR	2.5, 1.5	NR	Radiologist specialized in abdominal imaging	Histopathological examination after surgery
Stabile Ianora et al. [39]	2003, Italy	27	4 × 2.5	Iodinated contrast agent (2 ml/kg)	Axial and MPR	2.5, 1	All identifiable LN's	Two experienced radiologists	Histopathological examination after surgery

HU, hounsfield units; LN's, lymph nodes; MPR, multiplanar reformation; NR, not reported



**Table 5.** Characteristics of the three included magnetic resonance imaging studies

Study	Year, country	No. of patients	Field strength (T), coil type	Use of intravenous contrast (dose)	Sequence(s)	Imaging plane	Section thickness (mm), gap (mm)	Criteria for positivity	Interpreter(s)	Reference standard
Arocena et al. [24]	2006, Spain	21	1.0, Phased array body coil	Gadolinium (NR)	-T1W GE, IP+OP -T2W HASTE -T1W HASTE -STIR -T1W GE, IP+OP post-contrast	Axial, oblique coronal, and sagittal	-7, NR -5, NR -8, NR -7-8, NR -7, NR	LN >10 mm	Radiologist with wide experience in gastric disease examination	Histopathological examination after surgery (average of 15 resected LNs)
Kim et al. [45]	2000, South Korea	35	1.0, Phased array body coil	—	-T1W FLASH -T2W HASTE -T1W True-FISP	Axial, coronal, and sagittal	8 mm, NR	LN >8 mm in short-axis diameter	Two radiologists	Intraoperative findings and histopathological examination after surgery
Kang et al. [47]	2000, South Korea	46	1.5 T, Integrated body coil	Gadolinium, 0.1 mmol/kg	-T1W FLASH -T1W FLASH post-contrast	Axial, coronal, and sagittal	5 mm, NR	LN >8 mm in diameter or enhanced LNs regardless of size	Two radiologists	Histopathological examination after surgery

FLASH, fast low-angle shot; GE, gradient-echo; HASTE, half-Fourier acquisition single-shot turbo spin-echo; IP, in-phase; OP, out-of-phase; LN, lymph nodes; NR, not reported; STIR, short-tau inversion recovery; T1W, T1-weighted; T2W, T2-weighted; True-FISP, true fast imaging with steady-state precession

**Table 6.** Characteristics of the four included <sup>18</sup>F-fluoro-2-deoxyglucose positron emission tomography studies

Study	Year, country	No. of patients	Time of fasting before scanning	FDG dose, time interval between FDG administration and scanning	Attenuation correction, reconstruction method	Imaging plane	Criteria for positivity	Interpreter(s)	Reference standard
Mukai et al. [28]	2006, Japan	62	6 h	4.44 Mbq/kg, 60 min	Yes, NR	Axial	NR	A nuclear medicine radiologist and another radiologist	Histopathological examination after D2, D1 + $\alpha$ , $\beta$ , or D0 lymphadenectomy
Yun et al. [30]	2005, South Korea	81	4 h	370 MBq or 5.18 MBq/kg, 60 min	Yes, iterative	NR	FDG uptake similar to or higher than that of the liver	Two experienced nuclear physicians	Histopathological examination after D2, D3, or D4 lymphadenectomy
Tian et al. [38]	2004, China	27	6 h	148–185 MBq, 50–60 min	Yes, iterative	Axial, coronal, and sagittal	Lesions with an SUV >3.0	NR	Histopathological examination after surgery
Yeung et al. [51]	1998, United States	13	≥6 h	370 MBq, 45–60 min	Yes, NR	Axial, coronal, and sagittal	Abnormal and equivocal FDG uptake	Experienced PET reader	Intraoperative findings, histopathological examination after surgery, or clinical follow-up

FDG, <sup>18</sup>F-fluoro-2-deoxyglucose; NR, not reported; PET, positron emission tomography; SUV, standardized uptake value

**Table 7.** Characteristics of the included <sup>18</sup>F-fluoro-2-deoxyglucose positron emission tomography/computed tomography fusion study

Study	Year, country	No. of patients	Time of fasting before scanning	FDG dose, time interval between FDG administration and scanning	Attenuation correction, reconstruction method	Detector rows × collimation (mm)	Use of intravenous contrast (dose)	Imaging plane	Section thickness (mm), gap (mm)	Criteria for positivity	Interpreter(s)	Reference standard
Yang et al. [16]	2008, Japan	78	4 h	200 Mbq, 60 min	Yes, iterative	NR	NR	NR	NR	NR	NR	Histopathological examination after D1 + $\beta$ (for early gastric cancer) or D2 lymphadenectomy (for advanced gastric cancer)

FDG, <sup>18</sup>F-fluoro-2-deoxyglucose; NR, not reported

**Table 8.** Quality assessment of the included abdominal ultrasonography (AUS), endoscopic ultrasonography (EUS), multidetector-row computed tomography (MDCT), magnetic resonance imaging (MRI), <sup>18</sup>F-fluoro-2-deoxyglucose positron emission tomography (FDG-PET), and <sup>18</sup>F-fluoro-2-deoxyglucose positron emission tomography/computed tomography (FDG-PET/CT) fusion studies

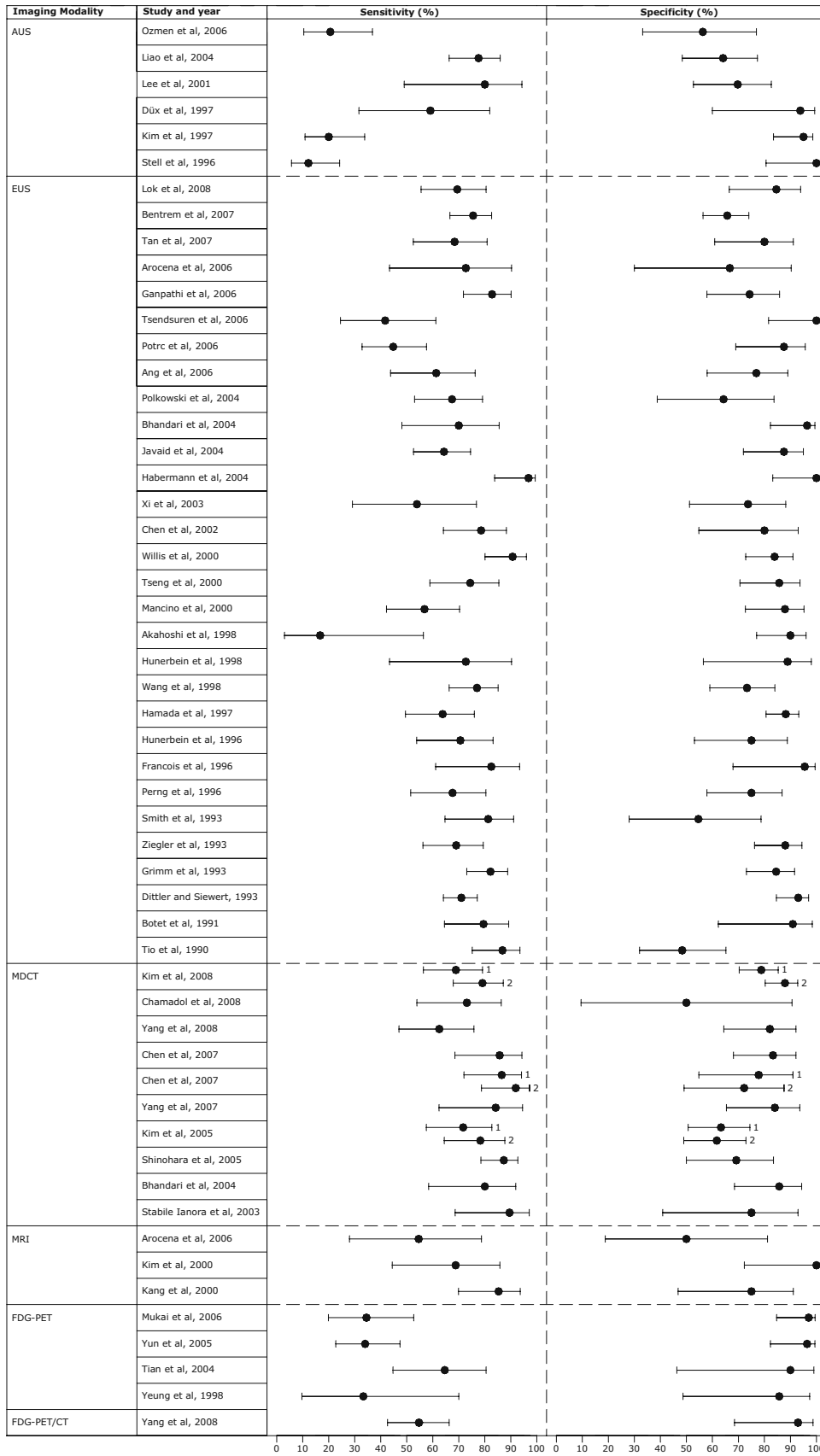
Imaging modality	Study	Year	Criteria										Total scores		Percentage of maximum score			
			IV					EV					IV	EV				
			1	2	3	4	5	6	7	8	1	2				3	4	5
AUS	Ozmen et al. [23]	2006	-	+	-	+	+	+	-	+	+	+	-	+	-	5	3	62
	Liao et al. [33]	2004	-	-	-	-	-	+	-	+	+	+	-	-	-	2	2	31
	Lee et al. [42]	2001	-	-	-	+	+	+	-	+	+	+	+	+	+	4	5	69
	Düx et al. [53]	1997	+	-	+	+	-	+	-	+	+	-	+	+	+	5	4	69
	Kim et al. [54]	1997	-	-	+	-	+	+	-	-	+	+	-	+	+	3	4	54
EUS	Stell et al. [57]	1996	-	-	-	-	+	-	-	+	+	+	+	+	+	2	5	54
	Lok et al. [17]	2008	-	-	-	-	+	-	-	-	+	+	+	-	+	1	4	38
	Bentrem et al. [19]	2007	+	-	-	+	+	+	-	+	+	-	+	+	+	5	4	69
	Tan et al. [20]	2007	-	-	+	+	+	+	-	+	+	+	-	-	-	5	2	54
	Arocena et al. [24]	2006	+	-	-	-	+	+	-	-	+	+	-	+	+	3	4	54
	Ganpathi et al. [25]	2006	-	-	-	-	+	+	-	+	+	+	+	-	+	3	4	54
	Tsendsuren et al. [26]	2006	-	-	-	+	+	+	-	+	+	+	-	-	-	4	2	46
	Ang et al. [27]	2006	+	-	-	-	+	+	+	-	+	-	-	+	-	3	2	38
	Potrc et al. [29]	2006	+	+	-	+	+	+	-	+	+	-	-	+	+	6	3	69
	Polkowski et al. [34]	2004	+	-	-	-	+	+	-	+	+	+	+	+	+	4	5	69
	Bhandari et al. [35]	2004	+	-	-	-	+	+	-	+	+	+	-	-	+	4	3	54
	Javaid et al. [36]	2004	-	-	-	+	+	+	-	+	+	+	-	+	-	4	3	54
	Habermann et al. [37]	2004	+	-	-	+	+	+	-	+	+	+	+	-	+	5	4	69
	Xi et al. [40]	2003	-	-	-	+	+	+	-	+	+	+	-	+	-	4	3	54
	Chen et al. [41]	2002	-	-	+	+	+	+	+	-	+	+	+	+	+	5	5	77
	Willis et al. [43]	2000	+	-	-	+	+	+	-	+	+	+	+	+	-	5	4	69
	Tseng et al. [44]	2000	-	-	-	+	+	+	-	+	+	+	-	+	+	4	4	62
	Mancino et al. [46]	2000	-	-	-	+	+	+	-	+	+	+	-	-	-	4	2	46
	Akahoshi et al. [48]	1998	+	-	-	-	+	+	-	+	+	+	+	+	-	4	4	62
	Hunerbein et al. [49]	1998	+	-	-	-	+	+	-	+	+	-	-	-	+	4	2	46
	Wang et al. [50]	1998	+	-	-	+	+	+	-	+	+	+	-	+	-	5	3	62
	Hamada et al. [52]	1997	-	-	-	+	+	+	-	+	+	+	-	-	-	4	2	46
	Hunerbein et al. [55]	1996	+	-	-	-	-	+	-	+	+	-	+	+	-	3	3	46
	François et al. [56]	1996	+	-	-	-	+	+	-	+	+	+	-	+	-	4	3	54
	Perng et al. [58]	1996	+	-	-	+	+	-	-	-	+	+	-	+	-	3	3	46
	Smith et al. [60]	1993	-	-	-	+	+	+	-	+	+	-	-	-	+	4	2	46
	Ziegler et al. [61]	1993	+	-	-	+	+	+	-	-	+	+	+	+	-	4	4	62
	Grimm et al. [62]	1993	+	-	-	-	-	+	-	+	+	+	-	-	-	3	2	38
	Dittler and Siewert [63]	1993	-	-	-	+	+	+	-	+	+	+	+	-	-	4	3	54
	Botet et al. [64]	1991	-	-	-	+	+	+	-	-	+	+	+	-	-	3	3	46
	MDCT	Tio et al. [65]	1990	-	-	-	+	+	+	-	+	+	+	-	-	4	2	46
		Kim et al. [14]	2008	-	-	-	-	+	+	-	+	+	+	+	+	3	5	62
		Chamadol et al. [15]	2008	-	-	-	-	+	+	-	+	+	+	-	+	3	4	54
Yang et al. [16]		2008	-	-	-	+	+	-	-	-	+	+	-	+	2	3	38	
Chen et al. [18]		2007	+	-	-	+	+	+	-	+	+	+	+	+	5	5	77	
Chen et al. [21]		2007	+	-	+	-	+	+	-	+	+	+	+	+	5	5	77	
Yang et al. [22]		2007	+	-	-	+	+	-	-	+	+	+	-	+	4	4	62	
Kim et al. [31]		2005	+	-	-	+	+	+	-	+	+	+	+	+	5	5	77	
Shinohara et al. [32]		2005	+	-	+	+	+	+	-	+	+	+	+	+	6	5	85	
Bhandari et al. [35]		2004	+	-	-	-	+	+	-	+	+	+	-	+	4	4	62	
Stabile Ianora et al. [39]		2003	+	-	+	+	+	+	-	+	+	+	-	+	6	4	77	
MRI		Arocena et al. [24]	2006	+	-	-	-	-	+	-	-	+	+	-	+	2	4	46
		Kim et al. [45]	2000	+	-	+	-	+	+	-	+	+	+	+	+	5	5	77
		Kang et al. [47]	2000	-	-	+	+	+	+	-	-	+	+	-	+	4	4	62
FDG-PET		Mukai et al. [28]	2006	-	-	-	+	+	+	-	-	+	+	+	+	3	5	62
	Yun et al. [30]	2005	-	+	-	+	+	+	-	+	+	+	-	+	5	3	62	
	Tian et al. [38]	2004	+	-	-	+	+	-	-	+	+	-	-	+	4	2	46	
FDG-PET/CT	Yeung et al. [51]	1998	-	-	-	+	+	-	-	+	+	-	+	+	3	4	54	
	Yang et al. [16]	2008	-	-	-	+	+	+	-	+	+	-	+	-	4	3	54	

IV, internal validity; EV, external validity

**Table 9.** Abdominal ultrasonography (AUS), endoscopic ultrasonography (EUS), multidetector-row computed tomography (MDCT), magnetic resonance imaging (MRI), <sup>18</sup>F-fluoro-2-deoxyglucose positron emission tomography (FDG-PET), and <sup>18</sup>F-fluoro-2-deoxyglucose positron emission tomography/computed tomography (FDG-PET/CT) fusion studies: sensitivity and specificity for detection of nodal metastasis

Imaging modality	Study	Year	Sensitivity		Specificity	
			Value	95% CI	Value	95% CI
AUS	Ozmen et al. [23]	2006	20.6	10.4–36.8	56.3	33.2–76.9
	Liao et al. [33]	2004	77.6	66.3–85.9	64.1	48.4–77.3
	Lee et al. [42]	2001	80.0	49.0–94.3	69.7	52.7–82.6
	Düx et al. [53]	1997	59.1	31.6–81.9	93.8	60.0–99.3
	Kim et al. [54]	1997	20.0	10.9–33.8	95.0	83.5–98.6
	Stell et al. [57]	1996	12.2	5.7–24.2	100	80.6–100
EUS	Lok et al. [17]	2008	69.4	55.5–80.5	84.6	66.5–93.9
	Bentrem et al. [19]	2007	75.5	66.6–82.6	65.7	56.4–74.0
	Tan et al. [20]	2007	68.4	52.5–80.9	80.0	60.9–91.1
	Arocena et al. [24]	2006	72.7	43.4–90.3	66.7	30.0–90.3
	Ganpathi et al. [25]	2006	82.8	71.8–90.1	74.3	57.9–85.8
	Tsendsuren et al. [26]	2006	41.7	24.5–61.2	100	81.6–100
	Ang et al. [27]	2006	61.3	43.8–76.3	76.9	58.0–89.0
	Potrc et al. [29]	2006	44.8	32.8–57.6	87.5	69.0–95.7
	Polkowski et al. [34]	2004	67.4	53.0–79.1	64.3	38.8–83.7
	Bhandari et al. [35]	2004	70.0	48.1–85.5	96.4	82.3–99.4
	Javaid et al. [36]	2004	64.3	52.6–74.5	87.5	71.9–95.0
	Habermann et al. [37]	2004	96.8	83.8–99.4	100	83.2–100
	Xi et al. [40]	2003	53.9	29.1–76.8	73.7	51.2–88.2
	Chen et al. [41]	2002	78.6	64.1–88.3	80.0	54.8–93.0
	Willis et al. [43]	2000	90.7	80.1–96.0	83.9	72.8–91.0
	Tseng et al. [44]	2000	74.4	58.9–85.4	85.7	70.6–93.7
	Mancino et al. [46]	2000	56.8	42.2–70.3	87.9	72.7–95.2
	Akahoshi et al. [48]	1998	16.7	3.0–56.4	90.0	77.0–96.0
	Hunerbein et al. [49]	1998	72.7	43.4–90.3	88.9	56.5–98.0
	Wang et al. [50]	1998	77.0	66.3–85.1	73.3	59.0–84.0
	Hamada et al. [52]	1997	63.8	49.5–76.0	88.2	80.6–93.2
	Hunerbein et al. [55]	1996	70.6	53.8–83.2	75.0	53.1–88.8
	François et al. [56]	1996	82.5	61.1–93.4	95.5	67.9–99.5
	Perng et al. [58]	1996	67.6	51.5–80.4	75.0	57.9–86.8
	Smith et al. [60]	1993	81.3	64.7–91.1	54.6	28.0–78.7
	Ziegler et al. [61]	1993	69.0	56.2–79.4	88.0	76.2–94.4
	Grimm et al. [62]	1993	82.2	73.1–88.8	84.5	73.1–91.6
	Dittler and Siewert [63]	1993	71.0	64.1–77.1	93.0	84.6–97.0
	Botet et al. [64]	1991	79.5	64.5–89.2	90.9	62.3–98.4
	Tio et al. [65]	1990	86.8	75.2–93.5	48.4	32.0–65.2
MDCT	Kim et al. [14]	2008				
	Axial images		68.9	56.4–79.1	78.8	70.3–85.3
	MPR		79.1	67.9–87.1	87.9	80.3–92.8
	Chamadol et al. [15]	2008	73.1	53.9–86.3	50.0	9.5–90.6
	Yang et al. [16]	2008	62.5	47.0–75.8	82.1	64.4–92.1
	Chen et al. [18]	2007	85.7	68.5–94.3	83.3	68.1–92.1
	Chen et al. [21]	2007				
	Axial images		86.5	72.0–94.1	77.8	54.8–91.0
	MPR		91.9	78.7–97.2	72.2	49.1–87.5
	Yang et al. [22]	2007	84.2	62.4–94.5	84.0	65.4–93.6
	Kim et al. [31]	2005				
	Axial images		71.7	57.5–82.7	63.3	50.7–74.4
	MPR		78.3	64.4–87.7	61.7	49.0–72.9
	Shinohara et al. [32]	2005	87.3	78.5–92.7	69.2	50.0–83.5
	Bhandari et al. [35]	2004	80.0	58.4–91.9	85.7	68.5–94.3
Stabile Ianora et al. [39]	2003	89.5	68.6–97.1	75.0	40.9–92.9	
MRI	Arocena et al. [24]	2006	54.6	28.0–78.7	50.0	18.8–81.2
	Kim et al. [45]	2000	68.8	44.4–85.8	100	72.3–100
	Kang et al. [47]	2000	85.3	69.9–93.6	75.0	46.8–91.1
	Mukai et al. [28]	2006	34.5	19.9–52.7	97.0	84.7–99.5
FDG-PET	Yun et al. [30]	2005	34.0	22.7–47.4	96.4	82.3–99.4
	Tian et al. [38]	2004	64.6	44.7–80.5	90.0	46.3–99.0
	Yeung et al. [51]	1998	33.3	9.7–70.0	85.7	48.7–97.4
FDG-PET/CT	Yang et al. [16]	2008	54.7	42.6–66.3	92.9	68.5–98.7

MPR, multiplanar reformation



**Fig. 1.** Abdominal ultrasonography (AUS), endoscopic ultrasonography (EUS), multidetector-row computed tomography (MDCT), magnetic resonance imaging (MRI), <sup>18</sup>F-fluoro-2-deoxyglucose positron emission tomography (FDG-PET), and FDG-PET/CT fusion; forest plots of sensitivity and specificity for depiction of nodal metastasis. 1, Axial slices; 2, multiplanar reformation

methodological quality were 77.1% and 87.5%. There was one MRI study [24] with low methodological quality, with sensitivity of 54.6% and specificity of 50.0%

- The sensitivity and specificity of FDG-PET varied between 33.3% and 64.6% (median, 34.3%) and 85.7% and 97.0% (median, 93.2%). There was no significant difference between the mean sensitivity of FDG-PET studies with high and low methodological quality (34.3% vs 49.0%;  $P = 0.515$ ). There also was no significant difference between the mean specificity of studies with high and low methodological quality (96.7% vs 87.9%;  $P = 0.131$ ).
- The sensitivity and specificity of the FDG-PET/CT fusion study were 54.7% and 92.2%, respectively.

## Discussion

This systematic review demonstrates that, to date, no imaging modality consistently achieves both high sensitivity and high specificity in the detection of LN metastasis in gastric cancer. The sensitivities and specificities of AUS, EUS, and MRI varied from poor (<60%) to high ( $\geq 80\%$ ). The sensitivity of MDCT varied from moderate (60%–80%) to high, whereas the specificity varied from poor to high. The sensitivity of FDG-PET varied from poor to moderate, whereas the specificity was high. Similarly, The sensitivity of FDG-PET/CT fusion was poor, whereas the specificity was high. For all imaging modalities, there were no significant differences between the mean sensitivities and specificities of the high-quality and low-quality studies. There were too many missing or mixed values for a substantial number of study characteristics and insufficient studies to use meta-regression or to perform subgroup analysis to examine other possible causes for the heterogeneous results. Possible causes are variations in patient characteristics and scanning protocols, and the use of different diagnostic criteria and implicit thresholds. Yet another likely cause of the heterogeneous results is the moderate methodological quality of the included studies. Only one AUS study had a prospective study design [53], in only one EUS study the time interval between EUS and the reference test was less than 16 days [29], and in none of the FDG-PET(/CT fusion) studies the time interval between FDG-PET(/CT fusion) and the reference test was less than 16 days. Except for one AUS study [23], one EUS study [29], and one FDG-PET study [30], none of the included studies applied histopathological analysis after  $\geq D2$  lymphadenectomy in all patients. Furthermore, the quality of pathological examinations of excised LNs, the skills of the surgeons, and the tumor extensions may also have affected sensitivity and specificity. Finally, test review bias may have been present in

all the included studies. Because of the heterogeneity and moderate methodological quality of the included studies, we omitted calculation of pooled sensitivities and specificities.

AUS and EUS rely on the morphological characteristics, echogenicity, and size of LNs as criteria to define metastasis. The latter may explain the insufficient diagnostic performance of AUS and EUS, because metastases in normal-sized LNs may be missed. A study investigating the correlation between LN size and metastatic infiltration in patients with gastric cancer found that 80% of tumor-free LNs had a diameter of 5 mm or less [66]. However, 55% of the metastatic lymph nodes were also 5 mm or less in diameter [66]. Thus, LN size only is not a reliable indicator of LN metastasis in gastric cancer. Furthermore, AUS is limited in obese patients or when overlying bowel gas is present, because in these circumstances adequate visualization of LNs is hampered. At high transducer frequencies, EUS has a limited depth of penetration, making visualization of more distant LNs difficult. Another major disadvantage of both AUS and EUS is their inherent operator-dependency. The diagnostic performance of AUS and EUS in detecting LN metastasis in gastric cancer has been studied since the early 1990s, and, as can be seen in Table 9 and Fig. 1, the diagnostic accuracy of AUS and EUS has not significantly improved over time.

The included MDCT studies mainly used LN size, but also degree of enhancement and LN shape as criteria to define malignancy. Although MDCT is much less subject to observer variability compared to AUS and EUS, metastases in LNs of normal size can still be missed. Remarkably, one MDCT study [39] defined all identifiable LNs as metastatic. Surprisingly, this study still reported a sensitivity of 89.5% and a specificity of 75.0%. The included MDCT studies used 4- to 64-section MDCT scanners. It is unlikely that newer MDCT technology, such as the application of 128- to 256-section MDCT scanners or dual-source technology, will improve diagnostic performance, because current MDCT scanners already have the ability to detect LNs of 5 mm or less in diameter.

The included conventional MRI studies all used different pulse sequences to obtain images. Two studies also obtained post-contrast images. All the studies used LN size as the criterion to define malignancy, and one study also defined enhancing LNs as metastatic. An explanation for the insufficient diagnostic performance of conventional MRI is its inability to identify metastatic LNs of normal size. Functional MRI techniques (including ultrasmall particles of iron oxide [USPIO]-enhanced MR lymphography and diffusion-weighted MRI) or a combination of conventional and functional MRI may be more accurate than conventional MRI

alone. USPIO-enhanced lymphography allows the identification of malignant nodal infiltration independent of LN size. After intravenous administration, USPIOs are taken up by macrophages in the reticuloendothelial system, predominantly within the LNs. Normal homogeneous uptake of USPIOs in nonmetastatic LNs shortens the T2 and T2\*, turning these nodes hypointense on T2- and T2\*-weighted images, whereas malignant LNs lack uptake and remain hyperintense. USPIO-enhanced lymphography indeed has been shown to achieve higher diagnostic precision than does conventional, unenhanced MRI for the detection of LN metastases of various tumors [67]. Although no USPIO-enhanced lymphography studies were identified for inclusion in this systematic review, its usefulness in detecting metastatic LNs in gastric cancer has already been demonstrated by a recent pilot study in 17 patients [68]. MR lymphography using other contrast agents may also have high potential [69], but this remains to be investigated. Diffusion-weighted MRI is another functional imaging technique, based on water diffusivity. Cancerous lesions which have architectural malformations are highlighted by this technique, because they have a restricted diffusion [70]. However, no studies on diffusion-weighted MRI were identified for inclusion in this systematic review.

A possible reason for the reported low to moderate sensitivity of FDG-PET is its limited resolution; current FDG-PET units have a 4- to 5-mm resolution [71], but it has been reported that 14.5% of metastatic LNs in gastric cancer have a largest diameter of less than 3 mm [66]. Consequently, these LN metastases can be missed by FDG-PET. Low FDG uptake of metastatic LNs may also explain the low sensitivity of FDG-PET; Stahl et al. [72] found that diffusely growing and mucus-containing gastric cancers may exhibit low FDG uptake. Another possible explanation for the low sensitivity of FDG-PET is the masking of perigastric LNs by FDG uptake of the adjacent primary tumor. On the other hand, FDG uptake of the primary tumor may mimic involvement of adjacent LNs, thereby decreasing specificity. Similarly, physiological FDG uptake of the stomach [73] may also mask or mimic metastatic perigastric LNs. FDG-PET/CT fusion provides both anatomic and functional information, and allows more accurate localization of foci with increased FDG uptake than stand-alone PET; this may reduce the problems of missing metastatic LNs with low FDG uptake, physiological FDG uptake being misinterpreted as pathological, and false localization of disease [74]. Additional advantages of using a combined PET/CT scanner are decreased scanning time and improved quality of the FDG-PET images [74]. However, the results of the FDG-PET/CT fusion study [16] included in this systematic review suggest that FDG-PET/CT fusion does not

improve sensitivity (or specificity). Of note, however, the poor sensitivity may mainly be a result of the limited resolution of the PET/CT scanner used in that study [16], which is only 6.3 mm [75]. The performance of PET/CT scanners with a higher resolution still has to be determined, to our knowledge.

Laparoscopic sentinel node (SN) biopsy is another promising tool to more accurately determine nodal status in patients with gastric cancer. The SN concept is based on the premise that tumor cells will preferentially metastasize to the first draining LN in the regional lymphatics, the SN. After identifying the SN (by use of a radionuclide tracer and/or dye), and laparoscopic biopsy, LN metastasis is confirmed or ruled out by histological examination. A disadvantage of laparoscopic SN biopsy, however, is its invasiveness. Although studies on laparoscopic SN biopsy have shown its potential [76–79], various technical and material limitations still have to be overcome. Also, the reliability of laparoscopic SN biopsy has yet to be determined by multicenter prospective clinical trials [80].

In conclusion, AUS, EUS, MDCT, conventional MRI, and FDG-PET do not achieve consistently high sensitivity and specificity in detecting LN metastasis in patients with gastric cancer. The value of high-resolution PET/CT fusion and functional MRI techniques still has to be determined.

## References

1. Parkin DM, Bray F, Ferlay J, Pisani P. Global cancer statistics, 2002. *CA Cancer J Clin* 2005;55:74–108.
2. Siewert JR, Böttcher K, Stein HJ, Roder JD. Relevant prognostic factors in gastric cancer: 10-year results of the German Gastric Cancer Study. *Ann Surg* 1998;228:449–61.
3. Zhang XF, Huang CM, Lu HS, Wu XY, Wang C, Guang GX, et al. Surgical treatment and prognosis of gastric cancer in 2613 patients. *World J Gastroenterol* 2004;10:3405–8.
4. Gotoda T, Yanagisawa A, Sasako M, Ono H, Nakanishi Y, Shimoda T, et al. Incidence of lymph node metastasis from early gastric cancer: estimation with a large number of cases at two large centers. *Gastric Cancer* 2000;3:219–25.
5. Hohenberger P, Gretschel S. Gastric cancer. *Lancet* 2003;362:305–15.
6. Swan R, Miner TJ. Current role of surgical therapy in gastric cancer. *World J Gastroenterol* 2006;12:372–9.
7. Brennan MF. Current status of surgery for gastric cancer: a review. *Gastric Cancer* 2005;8:64–70.
8. De Vita F, Giuliani F, Galizia G, Belli C, Aurilio G, Santabarbara G, et al. Neo-adjuvant and adjuvant chemotherapy of gastric cancer. *Ann Oncol* 2007;18(Suppl 6):20–3.
9. Barentsz J, Takahashi S, Oyen W, Mus R, De Mulder P, Reznick R, et al. Commonly used imaging techniques for diagnosis and staging. *J Clin Oncol* 2006;24:3234–44.
10. Rubin E, Palazzo JP. The gastrointestinal tract. In: Rubin E, Gorstein F, Rubin F, Schwartz R, Strayer D, editors. *Rubin's pathology. Clinicopathologic foundations of medicine*. 4th ed. Philadelphia: Lippincott Williams & Wilkins; 2005. p. 660–739.
11. Kelly S, Berry E, Roderick P, Harris KM, Cullingworth J, Gathercole L, et al. The identification of bias in studies of the

- diagnostic performance of imaging modalities. *Br J Radiol* 1997;70:1028–35.
12. Whiting P, Rutjes AW, Reitsma JB, Bossuyt PM, Kleijnen J. The development of QUADAS: a tool for the quality assessment of studies of diagnostic accuracy included in systematic reviews. *BMC Med Res Methodol* 2003;3:25.
  13. Whiting PF, Weswood ME, Rutjes AW, Reitsma JB, Bossuyt PN, Kleijnen J. Evaluation of QUADAS, a tool for the quality assessment of diagnostic accuracy studies. *BMC Med Res Methodol* 2006;6:9.
  14. Kim YN, Choi D, Kim SH, Kim MJ, Lee SJ, Lee WJ, et al. Gastric cancer staging at isotropic MDCT including coronal and sagittal MPR images: endoscopically diagnosed early vs advanced gastric cancer. *Abdom Imaging* 2009;34:26–34.
  15. Chamadol N, Wongwiwatchai J, Bhudhisawasd V, Pairojkul C. Accuracy of spiral CT in preoperative staging of gastric carcinoma: correlation with surgical and pathological findings. *J Med Assoc Thai* 2008;91:356–63.
  16. Yang Q-M, Kawamura T, Itoh H, Bando E, Nemoto M, Akamoto S, et al. Is PET-CT suitable for predicting lymph node status for gastric cancer? *Hepatogastroenterology* 2008;55:782–5.
  17. Lok K-H, Lee C-K, Yiu H-L, Lai L, Szeto M-L, Leung S-K. Current utilization and performance status of endoscopic ultrasound in a community hospital. *J Dig Dis* 2008;9:41–7.
  18. Chen BB, Liang PC, Liu KL, Hsiao JK, Huang JC, Wong JM, et al. Preoperative diagnosis of gastric tumors by three-dimensional multidetector row CT and double contrast barium meal study: correlation with surgical and histologic results. *J Formos Med Assoc* 2007;106:943–52.
  19. Bentrem D, Gerdes H, Tang L, Brennan M, Coit D. Clinical correlation of endoscopic ultrasonography with pathologic stage and outcome in patients undergoing curative resection for gastric cancer. *Ann Surg Oncol* 2007;14:1853–9.
  20. Tan SY, Wang JY, Shen L, Luo HS, Shen ZX. Relationship between preoperative staging by endoscopic ultrasonography and MMP-9 expression in gastric carcinoma. *World J Gastroenterol* 2007;13:2108–12.
  21. Chen CY, Hsu JS, Wu DC, Kang WY, Hsieh JS, Jaw TS, et al. Gastric cancer: preoperative local staging with 3D multi-detector row CT—correlation with surgical and histopathologic results. *Radiology* 2007;242:472–82.
  22. Yang DM, Kim HC, Jin W, Ryu CW, Kang JH, Park CH, et al. 64 Multidetector-row computed tomography for preoperative evaluation of gastric cancer: histological correlation. *J Comput Assist Tomogr* 2007;31:98–103.
  23. Ozmen MM, Zulfikaroglu B, Kucuk NO, Ozalp N, Aras G, Koseoglu T, et al. Lymphoscintigraphy in detection of the regional lymph node involvement in gastric cancer. *Ann R Coll Surg Engl* 2006;88:632–8.
  24. Arocena MG, Barturen A, Bujanda L, Casado O, Ramirez MM, Oleagoitia JM, et al. MRI and endoscopic ultrasonography in the staging of gastric cancer. *Rev Esp Enferm Dig* 2006;98:582–90.
  25. Ganpathi IS, So JB, Ho KY. Endoscopic ultrasonography for gastric cancer: does it influence treatment? *Surg Endosc* 2006;20:559–62.
  26. Tsendsuren T, Jun SM, Mian XH. Usefulness of endoscopic ultrasonography in preoperative TNM staging of gastric cancer. *World J Gastroenterol* 2006;12:43–7.
  27. Ang TL, Ng TM, Fock KM, Teo EK. Accuracy of endoscopic ultrasound staging of gastric cancer in routine clinical practice in Singapore. *Chin J Dig Dis* 2006;7:191–6.
  28. Mukai K, Ishida Y, Okajima K, Isozaki H, Morimoto T, Nishiyama S. Usefulness of preoperative FDG-PET for detection of gastric cancer. *Gastric Cancer* 2006;9:192–6.
  29. Potrc S, Skalicky M, Ivanecz A. Does endoscopic ultrasound staging already allow individual treatment regimens in gastric cancer? *Wien Klin Wochenschr* 2006;118 (Suppl 2):48–51.
  30. Yun M, Lim JS, Noh SH, Hyung WJ, Cheong JH, Bong JK, et al. Lymph node staging of gastric cancer using (18)F-FDG PET: a comparison study with CT. *J Nucl Med* 2005;46:1582–8.
  31. Kim HJ, Kim AY, Oh ST, Kim JS, Kim KW, Kim PN, et al. Gastric cancer staging at multi-detector row CT gastrography: comparison of transverse and volumetric CT scanning. *Radiology* 2005;236:879–85.
  32. Shinohara T, Ohyama S, Yamaguchi T, Muto T, Kohno A, Ogura T, et al. Preoperative TNM staging of advanced gastric cancer with multi-detector row computed tomography. *Japan Med Assoc J* 2005;48:175–82.
  33. Liao SR, Dai Y, Huo L, Yan K, Zhang L, Zhang H, et al. Trans-abdominal ultrasonography in preoperative staging of gastric cancer. *World J Gastroenterol* 2004;10:3399–404.
  34. Polkowski M, Palucki J, Wronska E, Szawlowski A, Nasierowska-Guttmejer A, Butruk E. Endosonography versus helical computed tomography for locoregional staging of gastric cancer. *Endoscopy* 2004;36:617–23.
  35. Bhandari S, Shim CS, Kim JH, Jung IS, Cho JY, Lee JS, et al. Usefulness of three-dimensional, multidetector row CT (virtual gastroscopy and multiplanar reconstruction) in the evaluation of gastric cancer: a comparison with conventional endoscopy, EUS, and histopathology. *Gastrointest Endosc* 2004;59:619–26.
  36. Javaid G, Shah OJ, Dar MA, Shah P, Wani NA, Zargar SA. Role of endoscopic ultrasonography in preoperative staging of gastric carcinoma. *ANZ J Surg* 2004;74:108–11.
  37. Habermann CR, Weiss F, Riecken R, Honarpisheh H, Bohnacker S, Staedtler C, et al. Preoperative staging of gastric adenocarcinoma: comparison of helical CT and endoscopic US. *Radiology* 2004;230:465–71.
  38. Tian J, Chen L, Wei B, Shao M, Ding Y, Yin D, et al. The value of vesicant 18F-fluorodeoxyglucose positron emission tomography (18F-FDG PET) in gastric malignancies. *Nucl Med Commun* 2004;25:825–31.
  39. Stabile Ianora AA, Pedote P, Scardapane A, Memeo M, Rotondo A, Angelelli G. Preoperative staging of gastric carcinoma with multidetector spiral CT. *Radiol Med (Torino)* 2003;106:467–80.
  40. Xi WD, Zhao C, Ren GS. Endoscopic ultrasonography in preoperative staging of gastric cancer: determination of tumor invasion depth, nodal involvement and surgical resectability. *World J Gastroenterol* 2003;9:254–7.
  41. Chen CH, Yang CC, Yeh YH. Preoperative staging of gastric cancer by endoscopic ultrasound: the prognostic usefulness of ascites detected by endoscopic ultrasound. *J Clin Gastroenterol* 2002;35:321–7.
  42. Lee DH, Ko YT, Park SJ, Lim JW. Comparison of hydro-US and spiral CT in the staging of gastric cancer. *Clin Imaging* 2001;25:181–6.
  43. Willis S, Truong S, Gribnitz S, Fass J, Schumpelick V. Endoscopic ultrasonography in the preoperative staging of gastric cancer: accuracy and impact on surgical therapy. *Surg Endosc* 2000;14:951–4.
  44. Tseng LJ, Mo LR, Tio TL, Fresner YT, Jao N, Lin RC, et al. Video-endoscopic ultrasonography in staging gastric carcinoma. *Hepatogastroenterology* 2000;47:897–900.
  45. Kim AY, Han JK, Seong CK, Kim TK, Choi BI. MRI in staging advanced gastric cancer: is it useful compared with spiral CT? *J Comput Assist Tomogr* 2000;24:389–94.
  46. Mancino G, Bozzetti F, Schicchi A, Schiavo M, Spinelli P, Andreola S. Preoperative endoscopic ultrasonography in patients with gastric cancer. *Tumori* 2000;86:139–41.
  47. Kang BC, Kim JH, Kim KW, Lee DY, Baek SY, Lee SW, et al. Value of the dynamic and delayed MR sequence with Gd-DTPA in the T-staging of stomach cancer: correlation with the histopathology. *Abdom Imaging* 2000;25:14–24.
  48. Akahoshi K, Chijiwa Y, Hamada S, Sasaki I, Nawata H, Kabemura T, et al. Pretreatment staging of endoscopically early gastric



- cancer with a 15 MHz ultrasound catheter probe. *Gastrointest Endosc* 1998;48:470–6.
49. Hunerbein M, Ghadimi BM, Haensch W, Schlag PM. Transendoscopic ultrasound of esophageal and gastric cancer using miniaturized ultrasound catheter probes. *Gastrointest Endosc* 1998;48:371–5.
  50. Wang JY, Hsieh JS, Huang YS, Huang CJ, Hou MF, Huang TJ. Endoscopic ultrasonography for preoperative locoregional staging and assessment of resectability in gastric cancer. *Clin Imaging* 1998;22:355–9.
  51. Yeung HW, Macapinlac H, Karpeh M, Finn RD, Larson SM. Accuracy of FDG-PET in gastric cancer. Preliminary experience. *Clin Positron Imaging* 1998;1:213–21.
  52. Hamada S, Akahoshi K, Chijiwa Y, Nawata H, Sasaki I. Relationship between histological type and endosonographic detection of regional lymph node metastases in gastric cancer. *Br J Radiol* 1997;70:697–702.
  53. Dux M, Roeren T, Kuntz C, Richter GM, Kauffmann GW. TNM staging of gastrointestinal tumors by hydrosoneography: results of a histopathologically controlled study in 60 patients. *Abdom Imaging* 1997;22:24–34.
  54. Kim JJ, Jung HC, Song IS, Choi KW, Kim CY, Han JK, et al. Preoperative evaluation of the curative resectability of gastric cancer by abdominal computed tomography and ultrasonography: a prospective comparison study. *Korean J Intern Med* 1997;12:1–6.
  55. Hunerbein M, Dohmoto M, Rau B, Schlag PM. Endosonography and endosonography-guided biopsy of upper-GI-tract tumors using a curved-array echoendoscope. *Surg Endosc* 1996;10:1205–9.
  56. François E, Peroux J, Mouroux J, Chazalle M, Hastier P, Ferrero J, et al. Preoperative endosonographic staging of cancer of the cardia. *Abdom Imaging* 1996;21:483–7.
  57. Stell DA, Carter CR, Stewart I, Anderson JR. Prospective comparison of laparoscopy, ultrasonography and computed tomography in the staging of gastric cancer. *Br J Surg* 1996;83:1260–2.
  58. Perng DS, Jan CM, Wang WM, Chen LT, Su YC, Liu GC, et al. Computed tomography, endoscopic ultrasonography and intraoperative assessment in TN staging of gastric carcinoma. *J Formos Med Assoc* 1996;95:378–85.
  59. Greenberg J, Durkin M, Van Drunen M, Aranha GV. Computed tomography or endoscopic ultrasonography in preoperative staging of gastric and esophageal tumors. *Surgery* 1994;116:696–701.
  60. Smith JW, Brennan MF, Botet JF, Gerdes H, Lightdale CJ. Preoperative endoscopic ultrasound can predict the risk of recurrence after operation for gastric carcinoma. *J Clin Oncol* 1993;11:2380–5.
  61. Ziegler K, Sanft C, Zimmer T, Zeitz M, Felsenberg D, Stein H, et al. Comparison of computed tomography, endosonography, and intraoperative assessment in TN staging of gastric carcinoma. *Gut* 1993;34:604–10.
  62. Grimm H, Binmoeller KF, Hamper K, Koch J, Henne-Bruns D, Soehendra N. Endosonography for preoperative locoregional staging of esophageal and gastric cancer. *Endoscopy* 1993;25:224–30.
  63. Dittler HJ, Siewert JR. Role of endoscopic ultrasonography in gastric carcinoma. *Endoscopy* 1993;25:162–6.
  64. Botet JF, Lightdale CJ, Zauber AG, Gerdes H, Winawer SJ, Urmacher C, et al. Preoperative staging of gastric cancer: comparison of endoscopic US and dynamic CT. *Radiology* 1991;181:426–32.
  65. Tio TL, Coene PP, Luiken GJ, Tytgat GN. Endosonography in the clinical staging of esophagogastric carcinoma. *Gastrointest Endosc* 1990;36 (Suppl 2):2–10.
  66. Mönig SP, Zirbes TK, Schröder W, Baldus SE, Lindemann DG, Dienes HP, et al. Staging of gastric cancer: correlation of lymph node size and metastatic infiltration. *AJR Am J Roentgenol* 1999;173:365–7.
  67. Will O, Purkayastha S, Chan C, Athanasiou T, Darzi AW, Gedroyc W, et al. Diagnostic precision of nanoparticle-enhanced MRI for lymph-node metastases: a meta-analysis. *Lancet Oncol* 2006;7:52–60.
  68. Tatsumi Y, Tanigawa N, Nishimura H, Nomura E, Mabuchi H, Matsuki M, et al. Preoperative diagnosis of lymph node metastases in gastric cancer by magnetic resonance imaging with ferumoxtran-10. *Gastric Cancer* 2006;9:120–8.
  69. Herborn CU, Lauenstein TC, Vogt FM, Lauffer RB, Debatin JF, Ruehm SG. Interstitial MR lymphography with MS-325: characterization of normal and tumor-invaded lymph nodes in a rabbit model. *AJR Am J Roentgenol* 2002;179:1567–72.
  70. Koh DM, Collins DJ. Diffusion-weighted MRI in the body: applications and challenges in oncology. *AJR Am J Roentgenol* 2007;188:1622–35.
  71. Rohren EM, Turkington TG, Coleman RE. Clinical applications of PET in oncology. *Radiology* 2004;231:305–32.
  72. Stahl A, Ott K, Weber WA, Becker K, Link T, Siewert JR, et al. FDG PET imaging of locally advanced gastric carcinomas: correlation with endoscopic and histopathological findings. *Eur J Nucl Med Mol Imaging* 2003;30:288–95.
  73. Koga H, Sasaki M, Kuwabara Y, Hiraka K, Nakagawa M, Abe K, et al. An analysis of the physiological FDG uptake pattern in the stomach. *Ann Nucl Med* 2003;17:733–8.
  74. von Schulthess GK, Steinert HC, Hany TF. Integrated PET/CT: current applications and future directions. *Radiology* 2006;238:405–22.
  75. Mullani NA, Mawlawi O. Why is the resolution of the Discovery PET/CT camera so poor? *J Nucl Med* 2005;46:898; author reply 898.
  76. Hiratsuka M, Miyashiro I, Ishikawa O, Furukawa H, Motomura K, Ohigashi H, et al. Application of sentinel node biopsy to gastric cancer surgery. *Surgery* 2001;129:335–40.
  77. Tonouchi H, Mohri Y, Tanaka K, Konishi N, Ohmori Y, Kobayashi M, et al. Lymphatic mapping and sentinel node biopsy during laparoscopic gastrectomy for early cancer. *Dig Surg* 2003;20:421–7.
  78. Song X, Wang L, Chen W, Pan T, Zhu H, Xu J, et al. Lymphatic mapping and sentinel node biopsy in gastric cancer. *Am J Surg* 2004;187:270–3.
  79. Mura G, Vagliasindi A, Framarini M, Mazza P, Solfrini G, Verdecchia GM. The sentinel node biopsy in early gastric cancer: a preliminary study. *Langenbecks Arch Surg* 2006;391:113–7.
  80. Kitagawa Y, Fujii H, Kumai K, Kubota T, Otani Y, Saikawa Y, et al. Recent advances in sentinel node navigation for gastric cancer: a paradigm shift of surgical management. *J Surg Oncol* 2005;90:147–51.