

## Neurogenic pulmonary edema caused by bilateral medial medullary infarction

Igor Antoncic · Siniša Dunatov · Matija Sosic ·  
Ronald Antulov · Marina Bralic

Received: 2 October 2014 / Accepted: 5 December 2014 / Published online: 12 December 2014  
© Springer-Verlag Italia 2014

Sir,

Neurogenic pulmonary edema (NPE) is a clinical syndrome characterized by the acute onset of pulmonary edema following a significant central nervous system (CNS) lesion in the absence of cardiopulmonary disease [1, 2]. In most cases the precise CNS lesion site directly associated with NPE could not be identified. According to some case reports and animal experiments these ‘NPE trigger zones’ include the hypothalamus and the medulla [3–5]. We report a case where NPE was induced by a bilateral medial medullary infarction (BMMI), a rare stroke syndrome per se.

A 63-year-old man diagnosed with hypertension was referred to our hospital with symptoms of vertigo, vomiting and tingling of the left side of the body. The symptoms occurred 2 h prior to admission. He became soporous (Glasgow Coma Scale 10) and developed acute respiratory failure. He was analgosedated, endotracheally intubated and mechanically ventilated. On admission, his blood pressure was 170/100 mmHg, pulse was 98/min, and body temperature was 36.3 °C. Laboratory values and head CT

were normal. A simple neurological examination (“diagnostic window”) was undertaken. The patient was alert, pupils and eye movements were normal. Right beating nystagmus on right gaze was present. Facial sense and movement were not impaired. He was tetraparetic with dominant weakness and hypoaesthesia of the left side of the body. The deep tendon reflexes were enhanced and Babinski’s sign was present bilaterally. On hospital day 5 the patient was weaned from the ventilator and extubated. His breathing was irregular and dyspneic. He was analgosedated, re-intubated and set on lung protective ventilation. Chest radiograph indicated findings consistent with pulmonary edema (Fig. 1a). Tracheotomy was performed. Weaning procedures were unsuccessfully attempted two more times. Finally, he was successfully weaned from the ventilator on the 24th day of his illness.

The patient then underwent brain magnetic resonance imaging (MRI) which revealed signal changes at the level of the bilateral medial medulla along with tissue loss. On the basis of these findings, BMMI was suggested (Fig. 1b). Neurological symptoms gradually regressed, although mild tetraparesis remained. The patient was transferred to a different facility to continue rehabilitation. On his last follow-up he could walk and stand with no support.

BMMI is a rare stroke subtype, usually presenting with sudden onset of tetraparesis/tetraplegia, loss of deep sensation, hypoglossal palsy, and bulbar dysfunction, with or without respiratory failure [6]. According to reported studies almost one-fourth of patients with BMMI develop respiratory failure [7]. Typically, the patient becomes acutely dyspneic, tachypneic, and hypoxic within minutes. As we reported the neurological status of our patient gradually improved, but weaning from the ventilator was unsuccessful because he developed pulmonary edema which complicated and therefore prolonged treatment

---

I. Antoncic · S. Dunatov · M. Sosic (✉) · R. Antulov ·  
M. Bralic

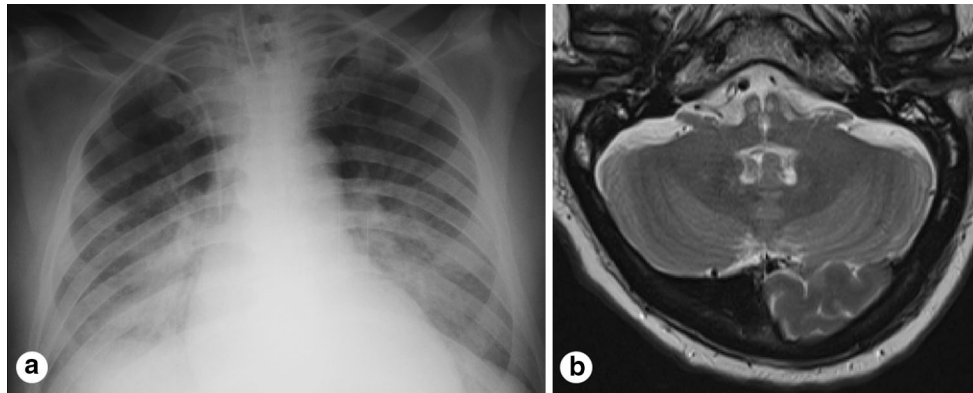
Intensive Care Unit, Department of Neurology, Clinical Hospital  
Center Rijeka, Cambierieva 17/8, 51000 Rijeka, Croatia  
e-mail: matija.sosic@yahoo.co.uk

I. Antoncic  
e-mail: igor.antoncic@ri.t-com.hr

S. Dunatov  
e-mail: dunatov@net.hr

R. Antulov  
e-mail: ronald.antulov@outlook.com

M. Bralic  
e-mail: marina.bralic@yahoo.com



**Fig. 1** **a** Anteroposterior chest radiograph presented bilateral alveolar opacities indicating the existence of pulmonary edema. **b** Axial T2-weighted MRI demonstrated a “heart-shaped” hyperintense signal in the bilateral medial medulla along with tissue loss

despite good neurological recovery. Chest radiograph will reveal bilateral hyperdense infiltrates consistent with acute respiratory distress syndrome (ARDS). The sudden development of hypoxemic respiratory failure following a catastrophic CNS event, which cannot be attributed to other causes of ARDS, is the only universally agreed upon characteristic of NPE. A common denominator in all cases of NPE is likely a surge in endogenous serum catecholamines that may result in changes in cardiopulmonary hemodynamics and Starling forces. According to reported similar cases it appears that the specific clinical manifestations of this surge may vary depending on the individual circumstance. Although the exact source of sympathetic outflow has not been identified, certain centers in the brain have been implicated. These ‘NPE trigger zones’ include the hypothalamus and the medulla, specifically area A1, A5, nuclei of solitary tract and the area postrema. Injury to area A1 or disruption of the efferent pathway between A5 and the cervical cord has been shown to result in the formation of pulmonary edema and an increase in systemic blood pressure. In a case series of 22 patients suffering from NPE, 11 of the patients had significant radiographic abnormalities in the hypothalamus [1]. In our case brain MRI confirmed BMMI which we associated with the development of NPE. The diagnosis of ‘pure’ NPE is a diagnosis of exclusion and requires documentation of non-cardiogenic pulmonary edema in the setting of neurological injury. The sporadic and relatively unpredictable nature of

NPE, as well as lack of etiologic-specific diagnostic markers may in part be responsible for its poor recognition at the bedside [1]. Despite its rarity, NPE occurrence in BMMI could significantly complicate treatment and influence outcome as reported in our case.

**Conflict of interest** The authors report no disclosures.

## References

1. Davison DL, Terek M, Chawla LS (2012) Neurogenic pulmonary edema. *Crit Care* 16:212
2. Inobe JJ, Mori T, Ueyama H, Kumamoto T, Tsuda T (2000) Neurogenic pulmonary edema induced by primary medullary hemorrhage: a case report. *J Neurol Sci* 172:73–76
3. Brown RH Jr, Beyerl BD, Iseke R, Lavyne MH (1986) Medulla oblongata edema associated with neurogenic pulmonary edema. Case report. *J Neurosurg* 64:494–500
4. Simon RP, Gean-Marton AD, Sander JE (1991) Medullary lesion inducing pulmonary edema: a magnetic resonance imaging study. *Ann Neurol* 30:727–730
5. Hannawi Y, Hannawi B, Rao CP, Suarez JI, Bershad EM (2013) Stroke-associated pneumonia: major advances and obstacles. *Cerebrovasc Dis* 35:430–443
6. Pongmoragot J, Parthasarathy S, Selchen D, Saposnik G (2013) Bilateral medial medullary infarction: a systematic review. *J Stroke Cerebrovasc Dis* 22:775–780
7. Kameda W, Kawanami T, Kurita K, Daimon M, Kayama T, Hosoya T, Kato T (2004) Lateral and medial medullary infarction: a comparative analysis of 214 patients. *Stroke* 35:694–699