



## Correction to: Anti-cyclic citrullinated peptide antibody in the cerebrospinal fluid in patients with rheumatoid arthritis who have central nervous system involvement

Misako Higashida-Konishi<sup>1</sup>  · Keisuke Izumi<sup>1,2</sup>  · Masako Tsukamoto<sup>1</sup> · Hiroaki Ohya<sup>1</sup> · Nozomi Takasugi<sup>1</sup> · Satoshi Hama<sup>1</sup> · Yutaro Hayashi<sup>1</sup> · Mari Ushikubo<sup>1</sup> · Kumiko Akiya<sup>1</sup> · Araki Kazuhiro<sup>1</sup> · Yutaka Okano<sup>1</sup> · Hisaji Oshima<sup>1</sup>

Published online: 22 June 2020

© International League of Associations for Rheumatology (ILAR) 2020

### Correction to: *Clinical Rheumatology*

<https://doi.org/10.1007/s10067-020-05044-0>

The authors regret that the original published version of the above article contained errors. The authors requested that these be noted and that the original paper remains unchanged.

The authors' first affiliation should be presented as **“Department of Connective Tissue Diseases, National Hospital Organization Tokyo Medical Center, 2-5-1 Higashigaoka, Meguro-ku, Tokyo, 152-8902 Japan”**.

---

The online version of the original article can be found at <https://doi.org/10.1007/s10067-020-05044-0>

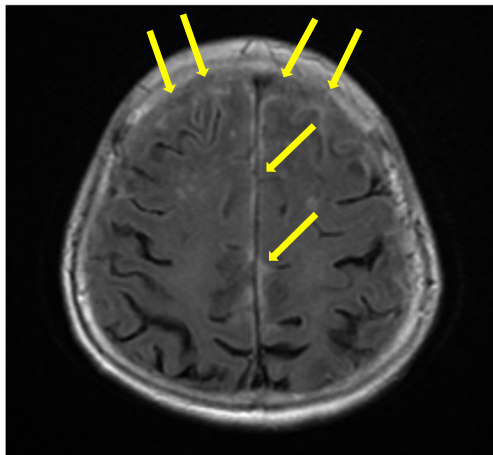
---

✉ Keisuke Izumi  
izz@keio.jp

<sup>1</sup> Department of Connective Tissue Diseases, National Hospital Organization Tokyo Medical Center, 2-5-1 Higashigaoka, Meguro-ku, Tokyo 152-8902, Japan

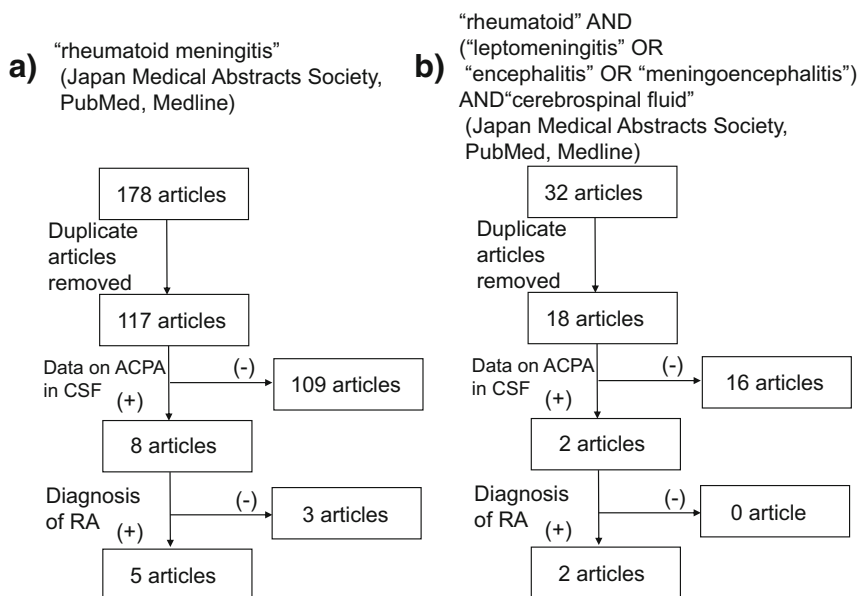
<sup>2</sup> Division of Rheumatology, Department of Internal Medicine, Keio University School of Medicine, 35 Shinanomachi, Shinjuku-ku, Tokyo 160-8582, Japan

Figure 1 image was incorrect, and in Fig. 4 panel b, a typo error was present, “ANDs” should have been “AND”. The corrected figures are now presented correctly as follows:



**Fig. 1** T2 FLAIR MRI image, day 2. AT2 FLAIR MRI image showed a high signal in the subarachnoid space over the frontal and parietal lobes. FLAIR MRI, fluid-attenuated inversion recovery magnetic resonance imaging

**Fig. 4** Flow diagram of the systematic literature review on patients with RA in whom ACPA in the CSF was measured. **a** Search term: “rheumatoid meningitis.” **b** Search terms: “rheumatoid” AND (“leptomeningitis” OR “encephalitis” OR “meningoencephalitis”) AND “cerebrospinal fluid.” ACPA, anti-cyclic citrullinated peptide antibody; CSF, cerebrospinal fluid; RA, rheumatoid arthritis



In the reference [15] of Table 1, the year “2014/2013” should have been “2013”.

**Table 1** Review of cases of patients with RA in whom ACPA in the CSF was measured

References	Age	Sex	CNS involvement in RA	Presence of RA	RA activity when diagnosed with RM, RL, or RE	ACPA (U/mL)		RF (IU/mL)		ACPA-IgG index (diagnosis of RM → after treatment)	Treatment
						Serum (diagnosis of RM → after treatment)	CSF (diagnosis of RM → after treatment)	Serum (diagnosis of RM → after treatment)	CSF (diagnosis of RM → after treatment)		
[15]	2013	57	F	RM	7 years before	ND	8.3 → 0.6	ND	ND	ND	PSL
[16]	2016	63	M	RM	2 months after the diagnosis of RM	No symptoms of active synovitis	472 → 248	26.2 → 8.5	140 → 60	ND	mPSL
[17]	2019	41	M	RL	At the same time	Right elbow was swollen and painful	> 600 → ND	Strong positive → ND	8 → ND	ND	mPSL + RTX
[18]	2019	62	F	RM	3 years before	No symptoms of active synovitis	> 1600 → 706	19,600 → 64	56 → 18	92.7 → negative	mPSL + MTX
[19]	2019	71	F	RM	Past history of RA	ND	9.3 → ND	0.8 → ND	ND	11.10 → ND	mPSL
[4]	2019	57	M	RE	1 day after the diagnosis of RE	No symptoms of active synovitis	1570 → ND	217 → ND	313 → ND	4 → ND	mPSL + MTX
This case	2019	61	F	RM	7 years before	No symptoms of active synovitis	287 → 61.4	23.9 → < 0.6	134.3 → 32	21.9 → < 15.0	PSL + IVCY

ACPA anti-cyclic citrullinated peptide antibody, CNS central nervous system, CSF cerebrospinal fluid, IVCY intermittent pulse intravenous cyclophosphamide therapy, ND not described, mPSL methyl prednisolone, PSL prednisolone, RA rheumatoid arthritis, RE rheumatoid encephalitis, RF rheumatoid factor, RL rheumatoid leptomeningitis, RM rheumatoid meningitis, RME rheumatoid meningoencephalitis, RTX rituximab

## References

4. Kitamura E, Kondo Y, Kanazawa N, Akutsu T, Nishiyama K, Iizuka T (2019) Autoimmune encephalitis as an extra-articular manifestation of rheumatoid arthritis. *Intern Med* 58:1007–1009
15. Ichiose S, Oohashi N, Watabe R, Satou S, Hoshi K, YahikoZawa H, Watanabe M (2013) A 57-year-old female case of rheumatoid meningitis with mental symptoms for which anti-cyclic citrullinated peptides antibody in the cerebrospinal fluid was useful for diagnosis. *Med J Nagano Red Cross Hosp* 27:110–111. (conference proceedings)
16. Shibahara T, Matsushita T, Matsuo R, Fukushima Y, Fukuda K, Sugimori H, Kamouchi M, Kitazono T, Ago T (2016) Anti-cyclic citrullinated peptide antibody positive meningoencephalitis in the preclinical period of rheumatoid arthritis. *Case Rep Neurol* 8:156–160. <https://doi.org/10.1159/000447627>
17. Lubomski M, Sy J, Buckland M, Lee AS, Richards B, Thompson E, Fulham M, Breen N, Morris K, Halmagyi GM (2019) Rheumatoid leptomeningitis presenting with an acute neuropsychiatric disorder. *Pract Neurol* 19:68–71. <https://doi.org/10.1136/practneurol-2018-001978>
18. Nissen MS, Nilsson AC, Forsberg J, Milthers J, Wirenfeldt M, Bonde C, Byg KE, Ellingsen T, Blaabjerg M (2019) Use of cerebrospinal fluid biomarkers in diagnosis and monitoring of rheumatoid meningitis. *Front Neurol* 10:666
19. Asano K, Kamimura N, Tsuchihashi Y, Watanabe D, Takahashi R (2019) A 71-year-old female with rheumatoid meningitis who presented with characteristic imaging findings on brain MRI and was useful for diagnosis by anti-CCP antibody in cerebrospinal fluid. *Rinsho Shinkeigaku (Clinical Neurology)* 59:299. (conference proceedings)

**Publisher's note** Springer Nature remains neutral with regard to jurisdictional claims in published maps and institutional affiliations.