



3-dimensional analysis of nasal soft tissue alterations following maxillary Lefort I advancement with and without impaction using 3D photogrammetry scanner

Hamoun Sabri^{1,2} · Azita Tehranchi³ · Farzin Sarkarat^{4,5}

Received: 16 September 2021 / Accepted: 5 October 2022 / Published online: 2 November 2022
© The Author(s), under exclusive licence to Springer-Verlag GmbH Germany, part of Springer Nature 2022

Abstract

Purpose This study was designed to investigate the changes in nasal soft tissue following maxillary Lefort I advancement with and without impaction in subjects presenting a skeletal class III malocclusion, using a 3D photogrammetry scanner.

Materials and methods Patients with class III malocclusion undergoing Lefort I advancement with and without impaction and bilateral sagittal split osteotomy with the standard technique were included in this study. Patients were divided into two groups: maxillary Lefort I advancement alone (group 1) and combined with impaction (group 2). Facial soft tissue landmarks of the nose including nasal height (NH), nasal length (NL), nasal tip projection (NTP), alar width (AW), alar base width (ABW), subalar width (Sbal), nasolabial angle (NLA), nasofrontal angle (NFA), and columella inclination (CI) before and at least 4 months after surgery were obtained by a 3D scanner.

Results Twenty-one patients were included in this study (Group 1: 11 and Group 2: 10). NH, NTP, and NL decreased significantly in both groups following surgery. In addition, Sbal decreased only in group 2. On the other hand, NLA and CI increased significantly in group 2. The inter-group comparison revealed a statistically significant difference in the alterations in NH, NL, and CI between the two groups.

Conclusion Changes in the nose soft tissue occurred after both surgeries, but their type and extent were different. Actions taken to reduce unwanted changes need to be further investigated. To evaluate the changes, 3D photogrammetry scan is a feasible imaging technique that can be used, providing numerous benefits.

Keywords Advancement · Impaction · Nasal changes · Orthognathic surgery · 3-dimensional photogrammetry · Lefort osteotomy

✉ Hamoun Sabri
Hamounsbi@gmail.com
Azita Tehranchi
azitatehranchi@yahoo.com
Farzin Sarkarat
sarkarat@hotmail.com

¹ Dental Research Center, School of Dentistry, Shahid Beheshti University of Medical Sciences, SBUMS, Arabi Ave, Daneshjoo Blvd, Velenjak, Tehran 19839-63113, Iran

² Department of Periodontics and Oral Medicine, School of Dentistry, University of Michigan, Ann Arbor, MI, USA

³ Dental Research Center, Dental Research Institute, Department of Orthodontics, Dental School, Shahid Beheshti University of Medical Sciences, Tehran, Iran

⁴ Department of Oral and Maxillofacial Surgery, Cranio-Maxillofacial Research Center, Dentistry Branch of Islamic, Azad University of Medical Sciences, Tehran, Iran

⁵ Department of Oral and Maxillofacial Surgery, Gulf Medical University, Sharjah, UAE

Introduction

Orthognathic surgery (OS) is a procedure used to treat moderate to severe malocclusions and has been widely performed to enhance facial esthetics and oro-masticatory function [1, 2]. A type of OS, the Lefort I osteotomy, allows movement of the maxilla in all three planes. It could be performed to correct midface hypoplasia, vertical maxillary excess, and dentofacial asymmetry [3]. Moreover, the Lefort I surgery and the movement of maxilla could alter the nasal soft tissue shape and position. Most alterations, such as the widening of the alar base width (ABW), occur in the nasolabial area [1]. In addition, alterations in Columella-Labial region and Nasofrontal region are also reported [4–6]. These alterations can have both positive and/or negative outcomes on patients' appearance [7].

As the esthetic outcomes of OS on patients' psychology and life quality are undeniable, it is crucial to evaluate the soft tissue changes and the skeletal movements [8, 9]. Craniofacial anthropometry is a widely used method in this manner, with applicabilities in face growth assessment, skeletal discrepancy diagnosis, and orthodontic and ortho-surgical treatment planning [10].

The conventional imaging method for orthognathic patients is 2D radiographic imaging. The systems that use 2D radiographic imaging have several limitations, such as substantial radiographic projection errors and radiation exposure. Moreover, they cannot strongly identify landmarks and are imprecise concerning the duplication of measurements. Other issues with 2D imaging systems are variations in the reference point positioning such as sella turcica and restrictions in soft tissue balance evaluation [11]. The newly available three-dimensional (3D) face scanning method for craniofacial morphology assessment has not only granted the advantage of faster and non-invasive surface anatomy capture but also provided a great potential to expand the quantitative assessment of the face [12, 13]. Other advantages of this method include no radiation exposure and high repeatability. It also provides the possibility of volumetric, topographic, regional, and linear evaluations [14]. This method can be used to assess soft tissue and skin surface alterations after OS more accurately than methods such as direct anthropometry, cephalometric photography, and 2D photogrammetry [12]. In addition, the accuracy of this method for identification of 3D facial landmarks was reported [15].

Facial landmarks can be digitally recorded with a 3D face scanner and can be used for facial recognition, facial emotion capture, facial cosmetic planning and surgery, and maxillofacial rehabilitation [16]. Therefore, assessing surgical outcomes on 3D facial landmarks is valuable,

especially as a patient's ethnic background might alter one's perception of esthetics and soft tissue alterations [17]. To our knowledge, no studies have been conducted to assess the postoperative alterations between the maxillary advancement only and advancement with impaction patients using a 3D photogrammetry scanner. Also, the outcome of either maxillary advancement or maxillary impaction has been studied by prior studies. Therefore, in this study we aimed to assess alterations of the soft tissue in class III malocclusion patients after the Lefort I maxillary advancement with and without impaction using 3D photogrammetry scanner.

Materials and methods

Study design

This study designed as a prospective clinical study and the eligibility criteria included patients requiring orthognathic surgery of maxillary Lefort I advancement with or without impaction and with no history of facial trauma, previous orthognathic surgeries, congenital problems, craniofacial syndromes, cleft lip, and palate. Moreover, patients should not have had an anterior nasal spine (ANS) trimming or Condylectomy within their treatment plan. Patients were divided into two groups: group 1 patients underwent the Lefort I advancement surgery without maxillary impaction, and group 2, consisted of patients underwent the maxillary advancement with impaction.

The ethics permission was approved by the Research Committee of the Shahid Beheshti University of Medical Sciences, Tehran, Iran. Informed consent from all patients was obtained.

3D face scanning method

Scrupulously, 3D photogrammetric scans were obtained from the patients before and after the surgery (Fig. 1). The patients' 3D photogrammetric images were taken with the Sense-2 3D Scanner (Sense; 3D Systems, Rock Hill, SC, USA) (Fig. 2). These images were taken immediately before the surgery (T0) and at least 4 months after the surgery (T1) to reduce measurement errors due to soft tissue swelling [18]. The scan was taken while the patients had their heads in the natural head position (NHP) and habitual occlusion. To reach this occlusion, they were asked to relax their facial muscles, swallow, and have their posterior teeth in normal occlusion. Additionally, for reaching the NHP, the patients were firstly asked to walk and relax following by gradually decreasing forward and backward head

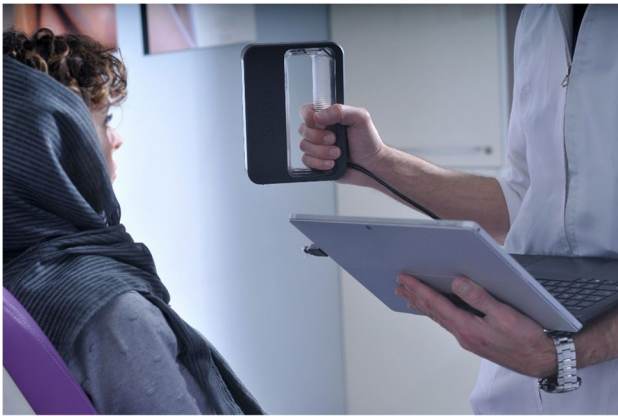

Fig. 1 The scanning process of the face in a patient with the Sense 2 scanner



Fig. 2 Sense 2; 3D scanner

Table 1 Sense 2 scanner device information (Source: 3dsystems.com)

Specification	Value
Supported operating systems	Windows 10® 64-bit
Maximum power consumption	5.0 VDC
Scan volume	Min: 0.2 m×0.2 m×0.2 m Max: 2 m×2 m×2 m
Dimensions	17.8 cm×12.9 cm×3.3 cm
Operating range	Min: 0.45 m Max: 1.6 m
Field of view	Horizontal: 45° Vertical: 57.5° Diagonal: 69°
Depth image size	640 px (w)×480 px (h)
Spatial x/y resolution @ 0.5 m	0.9 mm
Depth resolution @ 0.5 m	1 mm
Data interface	USB 3.0
USB cable length	200 cm
Maximal image throughput	30 fps

cephalometric tracing, and digital mock surgery and determined during the surgery with a digitally fabricated, acrylic surgical guide. Likewise, the amount of planned impaction determined and marked by a caliper on the bone. Next, using 4 L-shaped titanium mini-plates (two paranasal plates and two plates in the zygomatic buttress on each side), by rigid fixation with a total of 16 screws (Fig. 3). Subsequently, to prevent the widening of the alar base, the cinch suture was applied using 0-nylon thread. The mucosa was then sutured with 3–0 vicryl sutures. In group two, the vomer bone and nasal septum were shortened by the handpiece Burr.

movements until reaching a self-balanced position. They were then asked to stare at the reflection of their eyes in a mirror in front of them. The information of the Sense 3D scanner is shown in Table 1.

Surgical method

In this study, conventional maxillary Lefort I osteotomy and bilateral sagittal split Ramus osteotomy were performed. To reduce surgical error, all surgeries were performed with the same technique, and an alar cinch suture was used in all patients likewise the ANS was not trimmed. After the conventional osteotomy, the maxilla was fixed in the new place, which had been planned during the treatment planning procedure according to the consultation with the orthodontist colleague,

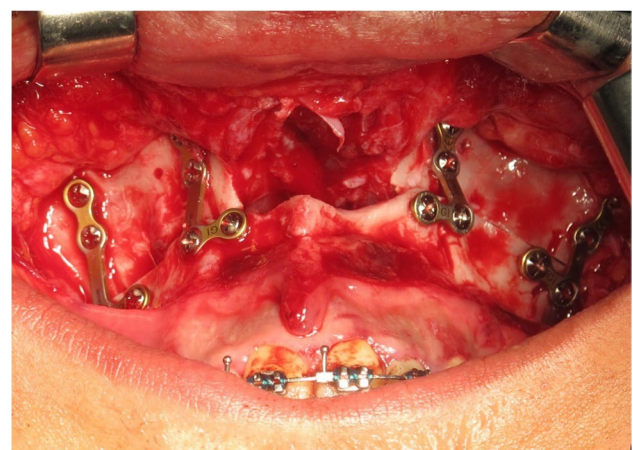


Fig. 3 Intra-operative photograph of utilized L-shape mini plates in fixation of maxilla

Landmarks

In this study, the facial landmarks were selected based on the study of Farkas et al. (Appendix 1) [19]. The accuracy of landmark detection in 3D photogrammetric images has been reported in previous studies [15, 20–23]. Before and after the surgery, the 3D face scans were processed by GOM Inspect 2019 software (Hotfix 7, Braunschweig, Germany) (the accuracy of this software in detecting the linear and angular measurements is presented in Appendix 2), and all the mentioned landmarks were localized by one investigator (Figs. 4, 5, 6, and 7). The landmarks of all subjects were re-evaluated at

least 2 weeks following the primary evaluation by the same investigator. An intra-observer reliability test was done by comparing measurements from the first and repeated landmark identification. According to the intra-class correlation coefficient (ICC) of 0.898 ($P < 0.001$), all detected variables indicated a high reliability.

Data analysis

After collection, the data was entered into SPSS software version 23 (SPSS Inc., Chicago, IL, USA). Descriptive results were measured by calculating mean, standard deviation,

Fig. 4 Landmarks detection, Frontal view. (a) Pre-operation, (b) post-operation. G: Glabella—N: Nasion—Prn: Pronasal—C: Columella—Al_R: Right Alar—Ac_R: Right Alar Curvature—Ls: Labiale Superius—En: Endocanthion—Sbal: Sub Alare—Sn: Subnasal

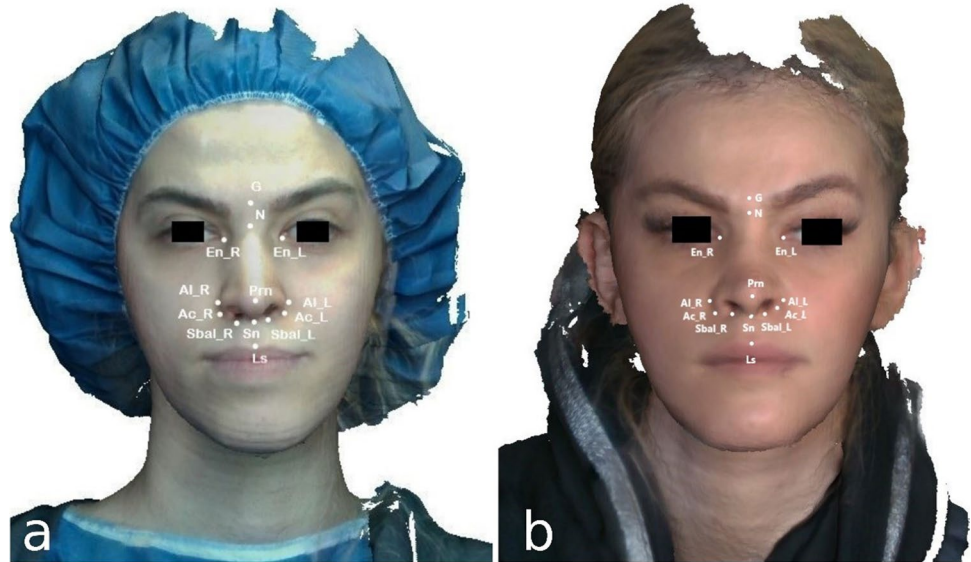


Fig. 5 Landmarks detection, lateral view. (a) Pre-operation. (b) Post-operation. 1. Nasofrontal angle. 2. Nasolabial angle. 3. Columella inclination—G: Glabella—N: Nasion—Prn: Pronasal—C: Columella—Al_R: Right Alar—Ac_R: Right Alar Curvature—Ls: Labiale Superius—Sn: Subnasal

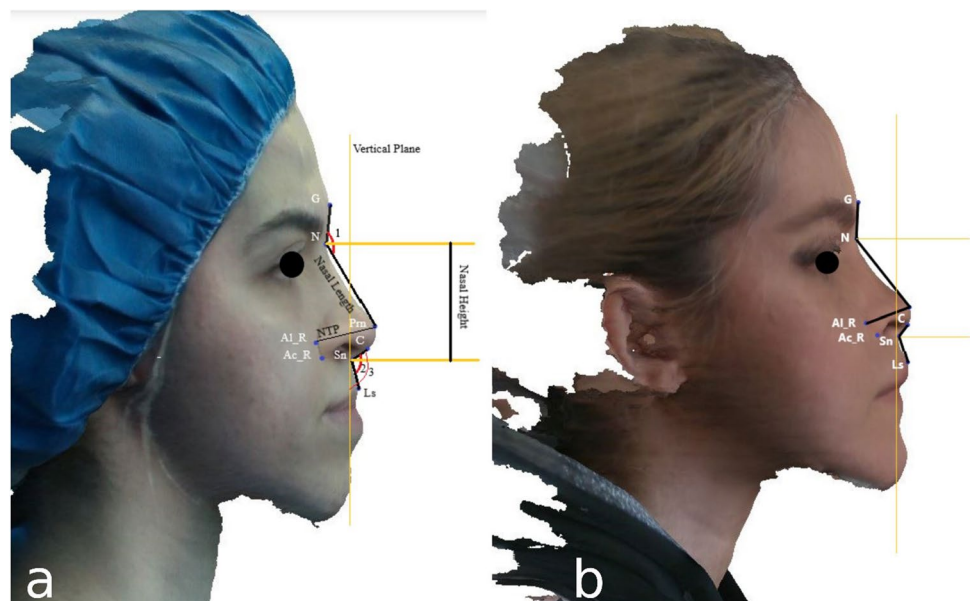
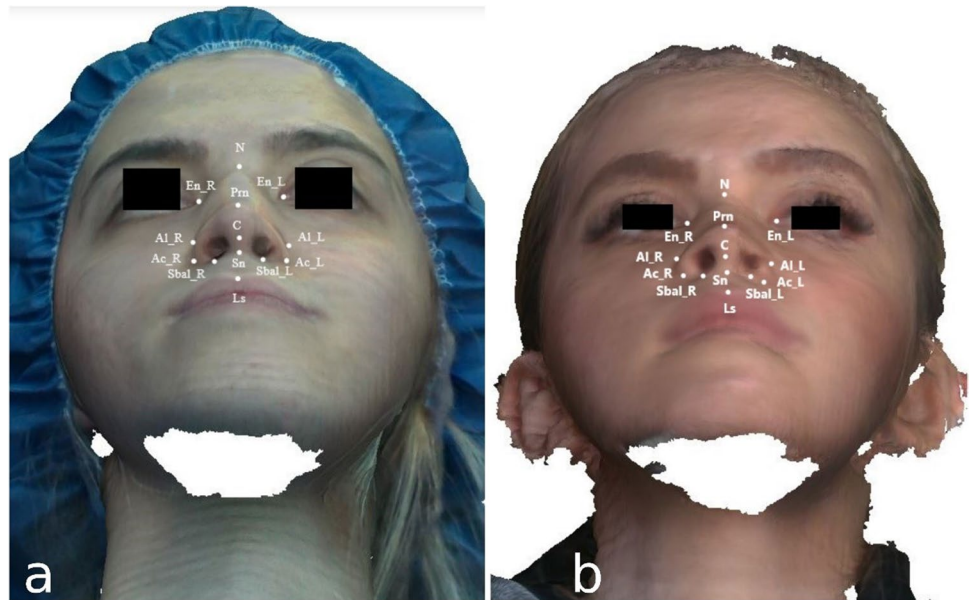


Fig. 6 Landmarks detection, inferior view. **(a)** Pre-operation. **(b)** Post-operation.—G: Glabella—N: Nasion—Prn: Pronasal – C: Columella – Al: Right Alar – Ac: Alar Curvature—Ls: Labiale Superius – Sn: Subnasal – Sbal: Subalar



frequency, and percentage. Data distribution was measured using the Kolmogorov–Smirnov test. Then, by performing an independent t-test and paired t-test, the two groups were compared. A p -value < 0.05 was considered statistically significant.

Results

This prospective clinical trial initially was performed on 29 included skeletal class III Iranian patients (Caucasians) who underwent bimaxillary orthognathic surgery

(Lefort I advancement \pm impaction plus bilateral sagittal split osteotomy for mandibular setback) in Farmaniyeh and Taleghani Hospitals in Tehran from January 2019 to January 2020. Unfortunately, because the final stages of this study coincided with the COVID-19 virus pandemic in the spring of 2020, 8 patients (4 patients from each group) whose pre-operation images were taken had to be excluded from this study for various reasons such as a referral from other cities and special systemic conditions. Thus, the number of completed and included cases decreased to 21.

In group 1, 11 patients (7 females and 4 males) underwent the Lefort I advancement surgery without impaction, and in group 2, 10 patients (5 females and 5 males) underwent the Lefort I advancement with impaction. The patients aged 18 to 46 years (mean 27.0) in the first group and 18 to 30 years (mean 21.2) in the second group. The mean intended advancement of maxilla was 4.2 ± 1.68 mm and 4 ± 1.11 mm for the first and second groups respectively. And the mean intended range of maxillary impaction for the second group was 4.5 ± 1.83 mm, which are reached by the use of mentioned surgical template. The complete demographic information of patients, including age, sex, and maxillary movement, is shown in Table 2.

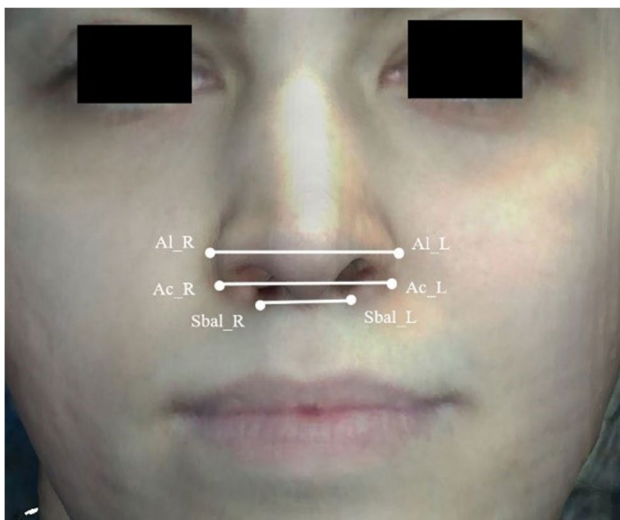

Fig. 7 Linear measurements (pre-operation)

Linear measurements

In group 1, the mean nasal height (NH) ($p = 0.006$), nasal tip projection (NTP) ($p = 0.011$), and nasal length (NL)

Table 2 Information of the subjects

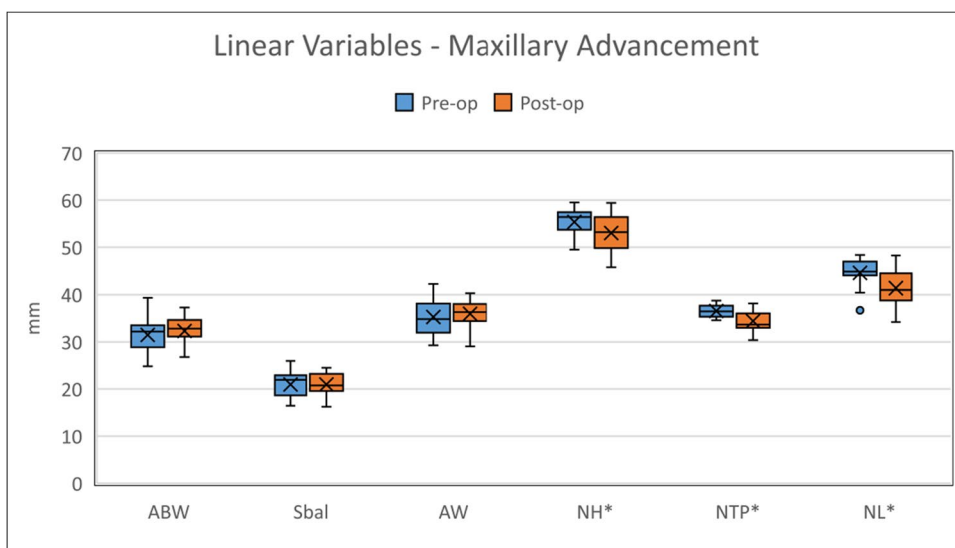
Patient information	Group I	Group II
N	11	10
Age	18–46 years Mean: 27.09	18–30 years Mean: 21.20
Gender (M/F)	4/7	5/5
Ethnicity	Caucasian	Caucasian
Type of surgery	Lefort I osteotomy (Maxillary Advancement) + mandibular setback (Bilateral sagittal split osteotomy)	Lefort I osteotomy (Maxillary Advancement with Impaction) + mandibular setback (Bilateral sagittal split osteotomy)
Malocclusion	Class III (<i>n</i> = 11)	Class III (<i>n</i> = 10)
Amount of intended maxillary movement	4.2 ± 1.68 mm advancement	4 ± 1.11 mm advancement, 4.5 ± 1.83 mm impaction

Table 3 Pre and post-operation measurements in the maxillary advancement patients (*n* = 11)

Variables	Pre-Op*	Post-Op*	Mean Difference	P-value
ABW (mm)	31.468 ± 4.096	32.311 ± 3.303	0.843	0.365
Sbal(mm)	20.964 ± 2.973	20.960 ± 2.904	-0.004	0.995
AW (mm)	35.273 ± 4.445	35.945 ± 3.278	0.672	0.333
NFA (degree)	135.350 ± 14.516	131.640 ± 17.435	-3.710	0.578
NLA (degree)	108.123 ± 11.394	113.536 ± 9.680	5.413	0.110
CI (degree)	117.370 ± 22.929	131.490 ± 20.760	14.120	0.087
NH (mm)	55.390 ± 3.415	53.020 ± 4.377	-2.370	0.006
NTP (mm)	36.539 ± 1.479	34.413 ± 2.288	-2.126	0.011
NL (mm)	44.558 ± 3.464	41.358 ± 4.087	-3.200	0.000

ABW, alar base width; Sbal, subalar width; AW, alar width; NFA, nasofrontal angle; CI, columella inclination; NH, nasal height; NTP, nasal tip projection; NL, nasal length. *mean ± SD

Fig. 8 Box plots show the median, interquartile range, 95% percentile, and outliers as circles for the linear measurements in maxillary advancement group. * indicates significant difference



(*p* = 0.000) were significantly reduced after the surgery. Additionally, no significant difference was observed in the subalar width (Sbal) average after the surgery. Alar width (AW) and alar base width (ABW) had a slight increase, but it was not significant (Table 3, Figs. 8 and 9).

In group 2, mean Sbal (*p* = 0.008), NH (*p* = 0.000), NTP (*p* = 0.003), and NL (*p* = 0.000) decreased significantly following the surgery. Although mean ABW increased more than 1 mm after the operation, it was not statistically significant (*p* = 0.074) (Table 4, Figs. 10 and 11).

Fig. 9 Box plots show the median, interquartile range, 95% percentile, and outliers as circles for the angular measurements in maxillary advancement group. * indicates significant difference

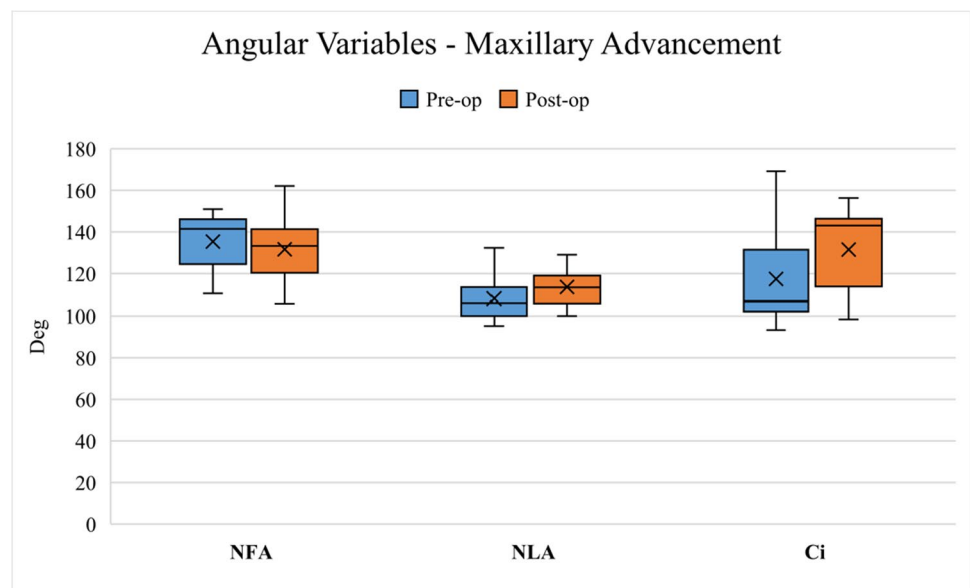


Table 4 Pre and post-operation measurements in the maxillary advancement with impaction patients ($n = 10$)

Variables	Pre-Op*	Post-Op*	Mean difference	P-value
ABW (mm)	28.417 ± 2.850	29.669 ± 2.775	1.252	0.074
Sbal (mm)	23.595 ± 2.008	20.265 ± 2.874	- 3.33	0.008
AW (mm)	34.689 ± 1.861	34.174 ± 2.441	- 0.515	0.080
NFA (degree)	135.084 ± 16.187	138.432 ± 15.959	3.348	0.377
NLA (degree)	113.584 ± 5.636	123.916 ± 9.981	10.332	0.000
CI (degree)	119.197 ± 10.629	134.317 ± 9.518	15.120	0.000
NH (mm)	54.936 ± 3.267	52.572 ± 2.908	- 2.364	0.000
NTP (mm)	38.814 ± 4.349	32.488 ± 5.082	- 6.326	0.003
NL (mm)	43.465 ± 2.608	40.114 ± 3.180	- 3.351	0.000

ABW, alar base width; Sbal, subalar width; AW, alar width; NFA, nasofrontal angle; CI, columella inclination; NH, nasal height; NTP, nasal tip projection; NL, nasal length. *mean ± SD

Angular measurements

In both groups, NLA and CI increased, but these changes were significant only in group 2 ($p = 0.000$). NFA decreased in group 1 but increased in group 2 although none of them were significant ($p = 0.578$, $p = 0.377$, respectively).

A comparison of changes seen in the soft tissue landmarks between advancement only and advancement with impaction surgeries of the 21 skeletal Class III cases along with their respective p values are shown in Table 5. NH, NL, and CI showed statistically significant changes between the two groups (P values of 0.001, 0.015, and 0.022 respectively).

Discussion

Recent advances in various clinical imaging modalities have improved the accuracy of the facial images and facilitated the 3D image acquisition not only in a less costly manner, but also providing more reliability in terms of the facial landmarks' identification compared to 2D techniques [24]. In the present study, we evaluated the nasal soft tissue alterations to reveal the changes in this area using a commercially available, low-cost 3D-photogrammetry scanner. This method can be used to assess changes in soft tissue and skin surface after orthognathic surgery more accurately than methods such as direct anthropometry,

Fig. 10 Box plots show the median, interquartile range, 95% percentile, and outliers as circles for the linear measurements in maxillary advancement with impaction group. * indicates significant difference

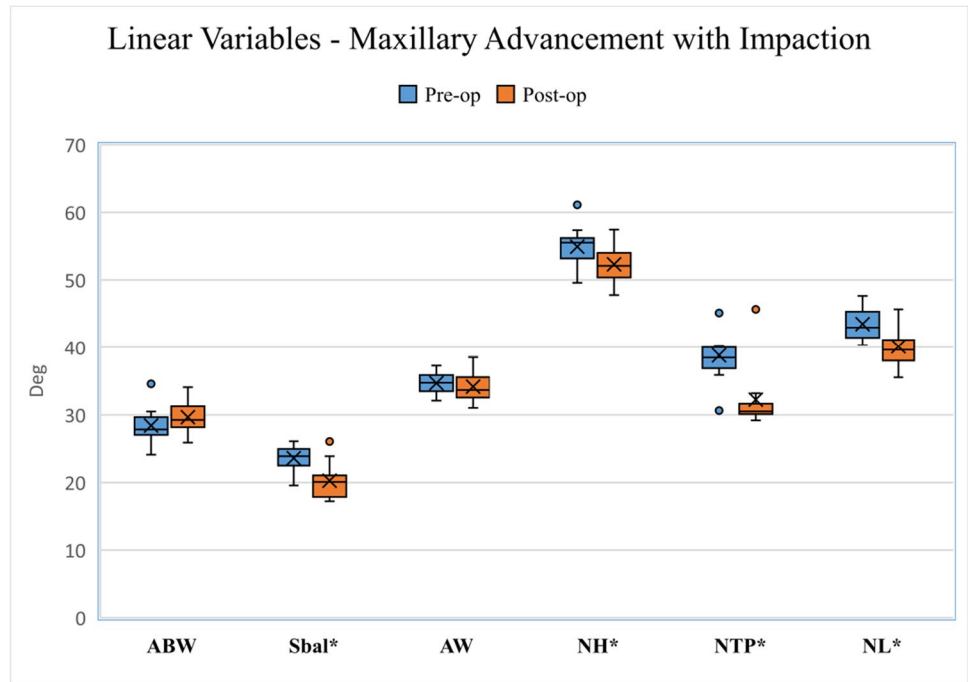
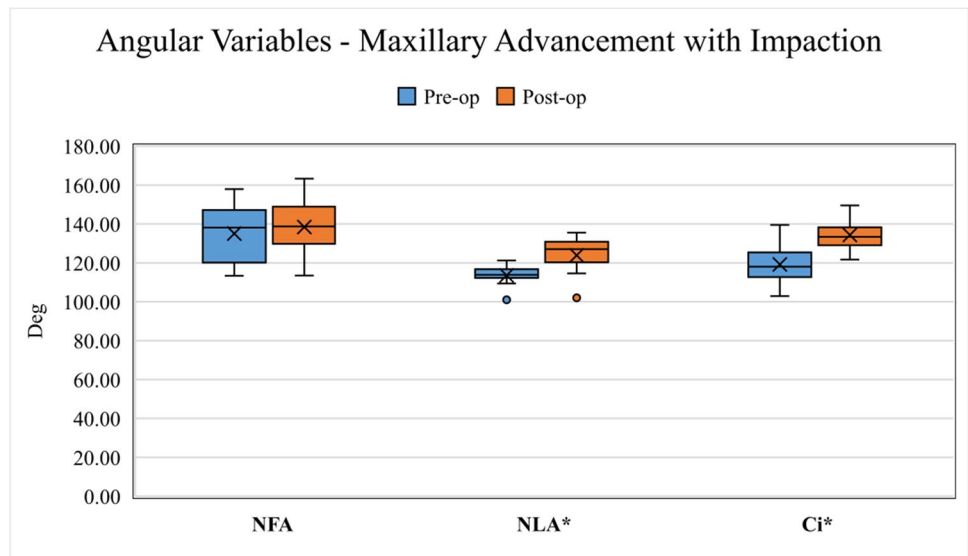


Fig. 11 Box plots show the median, interquartile range, 95% percentile, and outliers as circles for the angular measurements in maxillary advancement with impaction group. * indicates significant difference



cephalometric photography and 2D photography [12]. Additionally, this scanner is a fast and reliable device and has an error of 0.2 to 1 mm for clinical use compared to 0.5–1 mm of laser scanners [14]. Moreover, thanks to this imaging technique, our patients were exposed to lower dose of radiation compared to similar studies using CT scans [1, 25]. Additionally, this allows the clinicians to repeat images in different stages post surgically without

any concerns, benefitting from volumetric, topographic, regional, and linear evaluations [14]. Also, it allows for an easier documentation and analyses using the state-of-the-art software compared to the conventional and 2D photographs. Furthermore, one crucial advantage of 3D photogrammetry compared to 2D images is being able to standardize all images according to Yaw, Pitch, and Roll axes using the 3D image software, making it possible to

Table 5 Comparison of mean difference of variables between the two groups

Variables	Group 1 (Mean ± SD)	Group 2 (Mean ± SD)	P value
ABW (mm)	0.843 ± 5.26	1.252 ± 3.98	.123
Sbal(mm)	-0.004 ± 4.16	-3.33 ± 3.51	.499
AW(mm)	0.672 ± 5.52	-0.515 ± 3.07	.916
NFA (degree)	-3.710 ± 22.69	3.348 ± 22.73	.967
NLA (degree)	5.413 ± 14.95	10.332 ± 11.46	.193
CI(degree)	14.120 ± 30.93	15.120 ± 14.27	.022
NH(mm)	-2.370 ± 5.55	-2.364 ± 4.37	.001
NTP (mm)	-2.126 ± 2.72	-6.326 ± 6.69	.294
NL(mm)	-3.200 ± 5.36	-3.351 ± 4.11	.015

CI, confidence interval of the difference; ABW, alar base width; Sbal, subalar width; AW, alar width; NFA, nasofrontal angle; CI, columella inclination; NH, nasal height; NTP, nasal tip projection; NL, nasal length

evaluate the variables more accurately, which is hard to reach for the 2D photographs. Also, topographic surface measurement of the soft tissue is possible using these images, which is another advantage compared to 2D photographs.

Orthognathic surgery corrects the dental and facial abnormalities and creates a functional relationship between the maxilla and mandible, thus improving the coordination of the patient's facial components [11]. In this regard, it is essential to consider the esthetical outcomes of OS and changes in the soft tissues of the face in response to changes in the relevant hard tissues [26]. Maxillary repositioning osteotomies are often associated with alterations in the nose morphology [11]. These alterations, which are essential for surgical planning, might depend on the direction and the amount of the maxillary movement [10]. Thus, we evaluated the nasal soft tissue alterations via a 3D-photogrammetry scanner which also provided the benefit of enhanced patient communication thanks to the simplicity of presentation and comparison of the obtained 3D scans to the patients throughout the treatment and follow-up process.

Usually, the widening of the ABW occurs in all maxillary osteotomies by advancement or impaction [7, 10]. Trevisiol et al. reported a 0.3- and 0.5-mm increase in ABW for each mm of maxillary advancement and impaction, respectively [27]. We found that ABW in both groups insignificantly increased after the surgery. Also, two studies demonstrated a significant increase in ABW after 3D evaluation by stereophotogrammetry and facial morphometry [14, 28]. A reason for this increase is the

periosteum elevation along with the muscles and the ligaments from the anterior surface of the maxilla to stabilize the alar region [10]. Also, we found no significant difference not only in ABW but also in AW after the surgery following maxillary advancement, which indicates a positive effect on facial soft tissues' beauty and symmetry. A possible explanation for this might be the utilization of cinch suture in the present study. This finding is supported by a systematic review that reported cinch suture could effectively reduce or maintain ABW [29, 30].

An important indicator to assess alterations in the soft tissue of the nose is the change in NLA as the alterations of this angle might hurt the esthetic results of OS [26]. Anticipation of a significant increase in NLA, following more than 4 mm advancement of maxilla has been reported [31, 32]. NLA increased in both groups (only significant in group 2), with the mean increase in group 2 being higher than that of group 1. This angle is dependent on the position of three points (C, Sn, Ls). However, in our cases, the most possible determinant of these alterations would be the C point, since the CI also increased in both groups, which indicates an anticlockwise movement of the C point. However, the evidence of change in the nasal soft tissue after maxillary advancement is contradictory. Similar to the present study, Foroughi et al. reported no significant difference in NLA after maxillary advancement only based on cephalometric evaluation also, they trimmed the ANS in contrast to our study [26]. Conversely, Lai et al. reported a significant increase in NLA after maxillary advancement and clockwise rotation and without trimming ANS similar to this study [33]. On the other hand, Nagori et al. and Marsan et al. reported a decrease in NLA by cephalometric evaluation after maxillary advancement [34, 35]. The contradiction between these results may be due to differences in age, sex, race, and the time passed after surgery for obtaining the final scan. Also, reduction of ANS can be performed in Lefort I surgery to prevent/reduce the rotation of nasal tip in upward direction [4, 10, 36]. Re-contouring of ANS would possibly cause a decrease in NLA [37]. However, it is reported that this decrease is mainly a result of anterior movement of the lip apparatus rather than upturning of the nose [37]. In our study the ANS remained intact, and NLA increased in both groups (only significantly in group 2). Thus, this possibly not only prevented a reduction in NLA, but also dictated an escalation due to advancement counterclockwise movement of nasal tip. This also can be supported by the fact that CI also increased in both groups. These findings are in accordance to a study by Chen et al., in which they reported an increase in NLA with preserving ANS in Lefort I osteotomy [31]. Also,

in a recent similar study by Kilinc et al., on the same surgery method and without ANS trimming, the authors reported an increase in NLA for the maxillary advancement with impaction group, however this was not statistically significant.

Different studies have reported different NTP and NL changes after the Lefort I surgery, which may be due to differences in populations, surgical methods, clinical diagnosis, and assessment tools [12]. We observed a significant reduction in NH, NTP, and NL in both groups. Similarly, Worasakwutiphong et al. performed a 3D evaluation of class III patients after bimaxillary surgery and reported a significant decrease in NTP after both maxillary advancement with and without impaction not only in cleft, but also in non-cleft patients [12]. The advancement of the nasal base in both groups can account for this change. Having mentioned that, even small amounts of changes in the NTP would have different esthetic outcomes in different subjects, making it a crucial fact to bear in mind when discussing the surgery with patients.

NH, which is considered as the distance between Nasion and subnasale, decreased significantly in both groups. Considering the fact that the nasofrontal junction is a relatively fixed landmark in the performed procedure in this study, it is possible that the impaction of maxilla, which happened slightly in the first group as a result of the 2 mm gap produced by the usage of a burr to separate the maxilla, and in the second group intentionally as a part of the treatment plan, account for this phenomenon. In this regard, Vasudavan et al., reported the same outcome in their study on 37 maxillary advancement patients [5].

When it comes to NFA, a non-significant decrease can be seen in the advancement only group, which was consistent with a similar study by Metzler et al., in which they performed a mean of 5.5 mm of maxillary advancement and reported a significant decrease in the NFA. The mean advancement of the mentioned study was comparable with our study (4.5 mm). However, for the second group with advancement and impaction, a non-significant increase was observed. This finding was in contrast with the study by Worasakwutiphong et al., in which they reported a significant decrease of 1.28 degrees in NFA in patients who underwent maxillary advancement with impaction. The literature unraveling the changes in NFA is scarce. Hence, it could be assumed that most of the changes in NFA would be as a consequence of alterations in the position of the nasal portion of this angle (Prn point) as the nasofrontal junction would be remained relatively stable in Lefort I surgery.

A limitation in this study was losing access to 8 patients, who were initially enrolled in, due to the

Covid-19 pandemic. Therefore, we suggest further investigations with bigger sample sizes to better evaluate the nasal soft tissue changes after the Lefort I advancement using 3D scanners according to age, sex, ethnicities, and factors such as Cinch sutures that might influence the nasal soft tissue changes. Also, a possible shortcoming of the utilized imaging method would be the possible inability to understand the skeletal origin of the changes in soft tissue. For instance, regarding the changes in NH, it was impossible to understand whether the changes are a consequence of the movement of subnasal or not, making it necessary to acquire further radiographic scans, should we require to evaluate the nature of the changes. Similarly, to evaluate the exact amount of movements of maxilla, comparison of the underlying hard tissue pre- and post-operatively using radiographic images (e.g. lateral cephalograms) are necessary and 3D scanners possess limitations in this regard. In summary, the 3D photogrammetry imaging technique will allow the clinicians for acquiring a serial of images during the pre- and post-operative phases as well as a quantitative evaluation of the facial soft tissue. Additionally, confounding factors to this study includes the lack of a control group, errors associated with the surgical planning and fabrication of the surgical guides and variations in the anatomic points. Finally, the evaluation of the long-term outcomes of these procedures, by longitudinal follow-up studies would also be beneficial as the data pointing out this is relatively scarce in the literature. Lastly, the mentioned changes in nasal soft tissue may have different effects on appearance among people of different races due to differences in perception of beauty among societies. Therefore, the surgeon should be aware of these changes and discuss their post-operation possibilities with patients.

Conclusion

First and foremost, this study supported the fact that 3D photogrammetry imaging would be a promising method in the evaluation of facial soft tissue for orthognathic surgery candidates, providing several benefits compared to 2D images and radiographs. Using the mentioned evaluation process, various changes were observed after maxillary advancement with and without impaction. In patients without impaction, NLA increased significantly. In patients with impaction, NLA and CI increased significantly, while there was a significant reduction in Sbal, NH, NL, and NTP. Finally, cinching suture could reduce the amount of widening of the alar base.

Appendix 1

Table 6

Table 6 The anthropometric landmark points, lines and angles and their definitions

Points		
Tr	Tragus	Ridge points on the rim of the tragus, terminating with the superior and inferior points of maximum curvature at the margins of the tragus
Al	Alar	The most lateral point on each alar contour
Ac	Alar Curvature	The point of insertion of the Nasal Base to the facial soft tissue
Sbal	Subalar	The point where the nasal septum merges with the upper cutaneous lip in the mid-sagittal plane
En	Endocanthion	The soft tissue point located at the inner commissure of each eye fissure
G	Glabella	the smooth part of the forehead above and between the eyebrows
N	Nasion	The mid-point on the soft tissue contour of the base of the nasal root at the level of the fronto-nasal suture
Ls	Labiale Superius	The mid-point of the vermilion line of the upper lip
Prn	Pronasal	The most anterior mid-point of the nasal tip
Sn	Subnasal	The point where the nasal septum merges with the upper cutaneous lip in the mid-sagittal plane
C	Columella	The skin that separates two nostrils
Angular Landmarks		
NFA	Nasofrontal Angle	Angle between two lines connecting Glabella to Nasion and from Nasion to nasal dorsum (G-N-Prn)
NLA	Nasolabial Angle	Angle between two lines connecting the upper limit of the columella to the subnasal and from the subnasal to the upper limit of the upper lip (C-Sn-Ls)
Ci	Columella Inclination	The angle between the line passing through the columella and the subnasal with the vertical axis
Linear Landmarks		
Al_Al	Alar Width (AW)	Maximum distance between right and left alars
Ac_Ac	Alar Base Width (ABW)	The distance between the right and left alar curvatures
Sbal_Sbal	Subalar Width (Sbal)	The distance between the lower limits of the right and left alar
NH	Nasal Height	Distance between Nasion and Subnasal on the Y axis
NL	Nasal Length	Distance between Nasion and Pronasal
NTP	Nasal Tip Projection	The distance between Nasal Alar and Pronasal in the lateral view of the face

Appendix 2

Table 7

Table 7 The accuracy of GOM Inspect 2019 Software (Source: www.gom.com/en/products/gom-suite/gom-inspect-pro)

Accuracy	Type of measurement
0.001 mm	Linear Measurements
0.01 Rad	Angular Measurements

Declarations

Ethics approval This study was approved by the Clinical Research Ethics Committee of Shahid Beheshti University of Medical Sciences (IR.SBMU.DRC.REC.1398.020).

This study is registered in Iranian Registry of Clinical Trials (IRCT) (clinical trial code: IRCT20200726048214N1).

Informed consent Informed consent was obtained from all individual participants included in the study.

Consent to participate Written informed consent was obtained from all participants.

Consent for publication Written informed consent was obtained from all participants.

Conflict of interest The authors declare no competing interests.

References

- Jeong HI, Lee HS, Jung YS, Park HS, Jung HD (2017) Nasal soft tissue change following bimaxillary orthognathic surgery. *J Craniofac Surg* 28(7):e605–e608
- Hemmatpour S, Kadkhodaei Oliadarani F, Hasani A, Rakhshan V (2016) Frontal-view nasolabial soft tissue alterations after bimaxillary orthognathic surgery in Class III patients. *J Orofac Orthop* 77(6):400–408
- Buchanan EP, Hyman CH (2013) LeFort I Osteotomy. *Semin Plast Surg* 27(3):149–154
- Mommaerts MY, Lippens F, Abeloos JV, Neyt LF (2000) Nasal profile changes after maxillary impaction and advancement surgery. *J Oral Maxillofac Surg* 58(5):470–5 (discussion 5–6)
- Vasudavan S, Jayaratne YSN, Padwa BL (2012) Nasolabial soft tissue changes after Le Fort I advancement. *J Oral Maxillofac Surg* 70(4):e270–e277
- Atakan A, Özçirpici AA (2021) Correlation between cephalometric nasal changes and patients' perception after orthognathic surgery. *Am J Orthod Dentofac Orthop* 159(6):e449–e460
- Sabri H, Sarkarat F, Aghajani D (2021) Review of nasal soft tissue alterations in class III malocclusion patients following Lefort I Osteotomy. *Res-Dent-Sci* 18(4):302–310
- Zhao YJ, Xiong YX, Wang Y (2017) Three-dimensional accuracy of facial scan for facial deformities in clinics: a new evaluation method for facial scanner accuracy. *PLoS ONE* 12(1):e0169402
- Koban KC, Giunta RE (2016) Using mobile 3D scanning systems for objective evaluation of form, volume, and symmetry in plastic surgery: intraoperative scanning and lymphedema assessment. In: *Proc. of 7th Int. Conf. on 3D Body Scanning Technologies*, Lugano. <https://doi.org/10.15221/16.130>
- Khamashta-Ledezma L, Naini FB, Manisali M (2017) Review of nasal changes with maxillary orthognathic surgery. *J Istanbul Univ Fac Dent* 51(3 Suppl 1):S52–S61. <https://doi.org/10.17096/jiufd.09789>
- Hellak AF, Kirsten B, Schauseil M, Davids R, Kater WM, Korbmacher-Steiner HM (2015) Influence of maxillary advancement surgery on skeletal and soft-tissue changes in the nose - a retrospective cone-beam computed tomography study. *Head Face Med* [Internet]. 2015; 11:[23 p.]. Available from: <http://europepmc.org/abstract/MED/26152559>, <https://doi.org/10.1186/s13005-015-0080-y>, <https://europepmc.org/articles/PMC4495703>, <https://europepmc.org/articles/PMC4495703?pdf=render>
- Worasakwutiphong S, Chuang Y-F, Chang H-W, Lin H-H, Lin P-J, Lo L-J (2015) Nasal changes after orthognathic surgery for patients with prognathism and Class III malocclusion: analysis using three-dimensional photogrammetry. *J Formos Med Assoc* 114(2):112–123
- Nkenke E, Langer A, Laboureux X, Benz M, Maier T, Kramer M et al (2003) Validation of in vivo assessment of facial soft-tissue volume changes and clinical application in midfacial distraction: a technical report. *Plast Reconstr Surg* 112(2):367–380
- Coban G, Yavuz I, Karadas B, Demirbas AE (2020) Three-dimensional assessment of nasal changes after maxillary advancement with impaction using stereophotogrammetry. *Korean J Orthodont* 50(4):249–257
- Maal TJ, van Loon B, Plooi JM, Rangel F, Ettema AM, Borstlap WA et al (2010) Registration of 3-dimensional facial photographs for clinical use. *J Oral Maxillofac Surg* 68(10):2391–2401
- Jung J, Lee C-H, Lee J-W, Choi B-J (2018) Three dimensional evaluation of soft tissue after orthognathic surgery. *Head face Med* 14(1):21
- Ghorbanyjavadpour F, Rakhshan V (2019) Factors associated with the beauty of soft-tissue profile. *Am J Orthod Dentofac Orthop* 155(6):832–843
- Gill DS, Lloyd T, East C, Naini FB (2017) The facial soft tissue effects of orthognathic surgery. *Facial Plast Surg* 33(05):519–525
- Farkas LG (1994) Examination. *Anthropometry of the head and face*. Raven Press, New York
- Metzler P, Sun Y, Zemann W, Bartella A, Lehner M, Obwegeser JA et al (2014) Validity of the 3D VECTRA photogrammetric surface imaging system for cranio-maxillofacial anthropometric measurements. *Oral Maxillofac Surg* 18(3):297–304
- Lübbbers H-T, Medinger L, Kruse A, Grätz KW, Matthews F (2010) Precision and accuracy of the 3dMD photogrammetric system in craniomaxillofacial application. *J Craniofac Surg* 21(3):763–767
- Wong JY, Oh AK, Ohta E, Hunt AT, Rogers GF, Mulliken JB et al (2008) Validity and reliability of craniofacial anthropometric measurement of 3D digital photogrammetric images. *Cleft Palate Craniofac J* 45(3):232–239
- Nkenke E, Vairaktaris E, Kramer M, Schlegel A, Holst A, Hirschfelder U et al (2008) Three-dimensional analysis of changes of the malar–midfacial region after LeFort I osteotomy and maxillary advancement. *Oral Maxillofac Surg* 12(1):5–12
- Verzé L, Bianchi FA, Ramieri G (2014) Three-dimensional laser scanner evaluation of facial soft tissue changes after LeFort I advancement and rhinoplasty surgery: patients with cleft lip and palate vs patients with nonclefted maxillary retrognathic dysplasia (control group). *Oral Surg Oral Med Oral Pathol Oral Radiol* 117(4):416–423
- Almukhtar A, Ayoub A, Khambay B, McDonald J, Ju X (2016) State-of-the-art three-dimensional analysis of soft tissue changes following Le Fort I maxillary advancement. *Br J Oral Maxillofac Surg* 54(7):812–817
- Foroughi R, Khakbaz O, Maneshi M (2019) Middle and lower facial soft tissue changes after maxillary advancement through conventional or high Le Fort I osteotomy. *J Craniomaxillofac Res* 6(1):39–50
- Trevisiol L, Lanaro L, Favero V, Lonardi F, Vania M, D'Agostino A (2020) The effect of subspinal Le Fort I osteotomy and alar cinch suture on nasal widening. *J Craniomaxillofac Surg* 48(9):832–838
- Ferrario VF, Sforza C, Schmitz JH, Santoro F (1999) Three-dimensional facial morphometric assessment of soft tissue changes after orthognathic surgery. *Oral Surg Oral Med Oral Pathol Oral Radiol Endod* 88(5):549–556

29. Liu X, Zhu S, Hu J (2014) Modified versus classic alar base sutures after LeFort I osteotomy: a systematic review. *Oral Surg Oral Med Oral Pathol Oral Radiol* 117(1):37–44
30. Trevisiol L, Lanaro L, Favero V, Lonardi F, Vania M, D'Agostino A (2020) The effect of subspinal Le Fort I osteotomy and alar cinch suture on nasal widening. *J Cranio-Maxillofac Surg* 48(9):832–838
31. Chen CY, Lin CC, Ko EW (2015) Effects of two alar base suture techniques suture techniques on nasolabial changes after bimaxillary orthognathic surgery in Taiwanese patients with class III malocclusions. *Int J Oral Maxillofac Surg* 44(7):816–822
32. Ryckman MS, Harrison S, Oliver D, Sander C, Boryor AA, Hohmann AA et al (2010) Soft-tissue changes after maxillo-mandibular advancement surgery assessed with cone-beam computed tomography. *Am J Orthod Dentofacial Orthop* 137(4 Suppl):S86-93
33. Lai H-C, Denadai R, Ho C-T, Lin H-H, Lo L-J (2020) Effect of Le Fort I maxillary advancement and clockwise rotation on the anteromedial cheek soft tissue change in patients with skeletal class III pattern and midface deficiency: a 3D imaging-based prediction study. *J Clin Med* 9(1):262
34. Nagori H, Fattahi T (2017) Maxillary advancement surgery and nasolabial soft tissue changes. *IOSR J Dent and Med Sci* 3:23–29
35. Marşan G, Cura N, Emekli U (2009) Soft and hard tissue changes after bimaxillary surgery in Turkish female Class III patients. *J Cranio-Maxillofac Surg* 37(1):8–17
36. Freihofe Jr HPM (1977) Changes in nasal profile after maxillary advancement in cleft and non-cleft patients. *J Maxillofac Surg* 5:20–27
37. Conley RS, Boyd SB (2007) Facial soft tissue changes following maxillomandibular advancement for treatment of obstructive sleep apnea. *J Oral Maxillofac Surg* 65(7):1332–1340

Publisher's note Springer Nature remains neutral with regard to jurisdictional claims in published maps and institutional affiliations.

Springer Nature or its licensor holds exclusive rights to this article under a publishing agreement with the author(s) or other rightsholder(s); author self-archiving of the accepted manuscript version of this article is solely governed by the terms of such publishing agreement and applicable law.