

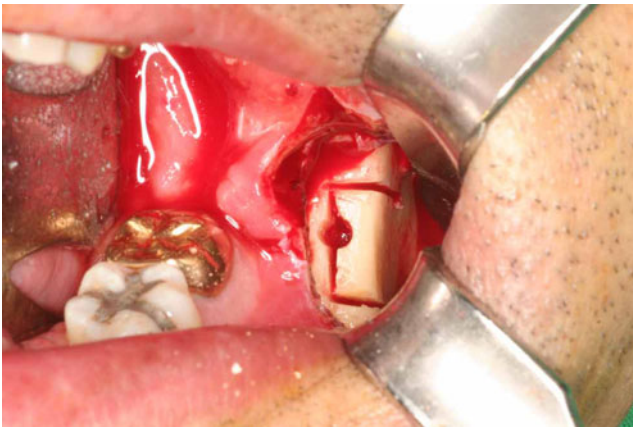
## Erratum to: Modified veneer bone graft with the concomitant installation of a dental implant: technical note

Seong-Gon Kim · Ji-Young Song · Yong-Chan Lee

Published online: 17 May 2011  
© Springer-Verlag 2011

**Erratum to: Oral Maxillofac Surg**  
**DOI 10.1007/s10006-011-0271-z**

The author wishes to apologize for inadvertently providing the wrong image for Fig. 2. Here is the correct image:



**Fig. 2** Using a sagittal saw, three osteotomy lines were designed on the outer cortical bone

The online version of the original article can be found at <http://dx.doi.org/10.1007/s10006-011-0271-z>.

S.-G. Kim (✉) · J.-Y. Song  
Department of Oral and Maxillofacial Surgery,  
College of Dentistry, Gangneung-Wonju National University,  
Gangneung, Gangwondo 210–702, Republic of Korea  
e-mail: epker@chol.com

Y.-C. Lee  
Department of Oral and Maxillofacial Surgery, Bestian Hospital,  
Seoul, Republic of Korea